



# Toxicological studies in poultry consuming fumonisin from corn contaminated with Brazilian Amazonian flora

## Estudios toxicológicos en aves de corral que consumen fumonisin de maíz contaminado con flora amazónica brasileña

Oelton Rosa Júnior<sup>1</sup>; Alex Sander Rodrigues Cangussu<sup>2</sup>; Ana Patrícia Carvalho da Silva<sup>3</sup>; Kenia Ferreira Rodrigues<sup>4</sup>; Mellanie Karoline do Carmo Félix<sup>5</sup>; Túllio Teixeira Deusdará<sup>6</sup>; Tatiani Pereira de Souza Ferreira<sup>7</sup>; Hélio de Sousa Brito<sup>8</sup>; Kelvinson Fernandes Viana<sup>9</sup>; Eliane Macedo Sobrinho<sup>10</sup>; Raimundo Wagner Souza Aguiar<sup>11</sup>; Gil Rodrigues dos Santos<sup>12</sup>

### ARTICLE DATA

- 1 Researcher, Ph.D. Universidade Federal do Tocantins, Gurupi, Brasil, [oelton.junior@gmail.com](mailto:oelton.junior@gmail.com)  
<https://orcid.org/0000-0002-8177-3480>
- 2 Professor, Ph.D. Universidade Federal do Tocantins, Gurupi, Brasil, [alexangussu@mail.uft.edu.br](mailto:alexangussu@mail.uft.edu.br)  
<https://orcid.org/0000-0003-2664-8027>
- 3 Professor, Ph.D. Universidade Federal do Tocantins, Gurupi, Brasil, [apcarvalhosilva@gmail.com](mailto:apcarvalhosilva@gmail.com)  
<https://orcid.org/0000-0003-0570-0711>
- 4 Professor, Ph.D. Universidade Federal do Tocantins, Gurupi, Brasil, [rodrigueskf@uft.edu.br](mailto:rodrigueskf@uft.edu.br)  
<https://orcid.org/0000-0002-2750-8870>
- 5 Researcher, MSc. Universidade Federal do Tocantins, Gurupi, Brasil, [mellanielorak@hotmail.com](mailto:mellanielorak@hotmail.com)  
<https://orcid.org/0000-0001-7776-4672>
- 6 Researcher, MSc. Universidade Federal do Tocantins, Gurupi, Brasil, [tullio@mail.uft.edu.br](mailto:tullio@mail.uft.edu.br)  
<https://orcid.org/0000-0002-7566-0631>
- 7 Researcher, MSc. Universidade Federal do Tocantins, Gurupi, Brasil, [nanatpsf@yahoo.com.br](mailto:nanatpsf@yahoo.com.br)  
<https://orcid.org/0000-0001-9680-0616>
- 8 Researcher, MSc. Universidade Federal do Tocantins, Gurupi, Brasil, [hellyosousa1245@gmail.com](mailto:hellyosousa1245@gmail.com)  
<https://orcid.org/0000-0002-6785-0267>
- 9 Professor, Ph.D. Universidade Federal da Integração Latino-Americana, Foz do Iguaçu-PR, Brasil, [kelvinson.viana@unila.edu.br](mailto:kelvinson.viana@unila.edu.br)  
<https://orcid.org/0000-0002-7806-0519>
- 10 Professor, Ph.D. Instituto Federal do Norte Minas Gerais, Araçuaí-MG, Brasil, [eliane.santos@ifnmg.edu.br](mailto:eliane.santos@ifnmg.edu.br)  
<http://orcid.org/0000-0002-1576-4957>
- 11 Professor, Ph.D. Universidade Federal do Tocantins, Gurupi, Brasil, [rwsa@uft.edu.br](mailto:rwsa@uft.edu.br)  
<https://orcid.org/0000-0002-5169-4968>
- 12 Professor, Ph.D. Universidade Federal do Tocantins, Gurupi, Brasil, [gilrsan@mail.uft.edu.br](mailto:gilrsan@mail.uft.edu.br)  
<https://orcid.org/0000-0002-3830-9463>

**Cite:** Júnior, O.; Cangussu, A.; Silva, A.; Rodrigues, K.; Félix, M.; Deusdará, T.; Ferreira, T.; Brito, H.; Viana, K.; Sobrinho, E.; Aguiar, R.; dos Santos, G. (2022). Toxicological studies in poultry consuming fumonisin from corn contaminated with Brazilian Amazonian flora. *Revista de Ciências Agrícolas*. 39(2): 56-68.  
doi: <https://doi.org/10.22267/rcia.223902.182>

Received: December 23 2021.  
Accepted: August 30 2022.

### ABSTRACT

The fungus *Fusarium verticillioides* produces fumonisins (FB1 and FB2), characterized by being the most frequently produced molecular forms and with greater toxicity. Fumonisin contamination is responsible for substantial losses during the meat production chain, so the safe levels of these compounds must be determined. The study was directed to establish safe levels of FB1 in poultry production; for this purpose, were used COBB 500® birds on experimental lots of infected corn during the 2015/2016 season in Brazil. The experimental group included 160 animals, divided into two groups: The T1 without fumonisin in the diet (control); and the T2 group in which corn was contaminated with 2.78 µg/g of fumonisin FB1. Histopathological effects of liver, heart, and small intestine, and zootechnical parameters were measured in birds treated. We found that there were no significant differences between the birds treated and untreated after 21 days of exposure to each treatment; F-values > P-values ( $P < 0,05$ ) for feed intake and weekly weight gain. Taken together, our data showed that the concentration evaluated is safe in poultry and will contribute to the design of future clinical studies.

**Keywords:** mycotoxins; corn meal; feed contamination.

### RESUMEN

El hongo *Fusarium verticillioides* produce fumonisinas (FB1 y FB2), caracterizadas por ser las formas moleculares más frecuentemente producidas y con la toxicidad más significativa. La contaminación por fumonisinas es responsable de pérdidas sustanciales durante la cadena de producción de carne por lo que niveles seguros de estos compuestos deben ser determinados. Este estudio pretende establecer niveles seguros de FB1 en la producción avícola; para ello, se utilizaron aves COBB 500® en lotes experimentales de maíz infectado durante la temporada 2015/2016 en Brasil. El grupo experimental incluyó 160 animales, divididos en dos grupos: T1 sin fumonisinas en la

dieta (control); y el grupo T2 en el que el maíz fue contaminado con 2,78µg/g de fumonisina FB1. Fueron medidos los efectos histopatológicos en hígado, corazón e intestino delgado y parámetros zootécnicos en aves tratadas. No se encontraron diferencias significativas entre las aves tratadas y el control después de 21 días de exposición, para consumo de alimento y ganancia de peso semanal. En conjunto, los resultados muestran que la concentración de FB1 evaluada es segura en aves de corral y contribuirán al diseño de futuros estudios clínicos.

**Palabras clave:** micotoxinas; harina de maíz; contaminación del alimento.

## INTRODUCTION

Climate variability and global warming strongly affect agricultural food production in particular regions as tropical and subtropic areas of the world. Brazil is one of the largest producers and exporters of poultry and livestock products globally, and the performance of this market may be affected by variations in the quality of soybean and corn crops, which are primary substrates used in animal feed (Bhardwaj *et al.*, 2021). Increases in the quality and productivity of the corn crop due to geographical expansion and the diffusion of new technologies, combined with a good diet and inherent conditions linked to the species, enhances the development of the avian market (Venkataramana *et al.*, 2014).

There are reports of corn crops produced at various times of the year with the increasing appearance of phytopathogenic microorganisms that provoke the production of mycotoxins (Shen *et al.*, 2018; Bhardwaj *et al.*, 2021). The primary toxigenic organisms belong to the genera *Fusarium*, *Aspergillus*, and *Penicillium* (Bhardwaj *et al.*, 2021). *Fusarium verticillioides* produces fumonisin, a toxic secondary metabolite (Priyanka *et al.*, 2015; Shen *et al.*, 2018).

Fumonisin production depends on the expression of biosynthetic enzymes that depend on environmental and nutritional factors via several signaling pathways (Walker *et al.*, 2016). Contamination with toxins FB<sub>1</sub>

and FB<sub>2</sub> produced by *F. verticillioides* (Van Cleemput *et al.*, 2019) occurs at various stages of corn production, causing rotting and seedling rust, posing risks for all sectors involved in food manufacture (Morales *et al.*, 2019; Oldenburg *et al.*, 2017).

There are possible risks associated with the production of the corn crop at various stages of production; these involve rot and rust of seedlings that risk reducing the quality of the products and compromising food manufacture distribution channel. These contaminations also generate economic losses for agribusiness, attributable to the disposal of food or feed. There are also public health risks associated with poor performance and immunosuppression (Oldenburg *et al.*, 2017; Morales *et al.*, 2019).

Fumonisin have 28 analogs divided into four groups, identified as series A, B, C, and P (Bhardwaj *et al.*, 2021; Shen *et al.*, 2018). The B series (FB<sub>1</sub>, FB<sub>2</sub> and FB<sub>3</sub>) contains the most relevant fumonisin and are the molecular forms most often produced by *F. verticillioides* with the most significant toxicity (Lerda, 2017). FB<sub>1</sub> is widely distributed geographically and frequently occurs in corn (Lerda, 2017). Foods contaminated with FB<sub>1</sub> can lead to diseases such as leukoencephalomalacia in horses (Van Cleemput *et al.*, 2019) pulmonary edema in pigs (Haschek *et al.*, 1992), nephrotoxicity in rodents, and esophageal cancer in humans (Van Cleemput *et al.*, 2019). In poultry, the toxin causes

variations in immunity, characterized by hepatic congestion (Murugesan *et al.*, 2015), intestinal congestion (Bouhet & Oswald, 2007), necrotic enteritis, and coccidiosis (Grenier *et al.*, 2016).

There are reports that in birds fed with the presence of fumonisin, there are changes in immunity due to immunosuppression, decreases in humoral immunity, and suppression of lymphocytes with hepatic congestion (Murugesan *et al.*, 2015), intestinal congestion (Bouhet & Oswald, 2007), necrotic enteritis, and coccidiosis (Grenier *et al.*, 2016). Murugesan *et al.* (2015) and Yarru *et al.* (2009) found that concentrations of 1.0mg/kg and 2.0mg/kg of AFB 1 caused decreases in hepatic gene expression of superoxide dismutase, glutathione S-transferase and with an increase in the relative gene expression Interleukin 6 and cytochrome p450 1A1 and 2H1 (Yarru *et al.*, 2009). In birds fed 2.0mg/kg of AFB 1, other liver genes were negatively regulated, including those associated with energy production and fatty acid metabolism (carnitine palmitoyltransferase), growth and development (insulin-like growth factor 1), antioxidant protection (glutathione S-transferase), detoxification (epoxide hydrolase), coagulation (coagulation factors IX and X), and immune protection (interleukins). By contrast, genes associated with cell proliferation (ornithine decarboxylase) were positively regulated (Yarru *et al.*, 2009).

The contamination of birds with FB1 negatively affects international trade and the economies of developed countries, giving rise to stricter supplier standards. Regulatory controls prevent the importation and local sale of products contaminated with fumonisin, directly affecting international trade in food products and feed (Alberts *et al.*, 2016). In this context, it is essential to focus on preventing factors that can affect

poultry performance and production. FB<sub>1</sub> contamination adversely affects international trade and the economies of developed countries, giving rise to more stringent supplier standards. Regulatory controls prevent the importation and the local commercialization of products contaminated with fumonisin, directly affecting the international trade of food products and feed (Alberts *et al.*, 2016).

It is essential to focus on the prevention of factors that may affect performance and poultry production. For this reason, it is essential to study the impact of FB1 on the poultry production chain. Therefore, our main objective was to identify a practical situation in which a corn crop from the 2015/2016 harvest could be proven to be infected by *F. verticillioides* to establish safe levels of this mycotoxin by evaluating crops in the 2015/2016 years using experimental culture from commercial hybrids. We also determined the zootechnical and histopathological parameters that would allow establishing minimum concentrations of FB1 that did not cause toxicological damage in birds of the COBB 500<sup>®</sup> lineage and contribute to the design of future studies involving the use of corn for human consumption.

## MATERIALS AND METHODS

**Identification, and susceptibility analysis of corn hybrids infected by *Fusarium* spp.** This material was obtained from crops located in Gurupi city from Tocantins/Brazil (11°43'45"S/49°04'07"W). We created a mini-station to mimic a favorable microclimate at the Federal University of Tocantins, and we evaluated the selection of hybrids of commercial corn with greater susceptibility to *Fusarium* spp. Ten commercial hybrids were infected. For the isolation of the pathogen, symptomatic seeds were used and

analyzed for the presence of *F. verticillioides*. Then, the fungus was transferred to Petri dishes containing BDA culture medium (200g potato, 20g dextrose, 20g agar, and 1000mL of distilled water). The isolates were identified based on their typical morphology, characterized by the presence of long chains of microconidia produced in monofials. The image was taken under a Leica DM1000 LED optical microscope Leica DM1000 LED (Software Application Suite version 4.9.0) with 100x objectives, coupled with a microcomputer and digital camera Leica.

The monosporic culture technique was used, in which a suspension of conidia of the fungus was placed in 5mL of distilled and sterilized water in Petri dishes containing agar-agar culture medium (2%). After 24 hours of incubation at room temperature, germinated conidia were observed. The germinated conidia were isolated in experimental tubes and Petri dishes containing BDA culture medium. Koch's postulates were satisfied in healthy plants of the hybrid 32R48YH, at phenological stage R1, with inoculations of the fungus suspension in the style-stigmas with  $5 \times 10^5$  conidia/mL. Samples were sent to the Agronomic Laboratory (Campinas, SP) for PCR analysis and genetic sequencing. DNA from *F. verticillioides* was extracted according to the protocol described by Doyle & Doyle (1990) using partial amplification of the specific calmodulin gene of 578bp. The primers were used Ver-1 (5'-CTT CCT GCG ATG TTT CTCC-3') and Ver-2 (5'-AAT TGG CCA TTG GTA TTA TAT ATCTA-3'). The purpose was to perform sequencing using specific primers to amplify and analyze the ITS1-5.8S regions of the calmodulin 578bp gene sequence that is a reference for identifying *F. verticillioides* (Rosa Júnior *et al.*, 2019).

**PCR assay.** The PCR reaction for the detection of *F. verticillioides* was carried out using a

mixture of 5.0µL of the buffer (100mM Tris-HCl pH 8.5, 500mM KCl 1X), 1.0µL of dNTPs (0.2mM), 1.5µL of MgCl<sub>2</sub>, 2.5µL of sense and antisense primers (0.5mM), 1.0µL of Taq DNA polymerase (LGC) enzyme (5U/µL) and 5.0µL of total DNA. The final reaction volume was adjusted with Milli-Q water to 50.0µL. The thermocycler regime for this reaction was 95°C for 5 minutes, 25 cycles of 1.5 minutes at 95°C, 1.5 minutes at 62°C, 1.5 minutes at 72°C, and a final extension step at 72°C for 10 minutes. This amplification product was subjected to conventional electrophoresis on a 1% agarose gel and visualized on a UV transilluminator.

**Feed formulation.** Ears with contaminated corn kernels were harvested in the phenological phase R6 (physiological maturity 98) and placed in automatic dryers, crushed, and ground for feeding birds in the T2 group (those give contaminated feed). A T1 control group was established consisting of birds fed with contamination-free feed. COBB 500® birds were used to evaluate the effect of *F. verticillioides* FB1 on zootechnical performance and histopathological damage. There was no addition of antibiotics or chemotherapeutic agents, or products of animal origin in any feed. The birds were monitored for 21 days to assess zootechnical performance and histopathological damage.

**Analysis of fumonisin in corn hybrids.** Samples of contaminated feed and control were sent to the Laboratory of Analytical Mycotoxicology (LAMIC) of the Federal University of Santa Maria (Santa Maria, RS). Ten grams of sample were crushed through 2.0-mm meshes and extracted with 50-mL water/acetonitrile (1:1, v/v) for 5 min in a high-speed blender. The extracts were then filtered; 20mL aliquots were diluted in acetonitrile/water with formic acid 1% (1:1, v/v) and subsequently analyzed using liquid chromatography-mass spectrometry (LC-

MS/MS), according to Dall'Asta *et al.* (2008), to determine the presence, concentration, and type of fumonisin FB1 and FB2. These values were calculated based on the calibration curve at six concentration levels ranging from 125 to 10,000mg/kg of FB1 and FB2 purified standard (Sigma Aldrich).

### **Experimental design in COBB 500 birds.**

The experiments design in COBB 500® birds were conducted in the experimental aviary of Veterinary Medicine and Animal Science at the Federal University of Tocantins, at the campus of Araguaína city, Tocantins/Brazil (07°11'28"S / 48°12'26"W). We used chicks of the COBB 500® strain on their first day of life. The mean weight was 38.7g. We randomly distributed the chicks in experimental cages to consume feed until the 21<sup>st</sup> day of life. They were distributed in a completely randomized experimental design with two treatments, T1 (feed without fumonisin) and T2 (corn contaminated with micotoxins from fungi at 2.78µg/g). The experimental group included 160 animals, divided into two groups: T1 without treatment, that is, the control group with no fumonisin in the diet; and the T2 group in which corn was contaminated with 2.78µg/g of fumonisin. The experimental group was distributed in a completely randomized design with two T1 and T2 treatments with ten replicates and eight birds in each group. On the 1<sup>st</sup> day of age, the birds were weighed and randomly distributed in the cages of each experimental group, receiving diets without fumonisin (Group T1) and diets with fumonisin at 2.78µg/g (Group T2). The experiment was conducted for up to 21 days. Zootechnical performance parameters were obtained from the 1<sup>st</sup> to the 21<sup>st</sup> day of life. Feed intake (FI), weight gain (WG), and feed conversion (FC) were calculated. WG was calculated as the difference between the final weight and the initial weight. Feed consumption was calculated as the difference between total

feed supplied and leftovers obtained. The FC was calculated as the ratio between the total FI and the WG, corrected for the weight of the dead birds. On day 21, birds and feeds were weighed for determination of FI, WG, and FC.

**Histopathological analysis.** Two birds of each replicate (totaling 20 birds of each treatment, T1 and T2) fasted for 12 hours and intramuscularly administered ketamine (40mg/kg) with xylazine (2mg/kg). They were sacrificed by cervical dislocation and were subsequently bled and eviscerated for visual and histological assessment of the internal organs (liver, small intestine, and heart) (Lerda, 2017). The experiment was conducted based on the norms of the experimental use of animals approved by CEU/UNILA under protocol number 001/2018.

For macroscopic analysis of the viscera, a necropsy was performed on 40 birds (20 birds in the T1 group and 20 birds in the T2 group). After evaluating the viscera, fragments of 3-mm thickness were removed, and these were placed in containers containing 10% formaldehyde buffered for at least 24 hours. The liver, heart, and small intestine were removed at necropsy and fixed in 10% buffered formaldehyde for histopathological analysis. After this procedure, the fragments were dehydrated in ethyl alcohol in increasing concentrations, diaphanized by xylol, infiltrated, and set in paraffin. The blocks were cut in a microtome set to 5µm.

The sections were subjected to hematoxylin-eosin staining, then a descriptive analysis of the results was performed. The liver, heart, and intestine were evaluated based on the histopathology observed after the end of the experiment. Intestine, liver, and heart fragments were collected, cleaved, and fixed in 10% buffered formaldehyde. After this

procedure, the fragments were dehydrated in ethyl alcohol in increasing concentrations, diaphanized by xylol, impregnated, and included in paraffin. The blocks were cut in a microtome adjusted to 5  $\mu\text{m}$ . The sections were subjected to hematoxylin-eosin staining. Then, a descriptive analysis of the results was performed. Slides were made for the hematoxylin-eosin staining and microscopy (400x).

Analyses were performed to determine the presence and degree of alterations in the T1 and T2 groups for vacuolations, villous atrophy, goblet cell hyperplasia, and hemorrhage or hepatic necrosis. Scores were as follows: 0) absence; 1) scant, up to 25% of the field; 2) moderate, greater than 25% but less than 50% of the field of observation; and 3) severe, greater than 50% of the field of observation (Cangussu *et al.*, 2018; Rashidi *et al.*, 2020).

**Statistical analysis.** The data were subjected to one-way Analysis of Variance and F-test with 95% confidence interval to evaluate the zootechnical parameters and histopathological data using software Assistat 7.7.

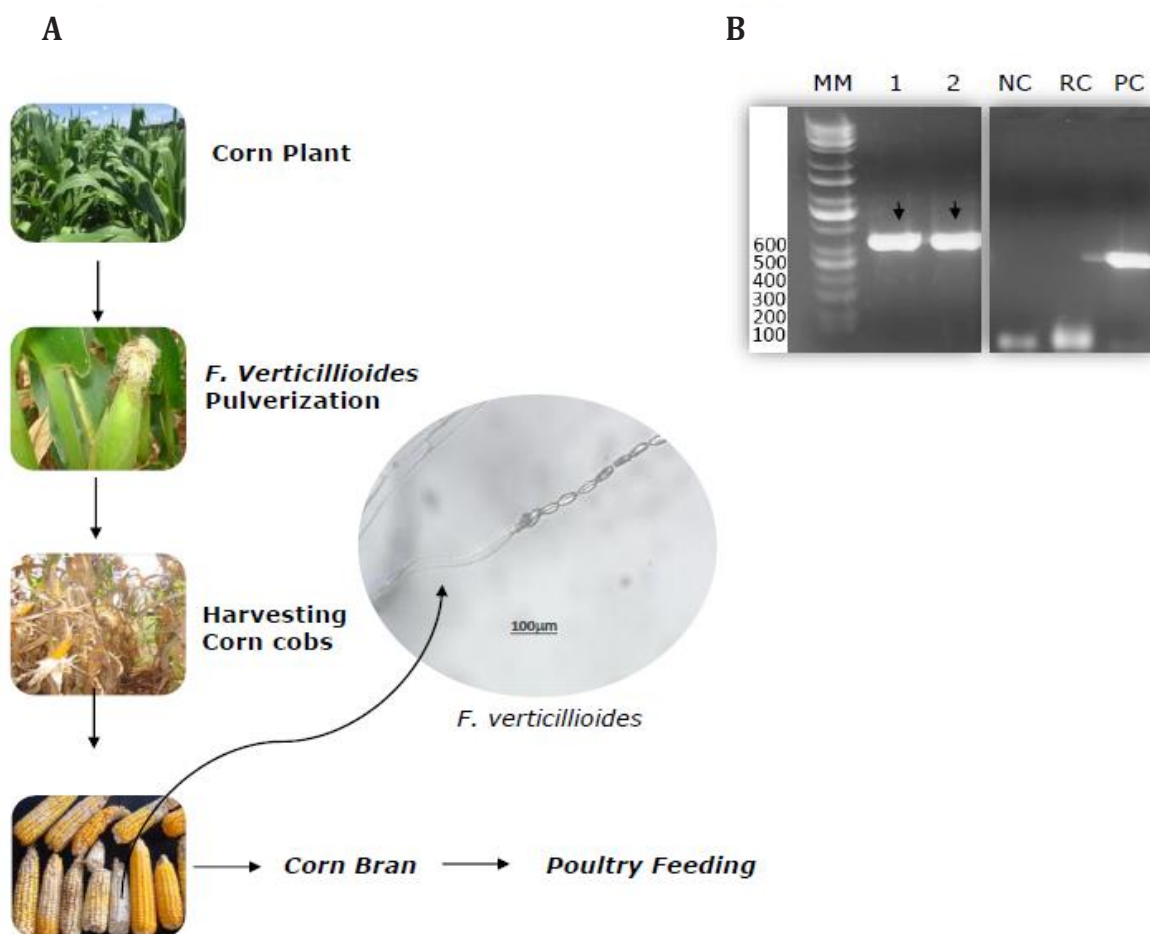
## RESULTS AND DISCUSSION

Corn grains infected with fumonisin from *F. verticillioides* were evaluated in the feed. These results suggest to understanding the effect on animal performance evaluated by zootechnical and histopathological parameters. The morphology of isolates obtained from ears of dry corn kernels in the stage (R6) was evaluated. Data showed conidiophores with microconidia in long chains of microconidia in monophyllides, characteristic structures of *F. verticillioides* (Figure 1). To confirm the molecular profile, we used amplified ITS1-5.8S regions referring

to the 578bp calmodulin gene sequence used to identify *F. verticillioides* (Figure 1b). The genes were sequenced, revealing 99% and 99.9% sequence similarity (Query cover) for *F. verticillioides* (Blast, NCBI, Icl/Query\_25443, Icl/Query\_10149), and plant health report (3162/2017-AGR). In the field experiment, the hybrid P32R48YH was selected for presenting the characteristics of susceptibility to disease and with the spraying of conidia of *F. verticillioides* during stage R1. The ears in stage R6 showed the morphological characteristics of infections with *F. verticillioides*, with levels of 2.78  $\mu\text{g g}^{-1}$  of fumonisin FB1 being determined in the feeding of birds.

Poultry fed control feed (T1) and feed contaminated with *F. verticillioides* and containing 2.78  $\mu\text{g/g}$  of fumonisin FB1 (T2). We performed the subsequent experiments with 160 COBB 500<sup>®</sup> birds, 80 birds in each group (T1 and T2) and were evaluated for animal performance monitored by zootechnical and histopathological parameters of sections of liver, heart, and small intestine.

The weight data from the birds were obtained at the beginning and the end of each week as follows: FI/bird of 1136.10g, FC/bird of 1.53g, and final WG of 746.14 g after 21 days consuming control feed (T1) (Table 1). Data on birds treated with *F. verticillioides*-contaminated corn (T2) were: FI/bird of 1110.38g, FC/bird of 1.50 g, and final WG of 743.63 g (Table 1). We also evaluated the individualized behavior of COBB 500<sup>®</sup> birds over 3 weeks, and WG was used as one of the performance parameters of birds fed with contaminated feed (T2) with *F. verticillioides* fumonisin FB1 and control feed (T2) without the presence of FB1 fumonisin. We did not find significant variations between the treatment groups T1 and T2 (Table 1), with an F-value > P-value.



**A** - Flowchart of corn crop planting and morphological structures of *F. verticillioides* produced in monophialids, with conidiophores and microconidia in chains. **B** - Molecular analysis of samples of fungal isolates obtained from corn. MM - molecular marked; 1 and 2 (*F. verticillioides*); NC - negative control; RC - relative control; PC - positive control.

**Figure 1.** Schematic flow of planting and molecular identification of *F. verticillioides*.

**Table 1.** Zootechnical parameters of poultry consuming Fumonisin of corn contaminated.

Treatment	FI (g/birds)	FCR (g/day)	WG (g)	FE (%)
T1	1136,10 <sup>a</sup> (18,35)	1,53 <sup>a</sup> (0,03)	805,02 <sup>a</sup> (14,12)	70,85 <sup>a</sup>
T2	1110,38 <sup>a</sup> (19,01)	1,50 <sup>a</sup> (0,02)	792,13 <sup>a</sup> (13,50)	71,33 <sup>a</sup>

Mean values followed by the same letter were not significantly different at the level of 5% probability; FI - Feed Intake; FCR - Feed Conversion; WG - Weight Gain; FE - Feed Efficiency.

The histopathological study was carried out using 20 birds in each group (T1 and T2). We evaluated histopathological data of the liver, heart, and small intestine of birds to investigate the occurrence of histopathological lesions such as vacuolations, villous atrophy, goblet cell hyperplasia, bleeding, and hepatic necrosis (Figure 2, Table 2). However, histological findings revealed slight changes with vacuolizations of the same intensity and distribution in both groups in sections of livers and hearts (Figure 2). This result suggests that the concentrations of 2.78 µg/g of FB1 obtained from the hybrid corn P32R48YH infected with *F. verticillioides* did not cause significant changes, either in terms of variation in zootechnical parameters or histopathological parameters.

**Table 2.** Score of histopathological data from sections of liver, small intestine, and heart of COOB 500® birds fed with ration contaminated with Fumonisin FB1 (T2) and birds fed with control ration without contamination (T1).

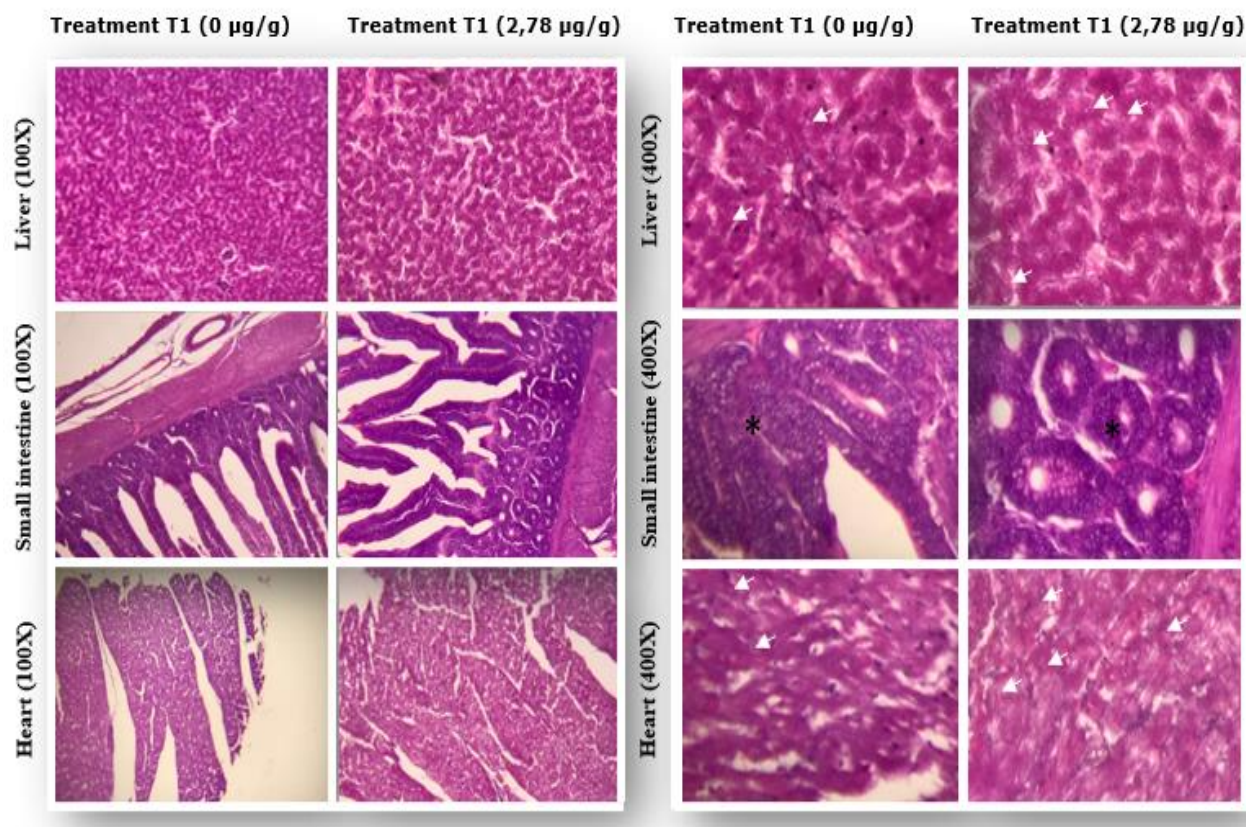
Treatment	Chickens' organs	Score	P
T1	Liver	0-1	ns
	Heart	0-1	ns
	Small intestine	0-1	ns
T2	Liver	0-1	ns
	Heart	0-1	ns
	Small intestine	0-1	ns

The scores were as follows: 0) absence; 1) scarce, up to 25% of the field; 2) moderate, greater than 25%, but less than 50% of the observation field; and 3) severe, greater than 50% of the observation field.

The existence of mycotoxins in agricultural products has become a global concern. For these reasons, the threat of mycotoxins poses an even greater concern for human and animal food security (Knutsen *et al.*, 2018). Mycotoxins such as aflatoxins, ochratoxins, trichothecenes, zearalenones, and fumonisin are economically important because of their associated toxicities, including nephrotoxicity, neurotoxicity, carcinogenic properties, and immunosuppressive effects, especially when present in high amounts (Shen *et al.*, 2018). In small amounts, mycotoxins can reduce appetite and WG in animals and cause diarrhea in humans (Kovalsky *et al.*, 2016) animal feed. The International Agency for Research on Cancer (IARC) classified fumonisin (FB1 and FB2) in the 2B carcinogen risk group concerning oesophageal cancer in humans (Shen *et al.*, 2018).

Mycotoxins affect both public health and have economic implications for agricultural production and the availability of food worldwide. Approximately 25% of all agricultural products are contaminated by mycotoxins (Bhardwaj *et al.*, 2021). For these reasons, the quality of products intended for food must be assessed before use to avoid any danger to the health of humans, animals, or the environment. Several maximum permissible concentrations have been proposed for various mycotoxins in different types of food. These restrictions vary from country to country due to differences in the origin of food, the possibility of contamination and ingestion at meals; there is currently no international legislation regulating permissible levels (Kovalsky *et al.*, 2016; Smith *et al.*, 2016).





**Figure 2.** (T1) control ration without contamination and (T1) with Fumonisin. The arrows represent discrete vacuolization observed in the liver and heart sections. (\*) without evident changes.

The European Union (EU) sets a maximum permissible level of 200µg/kg for FB1 + FB2 in processed corn-based foods. The European Food Safety Authority (EFSA) established the tolerable daily intake of 1µg/kg of body weight per day for humans (Knutsen *et al.*, 2018). The maximum tolerated level for birds, in general, is 0.02µg/g (Comissão Europeia, 2006). According to the US Food and Drug Administration, the maximum permissible levels of FB1 + FB2 for laying hens are 0.03µg/g and 0.1µg/g for broilers (Van Egmond & Jonker, 2005). Brazilian legislation also aims at control and quality concerning mycotoxin contamination and consequently ensures the population's health (Ministério da Saúde do Brasil, 2011). The concentrations of subclasses FB1 +

FB2 are permitted up to 1µg/g in products of animal origin (Ministério da Saúde do Brasil, 2011). Analytical methods such as high-performance liquid chromatography coupled with sequential mass spectrometry are used to identify and quantify mycotoxins, thereby helping to guarantee compliance with the legislation.

Our data revealed that the same in the concentration of 2.78µg/g fumonisin FB1 obtained in the P32R48YH hybrid that has the highest susceptibility for *F. verticillioides* infection not found significant histopathological damage or alteration in the zootechnical parameters in COBB 500® birds fed with feed containing this concentration of FB1 over 21 days. Wyatt & Henry (1993), also studied

concentrations 0, 0.2, 0.4, and 0.8 µg/g of FB1 purified in birds up to 21 days and did not observe significant variations in WG or FC. At concentrations of 1 to 2 µg/g of FB<sub>1</sub>, some reports indicated a low influence on animal performance. FB1 levels greater than 3 µg/g caused diarrhea, decreased food intake, and weight loss with swelling of the liver, kidneys, and hepatic necrosis (Ledoux *et al.*, 1996). The toxic effects of fumonisin are directly related to the dose ingested by the animal (Ledoux *et al.*, 1996; Murugesan *et al.*, 2015). However, Zachariasova *et al.* (2014) toxic secondary metabolites produced by microscopic filamentous fungi, are ubiquitous contaminants of crop plants and forage representing the main components of compound feeds. More than 300 mycotoxins are known today, but only five of them (aflatoxin B1, deoxynivalenol, zearalenone, fumonisins and ochratoxin A) stated that it is necessary to observe the concentration and the contact time of FB1 in birds because both determine the appearance of lesions that start in the mouth and evolve to damage to the intestine and liver. The primary lesions by FB1 have been reported in bird livers, with FB1 levels greater than 3 µg/g (Wielogorska *et al.*, 2016). The lesions begin after swelling with erosions in the stomach and intestine, culminating in hemorrhage and death (Kovalsky *et al.*, 2016) animal feed. Villous atrophy and goblet cell hyperplasia were also observed in the jejunum (Lerda, 2017). Rauber *et al.* (2012) reported the appearance of liver lesions such as hepatocellular vacuolization, bile duct hyperplasia, hepatocellular degeneration, bile duct proliferation, and lymphoid hyperplasia in birds fed high concentrations of FB1

(100 and 200 µg/g) without heart or small intestine lesions. Our histopathological data revealed only mild changes of vacuolations of the same intensity and distribution in livers and hearts in both treatments (T1 and T2), suggesting that 2.78 µg/g fumonisin obtained from the hybrid corn P32R48YH infected with *F. verticillioides* did not cause significant changes in histopathology, even though the dose was approximately three times above the maximum tolerance limit determined by Anvisa/Brazil.

## CONCLUSIONS

Study presents a relevant scientific contribution with the P32R48YH hybrid corn at stage R1 being the more susceptible to *F. verticillioides* infection with a maximum yield of fumonisin. In addition, the fumonisin produced of P32R48YH hybrid corn no caused impact on the health of poultry. This data will assist in establishing minimum and safe concentrations of FB1 and improve the criteria for poultry meat production.

## ACKNOWLEDGEMENTS

We would like to thank the Graduate Program in Plant Production, Biotechnology Graduate Program, and Biodiversity and the Biotechnology of the Bionorte Network Program, and the Vice-Dean of Research by the Federal University of Tocantins (UFT). And also, to the researchers ORJ, ASRC, APC, KFR, MKCF, TTD, TPSF, HSB, KfV, SEM, RWSA, GRS, who carried out the scope, writing, language and technical aspects of this work. **Conflict of interests:** The authors declare that there are no conflicts of interest.

## BIBLIOGRAPHIC REFERENCES

- Alberts, J.F.; Van Zyl, W.H.; Gelderblom, W.C.A. (2016). Biologically based methods for control of fumonisin-producing *Fusarium* species and reduction of the fumonisins. *Frontiers in Microbiology*. 7(548). doi: <https://doi.org/10.3389/fmicb.2016.00548>
- Bhardwaj, H.; Rajesh, H.; Sumana, G. (2021). Recent advances in nanomaterials integrated immunosensors for food toxin detection. *Journal of Food Science and Technology*. 59: 12–33. doi: <https://doi.org/10.1007/s13197-021-04999-5>
- Bouhet, S.; Oswald, I.P. (2007). The intestine as a possible target for fumonisin toxicity. *Molecular Nutrition Food Research*. 51(8): 925-931. doi: <https://doi.org/10.1002/mnfr.200600266>
- Cangussu, A.S.R.; Mariúba, L.A.M.; Lalwani, P.; Pereira, K.D.E.S.; Astolphi-Filho, S.; Orlandi, P.P.; Epiphanyo, S.; Viana, K.F.; Ribeiro, M.F.B.; Silva, H.M.; Marinho, C.R.F.; Nogueira, P.A. (2018). A hybrid protein containing MSP1a repeats and Omp7, Omp8 and Omp9 epitopes protect immunized BALB/c mice against anaplasmosis. *Veterinary Research*. 49(1): 1-11. doi: <https://doi.org/10.1186/s13567-018-0503-4>
- Comissão Europeia. (2006). Recomendação Da Comissão, de 17 de Agosto de 2006, sobre a presença de desoxinivalenol, zearalenona, ocratoxina A, toxinas T-2 e HT-2 e fumonisinas em produtos destinados à alimentação animal. Retrieved from <http://www.efsa.europa.eu/etc/medialib/efsa/science/contam/>
- Dall'Asta, C.; Galaverna, G.; Aureli, G.; Dossena, A.; Marchelli, R. (2008). A LC/MS/MS method for the simultaneous quantification of free and masked fumonisins in maize and maize-based products. *World Mycotoxin Journal*. 1(3): 237-246.
- Doyle, J.J.; Doyle J.L. (1990). Isolation of plant DNA from fresh tissue. *Focus*. 12: 13-15.
- Grenier, B.; Dohnal, I.; Shanmugasundaram, R.; Eicher, S.D.; Selvaraj, R.K.; Schatzmayr, G.; Applegate, T.J. (2016). Susceptibility of broiler chickens to coccidiosis when fed subclinical doses of deoxynivalenol and fumonisins—special emphasis on the immunological response and themycotoxin interaction. *Toxins*. 8(8): 2031. doi: <https://doi.org/10.3390/toxins8080231>
- Haschek, W.M.; Motelin, G.; Ness, D. K.; Harlin, K.S.; Hall, W.F.; Vesonder, R.F.; Peterson, R.E.; Beasley, V.R. (1992). Characterization of fumonisin toxicity in orally and intravenously dosed swine. *Mycopathologia*. 117(1–2): 83-96. doi: <https://doi.org/10.1007/BF00497283>
- Knutsen, H.K.; Alexander, J.; Barregård, L.; Bignami, M.; Brüschweiler, B.; Ceccatelli, S.; Cottrill, B.; Dinovi, M.; Edler, L.; Grasl-Kraupp, B.; Hogstrand, C.; Hoogenboom, L.; Nebbia, C.S.; Petersen, A.; Rose, M.; Roudot, A. C.; Schwerdtle, T.; Vleminckx, C.; Vollmer, G.; ... Oswald, I.P. (2018). Risks for animal health related to the presence of fumonisins, their modified forms and hidden forms in feed. *EFSA Journal*. 16(5):5242. doi: <https://doi.org/10.2903/j.efsa.2018.5242>
- Kovalsky, P.; Kos, G.; Nährer, K.; Schwab, C.; Jenkins, T.; Schatzmayr, G.; Sulyok, M.; Krska, R. (2016). Co-occurrence of regulated, masked and emerging mycotoxins and secondary metabolites in finished feed and maize—An extensive survey. *Toxins*. 8(12): 1-29. doi: <https://doi.org/10.3390/toxins8120363>
- Ledoux, D.R.; Bermudez, A.J.; Rottinghaus, G.E. (1996). Effects of Feeding *Fusarium moniliforme* Culture Material, Containing Known Levels of Fumonisin B1, in the Young Turkey Poult. *Poultry Science*. 75(12): 1472-1478. doi: <https://doi.org/10.3382/ps.0751472>

- Lerda, D. (2017). Fumonisin in Foods from Cordoba (Argentina), Presence: Mini Review. *Toxicology: Open Access*. 03(02): 2-5. doi: <https://doi.org/10.4172/2476-2067.1000125>
- Ministério da Saúde do Brasil. (2011). Resolução de Diretoria Colegiada – RDC No 07 in Ministério da Saude. Agencia Nacional de Vigilância Sanitaria. Brasil: Ministério da Saúde do Brasil.
- Morales, L.; Zila, C.T.; Mejía, D.E.M.; Arbelaez, M.M.; Balint-Kurti, P.J.; Holland, J.B.; Nelson, R.J. (2019). Diverse components of resistance to fusarium verticillioides infection and fumonisin contamination in four maize recombinant inbred families. *Toxins*. 11(2): 86. doi: <https://doi.org/10.3390/toxins11020086>
- Murugesan, G.R.; Ledoux, D.R.; Naehrer, K.; Berthiller, F.; Applegate, T.J.; Grenier, B.; Phillips, T.D.; Schatzmayr, G. (2015). Prevalence and effects of mycotoxins on poultry health and performance, and recent development in mycotoxin counteracting strategies. *Poultry Science*. 94(6): 1298-1315. doi: <https://doi.org/10.3382/ps/pev075>
- Oldenburg, E.; Höppner, F.; Ellner, F.; Weinert, J. (2017). Fusarium diseases of maize associated with mycotoxin contamination of agricultural products intended to be used for food and feed. *Mycotoxin Research*. 33(3): 167-182. doi: <https://doi.org/10.1007/s12550-017-0277-y>
- Priyanka, S.R.; Venkataramana, M.; Balakrishna, K.; Murali, H.S.; Batra, H.V. (2015). Development and evaluation of a multiplex PCR assay for simultaneous detection of major mycotoxigenic fungi from cereals. *Journal of Food Science and Technology*. 52(1): 486-492. doi: <https://doi.org/10.1007/s13197-013-1001-3>
- Rashidi, N.; Khatibjoo, A.; Taherpour, K.; Akbari-Gharaei, M.; Shirzadi, H. (2020). Effects of licorice extract, probiotic, toxin binder and poultry litter biochar on performance, immune function, blood indices and liver histopathology of broilers exposed to aflatoxin-B1. *Poultry Science*. 99(11): 5896-5906. doi: <https://doi.org/10.1016/j.psj.2020.08.034>
- Rauber, R.H.; Dilkin, P.; Mallmann, A.O.; Marchioro, A.; Mallmann, C.A.; Borsoi, A.; Nascimento, V.P. (2012). Individual and combined effects of Salmonella typhimurium lipopolysaccharide and fumonisin B1 in broiler chickens. *Poultry Science*. 91(11): 2785-2791. doi: <https://doi.org/10.3382/ps.2012-02489>
- Rosa Junior, O.F.; Dalcin, M.S.; Nascimento, V.L.; Haesbaert, F.M.; Ferreira, T.P.; Fidelis, R.R.; Sarmiento, R.; Aguiar, R.; De Oliveira, E.E.; Dos Santos, G.R. (2019). Fumonisin production by fusarium verticillioides in maize genotypes cultivated in different environments. *Toxins*. 11(4):215. doi: <https://doi.org/10.3390/toxins11040215>
- Shen, F.; Wu, Q.; Shao, X.; Zhang, Q. (2018). Non-destructive and rapid evaluation of aflatoxins in brown rice by using near-infrared and mid-infrared spectroscopic techniques. *Journal of Food Science and Technology*. 55(3): 1175-1184. doi: <https://doi.org/10.1007/s13197-018-3033-1>
- Smith, M.C.; Madec, S.; Coton, E.; Hymery, N. (2016). Natural Co-occurrence of mycotoxins in foods and feeds and their in vitro combined toxicological effects. *Toxins*. 8(4): 94. doi: <https://doi.org/10.3390/toxins8040094>
- Van Cleemput, J.; Poelaert, K.C.K.; Laval, K.; Van den Broeck, W.; Nauwynck, H.J. (2019). Deoxynivalenol, but not fumonisin B1, aflatoxin B1 or diesel exhaust particles disrupt integrity of the horse's respiratory epithelium and predispose it for equine herpesvirus type 1 infection. *Veterinary Microbiology*. 234: 17-24. doi: <https://doi.org/10.1016/j.vetmic.2019.05.009>

- Van Egmond, H.P.; Jonker, M.A. (2005). *Worldwide regulations for mycotoxins in food and feed in 2003: Summary of study*. European Union: Food and Nutrition Paper. 171p.
- Venkataramana, M.; Navya, K.; Chandranayaka, S.; Priyanka, S.R.; Murali, H.S.; Batra, H.V. (2014). Development and validation of an immunochromatographic assay for rapid detection of fumonisin B1 from cereal samples. *Journal of Food Science and Technology*. 51(9): 1920-1928. doi: <https://doi.org/10.1007/s13197-013-1254-x>
- Walker, C.; Maciel, C.G.; Milanesi, P.M.; Muniz, M.F.B.; Mezzomo, R.; Pollet, C.S. (2016). Morphological, molecular and pathogenicity characterization of *Fusarium acuminatum* and *Fusarium verticillioides* to *Cordia americana* seeds. *Ciencia Florestal*. 26(2): 463-473. doi: <https://doi.org/10.5902/1980509822747>
- Wielogorska, E.; MacDonald, S.; Elliott, C.T. (2016). A review of the efficacy of mycotoxin detoxifying agents used in feed in light of changing global environment and legislation. *World Mycotoxin Journal*. 9(3): 419-433. doi: <https://doi.org/10.3920/WMJ2015.1919>
- Wyatt, R.D.; Henry, M.H. (1993). A Review of Fumonisin Production by *Fusarium moniliforme* and Fumonisin Toxicosis in Animals. *Journal of Applied Poultry Research*. 2(2): 188-192. doi: <https://doi.org/10.1093/japr/2.2.188>
- Yarru, L.P.; Settivari, R.S.; Gowda, N.K.S.; Antoniou, E.; Ledoux, D.R.; Rottinghaus, G. E. (2009). Effects of turmeric (*Curcuma longa*) on the expression of hepatic genes associated with biotransformation, antioxidant, and immune systems in broiler chicks fed aflatoxin. *Poultry Science*. 88(12): 2620-2627. doi: <https://doi.org/10.3382/ps.2009-00204>
- Zachariasova, M.; Dzuman, Z.; Veprikova, Z.; Hajkova, K.; Jiru, M.; Vaclavikova, M.; Zachariasova, A.; Pospichalova, M.; Florian,
- M.; Hajslova, J. (2014). Occurrence of multiple mycotoxins in European feedingstuffs, assessment of dietary intake by farm animals. *Animal Feed Science and Technology*. 193: 124-140. doi: <https://doi.org/10.1016/j.anifeedsci.2014.02.007>