

The role of CBCT in the field of dental implantology

Barbara Jurić¹, Tatjana Matijaš¹

¹University Department of Health Studies, University of Split, Split, Croatia

Abstract

As radiology rapidly and continuously develops, dental radiological devices are becoming integral to dental practice. CBCT enables a precise three-dimensional image of the orofacial region. The wider use of CBCT devices is further encouraged by the flaws of two-dimensional radiological methods, especially concerning dental implantology. This paper aims to describe the advantages and disadvantages of using CBCT devices in planning and placing dental implants. It offers an insight into artifacts and radiation doses and their influence on the quality of the resulting image. The generation of multiplanar slices of the area of interest, the possibility of 3D reconstruction, the reduction of the magnification error, and the radiation dose are some of the important advantages of the CBCT device. A limited FOV and volume of the screening, a low range of contrasts, measuring of bone density and shades of grayscale, as well as possible artifacts of movement are some of its disadvantages. Not only did the CBCT device find a purpose in the processes of planning and placement of dental implants, but also in postoperative assessments of healing and possible complications. CBCT balances the price and radiation dose and the quality of clinical information. It is used in oral surgery, orthodontics, periodontology, and endodontics. Due to its precision and quality, the CBCT device is the foundation of dental implantology.

Keywords: bone density; CBCT; dental implants; teeth; 3D overview

Abbreviations and acronyms: ALARA (As Low As Reasonably Achievable), CBCT (Cone beam computed tomography), CT (Computed tomography), DICOM (Digital Imaging and Communications in Medicine), FD (Flat detector), FOV (Field of view), MRI (Magnetic resonance imaging), PACS (Picture Archiving and Communication System)

Corresponding author: Tatjana Matijaš, University Department of Health Studies, University of Split, Split, Croatia, e-mail: tmatijas@ozs.unist.hr

DOI: <https://doi.org/10.55378/rv.47.1.2>

Introduction

Due to rapid development and daily technological progress, radiology has found its place in many areas of human life. The importance of its development is primarily evident in medicine, where a number of radiological devices and methods are used in diagnostics and treatment. Radiological devices are used to detect and treat pathological conditions with the goal of curing them or improving patients' quality of life [1]. Radiology plays an important role in dental medicine as well. Dental radiography has become a crucial part of dental practice [2]. Its frequent use and rapid development have created a demand for the development of many radiological devices specialized for dental medicine. The result of the combination of digitalization and 3D image processing in dental radiography is an accurate and precise diagnosis which is crucial for further quality treatment [3].

Cone-Beam Computed Tomography (CBCT)

Technological progress in the medical field has led to it reaching new heights and enabled many accomplishments in several branches, primarily radiology. One of the more significant events in modern radiology is the emergence and use of the first Computed Tomography scan. The biggest downside of the CT scan is the large dose of radiation for the patient; hence its use is limited when scanning the orofacial region. The limitations of the CT scan have led to the development of a device that has all the advantages of the CT, and none of the disadvantages, which primarily means a lower radiation dose for the patient. Cone Beam Computed Tomography enables a 3D display of the orofacial region within the ALARA principle (As Low as Reasonably Achievable) [4]. A cone-shaped X-ray beam enables CBCT to cover the area which is being scanned with a single rotation of the X-ray beam and the detector (Figure 1) [5].

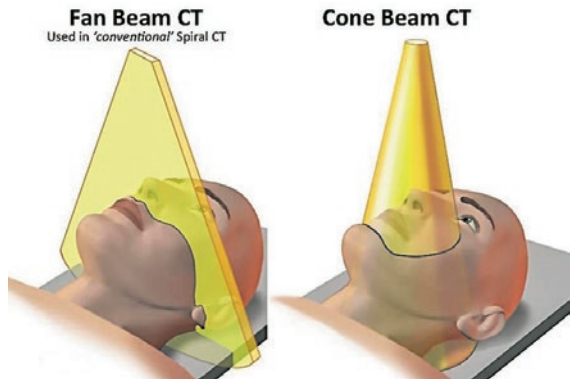


Figure 1. A depiction of CBCT's cone-shaped beam
 Source: <https://pocketdentistry.com/5-cone-beam-computed-tomography/>

CBCT consists of the source of X-rays, the image detector, and the gantry, also called the C-arm or rotating platform (Figure 2). The size of CBCT's focal spot is 0.5mm, which results in high-resolution images. The configuration of the opening size of the collimator depends on previously determined measurements of the FOV (Field of view) [3, 6]. Aluminum filters with an aluminum-equivalent thickness between 2.5 and 10 mm are situated at the end of the X-ray tube and prevent the absorption of low-energy photons in the patient's body [7]. CBCT uses a Flat Detector (FD) made out of amorphous silicon to transform incoming photons into electrical signals. Thanks to its size, it is easier to use, the dose is more efficient, the distortion of the scanned anatomical structures is minimal, and the FOV's dimensions can be changed [6].

The X-ray tube and the radiation detector form the gantry, or the C-arm, of a CBCT device. They are parallel to each other and can partially (180°) or completely (360°) rotate around the object they're scanning (Figure 3). By fixing the patient's head in place using a chin rest and a bite holder, its movement is limited and the creation of artifacts is minimized [6].

Several types of CBCT can be distinguished based on design, detector configurations, and protocol settings.



Figure 2. A CBCT device
 Source: <https://henryscheinequipment.co.nz/imaging/cone-beam/op-3d/>

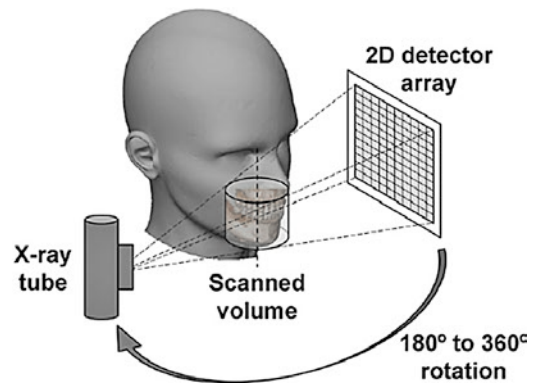


Figure 3. Depiction of the principle of rotation of the C-arm
 Source: <https://www.ncbi.nlm.nih.gov/pmc/articles/PMC4277439/>

The state of the patient is the main criterion for picking a mode of scanning and positioning the patient. They can be scanned in a standing, sitting, or lying position. The main fault of the device used to scan the patient in a standing position is the lack of a height regulation feature, while the CBCT devices used to scan in a sitting or lying position demand more room during the devices' placement [6].

Image quality

One of the most important factors which affect image quality is spatial resolution. The visibility of details enables further intervention to be exact and precise. Using lower radiation doses, CBCT creates high-resolution 3D images. The value of spatial resolution is shown through line-pairs per millimeter (lp/mm) and is primarily influenced by the size of the pixels, i.e. voxels, shades of the grayscale, and reconstruction methods. Tube voltage, tube current, rotation arch, and exposition time, all are parameters that influence the quality of the image [8]. By using volumetric reconstruction, it is possible to analyze structures in 3 planes. A voxel represents the smallest part of a 3D image and is characterized by the third dimension - depth (Figure 4) [9]. Its size varies from 0.076 mm to 0.4 mm and depends on the dimensions of the pixels on the CBCT detector [10]. The size of the voxel affects multiple factors which determine the quality of the image, such as spatial resolution, the amount of image noise, and the time it takes to reconstruct an image. A change in voxels' size affects the aforementioned parameters, as well as leads to a change in the dose of ionizing radiation the patient is being subjected to [9].

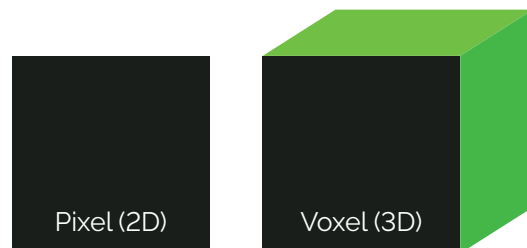


Figure 4. A pixel and a voxel
 Source: <https://www.nicepng.com/maxp/u2e6a9u2e6a9t4o0/>

Application of a CBCT device

The limitations of 2D radiography in diagnostics in the orofacial region have created a demand for the development and application of CBCT. CBCT enables more precise imaging and minimizes distortion and the superimposition of structures. CBCT is not only used in diagnostics but also in the planning and execution of treatment, as well as in therapy and tracking the patient's condition. The CBCT device is an indispensable part of the process of planning and placement of dental implants. It is used to measure the quality and quantity of the site of implantation, thus avoiding possible injuries of surrounding anatomical structures. Along with this pre-operative analysis, CBCT is also used for post-operative assessment. CBCT is not a method of choice when scanning soft tissue, even though it is possible to describe the appearance of paranasal sinuses based on CBCT images. CBCT's wide use in orthodontics has enabled the assessment of teeth's age, the visualization of tooth inclination, the measuring of the alveolar bone width, and the palatal bone thickness. The device is also used in endodontics, forensic odontology, and periodontology, and can be used to scan temporomandibular joints [11].

The planning and placement of dental implants

In recent years, dental implants have frequently been replacing fixed partial dentures in cases of missing teeth. Along with being long-lasting, dental implants lower the risk of caries as well as the sensitivity of the teeth, and their placement has a high success rate. For the process of placement to be successful and precise, and to avoid possible complications, it is imperative to be familiar with vital anatomical structures. Structures of the maxilla which are most often damaged during the placement of implants are the maxillary sinus, the nasal floor, and the nasopalatine canal. The most common injury is the perforation of the maxillary sinus, but it can be avoided by lifting the sinus and using an implant of proper length. When

installing implants in the mandible, special attention needs to be paid to the mandibular canal. If damaged, it can cause excessive bleeding, pain, and altered sensation [12]. The height and width of the bone, the orientation of the alveolar ridge, the length of the part of the jaw where teeth are missing, and the presence of pathological conditions are all crucial information for the process of placement which are acquired by analyzing CBCT scans [13]. Using special 3D modules, CBCT allows virtual planning, trying out, and testing various combinations of length and diameter of the implants (Figure 5). The 3D image enables viewing of the implant from all angles as well as rotation and tilting aimed at finding the optimal position. After planning out the placement in computer programs, the resulting template is used in the actual placement of the implants [14].

Aim of the article

The aim of this article is to describe the application of CBCT in the placement of dental implants and its advantages and disadvantages. Based on available literature from the past ten years, it explains the role CBCT has in the planning of the placement of dental implants and touches on the artifacts and radiation doses that have a significant effect on image quality.

Discussion

The role of CBCT in the placement of dental implants

Complete or partial edentulism is present in a large part of the human population. It negatively affects the sufferer's quality of life and makes it difficult to maintain optimal health. CBCT has become widely used due to the limitations of 2D methods, and thanks to its many advantages, it has become a vital part of dental implantology. Its main

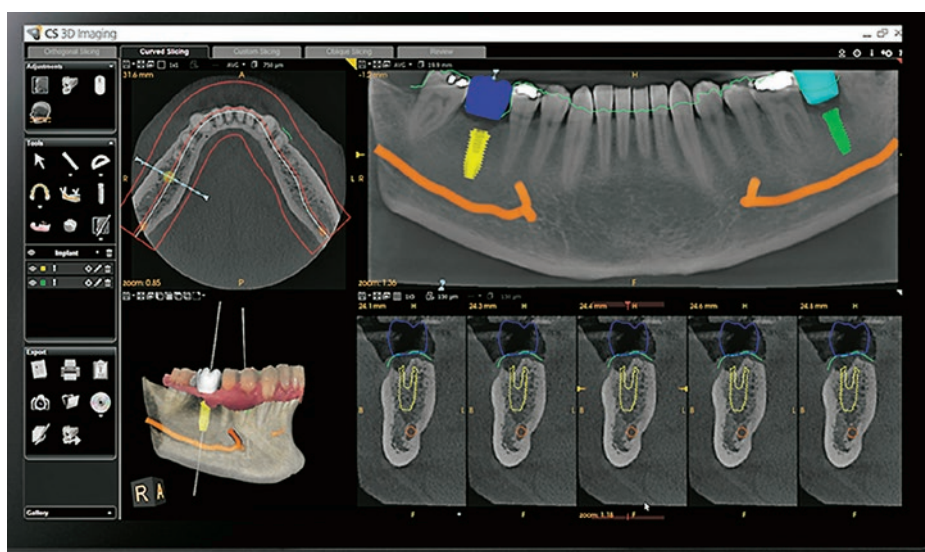


Figure 5. A depiction of a dental implant planning module

Source: <https://www.carestreamdental.com/en-gb/csd-products/optional-modules/prosthetic-driven-implant-planning-module/>

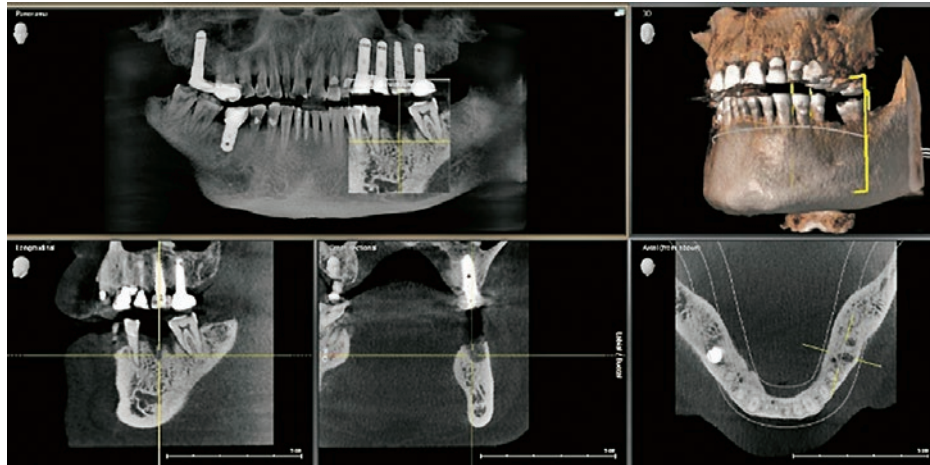


Figure 6. Sagittal, coronal, and axial cross-section; a 3D jaw reconstruction

Source: <http://latestnews.wickhamterracedental.com.au/brisbane-cbd-dentist-3d-cone-beam-x-ray-machine>

assets are the generation of multiplanar slices and the 3D reconstruction of structures (Figure 6). It also allows for an assessment of bone density and quality to ensure the success of the procedure [15]. Before CBCT was developed and widely used, the planning and placement of dental implants were based on clinical examinations, 2D radiological methods, and the analyses of dental studies. Superimposition of structures, distortion, and magnification error are just a few of the aforementioned methods' faults. 2D methods are not adequate for a precise and accurate assessment of distance between a dental implant and neuro-vascular and anatomical structures [13].

Due to its quality, analytical possibilities, and the accuracy of the data it provides, the application of CBCT in dentistry is becoming more frequent in recent times (Figure 7). The longevity and quality of dental implants have made them a method of choice when dealing with physical trauma, disease, abnormal growth and development of the teeth, as well as aesthetic issues. CBCT's accuracy, low radiation doses, lower cost for the patient, and high resolution are just some of the perks which secured its place in dental implantology [16]. CBCT-based surgery

takes less time and causes less post-operative swelling and pain. It includes coronal, axial, and sagittal projections, lateral cephalometric projections, 2D panoramic projections, and 3D projections. Its usefulness goes beyond planning and placing implants, as it can be applied to discover and analyze pathological processes in dental medicine, such as benign or malignant tumors, cysts, dental caries, and endodontic infections [17].

An orthopantomogram and an oblique sagittal reformatted view are projections necessary for the process of planning implant placement (Figure 8). The orthopantomogram is optimal for the analysis of the general condition of the teeth, the height of the bone and the presence of pathological processes. It is done using a CBCT device with a full field of view. The oblique sagittal reformatted view provides information about the height and width of the bone and is used to evaluate the cross-section of the mandible and the maxilla. Marking of the mandibular nerve and sinuous branches is based on the oblique sagittal reformatted view, which makes it invaluable for the process of planning and placing dental implants [17].

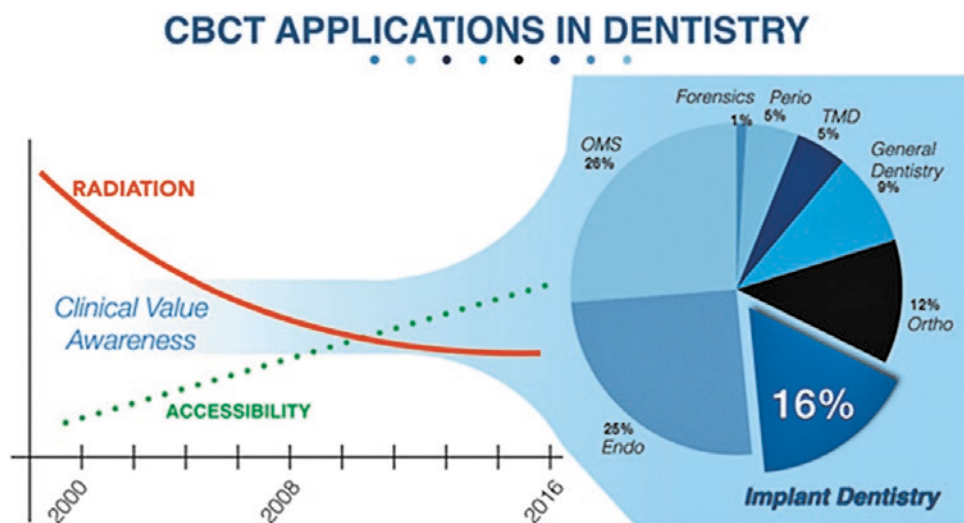


Figure 7. CBCT applications in dentistry

Source: <https://aap.onlinelibrary.wiley.com/doi/full/10.1902/jop.2017.160548>

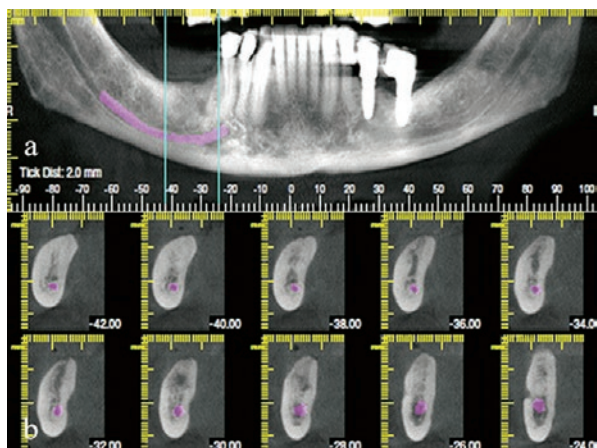


Figure 8. The orthopantomogram and the oblique sagittal reformatted view of the mandible
 Source: <https://www.ncbi.nlm.nih.gov/pmc/articles/PMC5750831/>

CBCT's application in dental implantology is based on predetermined guidelines which include the indications and limitations of its use, as well as the optimization of the radiation dose according to the requirements of the image. The pre-surgery stage of computer planning of the placement of dental implants requires 3D datasets which serve as a basis for the analysis of anatomical structures, density, quality, and shape of the bone, and many other aesthetic challenges. The main advantage of digital planning is its integrated approach to biomechanical, functional, and aesthetic factors and the minimal possibility of complications [18].

If the CBCT systems aren't standardized, the scanning parameters will drastically differ. The goal of CBCT imaging is to balance the price and the quality of results with optimal radiation doses for the patient. All CBCT scanning protocols should be adaptable to the individual patient and their indications. The size of the FOV is determined by the radiation dose, age, the requirements of the diagnostic task, and the patient's anatomy [18].

The concept of a virtual patient

A virtual patient concept is necessary for a surgical process in dental implantology. The virtual patient represents a digital record that is in accordance with all surgical, aesthetic, and prosthetic requirements and is used in planning and determining the ideal placement of a dental

implant. It is created by intertwining the data provided by CBCT, digital intraoral impressions, and the facial scan and loading it into a virtual coordinate system (Figure 9) [18]. A virtual teeth layout is formed according to the aesthetic and prosthetic requirements to determine the ideal position for the placement of a dental implant. A surgical guide is modeled after the virtual patient. Accuracy and precision are keys to a successful prosthetic surgical procedure [19]. After making a fixed denture, it needs to be made into a bite holder to be used during a double scan. The double CBCT scan enables a scan of the bite holder itself as well as a scan of the bite holder's position inside the patient's mouth. The acquired data is then integrated and used to create the virtual patient [20]. If the limited contrast and spatial resolution result in an inaccurate 3D reconstruction of the teeth, the creation of a surgical guide is not possible. If the surgical guide is placed on the teeth, CBCT is tasked with providing a faithful representation of dental arches, teeth, and alveolar processes [18].

The DICOM standard in CBCT devices

The DICOM standard (Digital Imaging and Communications in Medicine) is an integral part of radiographic devices used to scan teeth - its purpose is to define the image format [21]. CBCT provides an abundance of data which needs to be adequately stored. The DICOM standard compresses the images into smaller files using specialized algorithms and lossy or lossless methods, thus creating a large data storage capacity. For most CBCT systems there is a diagnostic data loss upon DICOM export. Other challenges in the digital data flow include the fact that there is a growing availability of non-DICOM 3D imaging data formats required to be used for an integrated virtual patient dataset. Examples include STL and OBJ formats, respectively, used for digital intraoral impressions and printing as well as for facial scanning [18].

PACS (Picture Archiving and Communication System) is a system used to transfer private visual medical data of the patient. Its use in dental medicine is limited to dental clinics, hospitals, and university centers. However, the transfer of integrated datasets into the PACS system is not possible due to the insufficient strength of the integrated virtual information which is lost on that level [18].

Postoperative use of the CBCT device

The use of CBCT is not limited to preoperative processing and planning. It does well in the postoperative assessment

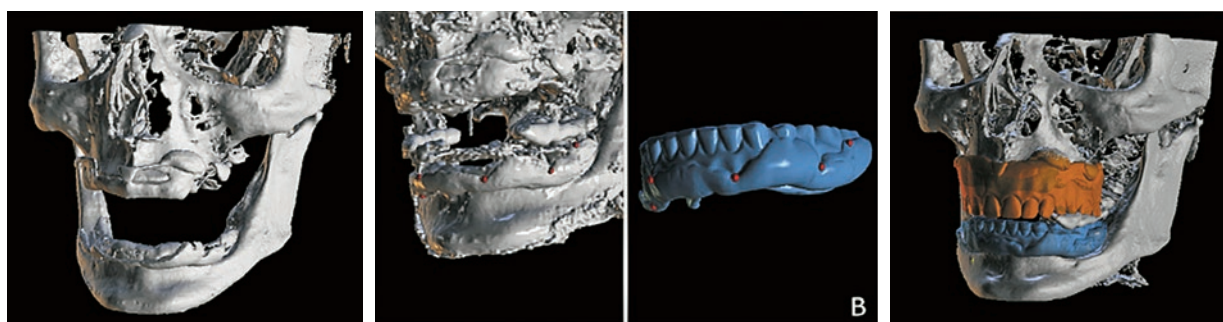


Figure 9. A 3D reconstruction of CBCT scans for the creation of a virtual patient
 Source: <https://pubmed.ncbi.nlm.nih.gov/32376032/>

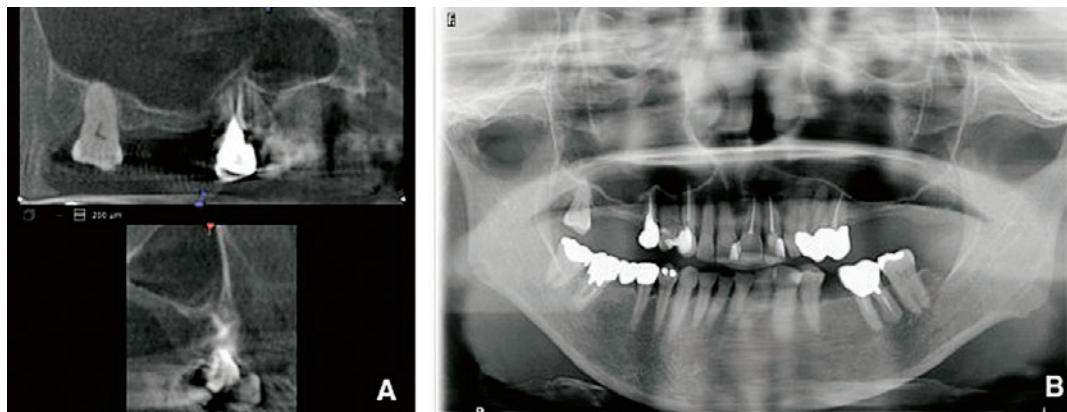


Figure 10. Pneumatization of the maxillary sinus

Source: <https://head-face-med.biomedcentral.com/articles/10.1186/1746-160X-10-20>

of healing and complications which might occur, mostly connected to the damage of neurovascular structures. In cases of injuries to neurovascular structures, dental implants must be removed. The placement of implants creates a risk of trigeminal injuries, intraoral hemorrhage, pneumatization of the maxillary sinus (Figure 10), and upper airway obstruction [18].

By analyzing the data acquired through a survey of UK dentists, Yilmaz et al. described the most common causes of iatrogenic trigeminal nerve injuries connected to dental implants. As it turns out, the most common reason for trigeminal nerve injuries is inadequate radiological assessment, which is why it is recommended to use CBCT with a small FOV when placing implants in the mandibular ramus [22].

In their study, Camps-Font et al. list factors which could increase the failure rate of the placement of dental implants which have been post-operatively infected during osseointegration. In cases of infection after the placement of dental implants, the success rate of the procedure decreases. Symptoms that point to a post-operative infection are puss, fistula in the surgical area, redness, pain, swelling, and heat [23].

The planning and placement of dental implants

For the surgical procedure to be successful and for the dental implant to be correctly positioned and stable, the density and quality of the bone need to be determined by using several pieces of software. The process of planning and placement of implants is a combination of multiple procedures. Along with determining the density and quality of the bone, it is necessary to localize and identify vital anatomical structures, as well as make a 3D topography of the alveolar ridge, a surgical guide, and to estimate possible complications and available options [15]. The distance from the roots of neighboring teeth, vital structures, occlusal plane, and relative position within the arch are all factors that make the placement of dental implants a complex procedure [13].

Quality and quantity of the bone

Quality and quantity of the bone are important factors in the placement of dental implants and are vital for the

success of the planning and positioning of the implants. Trauma, tumors, osteoporosis, and medical and radiation treatment lead to the weakening of the microstructure of bone tissue. Loss of teeth in the distal part of the maxilla increases the chances of injury of the maxillary sinus. Their pneumatization makes it impossible to place implants without performing bone reconstructions in the oral and maxillofacial region. Bone reconstructions are performed to increase the width and height of the alveolar bone before the placement of implants. A CBCT device is used to evaluate the quality and quantity of the bone - in addition to being precise and reliable, the device offers information on the position of the mandibular canal and the maxillary sinus floor [24].

The saddle length (mesiodistal), vertical bone height (occlusal-apical), and horizontal width (buccolingual) all need to be evaluated before the surgical procedure. Software packages containing CBCT are used when determining the width and height of the bone as well as the distance between the location of implant placement and neighboring vital structures. The clinician uses software to visualize the 3D alveolar ridge bone contour [13].

Pauwels et al. have researched and described the accuracy and reliability of Hounsfield units as indicators of bone density during the measuring of bone quality in their study. The quality and classification of the bone is determined using a Multidetector CT and based on Hounsfield units. A CBCT-based assessment has proven to be unreliable due to the limited field size, the limitations of the algorithm, and a large amount of scattered radiation [25].

The orientation and topography of the alveolar ridge

Before placing a dental implant, it is necessary to evaluate the orientation and topography of the alveolar ridge to avoid defects that could jeopardize the proper placement and alignment of the dental implant [13]. Defects of the alveolar ridge appear due to trauma, extraction, and periodontal disease. They can be determined using CBCT (Figure 11). They need to be evaluated, classified, and surgically corrected before placing dental implants [26].

Pitale et al. offer an overview of a comparative assessment of CBCT's precision and surgical intervention in determining defects and measuring the height of the alveolar ridge. As the approach to distal parts of back teeth

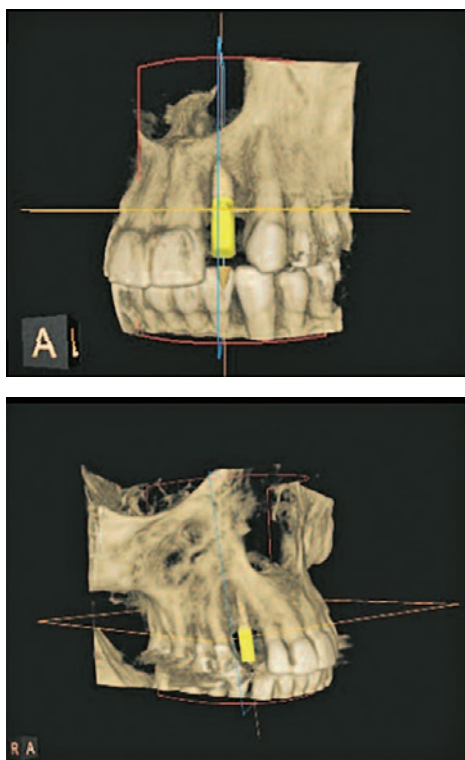


Figure 11. 3D model of an alveolar ridge defect
 Source: http://www.moderndentistrymedia.com/aug_sep2018/hartshorne_part2_references.pdf

is extremely difficult, CBCT is the best method for their visualization. The diagnostic accuracy of CBCT has proven lower for the front teeth as opposed to the back [27].

The identification and localization of anatomical structures

By identifying and localizing anatomical structures close to the location of implant placement many possible complications can be avoided. In case of teeth loss in the maxillary anterior region, which is an incredibly complicated area for planning and placement of implants, in most cases, it is necessary to perform bone augmentation. Pneumatization of the maxillary sinus is a complication that mostly occurs in implant placement in the distal part of the maxilla. This and other complications can be avoided by raising the floor of the maxillary sinus and by bone transplantation. Even though CBCT isn't suitable for scanning soft tissue, its scan of the maxillary sinus is accurate and precise (Figure 12). As opposed to the anterior maxilla, the anterior mandible is a favorable spot for implant placement. The submandibular gland fossa and the alveolar canal are the main orientation structures of the mandible. Their localization helps avoid complications such as intraoperative hemorrhaging, neurosensory loss, and the risk of perforation [13].

Based on the analysis of CBCT scans, Ribas et al. have conducted a study in which they evaluate mistakes in the positioning of dental implants and their interconnection

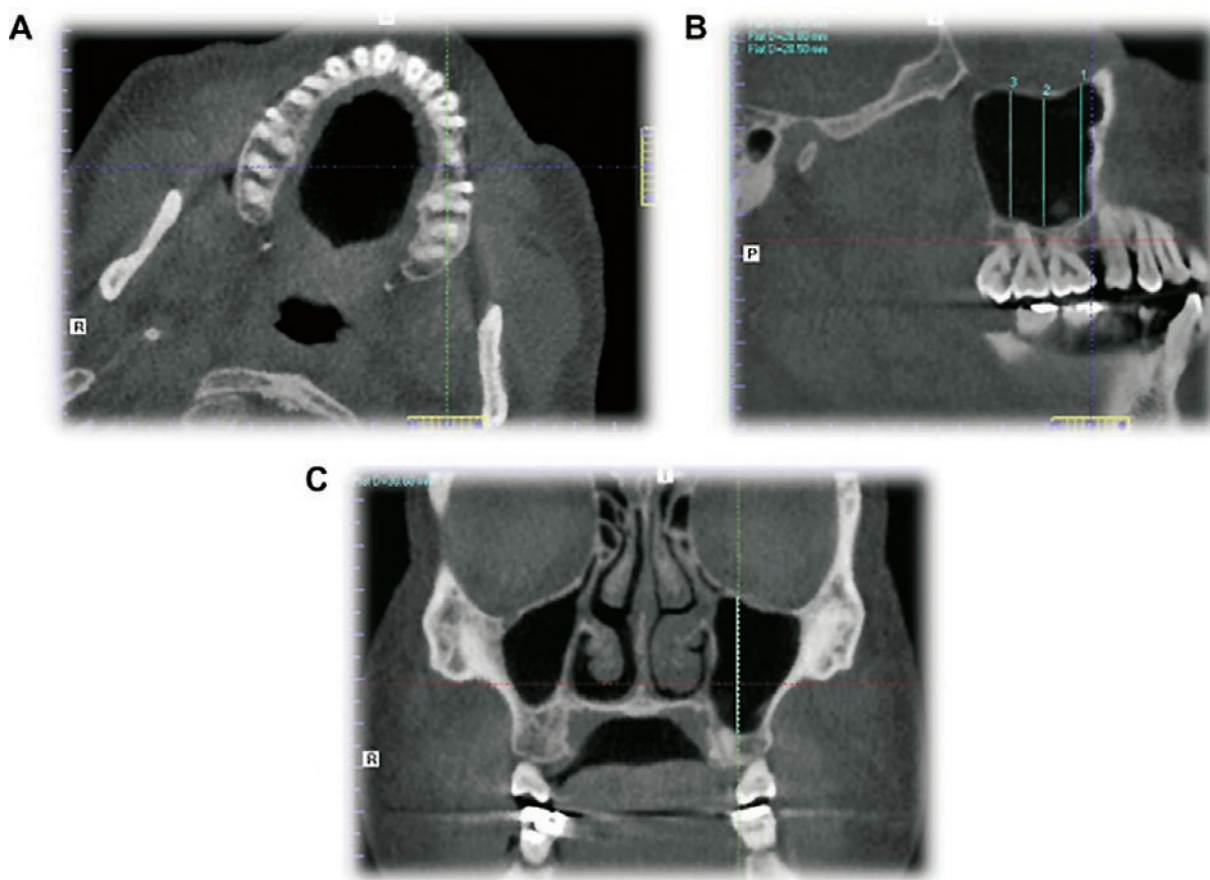


Figure 12. Measuring of the maxillary sinus and parts of the jaw in a transversal (A), sagittal (B), and coronal (C) cross-section
 Source: <https://www.sciencedirect.com/science/article/pii/S2090123213000854>

to neighboring anatomical structures. The mistakes were frequent during the positioning of the implants, but they were not related to the presence of anatomical variations [28].

Puri et al. analyzed 80 CBCT scans of the mandible. They studied the position and shape of the mandibular canal, anterior mental loop, mental foramen, and alveolar nerve. Due to large variations of anatomical orientation points it is necessary to determine a "safe region" before performing a surgical procedure. CBCT offers a clear view of the anatomical structures of the mandible [29].

Advantages of CBCT

CBCT has become widely used due to its many advantages over 2D radiological methods. Generation of 2D structures, 3D displays of the structures of the head and neck, decreased magnification error, lower price, and radiation dose, easier access to the scans through the DICOM standard, and fewer artifacts are just some of the advantages of CBCT [30].

The aforementioned advantages make the process of planning and placement of the implants easier and extremely precise. After an optical scan of the teeth, CBCT can create a digital model of the bone, teeth, and soft tissue. Its most significant advantage is the prevention of nerve injury which is done by laying out the trajectory of the nerve and choosing an implant of adequate length. Nerve injury can lead to complete or partial paralysis of parts of the lips and chin, which can become a permanent condition [13].

Choosing an implant of the right size ensures optimal support and the success of the procedure, which in turn enables the implant to last longer. CBCT offers the possibility of measurement during the process of choosing the right width and height of the implants. In addition to

measuring, the choice of implants is affected by the individual patient's needs, biological requirements, and bite plates. Because of the safe outcome of the placement it ensures, CBCT is a necessary imaging method in dental implantology [13].

Based on dentists' experiences, Garlapati et al. have conducted a survey in which they estimate the purpose and advantages of using CBCT devices in clinical practice in comparison with orthopantomography. In a span of 3 months, they gathered 620 CBCT scans and orthopantomograms. Almost half of the CBCT scans were done before the placement of dental implants, which establishes CBCT as a method of choice in dental implantology. It enables better diagnostics due to its precise and detailed scans, which is why it has been increasingly replacing orthopantomography in practice [31].

Rajković Pavlović et al. states the advantages of the analysis of data provided by CBCT during the estimation of morphological characteristics of the intra-alveolar septum of the maxillary sinus. They analyzed data acquired from the axial and sagittal cross-section and concluded that CBCT is extremely useful during implant placement in the area of maxillary molars [32].

By comparing data from a digital orthopantomogram and a CBCT device, Issrani et al. have estimated the risk connected to inferior nerve injury during a procedure on mandibular molars. After orthopantomography, impacted mandibular third molars had to be scanned using CBCT to determine the position of the mandibular canal. The use of orthopantomography is justified due to its lower price, even though CBCT is a far more advanced technique with higher accuracy and precision during analysis and making a diagnosis [33]. Acar et al. have described all advantages and disadvantages of CBCT's use in dental implantology in their paper, and have especially pointed out CBCT's ability to perform multiplanar reconstructions (Table 1) [34].

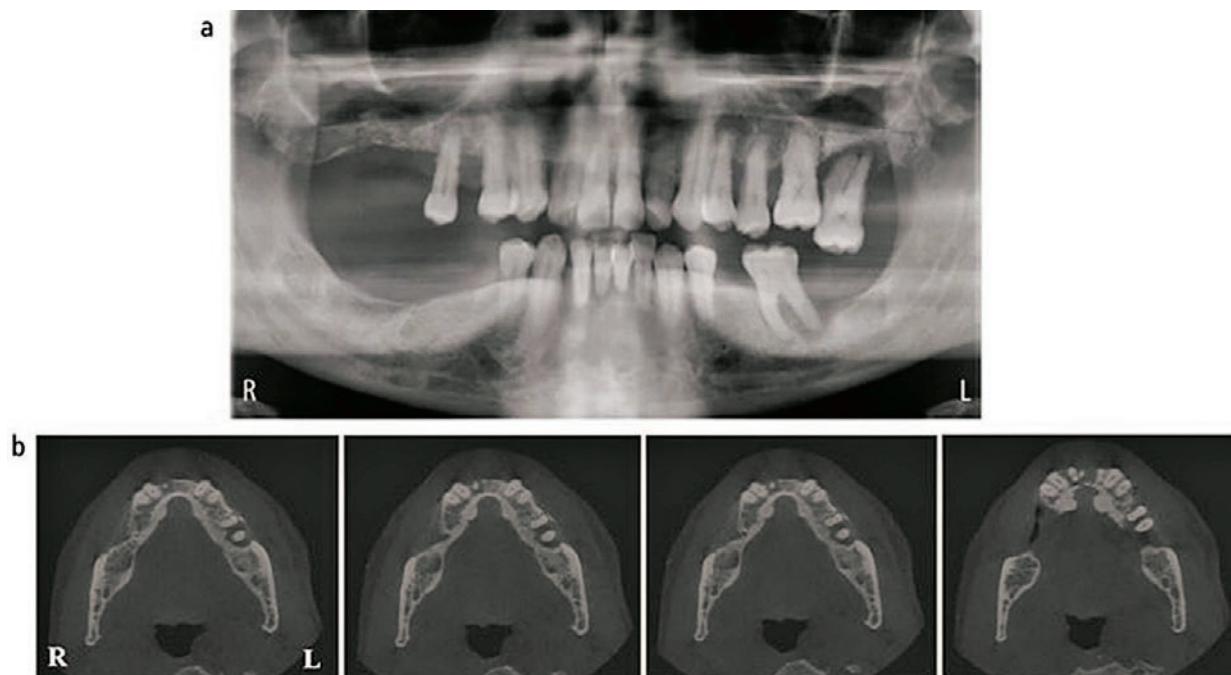


Figure 13. Orthopantomogram with potential implants in the lower jaw (a); CBCT showing a significant bone loss, especially in the bottom right section (b)

Source: <https://www.nature.com/articles/s41415-020-1522-x>

Table 1. The comparison of characteristics of CBCT and conventional radiography [34]

CBCT	Conventional radiography
3D imaging	2D imaging
Cross-sections and volumetric images	Superimpositions
Distortion removal	Distortion and magnification
higher radiation dose	Lower radiation dose
Higher cost	Lower cost
Larger devices	Less space required

Haiderali, a senior CBCT radiographer, has published a paper in the British Dental Journal in which she describes the role of the radiographer in the process of selecting the FOV, scanning, and voxel parameters based on clinical indications and the patient. This way, the exposure is optimized and the biggest possible amount of diagnostic information is acquired [35].

In the first case, she describes and compares the orthopantomographic and CBCT scans of a fifty-year-old before implant placement in the lower jaw. The orthopantomographic scans show flaws in the change of bone structure, but their extent is unable to be determined based on those images. However, based on CBCT images, a complete assessment of pathology and anatomical variations is possible (Figure 13) [35].

In the second case, a reconstruction of the panoramic view shows a tooth fracture, the increased density of the maxillary sinus, and the low position of the inferior borders (Figure 14). CBCT is not only used for the assessment of the condition of bone structures but also for the assessment of the condition of bone structures outside of the dental region. In the case of misidentification and mislocalization of neurovascular structures, their damage is inevitable [35].

Disadvantages of CBCT

Although CBCT has numerous advantages, certain disadvantages were also noted during its application. Low contrast range, restricted FOV, and volume of the scan are disadvantages that may be caused by the type and size of the detectors. CBCT displays hard tissues with more clarity than soft tissues, therefore the display of muscle attachments is limited. If the patient moves, the scanning must be repeated [30]. If the process of placing dental implants requires an assessment of soft tissue structures' condition, the patient should be referred for CT or MRI. CBCT does have fixation parts, but they are not very reliable [13].

In the process of planning and placing implants, CBCT is primarily used for an assessment of the condition of bone structures. Bone density is the main indicator of bone quality and is expressed using Hounsfield units. The level of the grayscale and the value of Hounsfield units in CBCT are not as relevant to the bone quality determination, as they are in CT [13].

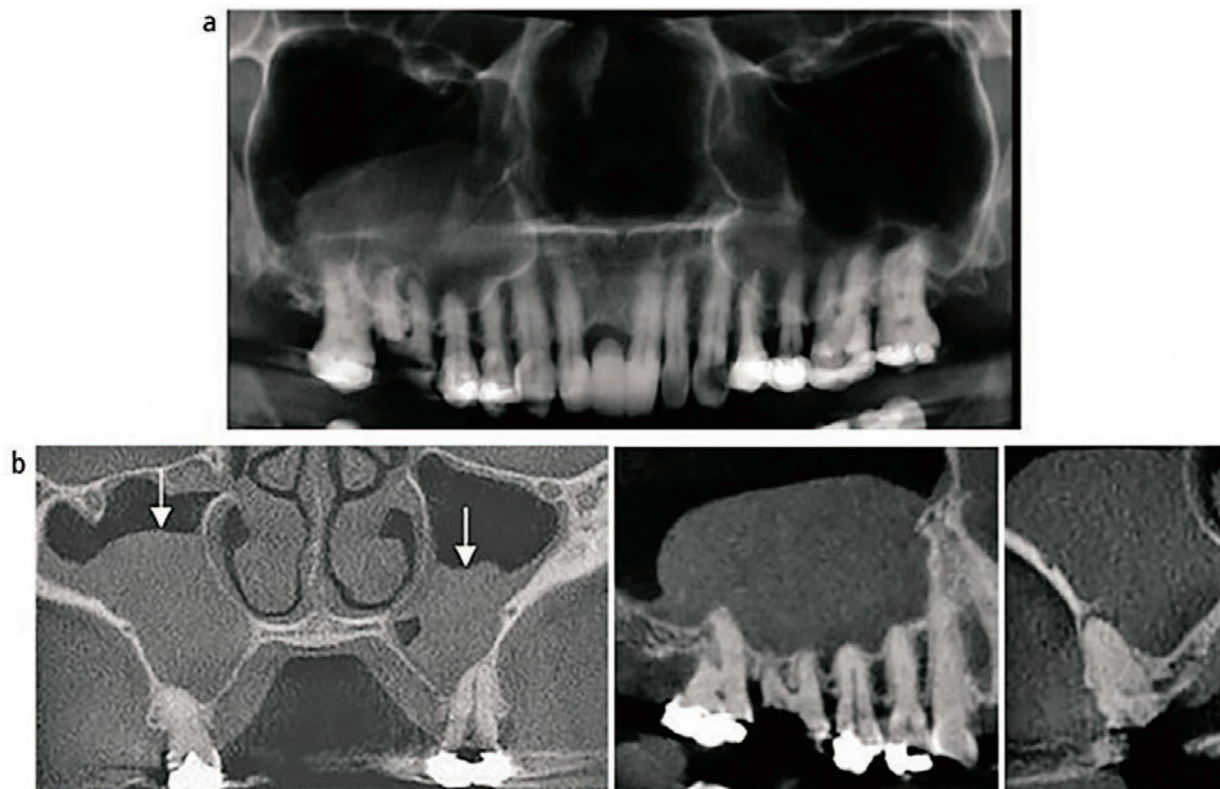


Figure 14. A reconstructed panoramic view of the teeth (a); a coronal cross section and display of increased density and thickness of the maxillary sinus wall (b)

Source: <https://www.nature.com/articles/s41415-020-1522-x>

The aim of the study conducted by Kim et al. is to prove that possibility CBCT can be used for assessing the mineral density of the bone. They point out the lower contrast and a larger amount of noise and the disadvantages of CBCT. Its reliability in measuring the mineral density of the bone has not yet been definitely confirmed [36].

In their study, Sönmez et al. compare and evaluate the accuracy of high-resolution ultrasound with CBCT during the measuring of gingival soft tissue in edentulous patients before the implant placement. The disadvantages of CBCT that were noticed during the study are scattered radiation, a higher dose of radiation, beam hardening artifacts, limited dynamic range, and minimal soft-tissue detail. High-resolution ultrasound is a method of choice for preoperative soft tissue assessment [37].

Artifacts in CBCT

Artifacts are a common occurrence on CBCT images and most often occur due to the presence of various materials and the patient's movement, which negatively affects the quality of the image and makes its analysis impossible. Artifacts are manifested in form of bright streaks, dark areas near the object, and complete loss of information between adjacent objects [18]. The artifacts are caused by factors related to image quality and physical factors of the device, but also can be caused by the patient, the patient's movement during image acquisition, and metallic materials in the examination area (Figure 15). Artifacts are created during the reconstruction of the obtained images [38].

Pauwels et al. analyzed metal artifacts in their research. They used a phantom that contains titanium and lead rods, and scanned it on 13 CBCT devices and one MSCT device, using low-dose and high-dose protocols (Figure 16). Artifacts were assessed by measuring the standard deviation of voxel values, and most CBCT

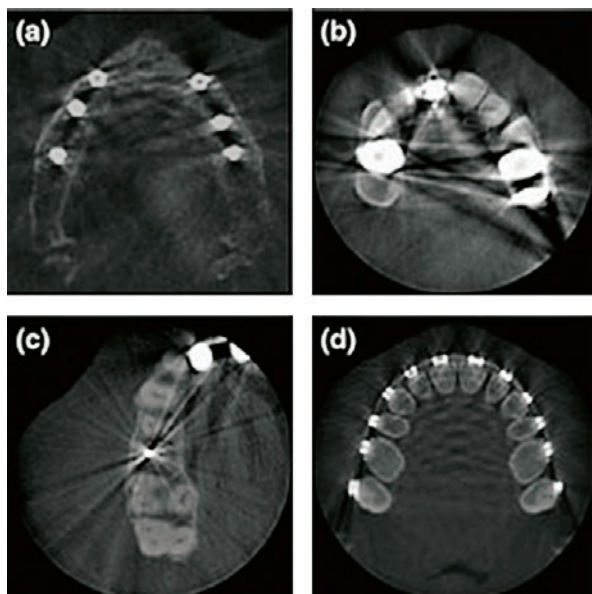


Figure 15. Metal artifacts in CBCT footage

Source: https://www.researchgate.net/figure/Examples-of-metal-artifacts-on-cone-beam-computed-tomography-images-in-clinical-practice_fig1_51877475

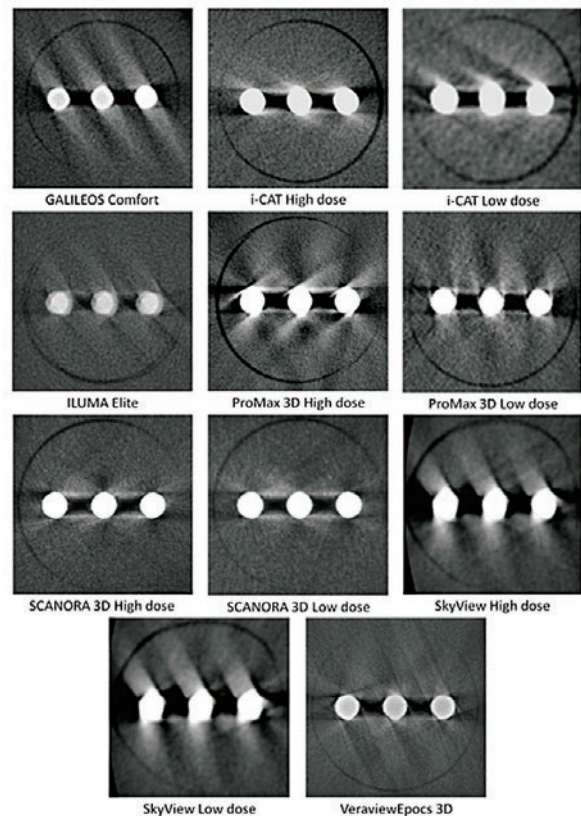


Figure 16. Axial sections of titanium rods

Source: https://www.researchgate.net/figure/Example-axial-slices-for-metal-artifact-inserts-showing-three-titanium-rods_fig4_51803619

devices performed worse for titanium artifacts than for lead ones [39].

Vehdani et al. analyzed CBCT images of metal artifacts caused by dental implants. The noise ratio was calculated based on measured grayscale values, and it is also influenced by the fixture material of dental implants, the part of the jaw that is being scanned, and scanning parameters. The size and longitudinal section of the fixtures had no impact on the creation of artifacts [40].

Radiation dose in CBCT

During the application of CBCT in the diagnostic process the goal is to achieve a balance between image quality and radiation dose. CBCT uses lower radiation doses compared to CT. The radiation dose needs to be adjusted to the patient and their indications [18]. Technological progress and improvement of software and hardware features enabled a smaller radiation dose for the patient. The modification of radiation dose was affected by detector technology, scanning time, and available fields of view. Most procedures in the implant placement process do not require high-resolution images [41]. An effective radiation dose of CBCT is from 13 μ Sv to 479 μ Sv. Compared to CT, CBCT is a method of reducing the radiation dose in the process of planning and implant placement. Application of the lowest mA setting, a pulsed exposure mode of acquisition, a reduction of the FOV, and radiation exposure time are just some of the ways to reduce the radiation dose [30].

Conclusion

Dental implants are increasingly used in the process of teeth replacement, and they successfully replace fixed dentures. CBCT has the possibility of measuring bone quality and quantity, the distances between anatomical structures, and postoperative assessment of the procedure's success. The construction and storage of patterns for implant placement are done using a 3D program for virtual planning. Because of numerous advantages such as high resolution, reduced costs, and lower radiation dose, CBCT has become an indispensable device in

dental implantology. Implants of the appropriate size are selected after the analysis of acquired information and after measurement-based CBCT scans, and they guarantee the durability and success of the procedure. CBCT isn't suitable for scanning soft-tissues structures due to the frequent occurrence of artifacts, the limited FOV, and the unreliability of measurement of bone density and shades of grayscale. Numerous post-surgical complications occur in those implant placement processes which were not planned based on CBCT scans, and it is often necessary to repeat the procedure. CBCT application in dental implant placement is of great importance and, because of its numerous advantages and qualities, irreplaceable. ■

Uloga CBCT-a u području dentalne implantologije

Sažetak

Brzim i kontinuiranim razvojem radiologije, dentalni radiološki uređaji postaju sastavni dio stomatološke prakse. CBCT omogućuje precizan trodimenzionalni prikaz orofacijalnog područja. Nedostatci dvodimenzionalnih radioloških metoda poticaj su za širu primjenu CBCT uređaja, posebno u području dentalne implantologije. Cilj rada je opisati prednosti i nedostatke primjene CBCT uređaja u procesu planiranja i postavljanja dentalnih implantata. Rad pruža uvid u artefakte i doze zračenja te njihov utjecaj na kvalitetu slike. Kao prednosti primjene CBCT uređaja posebno se ističu generiranje multiplanarnih rezova područja od interesa, mogućnost 3D rekonstrukcije, smanjenje pogreške povećanja, artefakti i doza zračenja. Ograničeni FOV i volumen snimanja, nizak raspon kontrasta, mjerenje gustoće kosti i nijansi sive skale te artefakti pomicanja neki su od nedostataka CBCT uređaja. Uz procese planiranja i postavljanja dentalnih implantata, CBCT uređaj je pronašao primjenu i u postoperativnim procjenama cijeljenja implantata i nastanka mogućih komplikacija. CBCT spoj je ravnoteže cijene i doze zračenja te kvalitete kliničkih informacija. CBCT uređaj primjenjuje se i u području oralne kirurgije, ortodonticije, parodontologije i endodonticije. Zbog svoje preciznosti i kvalitete, CBCT uređaj temelj je dentalne implantologije.

Ključne riječi: CBCT, dentalni implantati, gustoća kosti, zubi, 3D prikaz

References

- Janković S, Mihanović F. Uvod u radiologiju, Split: Sveučilište u Splitu, 2014.
- Pauwels R. History of dental radiography: Evolution of 2D and 3D imaging modalities. *Medical Physics International*. 2020;8(1):235-277.
- Janković S, Mihanović F, Punda A, Radović D, Barić A, Hrepić D. Radiološki uređaji i oprema u radiologiji, radioterapiji i nuklearnoj medicini. Split: Sveučilište u Splitu; 2015.
- Lauc T. 3D diagnostics in orofacial region. *Rad Hrvatske akademije znanosti i umjetnosti. Medicinske znanosti [Internet]*. 2012; (514=38):127-151.
- Available at: <https://hrcak.srce.hr/91370>
- Kumar M, Shanavas M, Sidappa A, Kiran M. Cone beam computed tomography - know its secrets. *J Int Oral Health*. 2015 Feb;7(2):64-8.
- Hartshorne J. Essential guidelines for using cone beam computed tomography (CBCT) in implant dentistry. Part 1: Technical considerations [Internet]. *International Dentistry-African Edition Vol.8 No.3*. 2018
- Available at: http://www.moderndentistrymedia.com/jun_jul2018/hartshorne_part1.pdf
- Pauwels R, Araki K, Siewerdsen JH, Thongvigitmanee SS. Technical aspects of dental CBCT: state of the art. *Dentomaxillofac Radiol*. 2015;44(1):20140224.
- Brüllmann D, Schulze RK. Spatial resolution in CBCT machines for dental/maxillofacial applications-what do we know today? *Dentomaxillofac Radiol*. 2015;44(1):20140204.
- Kehrwald R, Castro HS, Salmeron S, Matheus RA, Santaella GM, Queiroz PM. Influence of Voxel Size on CBCT Images for Dental Implants Planning. *Eur J Dent*. 2021 Dec 13.
- Komšić S. Učinkovitost CBCT-a u detekciji koštanih defekata kod generaliziranog kroničnog parodontitisa [Internet]. Zagreb, Sveučilište u Zagrebu, Stomatološki fakultet; 2021
- Available at: <https://repozitorij.sfzg.unizg.hr/islandora/object/sfzg:770>
- Venkatesh E, Elluru SV. Cone beam computed tomography: basics and applications in dentistry. *J Istanbul Univ Fac Dent*. 2017 Dec 2;51(3 Suppl 1):S102-S121
- Gupta R, Gupta N, Weber, DDS KK. Dental Implants. 2022 Aug 8. In: *StatPearls [Internet]*. Treasure Island (FL): StatPearls Publishing; 2023 Jan-. PMID: 29262027.

16. Hartshorne J. Essential guidelines for using cone beam computed tomography (CBCT) in implant dentistry. Part 2: Clinical considerations [Internet]. International Dentistry-African Edition Vol.8 No.4. 2018.
17. Available at: http://www.moderndentistrymedia.com/aug_sep2018/hartshorne_part2_references.pdf
18. Chan HL, Misch K, Wang HL. Dental imaging in implant treatment planning. *Implant Dent*. 2010 Aug;19(4):288-98.
19. Benavides E, Rios HF, Ganz SD, An CH, Resnik R, Reardon GT, Feldman SJ, Mah JK, Hatcher D, Kim MJ, Sohn DS, Palti A, Perel ML, Judy KW, Misch CE, Wang HL. Use of cone beam computed tomography in implant dentistry: the International Congress of Oral Implantologists consensus report. *Implant Dent*. 2012 Apr;21(2):78-86.
20. Rios HF, Borgnakke WS, Benavides E. The Use of Cone-Beam Computed Tomography in Management of Patients Requiring Dental Implants: An American Academy of Periodontology Best Evidence Review. *J Periodontol*. 2017 Oct;88(10):946-959.
21. Greenberg AM. Advanced dental implant placement techniques. *J Istanbul Univ Fac Dent*. 2017 Dec 2;51(3 Suppl 1):S76-S89.
22. Jacobs R, Salmon B, Codari M, Hassan B, Bornstein MM. Cone beam computed tomography in implant dentistry: recommendations for clinical use. *BMC Oral Health*. 2018 May 15;18(1):88.
23. Flügge TV, Nelson K, Schmelzeisen R, Metzger MC. Three-dimensional plotting and printing of an implant drilling guide: simplifying guided implant surgery. *J Oral Maxillofac Surg*. 2013 Aug;71(8):1340-6.
24. Li J, Sommer C, Wang HL, Lepidi L, Joda T, Mendonca G. Creating a virtual patient for completely edentulous computer-aided implant surgery: A dental technique. *J Prosthet Dent*. 2021 Apr;125(4):564-568.
25. About DICOM: Overview
26. Available at: <https://www.dicomstandard.org/about>
27. Yılmaz Z, Ucer C, Scher E, Suzuki J, Renton T. A Survey of the Opinion and Experience of UK Dentists: Part 1: The Incidence and Cause of Iatrogenic Trigeminal Nerve Injuries Related to Dental Implant Surgery. *Implant Dent*. 2016 Oct;25(5):638-45.
28. Camps-Font O, Martín-Fatás P, Clé-Ovejero A, Figueiredo R, Gay-Escoda C, Valmaseda-Castellón E. Postoperative infections after dental implant placement: Variables associated with increased risk of failure. *J Periodontol*. 2018 Oct;89(10):1165-1173.
29. Rac M. Ugradnja dentalnih implantata-čimbenici uspjeha i razlike terapije [Internet] Zagreb, Sveučilište u Zagrebu, Stomatološki fakultet; 2021
30. Available at: <https://zir.nsk.hr/islandora/object/sfzg:956>
31. Pauwels R, Jacobs R, Singer SR, Mupparapu M. CBCT-based bone quality assessment: are Hounsfield units applicable? *Dentomaxillofac Radiol*. 2015;44(1):20140238.
32. Bilandžija V. Tehnike augmentacije kod vertikalne atrofije alveolarnog grebena [Internet] Zagreb, Sveučilište u Zagrebu, Stomatološki fakultet, 2016
33. Available at: <https://repozitorij.sfzg.unizg.hr/islandora/object/sfzg:188>
34. Pitale U, Mankad H, Pandey R, Pal PC, Dhakad S, Mittal A. Comparative evaluation of the precision of cone-beam computed tomography and surgical intervention in the determination of periodontal bone defects: A clinicoradiographic study. *J Indian Soc Periodontol*. 2020 Mar-Apr;24(2):127-134.
35. Ribas BR, Nascimento EHL, Freitas DQ, Pontual ADA, Pontual MLDA, Perez DEC, Ramos-Perez FMM. Positioning errors of dental implants and their associations with adjacent structures and anatomical variations: A CBCT-based study. *Imaging Sci Dent*. 2020 Dec;50(4):281-290.
36. Puri A, Verma P, Mahajan P, Bansal A, Kohli S, Faraz SA. CBCT Evaluation of the Vital Mandibular Interforaminal Anatomical Structures. *Ann Maxillofac Surg*. 2020 Jan-Jun;10(1):149-157.
37. Joshi H, Pandya J. 3D IMAGING AND CBCT: A RISING TREND IN DENTISTRY AND ORTHODONTICS [Internet]. International Research Journal of Modernization in Engineering Technology and Science. Volume:03/Issue:03/March-2021
38. Available at: https://www.irjmets.com/uploadedfiles/paper/volume3/issue_3_march_2021/6581/1628083278.pdf
39. Garlapati K, Babu DBG, Chaitanya NCSK, Guduru H, Rembers A, Soni P. Evaluation of Preference and Purpose of Utilisation of Cone Beam Computed Tomography (CBCT) Compared to Orthopantomogram (OPG) by Dental Practitioners – A Cross-Sectional Study. *Pol J Radiol*. 2017 May 4;82:248-251.
40. Pavlovic ZR, Milanovic P, Vasiljevic M, Jovicic N, Arnaut A, Colic D, Petrovic M, Stevanovic M, Selakovic D, Rosic G. Assessment of Maxillary Molars Interradicular Septum Morphological Characteristics as Criteria for Ideal Immediate Implant Placement-The Advantages of Cone Beam Computed Tomography Analysis. *Diagnostics (Basel)*. 2022 Apr 16;12(4):1010.
41. Issrani R, Prabhu N, Sghaireen M, Alshubrmi HR, Alanazi AM, Alkhalaf ZA, Alnusayri MO, Aljohani FM, Khan ZA. Comparison of Digital OPG and CBCT in Assessment of Risk Factors Associated with Inferior Nerve Injury during Mandibular Third Molar Surgery. *Diagnostics (Basel)*. 2021 Dec 6;11(12):2282.
42. Acar B, Kamburoğlu K. Use of cone beam computed tomography in periodontology. *World J Radiol*. 2014 May 28;6(5):139-47.
43. The role of CBCT in implant dentistry: uses, benefits and limitations. *Br Dent J* **228**, 560-561 (2020).
44. Sönmez G, Kamburoğlu K, Gülşahi A. Accuracy of high-resolution ultrasound (US) for gingival soft tissue thickness measurement in edentulous patients prior to implant placement. *Dentomaxillofac Radiol*. 2021 Jul 1;50(5):20200309.
45. Kim DG. Can dental cone beam computed tomography assess bone mineral density? *J Bone Metab*. 2014 May;21(2):117-26.
46. Terrabuio BR, Carvalho CG, Peralta-Mamani M, Santos PSDS, Rubira-Bullen IRF, Rubira CMF. Cone-beam computed tomography artifacts in the presence of dental implants and associated factors: an integrative review. *Imaging Sci Dent*. 2021 Jun;51(2):93-106.
47. Pauwels R, Stamatakis H, Bosmans H, Bogaerts R, Jacobs R, Horner K, Tsiklakis K; SEDENTEXCT Project Consortium. Quantification of metal artifacts on cone beam computed tomography images. *Clin Oral Implants Res*. 2013 Aug;24 Suppl A100:94-9.
48. Vahdani N, Moudi E, Ghobadi F, Mohammadi E, Bijani A, Haghani S. Evaluation of the Metal Artifact Caused by Dental Implants in Cone Beam Computed Tomography Images. *Maedica (Bucur)*. 2020 Jun;15(2):224-229.
49. Rios HF, Borgnakke WS, Benavides E. The Use of Cone-Beam Computed Tomography in Management of Patients Requiring Dental Implants: An American Academy of Periodontology Best Evidence Review. *J Periodontol*. 2017 Oct;88(10):946-959.