



AALBORG UNIVERSITY
DENMARK

Aalborg Universitet

Lemierre's syndrome-A diagnostic challenge

Bedan, Martin; Gloksin, Witold; Hagen, Trine Langfeldt

Published in:
Diagnostic Microbiology and Infectious Disease

DOI (link to publication from Publisher):
[10.1016/j.diagmicrobio.2023.116023](https://doi.org/10.1016/j.diagmicrobio.2023.116023)

Creative Commons License
CC BY 4.0

Publication date:
2023

Document Version
Publisher's PDF, also known as Version of record

[Link to publication from Aalborg University](#)

Citation for published version (APA):
Bedan, M., Gloksin, W., & Hagen, T. L. (2023). Lemierre's syndrome-A diagnostic challenge. *Diagnostic Microbiology and Infectious Disease*, 107(2), [116023]. <https://doi.org/10.1016/j.diagmicrobio.2023.116023>

General rights

Copyright and moral rights for the publications made accessible in the public portal are retained by the authors and/or other copyright owners and it is a condition of accessing publications that users recognise and abide by the legal requirements associated with these rights.

- Users may download and print one copy of any publication from the public portal for the purpose of private study or research.
- You may not further distribute the material or use it for any profit-making activity or commercial gain
- You may freely distribute the URL identifying the publication in the public portal -

Take down policy

If you believe that this document breaches copyright please contact us at vbn@aub.aau.dk providing details, and we will remove access to the work immediately and investigate your claim.



Contents lists available at ScienceDirect

Diagnostic Microbiology and Infectious Disease

journal homepage: www.elsevier.com/locate/diagmicrobio

Case Report

Lemierre's syndrome—A diagnostic challenge

Martin Bedan*, Witold Gloksin, Trine Langfeldt Hagen

Aalborg University Hospital, Thisted Hospital, Thisted, Denmark

ARTICLE INFO

Article history:

Received 13 March 2023
Revised in revised form 6 July 2023
Accepted 9 July 2023
Available online 13 July 2023

Keywords:

Case report
Lemierre's syndrome
Fusobacterium necrophorum
Bacterial infection

ABSTRACT

In this case report, we present a young man with Lemierre's syndrome, which is a potentially fatal condition most commonly caused by the bacterium *Fusobacterium necrophorum*. When Lemierre's syndrome is suspected, it is important to consider X-ray, ultrasound, and CT scan, as they can bring tremendous diagnostic value.

© 2023 The Author(s). Published by Elsevier Inc. This is an open access article under the CC BY license (<http://creativecommons.org/licenses/by/4.0/>)

1. Introduction

Lemierre's syndrome (LS) is a rare condition most commonly caused by the gram-negative, anaerobic rod-shaped bacterium *Fusobacterium necrophorum* (FN) that can pose a serious threat with a fatal outcome if not recognized and treated properly [1].

In this case report we present a young man with LS and highlight the diagnostic value of imaging techniques.

2. Case

A 29-year-old, otherwise healthy male was admitted to our emergency department due to fever, productive cough, throat pain, slight dysphagia, and a sparse amount of brownish expectoration that had developed over a few days. The patient did not exhibit a history of poor oral hygiene prior to admission and had not undergone any recent dental procedures. The physical examination showed a slightly erythematous palate with white circular areas and pronounced redness of both tonsils, as well as submandibular lymphadenopathy. His temperature was 40.4°C and C-reactive protein (CRP) was elevated to 319 mg/L. He had been treated with oral roxithromycin for 1 day. This was replaced by intravenous (IV) cefuroxime due to suspicion of tonsillitis since he previously had an anaphylactic

reaction to penicillin. After 24 hours he became afebrile and was feeling subjectively better.

A few days after admission, blood cultures flagged positive for FN in 1 of 3 cultivation flasks, which raised suspicion of LS. A computed tomography scan (CT scan) showed multiple bilateral infiltrates in both lungs compatible with septic emboli and the final diagnosis of LS was made. Metronidazole was added as a complementary antibiotic.

The patient was discharged to outpatient parental antibiotic therapy (OPAT) for a total of 3 weeks of IV ceftriaxone and oral metronidazole. However, metronidazole had to be discontinued due to severe nausea and elevated alanine aminotransferase (ALT), after which the patient was successfully treated with ceftriaxone as monotherapy for the remainder of the treatment course.

A repeat CT-scan approximately 6 weeks after the start of treatment showed significant regression in the affected pulmonary areas. Figs. 1A–C show the initial CT scans performed as part of the diagnostic process compared to the repeat CT scans after 6 weeks of treatment in the coronal plane.

3. Discussion

Sinave et al. reviewed the literature on LS and analyzed a total of 38 cases and found that LS was associated with FN in 81% of the cases. However, other pathogenic species have also been associated with LS [2]. In the classical presentation of LS, the primary infection consists of pharyngitis, whereafter a local invasion of the parapharyngeal space and internal jugular vein (IJV) can occur, leading to septic thrombophlebitis. The infection can progress by hematogenous spread to other organs, most commonly to the lungs [3]. There is a

Abbreviations: ALT, alanine aminotransferase; CRP, C-reactive protein; CT, computed tomography; FN, *Fusobacterium necrophorum*; IJV, internal jugular vein; IV, intravenous; LS, Lemierre's syndrome; NTM, nontuberculosis mycobacteria; OPAT, outpatient parental antibiotic therapy

* Corresponding author: Tel: +45 26 22 76 49

E-mail addresses: m.bedan@rn.dk (M. Bedan), w.gloksin@rn.dk (W. Gloksin), trine.hagen@rn.dk (T.L. Hagen).

<https://doi.org/10.1016/j.diagmicrobio.2023.116023>

0732-8893/© 2023 The Author(s). Published by Elsevier Inc. This is an open access article under the CC BY license (<http://creativecommons.org/licenses/by/4.0/>)

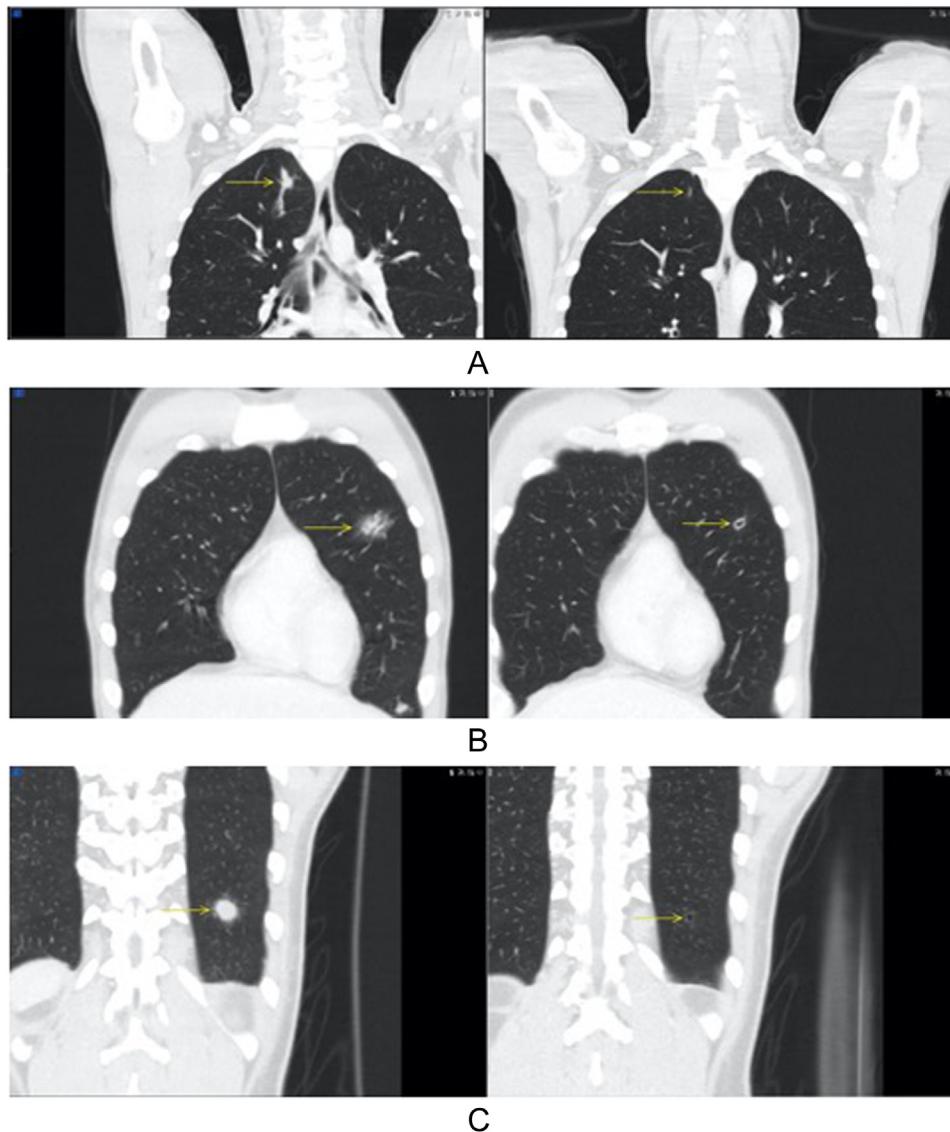


Fig. 1. Initial CT scans of the thorax after early antibiotic commencement compared to repeat CT scans after 6 weeks of treatment, demonstrating significant regression of infiltrates (arrows) and development of small areas of cavitation. (A) Shows an infiltrate located in the upper lobe of the right lung (first segment). The infiltrate was significantly reduced in size. (B) Shows an infiltrate located in the upper lobe of the left lung (fourth segment). The infiltrate was partially reduced in size with cavitary formation. (C) Shows an infiltrate located in the lower lobe of the left lung (10th segment). The infiltrate was significantly reduced in size with cavitary formation.

general consensus in the literature regarding the diagnostic criteria of LS:

1. Case report or clinical findings consistent with pharyngeal illness, such as tonsillitis.
2. Septic emboli (e.g., in the lungs).
3. Either thrombosis of the IJV or findings of FN in blood culture [4].

However, it is important to be aware of the existence of literature that has presented other diagnostic criteria [5].

A systematic review conducted by Karkos et al. revealed that X-ray was the first-line investigation in the majority (92%) of LS patients in acute care. In 75% of the cases, some degree of pulmonary consolidation was shown on the X-ray, whereas 10% of the X-rays were reported as normal [4]. Furthermore, septic emboli, a key feature of LS, can to some degree be detected in plain radiography in 23% to 47% of cases as cavitation [6].

A CT scan is optimal for clearly showing septic emboli and IJV thrombosis, but ultrasound can also play an important role in the diagnosis of LS. It is an inexpensive, simple, safe, and quick method

for detecting IJV thrombosis; however, it is a highly operator-dependent examination [7].

In our case, the suspicion of LS did not arise until the pathogen was identified in blood culture. The CT-scan revealed signs of septic emboli in both lungs, and if this examination had been performed before the results of the blood culture were available, it would more likely have given rise to the suspicion earlier. Regardless, the final diagnosis would have been made when the blood culture was available because only then were all 3 diagnostic criteria of the disease met.

Although apical cavitary lesions, as shown in the CT-scan of our patient, could have other causes, such as tuberculosis, nontuberculous mycobacteria (NTM), or fungal infections [8], we ascribe these radiological findings to the infection caused by FN. First, these infections are most often associated with certain risk factors, such as immunosuppression [8,9] and exposure in an endemic setting. Our patient neither showed signs of immunosuppression nor had any history of likely previous exposure to these pathogens. Secondly, since the patient quickly responded to the initiated treatment, we did not find indication to investigate for other, less likely causes.

Table 1

Overview of published case reports with LS caused by FN.

Reference, year	Age, gender	Symptomatology	Antibiotic treatment
Panchani et al., 2021 [10]	65, M	Fever, rigors, chills, dysuria, urinary frequency, vomiting	Piperacillin/tazobactam, metronidazole
Alves et al., 2019 [11]	12, F	Fever, epistaxis, petechial lesions, odynophagia	Amoxicillin/clavulanate, metronidazole
Whittle et al., 2018 [12]	16, M	Fever, diarrhea, vomiting, abdominal pain	Benzylpenicillin, metronidazole
Singh et al., 2018 [13]	32, M	Fever, sore throat, abdominal pain, cough, dyspnea, hemoptysis	Ampicillin-sulbactam
Vijay et al., 2018 [14]	21, M	Fever, sore throat, cough, dyspnea, odynophagia, rigors, neck/ ear/chest pain	Piperacillin/tazobactam, metronidazole
Hedenmark et al., 2018 [15]	16, F	Fever, sore throat, breathing difficulties	Benzylpenicillin, metronidazole, clindamycin
Quast et al., 2017 [16]	18, F	Fever, headache, meningeal signs	Meropenem, metronidazole
Mellor et al., 2017 [17]	64, M	Fever, abdominal pain, diarrhea, emesis	Ertapenem
He et al., 2015 [18]	17, M	Fever, sore throat, generalized myalgia, vomiting	Meropenem, metronidazole
Murata et al., 2013 [19]	37, F	Fever, sore throat, rigors, cough, nausea	Ampicillin
Iwasaki et al., 2012 [20]	44, M	Fever, sore throat	Doripenem

At the time blood samples were collected from our patient, he had been treated with oral roxithromycin for 1 day, which could explain why only 1 out of 3 cultivation flasks were positive for FN. Thus, it is important for physicians to consider potentially on-going antibiotic treatment prior to sampling of patients when results of samples are negative. Only 1 positive cultivation flask could also be suggestive of contamination; however, the symptoms, and radiological findings were strongly indicative for LS. Table 1 contains an overview of published case reports of LS caused by FN, including symptomatology and choice of antibiotic treatment.

Another clinical challenge that could constitute a diagnostic problem is if the blood samples show other possible variants or pathogenic species instead of FN, such as staphylococcus aureus or streptococcus species. These pathogens are not included in some of the diagnostic criteria of the disease, which unfortunately could result in some patients being overlooked. Thus, it is likely that the diagnostic criteria, as they are established today, are not sensitive enough to include all patients with LS and need to be revised in order to effectively encompass all patients with LS. Finally, it is highly possible that due to the rarity of the disease, the physician has never experienced similar cases, and therefore cannot narrow down the diagnosis quickly enough.

4. Conclusion

LS is a rare disease, and often the suspicion of the disease arises only when the blood cultures become available after several days. LS should be particularly suspected in young, otherwise healthy patients with a history of prolonged oropharyngeal infection and fever, especially if there are signs of metastatic infection, which most commonly occurs in the lungs. We hope physicians take the importance of chest X-ray, ultrasound, and finally CT scan into consideration, as they can bring tremendous diagnostic value to initiating appropriate antibiotic therapy as fast as possible.

Declaration of Competing Interest

The authors declare that they have no known competing financial interests or personal relationships that could have appeared to influence the work reported in this paper.

Consent

Informed consent was obtained from our patient for publication of this case report on June 17, 2022.

Author's contribution

Witold Gloksin was responsible for obtaining optimal CT scans, as well as providing thorough description of these scans. Trine Hagen provided supervision and essential feedback throughout the process, including grammatical revision and suggestions to improve the manuscript's content.

References

- [1] Gore MR. Lemierre syndrome: a meta-analysis. *Int Arch Otorhinolaryngol* 2020;24(3):e379–85.
- [2] Sinave CP, Hardy GJ, Fardy PW. The Lemierre syndrome: suppurative thrombophlebitis of the internal jugular vein secondary to oropharyngeal infection. *Medicine* 1989;68(2):85–94.
- [3] Chirinos JA, Lichtstein DM, Garcia J, Tamariz LJ. The evolution of Lemierre syndrome: report of 2 cases and review of the literature. *Medicine* 2002;81(6):458–65.
- [4] Karkos PD, Asrani S, Karkos CD, Leong SC, Theochari EG, Alexopoulou TD, et al. Lemierre's syndrome: a systematic review. *Laryngoscope* 2009;119(8):1552–9.
- [5] Valerio L, Corsi G, Sebastian T, Barco S. Lemierre syndrome: current evidence and rationale of the bacteria-associated thrombosis, thrombophlebitis and Lemierre syndrome (BATTLE) registry. *Thromb Res* 2020;196:494–9.
- [6] Gadkowski LB, Stout JE. Cavitory pulmonary disease. *Clin Microbiol Rev* 2008;21(2):305–33.
- [7] Hadjinicolaou AV, Philippou Y. Lemierre's syndrome: a neglected disease with classical features. *Case Rep Med* 2015;2015:846715.
- [8] Ryu JH, Swensen SJ. Cystic and cavitory lung diseases: focal and diffuse. *Mayo Clin Proc* 2003;78(6):744–52.
- [9] Pennington KM, Vu A, Challener D, Rivera CG, Shweta FNU, Zeuli JD, et al. Approach to the diagnosis and treatment of non-tuberculous mycobacterial disease. *J Clin Tuberc Other Mycobact Dis* 2021;24:100244.
- [10] Panchani D, Nair D. Not always as simple as a UTI: an atypical case of Lemierre's syndrome, the forgotten disease. *Clin Med* 2021;21(6):e664–6.
- [11] Alves S, Stella L, Carvalho I, Moreira D. Lemierre's syndrome: a disguised threat. *BMJ Case Rep* 2019;12(4):e228397.
- [12] Whittle T, Ammiraghi N, Sarkar B. Lemierre's syndrome: a rare cause of sepsis presenting with an absence of throat symptoms. *BMJ Case Rep* 2018;2018:bcr2017224151.
- [13] Singh P, Adial A, Mann J, Iftikhar A. Lemierre's syndrome: cavitory lung disease caused by uncommon bacteria. *BMJ Case Rep* 2018;2018:bcr2018224713.
- [14] Vijay V, Fattah Z. Lesson of the month 1: Lemierre's syndrome: a reminder of the 'forgotten disease'. *Clin Med (Lond)* 2018;18(1):100–2.
- [15] Hedenmark J, Holm K, Moberger F, Torell E. Lemierres syndrom – en påminnelse om »den glömda sjukdomen» - God kunskap under hela vårdkedjan viktigt för att i tid väcka misstanke. *Lakartidningen* 2018;115:EWPE.
- [16] Quast DR, Lotz TA, Breuer TKG. Lemierre syndrome after tonsillectomy. *Dtsch Arztebl Int* 2017;114(40):679.
- [17] Mellor TE, Mitchell N, Logan J. Lemierre's syndrome variant of the gut. *BMJ Case Rep* 2017;2017:bcr2017221567.
- [18] He J, Lam JC, Adlan T. Clival osteomyelitis and hypoglossal nerve palsy—Rare complications of Lemierre's syndrome. *BMJ Case Rep* 2015;2015:bcr2015209777.
- [19] Murata Y, Wada M, Kawashima A, Kagawa K. Early diagnosis of Lemierre's syndrome based on a medical history and physical findings. *Intern Med* 2013;52(2):285–8.
- [20] Iwasaki T, Yamamoto T, Inoue K, Takaku K. A case of Lemierre's syndrome in association with liver abscess without any other metastatic lesions. *Intern Med* 2012;51(11):1419–23.