



Aalborg Universitet

AALBORG UNIVERSITY  
DENMARK

**Single-crown restorations supported by short implants versus standard-length implants in conjunction with maxillary sinus floor augmentation in the posterior maxilla**

*A randomized controlled trial*

Nielsen, Helle Baungaard

DOI (link to publication from Publisher):  
[10.54337/aau528211167](https://doi.org/10.54337/aau528211167)

Publication date:  
2023

Document Version  
Publisher's PDF, also known as Version of record

[Link to publication from Aalborg University](#)

*Citation for published version (APA):*  
Nielsen, H. B. (2023). *Single-crown restorations supported by short implants versus standard-length implants in conjunction with maxillary sinus floor augmentation in the posterior maxilla: A randomized controlled trial.* Aalborg Universitetsforlag. Aalborg Universitet. Det Sundhedsvidenskabelige Fakultet. Ph.D.-Serien  
<https://doi.org/10.54337/aau528211167>

**General rights**

Copyright and moral rights for the publications made accessible in the public portal are retained by the authors and/or other copyright owners and it is a condition of accessing publications that users recognise and abide by the legal requirements associated with these rights.

- Users may download and print one copy of any publication from the public portal for the purpose of private study or research.
- You may not further distribute the material or use it for any profit-making activity or commercial gain
- You may freely distribute the URL identifying the publication in the public portal -

**Take down policy**

If you believe that this document breaches copyright please contact us at [vbn@aub.aau.dk](mailto:vbn@aub.aau.dk) providing details, and we will remove access to the work immediately and investigate your claim.



**SINGLE-CROWN RESTORATIONS SUPPORTED  
BY SHORT IMPLANTS VERSUS STANDARD-  
LENGTH IMPLANTS IN CONJUNCTION WITH  
MAXILLARY SINUS FLOOR AUGMENTATION  
IN THE POSTERIOR MAXILLA**

A RANDOMIZED CONTROLLED TRIAL

**BY  
HELLE BAUNGAARD NIELSEN**

DISSERTATION SUBMITTED 2023



**AALBORG UNIVERSITY**  
DENMARK



**SINGLE-CROWN RESTORATIONS SUPPORTED BY SHORT  
IMPLANTS VERSUS STANDARD-LENGTH IMPLANTS IN  
CONJUNCTION WITH MAXILLARY SINUS FLOOR  
AUGMENTATION IN THE POSTERIOR MAXILLA**

**A RANDOMIZED CONTROLLED TRIAL**

Helle Baungaard Nielsen



**AALBORG UNIVERSITY**  
DENMARK



AALBORG UNIVERSITY HOSPITAL

PhD thesis submitted

2023

Dissertation submitted: February 2023

Main supervisor: Professor Thomas Starch-Jensen, DDS, PhD,  
Dept. of Oral and Maxillofacial Surgery and Dept. of  
Clinical Medicine, Aalborg University Hospital and  
Aalborg University, Denmark

Co-supervisor: Søren Schou, DDS, PhD, DrOdont.  
Dept. of Periodontology, School of Dentistry,  
University of Copenhagen, Denmark

PhD committee: Professor Søren Kold (chair)  
Aalborg University, Denmark

Professor Daniel S. Thoma  
University of Zurich, Switzerland

Professor Jörg Wiltfang  
University Medical Centre Schleswig-Holstein, Germany

PhD Series: Faculty of Medicine, Aalborg University

Department: Department of Clinical Medicine

ISSN (online): 2246-1302  
ISBN (online): 978-87-7573-753-6

Published by:  
Aalborg University Press  
Kroghstræde 3  
DK – 9220 Aalborg Ø  
Phone: +45 99407140  
aauf@forlag.aau.dk  
forlag.aau.dk

© Copyright: Helle Baungaard Nielsen

Printed in Denmark by Stibo Complete, 2023

## TABLE OF CONTENT

LIST OF PAPERS.....	5
ABBREVIATIONS.....	7
ENGLISH SUMMARY .....	9
DANSK RESUME.....	13
TABLES ANG FIGURES .....	17
BACKGROUND.....	19
INTRODUCTION.....	22
AIMS AND HYPOTHESES.....	27
MATERIALS AND METHODS .....	29
RESULTS .....	41
DISCUSSION .....	49
CONCLUSION .....	54
CLINICAL IMPLICATIONS AND FUTURE PERSPECTIVES .....	57
ACKNOWLEDGEMENTS .....	59
REFERENCES.....	61
APPENDIX: PAPER I-III.....	69





## LIST OF PAPERS

The present PhD thesis is based on the following three publications published in peer-reviewed journals, including one systematic review and two clinical studies. The publications will be referred to by their Roman numerals (I-III):

- I. Short implants ( $\leq 8$  mm) compared to standard length implants ( $> 8$  mm) in conjunction with maxillary sinus floor augmentation: a systematic review and meta-analysis. Nielsen HB, Schou S, Isidor F, Christensen AE, Starch-Jensen T. *Int J Oral Maxillofac Surg.* 2019;48(2):239-49.
- II. Single-crown restorations supported by short implants (6 mm) compared with standard-length implants (13 mm) in conjunction with maxillary sinus floor augmentation: a randomized, controlled clinical trial. Nielsen HB, Schou S, Bruun NH, Starch-Jensen T. *Int J Implant Dent.* 2021;7(1):66.
- III. Professional and patient-reported outcomes of two surgical approaches for implant supported single-crown restoration: 1-year results of a randomized controlled clinical trial. Nielsen HB, Schou S, Bruun NH, Starch-Jensen T. *Clin Oral Implants Res.* 2022;33(2):197-208.



## **ABBREVIATIONS**

BOP	Bleeding on probing
CI	Confidence interval
DBBM	Deproteinized bovine bone mineral
IP	Implant placement
MeSH	Medical subject heading
MSFA	Maxillary sinus floor augmentation
OHIP	Oral health impact profile
PES	Pink esthetic score
PIMBL	Peri-implant marginal bone loss
PPD	Probing pocket depth
PROMs	Patient-reported outcome measures
OHRQoL	Oral health-related quality of life
RCT	Randomized controlled trial
SCR	Single-crown restoration
SD	Standard deviation
SI	Short implant
SLI	Standard-length implant
VAS	Visual analogue scale
WES	White esthetic score



## ENGLISH SUMMARY

The present PhD thesis is based on one systematic review (Paper I) and a randomized controlled trial (RCT) assessing prosthetic rehabilitation in the posterior maxilla with fixed single-crown restorations supported by short implants (6 mm) compared with standard-length implants (13 mm) in conjunction with maxillary sinus floor augmentation (MSFA) after 1-year of functional implant loading with focus on clinical and radiographic parameters (Paper II). In addition, professional and patient-reported outcome measures (PROMs) (Paper III) were assessed after 1-year of functional implant loading.

Prosthetic rehabilitation of the partially edentulous posterior maxilla with an implant-supported fixed prosthesis is frequently compromised due to atrophy of the alveolar process or pneumatization of the maxillary sinus following loss of teeth. Therefore, vertical alveolar ridge augmentation is frequently necessary before or in conjunction with placement of implants. MSFA applying the lateral window technique is the most commonly applied surgical procedure to increase the vertical alveolar ridge height of the posterior maxilla prior to or in conjunction with placement of implants. Autogenous bone grafts are generally considered as the preferred grafting material for MSFA due to its osteoinductive, osteogenic, and osteoconductive characteristics. However, harvesting of autogenous bone grafts is associated with a supplementary surgical procedure, risk of donor site morbidity, and unpredictable resorption of the grafting material. Placement of short implants have therefore been advocated as an alternative treatment modality to simplify the surgical procedure and eliminate the need for harvesting of an autogenous bone graft.

The purpose of Paper I was to test the hypothesis of no difference in treatment outcome after prosthetic rehabilitation of the posterior maxilla with fixed single-crowns supported by short implants ( $\leq 8$  mm) compared with standard-length implants ( $> 8$  mm) in conjunction with MSFA using the lateral window technique after an observation period of  $\geq 3$  years in a systematic review. Three RCTs fulfilled the inclusion criteria. Both treatment modalities revealed high survival rates of suprastructures and implants as well as limited peri-implant marginal bone loss (PIMBL) after  $\geq 3$  years of functional implant loading. Descriptive statistics and meta-analyses revealed no significant differences in implant survival and PIMBL between the two

treatment modalities. However, standard-length implants in conjunction with MSFA were characterized by a tendency to increased PIMBL. There was no statistically significant difference in the overall patient satisfaction between the two treatment modalities. The hypothesis of no difference in the implant treatment outcome could therefore not be rejected. Nevertheless, placement of short implants in the posterior maxilla seems to be a suitable alternative for prosthetic rehabilitation of the partial edentulous posterior maxilla compared with placement of standard-length implants in conjunction with MSFA. However, conclusions drawn from the present systematic review should be interpreted with caution due to few RCTs involving small patient samples and limited follow-up periods.

The purpose of Paper II was to test the hypothesis of no difference in implant treatment outcome following prosthetic rehabilitation with fixed single-crown restorations supported by short implants (6 mm) compared with standard-length implants (13 mm) in conjunction with MSFA after 1-year of functional implant loading. Forty patients with partial edentulism in the posterior maxilla were randomly allocated to short implant or standard-length implant in conjunction with MSFA using 50% particulated autogenous bone graft from the ascending mandibular ramus mixed with 50% deproteinized bovine bone mineral (DBBM) (Bio-Oss®). The clinical and radiographic examination included assessment of the residual alveolar bone height, plaque score, bleeding on probing (BOP), and probing pocket depth (PPD) at the implant site and the adjacent teeth. PIMBL was assessed by periapical radiographs.

The survival of suprastructures and implants was 100% for both treatment modalities after 1-year of functional implant loading. There was no significant difference in PIMBL, clinical parameters of inflammation and mechanical complications between the two treatment modalities at any time-point ( $P > 0.05$ ). However, placement of standard-length implants in conjunction with MSFA was associated with a higher incidence of biological complications.

The hypothesis of no difference in professional evaluation and PROMs after prosthetic rehabilitation with fixed single-crown restorations supported by short implants (6 mm) compared with standard-length implants (13 mm) in conjunction with MSFA after 1-year of functional implant loading was addressed in Paper III. PROMs were assessed using Oral Health Impact Profile (OHIP-14) and validated

self-administrated questionnaire assessing the peri-implant soft tissues, implant crown, implant function, and overall implant treatment outcome using a visual analogue scale (VAS). Professional evaluation included Pink Esthetic Score (PES) and White Esthetic Score (WES). No significant differences in professional evaluation or PROMs were revealed at any time point between the two treatment modalities ( $P > 0.05$ ). OHIP-14 score decreased at baseline and 1-year after functional implant loading compared with the preoperative assessment indicating improved oral health-related quality of life (OHRQoL) with both treatment modalities. It was therefore concluded that professional evaluation and PROM following prosthetic rehabilitation in the posterior maxilla with fixed single-crown restorations supported by short implants seems to be comparable with placement of standard-length implants in conjunction with MSFA after 1-year of functional implant loading.

The conclusions of the present PhD thesis indicate that prosthetic rehabilitation of the posterior maxilla with fixed single-crown restorations supported by short implants seems to be suitable treatment alternative compared with placement of standard-length implants in conjunction with MSFA after 1-year of functional implant loading. However, further long-term RCTs involving larger patient samples, assessment of donor site morbidity, and economic perspectives are needed before definite evidence-based clinical implications can be provided for prosthetic rehabilitation of the posterior maxilla with fixed single-crown restorations.





## DANSK RESUME

Nærværende ph.d.-afhandling er baseret på en systematisk oversigtsartikel (Artikel I) samt en randomiseret kontrolleret undersøgelse (RCT) efter protetisk rehabilitering af den posteriore maksil med enkeltandskroner understøttet af korte implantater sammenlignet med indsættelse af standardlængde implantater i kombination med sinusløftproceduren efter 1-års funktionel belastning (Artikel II). Endvidere belyses patienttilfredshed og tandlægelig tilfredshed (professionel tilfredshed) med de to behandlingsmodaliteter efter 1-års funktionel belastning (Artikel III).

Protetisk rehabilitering af den partielle tandløse posteriore maksil med implantat-understøttet fastsiddende protetik er ofte vanskelig eller umulig som følge af svind af alveolarkammen og pneumatisering af sinus maxillaris efter tandtab. Vertikal knoglegenopbygning af alveolarkammen er derfor ofte nødvendig enten forud for eller i forbindelse med implantatindsættelsen.

Sinusløftproceduren ved hjælp af lateral vindueteknik og anvendelse af et partikulært autologt knogletransplantat og/eller et knogleerstatningsmateriale er den hyppigst anvendte kirurgiske metode til at øge alveolarkammens vertikale højde i den posteriore maksil. Imidlertid er udtagning af autologt knogletransplantat associeret med en supplerende kirurgisk procedure, risiko for morbiditet svarende til donorstedet og en uforudsigelig resorption af transplantationsmaterialet. Indsættelse af korte implantater har derfor været foreslået som et behandlingsalternativ til protetisk rehabilitering af den partielle tandløse posteriore maksil med henblik på at simplificere den kirurgiske procedure og eliminere behovet for anvendelsen af et autologt knogletransplantat.

Artikel I havde til formål at teste hypotesen om ingen forskel i behandlingsresultatet efter protetisk rehabilitering af den posteriore maksil med enkeltandskroner understøttet af korte implantater ( $\leq 8$  mm) sammenlignet med standardlængde implantater ( $\leq 8$  mm) i kombination med sinusløftproceduren ved hjælp af lateral vindueteknik efter en observationsperiode på  $\geq 3$  år i en systematisk oversigtsartikel. Tre RCTs opfyldte inklusionskriterierne. Begge behandlingsmodaliteter viste høj overlevelse af implantater og suprastrukturer samt begrænset peri-implantært marginalt knogletab efter  $\geq 3$  års funktionel implantatbelastning. Deskriptiv statistik og meta-analyse viste ingen signifikant

forskel i implantatoverlevelse og peri-implantært marginalt knogletab mellem de to behandlingsmodaliteter. Imidlertid var standardlængde implantater i kombination med sinusløftproceduren karakteriseret ved en øget tendens til peri-implantært marginalt knogletab. Der var ingen statistisk signifikant forskel i den overordnede patienttilfredshed mellem de to behandlingsmodaliteter. Hypotesen om ingen forskel i behandlingsresultatet kunne derfor ikke forkastes. Imidlertid blev indsættelse af korte implantater anset som et egnet behandlingsalternativ til protetisk rehabilitering af den partielle tandløse posteriore maksil sammenlignet med indsættelse af standardlængde implantater i kombination med sinusløftproceduren. Konklusionerne fra denne systematiske oversigtsartikel bør fortolkes med forsigtighed grundet få RCTs med et begrænset patientantal.

Artikel II havde til formål at teste hypotesen om ingen forskel efter implantatbehandling og protetisk rehabilitering med enkeltandskroner understøttet af korte implantater (6 mm) sammenlignet med indsættelse af standardlængde implantater (13 mm) i kombination med sinusløftproceduren efter 1-års funktionel implantatbelastning. I alt blev 40 patienter med partiel tandløshed i den posteriore maksil randomiseret til kort implantat eller et standardlængde implantat i kombination med sinusløftproceduren og en blanding af 50% partikuleret autolog knogle fra ramus mandibulae og 50% deproteiniseret knogleerstatningsmateriale (DBBM) (Bio-Oss®). Den præoperative kliniske og radiologiske undersøgelse inkluderede måling af alveolarkammens residualhøjde, plak score, blødning ved sondering og pochemåling samt måling af alveolarkammens residualhøjde. Periapikal røntgenoptagelse blev foretaget med henblik på vurdering af det marginale knogleniveau. Overlevelsen af suprastrukturer og implantater var 100% for korte implantater og standardlængde implantater i kombination med sinusløftproceduren efter 1-års funktionel implantatbelastning. Der var ingen signifikant forskel i det peri-implantære marginale knogletab, kliniske inflammatoriske parametre og mekaniske komplikationer mellem de to behandlingsmodaliteter på evalueringstidspunkterne ( $P > 0.05$ ). Imidlertid var indsættelse af standardlængde implantater i kombination med sinusløftproceduren forbundet med en øget forekomst af biologiske komplikationer.

Artikel III havde til formål at teste hypotesen om ingen forskel i professionel (tandlægefaglig) og patient-relateret vurdering af behandlingsresultatet efter protetisk rehabilitering med enkelttandskrone understøttet af kort implantat (6 mm)

sammenlignet med standardlængde implantat (13 mm) i kombination med sinusløftproceduren efter 1-års funktionel implantatbelastning. Patient-relateret evaluering involverede OHIP-14 samt et valideret spørgeskema til vurdering af det peri-implantære væv, implantatkronen, implantatfunktion og det overordnede behandlingsresultat ved hjælp af visuel analog skala (VAS). Professionel evaluering inkluderede Pink Esthetic Score (PES) og White Esthetic Score (WES). Der var ingen signifikant forskel i professionel eller patient-relateret vurdering af behandlingsresultatet mellem behandlingsmodaliteterne på evalueringstidspunkterne ( $P > 0.05$ ). OHIP-14 score faldt ved baseline og efter 1-års funktionel implantatbelastning sammenlignet med præoperative målinger, hvilket indikerede en bedring i OHRQoL for begge behandlingsmodaliteter. Det blev derfor konkluderet, at professional og patient-relateret vurdering af behandlingsresultatet efter protetisk rehabilitering af den posteriore maksil med enkelttandskroner understøttet af korte implantater var sammenlignelig med indsættelse af standardlængde implantater i kombination med sinusløftproceduren efter 1-års funktionel implantatbelastning.

Konklusionerne fra nærværende ph.d.-afhandling indikerer, at protetisk rehabilitering af den posteriore maksil med enkelttandskroner understøttet af korte implantater synes at være sammenlignelig med indsættelse af standardlængde implantater i kombination med sinusløftproceduren efter 1-års funktionel implantatbelastning. Imidlertid er der behov for flere RCTs med større patientantal, vurdering af patientubehag og morbiditet svarende til donorstedet samt økonomiske aspekter før evidensbaserede kliniske retningslinjer for protetisk rehabilitering af den posteriore maksil med enkelttandskroner understøttet af korte implantater eller standardlængde implantater i kombination med sinusløftproceduren kan anbefales.



## TABLES AND FIGURES

### Tables:

- Table 1: Inclusion and exclusion criteria for enrolment, paper I.
- Table 2: PICOS guidelines, paper I.
- Table 3: Inclusion and exclusion criteria for enrolment, paper II and III.
- Table 4: Outcome measures and time schedule, paper II and III.
- Table 5: Peri-implant marginal bone loss over a 1-year period, paper II.
- Table 6: Clinical parameters of mucosal inflammation over a 1-year period, paper II.
- Table 7: Biological and mechanical complications over a 1-year period, paper II.
- Table 8: Subjective evaluation of treatment outcome using VAS questionnaire, paper III.
- Table 9: Professional evaluation of implant treatment outcome using PES and WES, paper III.

### Figures:

- Figure 1: Placement of a short implant in the posterior maxilla.
- Figure 2: Placement of a standard-length implant in conjunction with MSFA in the posterior maxilla.
- Figure 3: Clinical photos of the screw-retained single-crown restoration in the maxillary second molar region.
- Figure 4: PRISMA flow diagram demonstrating the results of the systematic literature search, paper I.
- Figure 5: Meta-analysis for patient-based implant loss using Petos method with continuity correction of 0.5, paper I.
- Figure 6: Meta-analysis for PIMBL using a fixed effects model with inverse variance, paper I.



## **BACKGROUND**

Alveolar ridge augmentation is often necessary before or in conjunction with implant placement in the posterior maxilla. MSFA using the lateral window technique is the most commonly used method to increase the alveolar bone height of the posterior maxilla, and high prosthesis and implant survival have been reported in several systematic reviews and meta-analyses (1–6). Autogenous bone is considered the preferred grafting material, either alone or in combination with a bone substitute, due to its osteoinductive, osteogenic, and osteoconductive characteristics (7). However, the use of autogenous bone grafts is associated with a supplementary surgical procedure and risk of donor site morbidity. Moreover, unpredictable graft resorption has previously been reported following alveolar ridge augmentation with the use of an autogenous bone graft (3,8,9). Bone substitutes of biologic or synthetic origin are therefore commonly used alone or in combination with diminutive quantities of autogenous bone graft to simplify the surgical procedure by diminishing the need for extensive bone harvesting (10,11,12). However, the use of bone substitutes is associated with extra costs and provide only osteoconductive properties. Moreover, bone substitutes of biologic origin involve a risk of contamination, activation of host immune system, and disease transmission. Moreover, they can be refused by some patients for various reasons.

Prosthetic rehabilitation in the posterior maxilla with a fixed prosthetic solution supported by short implants have therefore been used increasingly during the last decades to simplify the surgical procedure and eliminate the need for bone harvesting or the use of biomaterials (6,13–15). However, comparable long-term RCTs assessing prosthetic rehabilitation of the posterior maxilla with short implants compared with standard-length implants in conjunction with MSFA is limited (16,17). Recent RCTs have demonstrated comparable implant treatment outcome as reported in several systematic reviews and meta-analyses (18-24). However, a successful clinical and radiographic treatment outcome do not necessarily reflect the patient's satisfaction with the surgical intervention as well as the esthetics or function of the final implant-supported restoration. Therefore, assessment of professional assessment and PROMs should supplement the clinical and radiographic evaluation. Consequently, further long-term RCTs are needed including assessment of clinical and radiographic parameters as well as donor site morbidity, professional assessment involving PES, WES and PROMs

before definite conclusions can be provided about prosthetic rehabilitation of the posterior maxilla with short implants compared with standard-length implants in conjunction with MSFA.





## **INTRODUCTION**

### **THE MAXILLARY SINUS**

The pyramid-shaped maxillary sinus is the largest of the paranasal sinuses and drains into the middle meatus of the nose through the osteomeatal complex (25). The maxillary sinus contains three recesses: 1) A zygomatic recess pointed laterally, bounded by the zygomatic bone, 2) An infraorbital recess pointed superiorly, bounded by the inferior orbital surface of the maxilla, and 3) An alveolar recess pointed inferiorly, bounded by the alveolar process of the maxilla with the roots of the premolars and molars having a close anatomical relationship to the maxillary sinus (26). The maxillary sinus is lined throughout its extent of a thin mucous membrane referred to as the Schneiderian membrane which consists of cilia-covered respiratory tract epithelium with mucous and serous glands (27). Bony septa occur relatively frequent in the maxilla, predominantly within the anterior part of the maxillary sinus. Bony septa can be partial or complete dividing the lower part of the maxillary sinus into several accessory sinus apartments (28,29).

### **ATROPHY OF THE ALVEOLAR RIDGE FOLLOWING CONGENITALLY MISSING TEETH OR LOSS OF TEETH IN THE POSTERIOR MAXILLA**

The alveolar process is a tooth-dependent tissue and the shape as well as the volume of the alveolar process is influenced by tooth form and eruption (30,31), including tooth presence or absence (32). Tooth extraction is a commonly performed dental procedures and post-extraction healing of the hard and soft tissues proceed in most cases uneventful. However, tooth removal is in most cases associated with subsequent alveolar bone loss (33) as well as structural and compositional changes of the overlying soft tissues (34). Previous studies have demonstrated pronounced dimensional changes of the alveolar ridge within the first 2-3 months post-extraction, predominantly related to the buccal aspect (35). The process of ridge remodelling is further complicated if the buccal wall is lost due to extraction or an inflammatory process (33). The dimensional alterations of the alveolar hard and soft tissues can be quite extensive, and the magnitude of these dimensional changes are important factors to consider in the

comprehensive treatment planning during prosthetic rehabilitation (33). In addition, with the greater emphasis on esthetics in the last decades, a thorough understanding of the resorptive pattern and bone alterations post-extraction would enhance the ability to obtain optimal function combined with satisfactory esthetics (33). Adequate height and width of the alveolar ridge is therefore a prerequisite for placement of implants with a sufficient length and diameter corresponding to the tooth which need to be replaced. Severe atrophy of the alveolar ridge following loss of teeth consequently compromises oral rehabilitation with implants (6). Alveolar ridge augmentation prior to or in combination with implant placement is therefore frequently necessary when dimensions of the alveolar process are inadequate.

### **STANDARD-LENGTH IMPLANTS IN CONJUNCTION WITH MSFA VERSUS SHORT IMPLANTS IN THE POSTERIOR MAXILLA**

Congenitally missing teeth or loss of teeth might have a highly negative impact of function and esthetics causing disability, decreased self-esteem and a reduced OHRQoL. Replacing missing teeth with an implant-supported fixed dental prostheses is considered a predictable treatment option with high survival of suprastructures and implants (4,36). Moreover, prosthetic rehabilitation with implants have demonstrated improved masticatory function and OHRQoL. Congenital missing teeth or tooth loss in the posterior maxilla is associated with pneumatization of the maxillary sinus and gradually alveolar ridge resorption causing larger proximity to the maxillary sinus, which compromise placement of standard-length implants without alveolar ridge augmentation (37). MSFA applying the lateral window technique is the traditionally used surgical procedure to increase the alveolar bone height in the posterior maxilla (38). Placement of standard-length implants in conjunction with MSFA have demonstrated high survival rate of suprastructures and implants, limited PIMBL and high patient satisfaction (39,40). However, MSFA is associated with risks of sinusitis, postsurgical discomfort and sick leave, increased cost and an extensive surgical intervention compared with placement of implants without alveolar ridge augmentation. Consequently, prosthetic rehabilitation in the posterior maxilla using short implant is therefore often used to diminish morbidity and improve patient satisfaction with the surgical intervention.

The necessary implant length and diameter to support a fixed prosthetic solution in the posterior maxilla is presently unknown. However, recent long-term studies have demonstrated high survival of suprastructures and implants, limited PIMBL and few complications following prosthetic rehabilitation in the posterior maxilla with the use of 6 mm implants (16,17). Consequently, the necessary implant length to support a fixed prosthetic solution in the posterior maxilla is controversial and the definition of a short implant is debatable.

There is no consensus in the literature concerning classification of dental implants as standard/long, short, or ultrashort. However, implants with an intra-bony length varying between 6 mm and 8 mm is generally considered as a short implant (41). The 4<sup>th</sup> European Association for Osseointegration (EAO) consensus conference in 2015 evaluated prosthetic rehabilitation in the posterior maxilla with short implants ( $\leq 8$  mm) compared with placement of standard-length implants ( $> 8$  mm) in conjunction with MSFA. Both treatment modalities revealed high implant survival after 16-18 months. Consequently, placement of short implants ( $\leq 8$  mm) was considered as a worthy treatment alternative to standard length implants in conjunction with MSFA, due to a higher frequency of biological complications, increased morbidity, costs, and surgical time following MSFA (36). The conclusions of the EAO consensus conference are in accordance with newly published systematic reviews and meta-analyses assessing prosthetic rehabilitation in the posterior maxilla with short implants and standard-length implants in conjunction with MSFA (42,43). Moreover, newly published long-term RCT have assessed implant treatment outcome following prosthetic rehabilitation with fixed single crowns supported by short implants (6 mm) compared with standard-length implants (11 mm) in the posterior maxilla revealing high survival rate of suprastructures and implants, limited PIMBL and few complications with both treatment modalities after 5-years of implant loading (16,17). However, placement of short implants was more prone for mechanical complications within the first years (16). PROMs and patient satisfaction were assessed by OHIP-14 (16) and a questionnaire assessing feelings, function, and overall patient satisfaction (17). High patient satisfaction was reported with both treatment modalities after 5-years of functional implant loading (16,17). However, professional assessment of the prosthetic solution was not conducted (16,17).

The influence of crown-to-implant ratio on implant survival have been assessed in several systematic reviews and meta-analyses revealing conflicting results (41,44-47).

However, it has been concluded in long-term studies and systematic reviews that an increased crown-to-implant ratio does not appear to be related with increased risk of implant loss, PIMBL, or mechanical complications (45-51). Moreover, it was concluded in a newly published systematic review assessing short implants in the posterior maxilla that a higher crown-to-implant ratio was not associated with increased risk of implant loss and PIMBL (51,52). However, the long-term influence of a higher crown-to-implant ratio on biological and mechanical complications remain unknown (16).

In summary, prosthetic rehabilitation in the posterior maxilla with short implants compared with standard-length implants in conjunction with MSFA have been assessed in systematic reviews and few long-term RCT revealing comparable survival of suprastructures and implants, PIMBL, frequency of complications as well as PROMs. However, the necessary implant length to support a fixed implant-supported prostheses in the posterior maxilla remains unknown and the long-term influence of an increased crown to-implant ratio on PIMBL needs further investigation. PROMs have solely been assessed in few studies, whereas professional assessment of the final prosthetic solution has never been conducted. Consequently, further long-term RCT assessing clinical and radiographic measurements as well as professional and PROMs are needed before definite conclusions can be provided about prosthetic rehabilitation of the posterior maxilla with the use of short implants compared with standard-length implants in conjunction with MSFA.



## **AIMS AND HYPOTHESES**

The aims of the present PhD thesis were to increase our knowledge about prosthetic rehabilitation of the partially edentulous posterior maxilla with fixed single-crown restorations supported by short implants or standard-length implants in conjunction with MSFA. The specific aims were to test the H0 hypothesis of:

- No differences in clinical and radiographic implant treatment outcome following prosthetic rehabilitation of the partially edentulous posterior maxilla with fixed single-crown restorations in the posterior maxilla supported by short implants or standard-length implants in conjunction with MSFA.
- No differences in professional and PROMs following prosthetic rehabilitation of the partially edentulous posterior maxilla with fixed single-crown restorations in the posterior maxilla supported by short implants or standard-length implants in conjunction with MSFA.





## **MATERIALS AND METHODS**

### **Paper I**

Paper I is a comprehensive systematic review assessing implant treatment outcome following prosthetic rehabilitation of the posterior maxilla with fixed single-crown restorations supported by short implants ( $\leq 8$  mm) compared with standard-length implants ( $> 8$  mm) in conjunction with MSFA using the lateral window technique after an observation period of  $\geq 3$  years. The systematic review was conducted in accordance with PRISMA guidelines and included RCT in humans (53).

Following outcome measures were included:

#### *Primary outcome measures:*

- Survival of suprastructures. Loss of suprastructure was defined as a total loss because of a mechanical and/or a biological complication.
- Survival of implants. Loss of implant was defined as mobility of a previously clinically osseointegrated implant or removal of a non-mobile implant due to progressive PIMBL or infection.

#### *Secondary outcome measures:*

- PIMBL. Evaluated by radiographic measurements.
- Implant stability quotient (ISQ). Estimated by resonance frequency analysis.
- PROMs.
- Complications.

Inclusion and exclusion criteria:

Inclusion criteria:	Exclusion criteria:
<ul style="list-style-type: none"> <li>• RCT with an observation period of <math>\geq 3</math> years assessing the implant treatment outcome after installation of short implants (<math>\leq 8</math> mm) in the posterior part of the maxilla compared to standard length implants (<math>&gt; 8</math> mm) in conjunction with MSFA using the lateral window technique.</li> <li>• A minimum of 10 patients in each treatment group and the number of inserted implants and the used surgical intervention had to be clearly specified.</li> </ul>	<ul style="list-style-type: none"> <li>• Uncontrolled clinical trials, case series, retrospective studies, letters to the editor, editorials, PhD theses, case reports, abstracts, technical reports, conference proceedings, animal or in vitro studies and review papers.</li> <li>• Studies with insufficient description of the performed numbers of surgical procedures, inserted implants, length of inserted implants, length of observation period, and studies involving osteotome-mediated MSFA in conjunction with implant installation.</li> <li>• Studies adding growth factors or platelet rich plasma to the graft materials.</li> </ul>

Table 1. Inclusion and exclusion criteria for enrolment in paper I.

Inclusion criteria and focused question were developed using PICOS Guidelines:

PICOS guidelines	
Patient and population (P)	Healthy patients with atrophy of the posterior maxilla receiving short implants or standard-length implants in conjunction with MSFA.
Intervention (I)	Short implants.
Comparator or control group (C)	Standard-length implants in conjunction with MSFA.
Outcomes (O)	The primary outcome measures included survival of suprastructures and survival of implants. Secondary outcome measures included PIMBL, implant stability quotient, PROM, and complications.
Study design (S)	RCT with the aim of comparing short implants with standard-length implants in conjunction with MSFA with an observation period of $\geq 3$ years.
Focused question	Are there differences in the long-term final implant treatment outcome between the two treatment modalities involving short implants compared with standard-length implants in conjunction with MSFA with an observation period of $\geq 3$ years.

Table 2. PICOS guidelines in paper I.

*Search strategy:*

The search strategy was conducted in Medline, Embase, and Cochrane Library including studies published in English from January 1, 1990 to June 1, 2017. The search strategy was performed in collaboration with a librarian and utilized a combination of both controlled vocabulary terms and free text terms (53).

## Paper II

Study II was a RCT assessing the implant treatment outcome with focus on clinical and radiological parameters following prosthetic rehabilitation of the partially edentulous posterior maxilla with fixed single-crown restorations supported by short implants (6 mm) compared with standard-length implants (13 mm) in conjunction with MSFA after 1-year of functional implant loading (51).

The study was conducted at the Department of Oral and Maxillofacial Surgery, Aalborg University Hospital, Denmark. Patients were recruited by public invitation through Facebook or admitted to the Department of Oral and Maxillofacial Surgery, Aalborg University Hospital, Denmark for implant placement in the posterior part of the maxilla, and consecutively enrolled between November 2016 and May 2018 (51).

*Outcome measures:*

- Survival of superstructures and implants.
- PIMBL.
- Clinical parameters of mucosal inflammation.
- Biological and mechanical complications.

Inclusion and exclusion criteria:

Inclusion criteria:	Exclusion criteria:
<ul style="list-style-type: none"> <li>• Systemically healthy patients of <math>\geq 20</math> years of age.</li> <li>• Need of one implant in the posterior part of the maxilla.</li> <li>• Sufficient buccolingual bone width (<math>\geq 8</math> mm).</li> <li>• Missing posterior tooth in the maxilla for at least four months.</li> <li>• Residual alveolar bone height of a least 5.5 mm and less than 8 mm.</li> <li>• Sufficient mesial-distal dimension (7-9 mm).</li> <li>• Presence of 7-10 mm of occlusal-gingival space to the opposing occluding dentition.</li> <li>• Presence of occluding mandibular teeth.</li> <li>• Able to understand and sign an informed consent form.</li> </ul>	<ul style="list-style-type: none"> <li>• General contraindications to implant surgery.</li> <li>• Poor oral hygiene and motivation.</li> <li>• Progressive periodontitis.</li> <li>• Acute infection in the area intended for implant placement.</li> <li>• Parafunctional habits (Bruxism and/or clenching).</li> <li>• Psychiatric problems or unrealistic expectations.</li> <li>• Pregnancy.</li> <li>• Heavy tobacco use (&gt;10 cigarettes per day).</li> <li>• Substance abuse.</li> </ul>

*Table 3. Inclusion and exclusion criteria for enrolment in paper II and III.*

### **Paper III**

Study III was a RCT assessing professional and PROM after prosthetic rehabilitation of the posterior maxilla with fixed single-crown restorations supported by short implants (6 mm) compared with standard-length implants (13 mm) in conjunction with MSFA after 1-year of functional implant loading (54).

The study was conducted at the Department of Oral and Maxillofacial Surgery, Aalborg University Hospital, Denmark. Patients were recruited by public invitation

through Facebook or admitted to the Department of Oral and Maxillofacial Surgery, Aalborg University Hospital, Denmark for implant placement in the posterior part of the maxilla, and consecutively enrolled between November 2016 and May 2018 (54).

*Outcome measures:*

- PROMs as evaluated by OHIP-14 and self-administrated questionnaires.
- Professional evaluation using PES and WES.

**Paper II and III**

Forty patients with partial edentulism in the posterior maxilla were randomly allocated to prosthetic rehabilitation involving a fixed single-crown restoration supported by a short implant (6 mm) (Astra Tech Implant System Osseospeed EV 4.2; Dentsply Sirona Implants, Mölndal, Sweden) (test) or a standard-length implant (13 mm) (Astra Tech Implant System Osseospeed EV 4.2; Dentsply Sirona Implants, Mölndal, Sweden) (control) in conjunction with MSFA using 50% particulated autogenous mandibular bone graft from the ascending mandibular ramus mixed with 50% DBBM (Bio-Oss® particle size 1-2 mm, Geistlich Pharma AG, Wolhusen, Switzerland) (51,54).

*Randomization:*

An independent block randomization schedule was generated in blocks of four and designed to ensure a balanced distribution of treatments. The randomized treatment code was available in closed identical non-transparent sealed envelopes, and the patients were randomly assigned to the test or control group by pulling an envelope one week before surgery (51,54). Patients were informed about their allocation group. Therefore, blinding was not applicable (51,54).

## **ETHICAL CONSIDERATION**

Approval to conduct the RCT was obtained from the Research Ethics Committee and the Danish Data Protection Agency. The studies were performed in accordance with the Declaration of Helsinki and Consolidated Standards of Reporting Trials (CONSORT) statement.

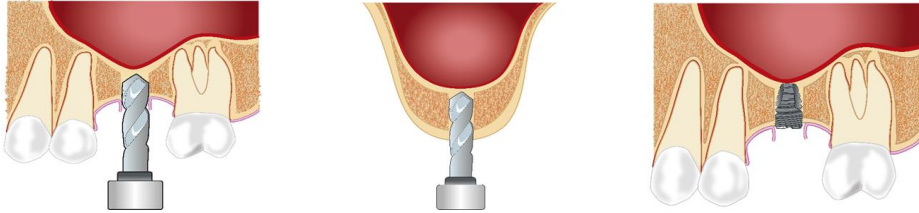
Potential candidates were given verbal and written information at a clinical visit prior to the surgical procedure. Written informed consent was obtained from every patient before enrolment. Participation was voluntary and the patients could at any giventime withdraw from the study. Confidentiality of information and anonymity of all patients were respected. Authors and health personnel involved in the study disclosed any financial or personal relationship with people or organizations that could inappropriately influence their work. The studies did not expose patients to additional risks compared with the standard procedure (51,54).

## **SURGICAL PROCEDURE**

### **Paper II and III**

#### *Short implants*

A 6 mm short implant (Astra Tech Implant System Osseospeed EV 4.2; Dentsply Sirona Implants, Mölndal, Sweden) with a cover screw was inserted in local anesthesia using Lidocaine (2%) with 1:200,000 adrenaline (Xylocaine, Amgros I/S, Denmark). An implant bed was successively prepared using standard implant protocol at 1.200 rpm with saline irrigation according to manufacturer´s recommendations. The sutures were removed 7-10 days after surgery. No provisional restoration was allowed during the healing period (51,54).



*Fig. 1. Placement of a short implant in the posterior maxilla.*

### *Standard-length implants in conjunction with MSFA*

A 13 mm standard-length implant (Astra Tech Implant System Osseospeed EV 4.2; Dentsply Sirona Implants, Mölndal, Sweden) in conjunction with MSFA was inserted in local anaesthesia using Lidocaine (2%) with 1:200,000 adrenaline. As an option, oral sedation (Apozepam, 5-10 mg, Teva, Denmark) or general anaesthesia with nasotracheal intubation was used (53). A 1 x 1 cm window to the maxillary sinus was created with metal and diamond burs. The Schneiderian membrane was carefully elevated from the maxillary sinus floor as well as the lateral sinus wall creating a compartment for placement of the grafting material. An implant bed was successively prepared following the manufacturer's recommendations at 1.200 rpm and the 13 mm implant with cover screw was inserted (51,54).

A 3 x 2 x 0.5 cm predominantly cortical bone graft was harvested from the outer cortex of the ascending mandibular ramus. The autogenous bone graft was milled using a bone-mill (Roswitha Quéting Dentalprodukte, Germany) with 3-mm perforations to obtain bone graft particles with a size of 0.5-2 mm<sup>3</sup>. The created cavity in the maxillary sinus around the inserted implant was loosely packed with an equal distribution of autogenous bone graft and DBBM (Bio-Oss®). The created window to the maxillary sinus was covered by a resorbable collagen barrier membrane (25 x 25 mm, Bio-Gide, Geistlich Pharma AG, Wolhusen, Switzerland) before suturing. The sutures were removed 7-10 days after surgery. No provisional restoration was allowed during the healing period (51,54).

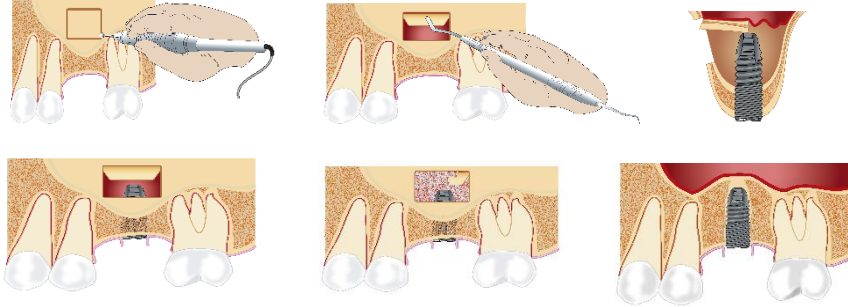


Fig. 2. Placement of a standard-length implant in conjunction with MSFA.

### *Healing abutment connection*

Healing abutment connection was performed in local anaesthesia using Lidocaine (2%) with 1:200,000 adrenaline six months after implant placement. The sutures were removed after 7-10 days, and the prosthetic restoration was initiated three weeks after healing abutment connection (51,54).

### *Prosthetic restoration*

Prosthetic rehabilitation included an individualized abutment (Atlantis, Dentsply Sirona Implants, Mölndal, Sweden) and a screw-retained single-crown restoration. Occlusal surfaces, protrusion, and laterotrusion were adjusted in slight contact with the opposite dentition. The patients were enrolled in an oral hygiene maintenance program with recall visits every six months. A meticulous control of occlusion and articulation was performed involving evaluation of protrusion and laterotrusion. Moreover, maintenance care was provided. All prosthetic restorations and maintenance were performed in private practice by Dr. Connie Blauenfeldt, Aalborg Tandplejeteam, Aalborg, Denmark (51,54).

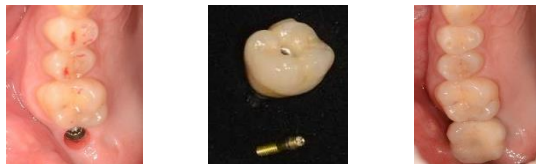

Fig. 3. Clinical photos of the screw-retained single-crown restoration in the maxillary second molar region.

## **OUTCOME MEASURES**

### **Paper II and III**

Clinical examination was performed at baseline (after placement of the definitive crown) and after 1-year of functional implant loading. Survival of suprastructure and implant, PIMBL, plaque score, BOP, PPD, biological complications, and mechanical complications were recorded at each visit (51). Professional assessment of the esthetic implant treatment outcome was evaluated using PES and WES (54). Digital clinical photos of the treated implant region including the anterior premolar or molar were taken at baseline and after 1-year of functional implant loading using Canon EOS 10D with a MR-14EX Macro Ring Lite and EF 100 mm 1:2.8 USM Macro Lens (Canon, Tokyo, Japan). Photos of the implant crown and the peri-implant tissues were taken using two projections, one facial projection perpendicular to the facial implant crown and one occlusal projection (54).

PES includes 7 different variables: mesial papilla, distal papilla, soft-tissue level, soft-tissue contour, alveolar process deficiency, soft-tissue colour, and texture. Each variable was assessed with a 0, 1, or 2 score, with 0 being the poorest score and 2 the best according to the degree of match or mismatch compared with the anterior premolar or molar (54). The highest possible PES was 14. WES includes five different variables: Crown form, volume, colour, translucency, and texture. Each variable was assessed with a 0, 1, or 2 score, with 0 being the poorest score and 2 the best according to the degree of match or mismatch compared with the anterior premolar or molar (54). The highest possible WES was 10. The association between the esthetic treatment outcome was assessed by professionals (PES and WES) and PROMs (VAS analysis) at baseline and after 1-year of functional implant loading. PROMs were evaluated using a standard Danish translated version of OHIP-14 questionnaire (54). Detailed instructions for completing the OHIP-14 were given to the patients before they completed the questionnaire by themselves, to prevent being influenced by the surgeon or nurses' opinions and wills. OHIP-14 was filled in at enrolment, baseline, and after 1-year of functional implant loading (54). Response format of OHIP-14 was as follows: All the time: 4, Very often: 3, Fairly often: 2, Sometimes: 1, Never: 0. OHIP-14 scale ranged from 0 to 56, with higher scores indicating poorer QoL. OHIP-



14 is divided into seven areas of investigation according to the type of question: Q1-Q2 (Functional limitation), Q3-Q4 (Physical pain), Q5-Q6 (Psychological discomfort), Q7-Q8 (Physical disability), Q9-Q10 (Psychological disability), Q11-Q12 (Social disability), Q13-Q14 (Handicap). In each patient, QoL was defined by estimating the OHIP-14 summary score (54).

A self-administrated questionnaire involving VAS was used to assess patient satisfaction with the peri-implant soft tissues, implant crown, implant function, and overall implant treatment at baseline and after 1-year of functional implant loading (54). Each question was scored on a 100 mm VAS with 0 indicating extreme dissatisfaction and 100 indicating complete satisfaction. The VAS scores were measured to the nearest mm by a ruler (54). Outcome measures and time plan are outlined in Table 4:

	T0	T1	T2	T3
	Before surgery	7 days postoperative	Baseline	One year
Survival of suprastructure and implant		x	x	x
PIMBL		x	x	x
Plaque score	x	x	x	x
BOP	x	x	x	x
PPD	x	x	x	x
Mechanical and biological complications		x	x	x
PES and WES			x	x
VAS			x	x
OHIP-14	x		x	x

Table 4. Outcome measures and time schedule in paper II and III.

## STATISTICAL ANALYSIS

### Paper I

Data management and analysis were performed using the metaprop function in STATA 14 (Stata Corp. 2015. Stata Statistical Software: Release 14. College Station, TX: StataCorp LP). Meta-analyses were conducted only if there were studies of similar comparison, reporting identical outcome measures (53). However, the studies

included revealed considerable variations in study design, i.e., different implant design, implant region, time frame between placement and loading of the implant, residual alveolar bone height, prosthetic solution, and type of outcome measures (53). Therefore, a well-defined meta-analysis was not applicable (53). However, the odds ratio in relation to patient-based implant loss were analysed, including a forest plot (53). One of the included studies had an implant loss of 0% for both implant types (39). Hence, standard methods excluded this study from the pooled estimate. Therefore, Petos method for pooling data with a continuity correction by adding 0.5 to each cell in the contingency table for the study was used (53,55). Moreover, a sensitivity analysis for pooling data was performed involving a fixed effects model with Mantel-Haenszel method for pooling data. The difference in PIMBL across the included studies were analysed, including a forest plot. A fixed effects model with inverse variance was used and the difference in PIMBL was expressed as mean percentage with a 95% confidence interval (CI) (53).

## **Paper II and III**

Data management and analysis were performed using STATA (StataCorp. 2019. Stata Statistical Software: Release 16. College Station, TX: StataCorp LLC.). Level of significance was 0.05. Patient demographics were reported as n when categorical and as means and standard deviations. P-values were estimated by Fischers exact test when categorical, and by Kruskal Wallis test when continuous (51). Differences between values at different times were reported as mean and standard deviation and were compared using t-test (51). Differences in scores from baseline to follow-up for OHIP-14, VAS, PES, and WES were calculated and means of the differences were compared using Ordinary Least Square regression with robust variance estimation to compensate for non-normal residuals (54).

### *Power calculation*

To ensure adequate power (Paper II and III), a sample size was determined using a power calculation based on differences in PIMBL changes performed in a previously published study involving replacement of a single-tooth implant using two different protocols of implant treatment (56). The calculation was based on the observed

changes in PIMBL from insertion of the implant to abutment connection (a change of 0.65 mm and a standard deviation of 0.65), 17 patients in each group reached a power of 97% at the 5%-level (51,54). With 15% to cover dropouts, each treatment group included 20 patients.



## RESULTS

The main results of the studies (paper I-III) are presented below.

### Paper I

Three studies fulfilling inclusion and exclusion criteria were included for analysis.

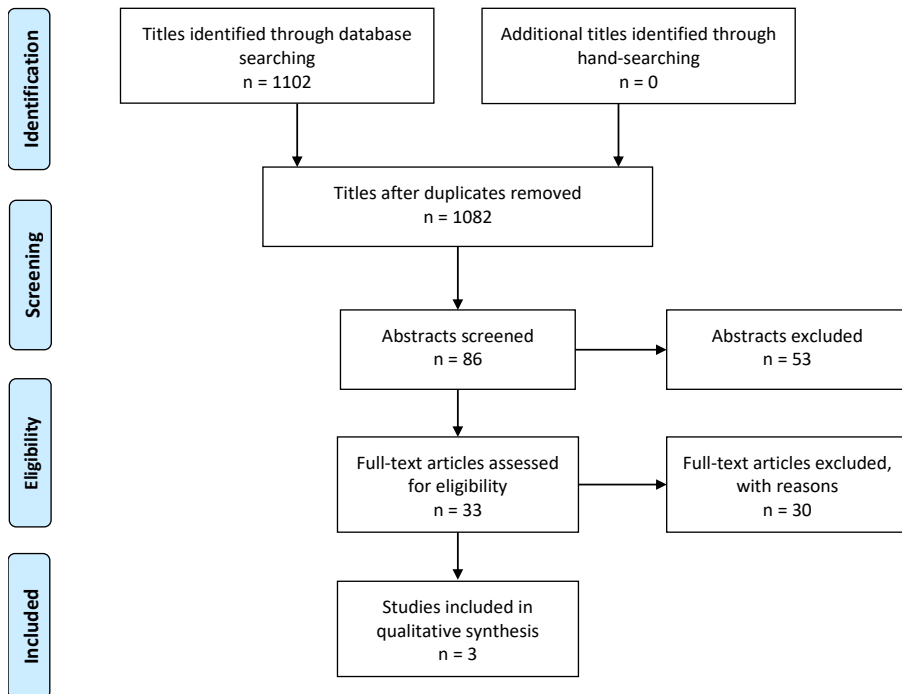


Fig. 4. PRISMA flow diagram demonstrating the results of the systematic literature search in paper I.

Survival of suprastructures was assessed in one study (57). The 3-year patient-based survival of suprastructures was 87% with short implants and 100% with standard-length implants in conjunction with MSFA. There was no statistically significant difference between the two treatment modalities. Survival of implants was assessed in all three included studies (39,40,57). The 3-year patient-based implant survival was 87% for short implants and 93% for standard-length implants in conjunction with MSFA (57). The 3-year patient-based implant survival was 100% for short implants compared to 95% for standard-length implants in conjunction with MSFA (40). Finally, the 3-year patient-based implant survival was 100% for both treatment

modalities (39). In conclusion, there was no statistically significant difference between the 3-year implant survival in the posterior part of the maxilla after placement of short implants compared with standard-length implants in conjunction with MSFA (53).

PIMBL was assessed in all the included studies (39,40,57). The 3-year PIMBL was 1.02 mm and 1.54 mm after placement of short implants compared with standard-length implants in conjunction with MSFA (57). The difference between the two treatment modalities was statistically significant. A 3-year PIMBL of 0.20 mm was reported after placement of short implants compared to 0.27 mm with standard-length implants in conjunction with MSFA (40). The difference between the two treatment modalities was statistically significant (40). Finally, a 3-year PIMBL of 0.6 mm in the premolar region and 0.4 mm in the molar region after placement of short implants compared to 0.4 mm and 0.5 mm with standard-length implants in conjunction with MSFA was reported (39). There was no statistically significant difference in the PIMBL between the two treatment modalities (39). In general, limited PIMBL was revealed with both treatment modalities after 3-years. However, placement of standard-length implants in conjunction with MSFA was associated with a significantly increased PIMBL compared with short implants (39).

ISQ was evaluated in one study (40). Both treatment modalities demonstrated high ISQ value at implant placement and after 3-years. However, a significantly higher ISQ value was reported after installation of standard-length implants in conjunction with MSFA compared to short implants after 3-years (40).

PROM was assessed in one study disclosing no statistically significant difference between the two treatment modalities concerning the overall patient satisfaction (40). However, treatment involving standard-length implants in conjunction with MSFA was significantly more time-consuming. Moreover, patients receiving short implants were significantly more fully satisfied with the cost of the treatment (40).

Biological complications were reported in two studies (40,57). Perforation of the sinus membrane occurred in three patients after placement of short implants compared to one sinus membrane perforation after installation of standard implants in conjunction with MSFA (57). Intraoperative or postoperative bleeding, pain, and swelling were infrequently reported after placement of standard-length implants in conjunction with MSFA, while these complications were not reported after placement of short implants (40). Peri-implant mucositis was reported in one patient 2-years after

loading of short implants (57). Loss of graft material occurred in one patient due to chronic sinusitis after placement of standard-length implants in conjunction with MSFA (40). Technical complications were reported in one study (39). There was no statistically significant difference in the occurrence of technical complications between the two treatment modalities (39). In general, the frequency and severity of biological and technical complications associated with the two treatment modalities were generally low and not severe which seems to be in accordance with previous publications (19,58).

## Results of meta-analysis

Meta-analysis for patient-based implant loss using Petos method with continuity correction of 0.5 demonstrated an odds ratio of 0.898 (95% CI = 0.148 to 5.442) for short implants compared with standard-length implants in conjunction with MSFA (53).

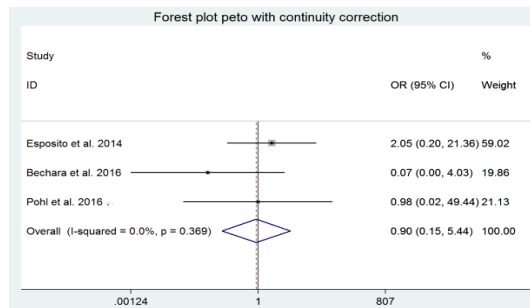


Fig. 5. Meta-analysis for patient-based implant loss using Petos method with continuity correction of 0.5 in paper I.

A test for heterogeneity revealed no important heterogeneity among the included studies, but the results are non-significant ( $P = 0.369$ ). Sensitivity analysis showed a similar result, but a different heterogeneity ( $P = 2.251$ ).

Meta-analysis using a fixed effects model with inverse variance demonstrated a mean difference in PIMBL of -0.07 mm (95% CI = -0.122 to -0.018) between standard-length implants in conjunction with MSFA compared with short implants. A sensitivity analysis showed similar but non-significant results (53).

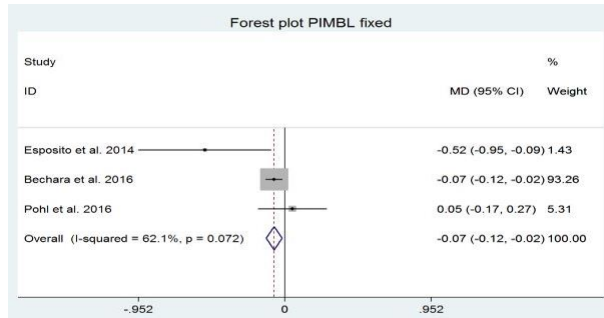


Fig. 6. Meta-analysis for PIMBL using a fixed effects model with inverse variance in paper I.

Meta-analyses revealed no significant differences in implant survival and PIMBL between the two treatment modalities. However, standard-length implants in conjunction with MSFA were characterized by a tendency of increased PIMBL (53).

### PAPER II and III

Forty patients with partial edentulism in the posterior part of the maxilla were randomly allocated to prosthetic rehabilitation with fixed single-crown restorations supported by a short implant (test) or standard-length implant in conjunction with MSFA (control) (51,54). There were no statistically significant differences between the test and control group regarding patient demographics or preoperative periodontal health status. Of the 40 patients enrolled, 37 completed the study (51,54).

#### *Survival of suprastructures and implants*

Survival of suprastructures and implants was 100% for both treatment modalities after 1-year of functional implant loading (51).

#### *Peri-implant marginal bone loss*

PIMBL at baseline and after 1-year of functional implant loading compared with the bone level at implant placement are outlined in Table 5.



PIMBL	Short implant Mean, (SD)	Standard-length implant and maxillary sinus floor augmentation. Mean, (SD)	P*
Δ IP - Baseline	0.32 (0.15)	0.25 (0.12)	0.16
Δ IP - 1-year	0.60 (0.17)	0.51 (0.14)	0.09
Δ Baseline - 1-year	0.28 (0.17)	0.26 (0.14)	0.64

Table 5. Peri-implant marginal bone loss over a 1-year period in paper II.

\*P value for same expected change from baseline to follow-up. Analysis by t-test.

### Clinical parameters of mucosal inflammation

Plaque score, BOP, and PPD at implant placement, baseline, and 1-year of functional implant loading are outlined in Table 6.

	Short implant Mean, (SD)			Standard-Length Implant and MSFA Mean, (SD)			P value
	Implant		1-year	Implant		1-year	
	Placement	Baseline		Placement	Baseline		
PI	1.62 (0.6)	1.46 (0.4)	1.32 (0.4)	1.68 (0.5)	1.38 (0.5)	1.36 (0.3)	0.52
PPD	2.80 (0.8)	2.6 (0.6)	2.4 (0.5)	2.9 (0.5)	2.7 (0.4)	2.5 (0.6)	0.41
BOP (%)	38	27	24	36	28	22	0.64

Table 6. Clinical parameters of mucosal inflammation over a 1-year period in paper II.

### Biological and mechanical complications

Standard-length implants in conjunction with MSFA revealed a statistically significant higher incidence of biological complications compared with short implants. There were no significant differences in mechanical complications between the two treatment modalities (P = 0.13). Biological and mechanical complications are outlined in Table 7.

	Patients, Short implant, n		Standard-length implant and maxillary sinus floor augmentation, n	P*
<b>Biological complications</b>	11	0	11	0.00
Intraoperative bleeding	1	0	1	0.46
Perforation of the Schneiderian membrane	3	0	3	0.09
Pain and swelling	4	0	4	0.04
Extensive cicatricial soft tissue	1	0	1	0.46
Infection	1	0	1	0.46
Permanent neurosensory disturbance	1	0	1	0.46
<b>Mechanical complications</b>	8	2	6	0.13
Abutment screw loosening	4	1	3	0.34
Loss of abutment	1	0	1	0.49
Loosening of suprastructure	1	0	1	0.49
Chipping of ceramics	2	1	1	1.00

Table 7. Biological and mechanical complications over a 1-year period in paper II.

\*Fischers exact test.

### Patient-related outcome measures

There were no significant differences in PROMs between the two treatment modalities at any time point ( $P > 0.05$ ). OHIP-14 scores decreased at baseline and after 1-year of functional implant loading in comparison to the preoperative assessment indicating improved OHRQoL with both treatment modalities (54). Evaluation of the peri-implant soft tissues, implant crown, implant function, and overall implant treatment using VAS scores at baseline and after 1-year of functional implant loading is outlined in Table 8. In general, the patients were overall very satisfied in both test and control group. None of the differences between the two groups were statistically significant ( $P > 0.05$ ) (54).

Dimension	Variables	Short implants Mean (SD)		Standard-length implants + MSFA Mean (SD)		P*
		Baseline	1-year	Baseline	1-year	
Peri-implant soft tissues	Are you satisfied with the appearance of the peri-implant soft tissues?	9.3 (0.7)	9.4 (0.6)	9.4 (0.6)	9.5 (0.5)	0.87
	Are you satisfied with the shape of the peri-implant soft tissues?	9.2 (0.6)	9.3 (0.5)	9.0 (0.6)	9.2 (0.5)	0.83
	Are you satisfied with the colour of the peri-implant soft tissues?	9.3 (0.8)	9.4 (0.6)	9.0 (0.5)	9.2 (0.5)	0.60
	Average score	9.3 (0.7)	9.4 (0.6)	9.1 (0.6)	9.3 (0.5)	0.88
Implant crown	Are you satisfied with the appearance of the implant crown?	9.3 (0.9)	9.4 (0.6)	9.8 (0.4)	9.9 (0.2)	0.08
	Are you satisfied with the shape of the implant crown?	8.9 (0.6)	9.2 (0.6)	8.8 (0.6)	9.4 (0.9)	0.65
	Are you satisfied with the colour of the implant crown?	9.1 (0.4)	9.2 (0.5)	9.4 (0.5)	9.4 (0.5)	0.89
	Average score	9.1 (0.7)	9.3 (0.6)	9.3 (0.6)	9.6 (0.7)	0.65
Implant function	The implant is functioning well	9.4 (0.5)	9.6 (0.5)	9.5 (0.5)	9.6 (0.5)	0.83
	The implant does not cause problems when I speak	9.4 (0.6)	9.6 (0.5)	9.8 (0.4)	9.9 (0.3)	0.33
	The implant does not cause problems when I eat	9.3 (0.6)	9.4 (0.5)	9.2 (0.7)	9.4 (0.5)	0.37
	The implant does not cause problems when I brush	9.8 (0.4)	9.9 (0.3)	10.0 (0.0)	10.0 (0.0)	0.87
	Average score	9.5 (0.6)	9.6 (0.5)	9.6 (0.6)	9.7 (0.5)	0.83
Total implant treatment	Are you satisfied with the total implant treatment in general?	9.2 (0.6)	9.3 (0.5)	9.2 (0.6)	9.2 (0.6)	0.60

Table 8. Subjective evaluation of treatment outcome using VAS questionnaire in paper III.

\*P-value for same expected change from baseline to follow-up.

Professional evaluations using PES and WES are outlined in Table 9. There were no significant differences in PES and WES between the two treatment modalities neither at baseline ( $P > 0.05$ ) nor after 1-year of functional implant loading ( $P > 0.05$ ) (54).

PES	Mesial papilla		Distal papilla		Level of soft tissue margin		Soft tissue contour		Alveolar process		Soft tissue colour		Soft tissue texture		Total	
	Base line	1-year	Base line	1-year	Base line	1-year	Base line	1-year	Base line	1-year	Base line	1-year	Base line	1-year	Base line	1-year
SI Mean (SD)	1.5 (0.5)	1.8 (0.4)	1.4 (0.5)	1.6 (0.5)	1.1 (0.4)	1.6 (0.6)	1.4 (0.6)	1.4 (0.6)	1.6 (0.5)	1.6 (0.5)	1.4 (0.5)	1.6 (0.5)	1.6 (0.5)	1.6 (0.5)	10.1 (1.1)	11.3 (1.3)
SLI/ MSF A Mean (SD)	1.6 (0.5)	1.8 (0.4)	1.4 (0.5)	1.8 (0.4)	1.4 (0.5)	1.5 (0.5)	1.4 (0.5)	1.5 (0.5)	1.6 (0.5)	1.6 (0.5)	1.4 (0.5)	1.5 (0.5)	1.5 (0.5)	1.5 (0.5)	10.2 (1.2)	11.2 (1.1)
$p^*$																0.53

WES	Tooth form		Tooth volume /outline		Colour (hue/value)		Translucency		Soft tissue texture		Total	
	Base line	1-year	Base line	1-year	Base line	1-year	Base line	1-year	Base line	1-year	Base line	1-year
SI Mean (SD)	1.6 (0.5)	1.6 (0.5)	1.6 (0.5)	1.6 (0.5)	1.6 (0.5)	1.6 (0.5)	1.6 (0.5)	1.6 (0.5)	1.6 (0.5)	1.8 (0.4)	8.0 (0.9)	8.1 (1.0)
SLI/MS FA Mean (SD)	1.5 (0.5)	1.6 (0.5)	1.6 (0.5)	1.7 (0.5)	1.5 (0.5)	1.5 (0.5)	1.6 (0.5)	1.6 (0.5)	1.7 (0.5)	1.8 (0.4)	8.0 (1.0)	8.1 (1.0)
$p^*$												0.64

Table 9. Professional evaluation of implant treatment outcome using PES and WES in paper III.

\*P-value for same expected change from baseline to follow-up.



## **DISCUSSION**

The objective of the present dissertation was to investigate the implant treatment outcome following prosthetic rehabilitation in the posterior maxilla with a fixed single-crown restorations supported by a short implant (6 mm) compared with a standard-length implant (13 mm) in conjunction with MSFA after 1-year of functional implant loading as well as an assessment of professional and PROM. A systematic review and a RCT were conducted to clarify the current knowledge and improve the level of evidence about prosthetic rehabilitation in the posterior maxilla with dental implants.

Survival of implants and PIMBL are generally the most commonly used criteria to assess various implant treatments (59). However, these parameters do not necessarily reflect the patient's anticipations and satisfaction with the surgical intervention and the implant-supported restoration. Therefore, assessment of oral rehabilitation with dental implants should also involve PROMs, as suggested in a recent Consensus Report of the International Team for Implantology (ITI) (60,61). Consequently, professional assessment and PROMs were included in the present dissertation. In the following sections, the results of the performed systematic review and the RCT are discussed in relation to clinical and radiographical parameters as well as professional and PROMs following prosthetic rehabilitation of the posterior maxilla with a fixed single-crown restoration supported with a short implant (6 mm) compared with standard-length implant (13 mm) in conjunction with MSFA after 1-year of functional implant loading. Finally, clinical implications and future perspectives of the present dissertation are emphasized.

### **Paper I**

A systematic review is a meticulous and structured synthesis of empirical evidence that consists of a predefined research question. Systematic reviews and meta-analyses are considered as the best evidence for answering a definitive research question due to the transparency of each phase of the synthesis process that delimit bias. Conclusions of a systematic review represent a detailed and comprehensive overview of the available evidence on a given topic. Therefore, a systematic review is frequently used for developing evidence-based clinical guidelines and defining future research agendas. However, the value and strength of a systematic review can be compromised by the selection of studies, heterogeneity among the included studies, inappropriate subgroup

analyses, publication bias, and loss of information on important outcomes due to predefined eligibility inclusion criteria and systematically extraction of specified data.

Meta-analysis is a statistical method that integrates and combine results of homogenous and comparable studies. Systematic reviews are frequently combined with a meta-analysis to increase the strength of evidence and improve the statistical power. However, combining inhomogeneous studies in a meta-analysis incorporates a risk of misleading conclusions, especially if heterogeneity and bias is not considered. The current knowledge of prosthetic rehabilitation of the posterior maxilla with fixed single-crown restorations supported by short implants compared with standard-length implants in conjunction with MSFA with an observation period of 3-years was assessed in the systematic review (53). However, the included studies revealed as previously described considerable variations in study design, i.e., different implant design, implant region, time frame between placement of implant and functional implant loading, residual alveolar bone height, prosthetic solution, and type of outcome measures. Therefore, a well-defined meta-analysis could not be applied. However, the odds ratio in relation to patient-based implant loss were analysed after an observation period of more than 3-years revealing non-significant lower odds for losing short implants compared with standard-length implants in conjunction with MSFA. (Fig. 5). In addition, the meta-analysis revealed no significant differences in PIMBL between the two treatment modalities. The included RCTs of the present systematic review disclosed low risk of bias. High survival rates of suprastructures and implants with limited PIMBL were observed with both treatment modalities. In addition, high ISQ value and high patient satisfaction were reported. Despite the high quality of the included studies and the low risk of bias, there is a potential risk of bias due to the heterogeneity among the included studies. Further homogenous RCTs with large patient samples including an observation period of more than three years therefore seems necessary, and the conclusions drawn from the results of this systematic review and meta-analysis should be cautiously interpreted.

## **Paper II and II**

The study was designed as a classic two-armed RCT comparing an intervention group (short implants) and a control group (standard-length implants in conjunction with MSFA). The design of the present study is characterized by various limitations

including small sample size, short-term observation period, and no blinding of participants or assessors. No statistically significant differences in survival of suprastructures or implants, PIMBL, mechanical complications, professional or PROMs were revealed at any time point between the two treatment modalities. Consequently, the two treatments modalities seem comparable for prosthetic rehabilitation in the posterior maxilla as evaluated after 1-year of functional implant loading.

Short implants with an increased crown height and higher crown-to-implant ratio did not seem to have a negative impact on the treatment outcome. However, previous studies have reported a slightly higher rate of mechanical complications on the prosthetic level using short implants (62). In the presented study, the difference between the two treatment modalities according to crown-to-implant ratio was significant ( $P \leq 0.049$ ). No significant differences in implant survival, PIMBL, and mechanical complications were revealed between the two treatment modalities.

Standard-length implants in conjunction with MSFA showed a significant higher incidence of biological complications, including intraoperative perforation of the Schneiderian membrane as well as postoperative bleeding, swelling, and pain. In addition, a permanent neurosensory disturbance of the alveolar inferior nerve was observed in one patient after autogenous bone harvesting from the ascending mandibular ramus. Patient satisfaction was evaluated by self-administrated questionnaires using VAS, which is considered a valid and reliable assessment tool. Despite the above-mentioned complications, patients' rating showed an overall high and comparable satisfaction with the implant treatment outcome at baseline and after 1-year of functional implant loading with both treatment modalities. In a recently published RCT, fixed single-crown restorations in the posterior maxilla with short implants (6 mm) compared with standard-length implants (11-15 mm) in conjunction with MSFA demonstrated an implant survival rate of 98.5% with short implants and 100% with standard-length implants after 5-years of functional implant loading (16). Limited PIMBL was revealed with both treatment modalities without any statistically significant differences, although standard-length implants in conjunction with MSFA were associated with a higher incidence of biological complications compared with short implants (16). These long-term results are in accordance with the results of the present short-term study.

The present study was limited by a small sample size and a short-term observation

period. However, a power calculation was based on the observed changes in marginal bone level from insertion of the implant to abutment connection (a change of 0.65 mm and a standard deviation of 0.65), including 17 patients allowed us to reach a power of 97% at the 5% level. Despite extensive advertisement and effort and due to a limited time frame, patient recruitment turned out to be challenging and time consuming. A larger sample size and a longer observation period would therefore be desirable.





## CONCLUSION

The accomplished systematic review (Paper I) and RCT (Paper II and III) warrant the following main conclusions:

- The hypothesis of no difference in implant treatment outcome after prosthetic rehabilitation of the posterior maxilla with fixed single-crown restorations supported by short implants ( $\leq 8$  mm) compared with standard-length implants ( $> 8$  mm) in conjunction with MSFA using the lateral window technique after an observation period of long-term RCT ( $\geq 3$  years) could not be rejected due to significant heterogeneity among the included studies (Paper I).
- Prosthetic rehabilitation in the posterior maxilla with fixed single-crown restorations supported by short implants (6 mm) or standard-length implants (13 mm) in conjunction with MSFA revealed comparable clinical and radiographic implant treatment outcomes after 1-year of functional implant loading, although standard-length implants were associated with a higher frequency of biological complications (Paper II).
- Prosthetic rehabilitation in the posterior maxilla with fixed single-crown restorations supported by short implants (6 mm) or standard-length implants (13 mm) in conjunction with MSFA revealed comparable professional evaluation of esthetics and PROMs after 1-year of functional implant loading (Paper III).
- Prosthetic rehabilitation in the posterior maxilla with fixed single-crown restoration supported by short implants (6 mm) or standard-length implants (13 mm) in conjunction with MSFA seem to be characterized by comparable treatment outcomes as evaluated in short-term study (Paper II and III).
- Further, long-term RCTs assessing prosthetic rehabilitation in the posterior maxilla with short implants compared with standard-length implants in conjunction with MSFA, including larger patient samples, assessment of donor site morbidity, economic perspective, length of treatment time, patient's perception of recovery, influence of crown-to-implant ratio on long-term

implant treatment outcome, and PROMs are needed before definite evidence-based clinical implications can be provided about the two treatment modalities.



## **CLINICAL IMPLICATIONS AND FUTURE PERSPECTIVE**

From a clinical and patient perspective, it would be an advantage, if prosthetic rehabilitation in the posterior maxilla with fixed single-crown restorations supported by short implants could replace standard-length implants in conjunction with MSFA due to shortened surgical time, decreased cost, diminished postoperative discomfort, reduced risk of biological complications, no donor site morbidity, including risk of neurosensory disturbances. The present thesis indicates that short implants seem to be a comparable treatment modality for prosthetic rehabilitation of the posterior maxilla with fixed single-crown restorations compared with standard-length implants in conjunction with MSFA after 1-year of functional implant loading. However, the current knowledge about prosthetic rehabilitation in the posterior maxilla is based on few long-term RCTs mainly focusing on clinical and radiographic implant treatment outcome in small patient samples. Moreover, the influence of a higher crown-to-implant ratio on long-term implant treatment outcome are still not sufficient elucidated. Further long-term RCT including larger patient samples are therefore needed before definitive evidence-based clinical implications can be provided about prosthetic rehabilitation of the posterior maxilla with fixed single-crown restorations supported by short implants or standard-length implants in conjunction with MSFA.



## ACKNOWLEDGMENTS

The dissertation would not have been conducted without the support, help, guidance, and assistance from colleagues and family.

First and foremost, I would like to sincerely thank my main supervisor Professor Thomas Starch-Jensen. I am deeply indebted and thankful for this great opportunity and for his scientific and skilful guidance, encouragement, motivation, and valuable support.

Furthermore, a special thanks to my co-supervisor Søren Schou for highly appreciated and skillful support, contribution, and outstanding knowledge sharing.

I gratefully acknowledge the valuable support and study design proposals of co-supervisor, Professor Flemming Isidor. It was a privilege working under his inspiring guidance and supervision.

I am thankful to the entire staff at the Department of Oral and Maxillofacial Surgery, Aalborg University Hospital, Denmark for continuous support. A special thanks to Louise Fibiger Vangdal for logistic assistance and a special gratitude to Janek Dalsgaard Jensen for supporting me. I am thankful for the time, encouragement, and flexibility throughout the years of conducting the thesis.

Many thanks to Niels Henrik Bruun for valuable help and support with analyses of the data and many thanks to Connie Blauenfeldt for valuable help with the prosthetics.

Dentsply Sirona, Göteborg, Sweden is gratefully acknowledged for generously donating implants and prosthetic components.

Finally, but most importantly, a very special thank goes to my family for supporting me during the entire study period.

This thesis is dedicated to my beloved son, Peter Christian.





## REFERENCES

1. Pjetursson BE, Tan WC, Zwahlen M, Lang NP. A systematic review of the success of sinus floor elevation and survival of implants inserted in combination with sinus floor elevation. *J Clin Periodontol.* 2008;35(8):216–40.
2. Jensen SS, Terheyden H. Bone augmentation procedures in localized defects in the alveolar ridge: clinical results with different bone grafts and bone-substitute materials. *Int J Oral Maxillofac Implants.* 2009;24 Suppl:218-36.
3. Nkenke E, Stelzle F. Clinical outcomes of sinus floor augmentation for implant placement using autogenous bone or bone substitutes: a systematic review. *Clin Oral Implants Res.* 2009;20 Suppl 4:124–33.
4. Pjetursson BE, Thoma D, Jung R, Zwahlen M, Zembic A. A systematic review of the survival and complication rates of implant-supported fixed dental prostheses (FDPs) after a mean observation period of at least 5 years. *Clin Oral Implants Res.* 2012;23 Suppl 6:22–38.
5. Corbella S, Taschieri S, Del Fabbro M. Long-Term Outcomes for the Treatment of Atrophic Posterior Maxilla: A Systematic Review of Literature. *Clin Implant Dent Relat Res.* 2015;17(1):120–32.
6. Esposito M, Ardebili Y, Worthington HV. Interventions for replacing missing teeth: different types of dental implants. *Cochrane Database Syst Rev.* 2014;22;(7):CD003815.
7. Burchardt H. The biology of bone graft repair. *Clin Orthop Relat Res.* 1983;174:28–42.
8. Clavero J, Lundgren S. Ramus or chin grafts for maxillary sinus inlay and local onlay augmentation: comparison of donor site morbidity and complications. *Clin Implant Dent Relat Res.* 2003;5(3):154–60.
9. Jensen T, Schou S, Stavropoulos A, Terheyden H, Holmstrup P. Maxillary sinus floor augmentation with Bio-Oss or Bio-Oss mixed with autogenous bone as graft in animals: a systematic review. *Int J Oral Maxillofac Surg.* 2012;41(1):114–20.
10. Danesh-Sani SA, Engebretson SP, Janal MN. Histomorphometric results of different grafting materials and effect of healing time on bone maturation after

- sinus floor augmentation: a systematic review and meta-analysis. *J Periodontol Res.* 2017;52(3):301-12.
11. Lundgren S, Cricchio G, Hallmann M, Jungner M, Rasmussen L, Sennerby L. Sinus floor elevation procedures to enable implant placement and integration: techniques, biological aspects and clinical outcomes. 2017;73(1): 103-20.
  12. Starch-Jensen T, Mordenfeld A, Becktor JP, Jensen SS. Maxillary Sinus Floor Augmentation With Synthetic Bone Substitutes Compared With Other Grafting Materials: A Systematic Review and Meta-analysis. *Implant Dent.* 2018 Jun;27(3):363-374.
  13. Perelli M, Abundo R, Corrente G, Saccone C. Short (5 and 7 mm long) porous implants in the posterior atrophic maxilla: a 5-year report of a prospective single-cohort study. *Eur J Oral Implantol.* 2012;5(3):265–72.
  14. Esposito M, Cannizzaro G, Soardi E, Pistilli R, Piattelli M, Corvino V, Felice P. Posterior atrophic jaws rehabilitated with prostheses supported by 6 mm-long, 4 mm-wide implants or by longer implants in augmented bone. Preliminary results from a pilot randomised controlled trial. *Eur J Oral Implantol.* 2012;5(1):19–33.
  15. Cannizzaro G, Felice P, Minciarelli AF, Leone M, Viola P, Esposito M. Early implant loading in the atrophic posterior maxilla: 1-stage lateral versus crestal sinus lift and 8 mm hydroxyapatite-coated implants. A 5-year randomised controlled trial. *Eur J Oral Implantol.* 2013;6(1):13–25.
  16. Thoma DS, Haas R, Sporniak-Tutak K, Garcia A, Taylor TD, Hämmerle CHF. Randomized controlled multicentre study comparing short dental implants (6 mm) versus longer dental implants (11–15 mm) in combination with sinus floor elevation procedures: 5-Year data. *J. Clin. Periodontol.* 2018;45(12):1465–74.
  17. Guljé FL, Raghoobar GM, Vissink A., Meijer HJA. Single crowns in the resorbed posterior maxilla supported by either 11-mm implants combined with sinus floor elevation or 6-mm implants: A 5-year randomised controlled trial. *Int. J. Oral Implant.* 2019;12(3):315–26.
  18. Esposito M, Pellegrino G, Pistilli R, Felice P. Rehabilitation of posterior atrophic edentulous jaws: prostheses supported by 5 mm short implants or by longer implants in augmented bone? One-year results from a pilot randomised

- clinical trial. *Eur J Oral Implantol.* 2011;4(1):21–30.
19. Guljé FL, Raghoobar GM, Vissink A, Meijer HJA. Single crowns in the resorbed posterior maxilla supported by either 6-mm implants or by 11-mm implants combined with sinus floor elevation surgery: a 1-year randomised controlled trial. *Eur J Oral Implantol.* 2014;7(3):247–55.
  20. Telleman G, Raghoobar GM, Vissink A, den Hartog L, Huddleston Slater JJR, Meijer HJA. A systematic review of the prognosis of short (<10 mm) dental implants placed in the partially edentulous patient. *J Clin Periodontol.* 2011;38(7):667–76.
  21. Sun HL, Huang C, Wu YR, Shi B. Failure rates of short ( $\leq 10$  mm) dental implants and factors influencing their failure: a systematic review. *Int J Oral Maxillofac Implants.* 2011;26(4):816–25.
  22. Atieh MA, Zadeh H, Stanford CM, Cooper LF. Survival of short dental implants for treatment of posterior partial edentulism: a systematic review. *Int J Oral Maxillofac Implants.* 2012;27(6):1323–31.
  23. Annibaldi S, Cristalli MP, Dell'Aquila D, Bignozzi I, La Monaca G, Pilloni A. Short dental implants: a systematic review. *J Dent Res.* 2012;91(1):25–32.
  24. Srinivasan M, Vazquez L, Rieder P, Moraguez O, Bernard J-P, Belser UC. Survival rates of short (6 mm) micro-rough surface implants: a review of literature and meta-analysis. *Clin Oral Implants Res.* 2014;25(5):539–45.
  25. Jacob S. *Human Anatomy.* Elsevier. 2008;209-10.
  26. Hupp J, Tucker M, Ellis E. *Contemporary Oral and Maxillofacial Surgery.* 7th ed. Elsevier. 2018;369-89.
  27. Mavrodi A, Paraskevas G. Evolution of the paranasal sinuses' anatomy through the ages. *Anat Cell Biol.* 2013;46(4):235-8.
  28. Jensen T, Folkmar TB, Lund EB. Knoglesepta i sinus maxillaris: en usædvanlig røntgenologisk af tegning. *Tandlægebladet* 2003;107:754-6.
  29. Sakhdari S, Panjnoush M, Eyvazlou A, Niktash A. Determination of the prevalence, height, and location of the maxillary sinus septa using cone beam computed tomography. *Implant Dent* 2016;25(3):335-40.
  30. Marks, SC Jr. The basic and applied biology of tooth eruption. *Connect Tissue Res.* 1995;32(1-4):149-57.
  31. Marks, SC Jr, Schroeder, HE. Tooth eruption: theories and facts. *Anat Rec.*

- 1996;245(2):374-93.
32. Tallgren, A. The continuing reduction of the residual alveolar ridges in complete denture wearers: a mixed-longitudinal study covering 25 years. *J Prosthet Dent.* 1972;27(2):120–32.
  33. Tan WL, Wong TL, Wong MC, Lang NP. A systematic review of post-extraction alveolar hard and soft tissue dimensional changes in humans. *Clin Oral Implants Res.* 2012;23 Suppl 5:1-21.
  34. Schropp, L., Wenzel, A., Kostopoulos, L, Karring, T. Bone healing and soft tissue contour changes following single-tooth extraction: a clinical and radiographic 12-month prospective study. *Int J Periodontics Restorative Dent.* 2003;23(4):313-23.
  35. Araújo MG, Lindhe J. Dimensional ridge alterations following tooth extraction. An experimental study in the dog. *J Clin Periodontol.* 2005;32(2):212-8.
  36. Thoma DS, Zeltner M, Hüsler J, Hämmerle CH, Jung RE. EAO Supplement Working Group 4 - EAO CC 2015 Short implants versus sinus lifting with longer implants to restore the posterior maxilla: a systematic review. *Clin Oral Implants Res.* 2015;26 Suppl 11:154-69.
  37. Lemos CA, Ferro-Alves ML, Okamoto R, Mendonça MR, Pellizzer EP. Short dental implants versus standard dental implants placed in the posterior jaws: A systematic review and meta-analysis. *J Dent.* 2016;47:8-17.
  38. Boyne PJ, James RA. Grafting of the maxillary sinus floor with autogenous marrow and bone. *J Oral Surg.* 1980;38(8):613-6.
  39. Pohl V, Thoma DS, Sporniak-Tutak K, Garcia-Garcia A, Taylor TD, Haas R, Hämmerle CH. Short dental implants (6 mm) versus long dental implants (11-15 mm) in combination with sinus floor elevation procedures: 3-year results from a multicentre, randomized, controlled clinical trial. *J Clin Periodontol.* 2017;44(4):438-445.
  40. Bechara S, Kubilius R, Veronesi G, Pires JT, Shibli JA, Mangano FG. Short (6-mm) dental implants versus sinus floor elevation and placement of longer ( $\geq 10$ -mm) dental implants: a randomized controlled trial with a 3-year follow-up. *Clin Oral Implants Res.* 2017;28(9):1097-1107.
  41. Anitua E, Piñas L, Begoña L, Orive G. Long-term retrospective evaluation of short implants in the posterior areas: clinical results after 10-12 years. *J Clin*

- Periodontol. 2014;41(4):404-11.
42. Yan Q, Wu X, Su M, Hua F, Shi B. Short implants ( $\leq 6$  mm) versus longer implants with sinus floor elevation in atrophic posterior maxilla: a systematic review and meta-analysis. *BMJ Open*. 2019;28;9(10):e029826.
  43. Lozano-Carrascal N, Anglada-Bosqued A, Salomó-Coll O, Hernández-Alfaro F, Wang HL, Gargallo-Albiol J. Short implants ( $< 8$ mm) versus longer implants ( $\geq 8$ mm) with lateral sinus floor augmentation in posterior atrophic maxilla: A meta-analysis of RCT's in humans. *Med Oral Patol Oral Cir Bucal*. 2020;25(2):e168-e179.
  44. Hingsammer L, Watzek G, Pommer B. The influence of crown-to-implant ratio on marginal bone levels around splinted short dental implants: A radiological and clinical short term analysis. *Clin Implant Dent Relat Res*. 2017;19(6):1090-98.
  45. Ravidà A, Barootchi S, Alkanderi A, Tavelli L, Suárez-López Del Amo F. The Effect of Crown-to-Implant Ratio on the Clinical Outcomes of Dental Implants: A Systematic Review. *Int J Oral Maxillofac Implants*. 2019;34(5):1121–1131.
  46. Hadzik J, Krawiec M, Sławewski K, Kunert-Keil C, Dominiak M, Gedrange T. The Influence of the Crown-Implant Ratio on the Crestal Bone Level and Implant Secondary Stability: 36-Month Clinical Study. *Biomed Res Int*. 2018;4246874.
  47. Garaicoa-Pazmiño C, Suárez-López del Amo F, Monje A, Catena A, Ortega-Oller I, Galindo-Moreno P, Wang HL. Influence of crown/implant ratio on marginal bone loss: a systematic review. *J Periodontol*. 2014;85(9):1214-21.
  48. Blanes RJ. To what extent does the crown-implant ratio affect the survival and complications of implant-supported reconstructions? A systematic review. *Clin Oral Implants Res*. 2009;20 Suppl 4:67-72.
  49. Schneider D, Witt L, Hämmerle CHF. Influence of the crown-to-implant length ratio on the clinical performance of implants supporting single crown restorations: a cross-sectional retrospective 5-year investigation. *Clin Oral Implants Res*. 2012;23(2):169-74.
  50. Lee KJ, Kim YG, Park JW, Lee JM, Suh JY. Influence of crown-to-implant ratio on periimplant marginal bone loss in the posterior region: a five-year

- retrospective study. *J Periodontal Implant Sci.* 2012;42(6):231-36.
51. Nielsen HB, Schou S, Bruun NH, Starch-Jensen T. Single-crown restorations supported by short implants (6 mm) compared with standard-length implants (13 mm) in conjunction with maxillary sinus floor augmentation: a randomized, controlled clinical trial. *Int J Implant Dent.* 2021;7(1):66.
  52. Esfahrood ZR, Ahmadi L, Karami E, Asghari S. Short dental implants in the posterior maxilla: a review of the literature. *J Korean Assoc Oral Maxillofac Surg.* 2017;43(2):70-76.
  53. Nielsen HB, Schou S, Isidor F, Christensen AE, Starch-Jensen T. Short implants ( $\leq 8$  mm) compared to standard length implants ( $> 8$  mm) in conjunction with maxillary sinus floor augmentation: a systematic review and meta-analysis. *Int J Oral Maxillofac Surg.* 2019;48(2):239-49.
  54. Nielsen HB, Schou S, Bruun NH, Starch-Jensen T. Professional and patient-reported outcomes of two surgical approaches for implant supported single-crown restoration: 1-year results of a randomized controlled clinical trial. *Clin Oral Implants Res.* 2022;33(2):197-208.
  55. Cheng J, Pullenayegum E, Marshall JK, Iorio A, Thabane L. Impact of including or excluding both-armed zero-event studies on using standard meta-analysis methods for rare event outcome: a simulation study. *BMJ Open.* 2016;16;6(8):e010983.
  56. Schropp L, Isidor F. Clinical outcome and patient satisfaction following full-flap elevation for early and delayed placement of single-tooth implants: a 5-year randomized study. *Int J Oral Maxillofac Implants.* 2008;23(4):733-43.
  57. Esposito M, Pistilli R, Barausse C, Felice P. Three-year results from a randomised controlled trial comparing prostheses supported by 5-mm long implants or by longer implants in augmented bone in posterior atrophic edentulous jaws. *Eur J Oral Implantol.* 2014;7(4):383-95.
  58. Thoma DS, Haas R, Tutak M, Garcia A, Schincaglia GP, Hämmerle CHF. Randomized controlled multicenter study comparing short dental implants (6mm) versus longer dental implants (11-15mm) in combination with sinus floor elevation procedures. Part 1: demographics and patient-reported outcomes at 1 year of loading. *J Clin Periodontol.* 2014;42(1):72-80.
  59. Papaspyridakos P, Chen CJ, Singh M, Weber HP, Gallucci GO. Success

- criteria in implant dentistry: a systematic review. *J Dent Res.* 2012;91(3):242-8.
60. De Bruyn H, Raes S, Matthys C, Cosyn J. The current use of patient-centered/reported outcomes in implant dentistry: a systematic review. *Clin Oral Implants Res.* 2015;26 Suppl 11:45-56.
61. Feine J, Abou-Ayash S, Al Mardini M, de Santana RB, Bjelke-Holtermann T, Bornstein MM, Braegger U, Cao O, Cordaro L, Eycken D, Fillion M, Gebran G, Huynh-Ba G, Joda T, Levine R, Mattheos N, Oates TW, Abd-UI-Salam H, Santosa R, Shahdad S, Storelli S, Sykaras N, Treviño Santos A, Stephanie Webersberger U, Williams MAH, Wilson TG Jr, Wismeijer D, Wittneben JG, Yao CJ, Zubiria JPV. Group 3 ITI Consensus Report: Patient-reported outcome measures associated with implant dentistry. *Clin Oral Implants Res.* 2018 ;29 Suppl 16:270-275.
62. Quaranta A, Piemontese M, Rappelli G, Sammartino G, Procaccini M. Technical and biological complications related to crown to implant ratio: a systematic review. *Implant Dent.* 2014;23(2):180-7.





## **APPENDIX: PAPER I-III**

- I. Short implants ( $\leq 8$  mm) compared to standard length implants ( $> 8$  mm) in conjunction with maxillary sinus floor augmentation: a systematic review and meta-analysis. Nielsen HB, Schou S, Isidor F, Christensen AE, Starch-Jensen T. *Int J Oral Maxillofac Surg* 2019;48:239-49.
  
- II. Single-crown restorations supported by short implants (6 mm) compared with standard-length implants (13 mm) in conjunction with maxillary sinus floor augmentation: a randomized, controlled clinical trial. Nielsen HB, Schou S, Bruun NH, Starch-Jensen T. *Int J Implant Dent* 2021;7:66.
  
- III. Professional and patient-reported outcomes of two surgical approaches for implant supported single-crown restoration: 1-year results of a randomized controlled clinical trial. Nielsen HB, Schou S, Bruun NH, Starch-Jensen T. *Clin Oral Implants Res* 2022;33:197-208.

ISSN (online): 2246-1302  
ISBN (online): 978-87-7573-753-6

**AALBORG UNIVERSITY PRESS**