

# Tumour location is important in selecting patients who may benefit from abdominal compression when receiving SABR for lung tumours.

Rane, J.K.<sup>1</sup>, Harsanyi, C.<sup>1</sup>, Grimes, H.<sup>1</sup>, Moinuddin, S.<sup>1</sup>, Quingua, K.<sup>1</sup>, Petkar, S.<sup>1</sup>, Dubash, S.<sup>1</sup>, Hiley, C.<sup>1,2</sup>, Wilson, J. M.<sup>1</sup>

<sup>1</sup>University College London Hospitals NHS Foundation Trust

<sup>2</sup>CRUK Lung Cancer Centre of Excellence. UCL Cancer Institute. London

## Introduction

Abdominal compression (AC, figure 1) has been the standard motion mitigation technique for all abdominal stereotactic ablative radiotherapy (SABR) since March 2020 at UCLH. However, whether AC could be equally beneficial for motion mitigation for lung SABR is controversial (1). Since lower zone tumours move more than upper zone tumours (2), we tested whether motion mitigation by AC could be specifically beneficial for lower zone lung tumours. In this study, we characterised AC induced changes in tumour motion in more detail and assessed whether they translated into dosimetric benefit.

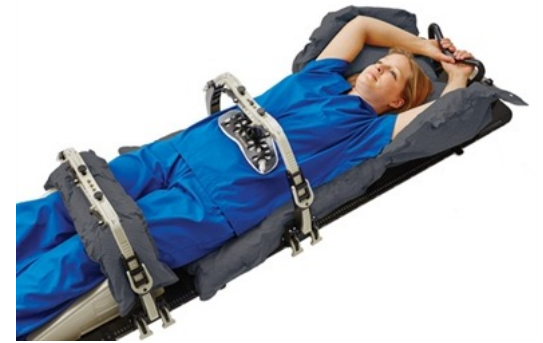

Figure 1 Civco Body Pro-lok™ system

## Methods:

6 patients with tumours caudal to the carina (Figure 2) were dual scanned using 4DCT with and without AC using Body Pro-lok™ system (Civco). Patients were contoured and planned on AC and uncompressed (UC) datasets. Plans were compared to assess target and organs at risk (OARs) dosimetry to select the most appropriate plan for treatment. The planned and delivered doses were 54 Gy in 3 fractions (n=2), 55 Gy in 5 fractions (n=1) and 60 Gy in 8 fractions (n=3).

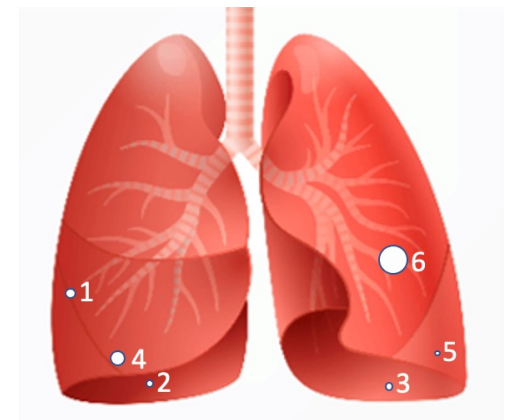
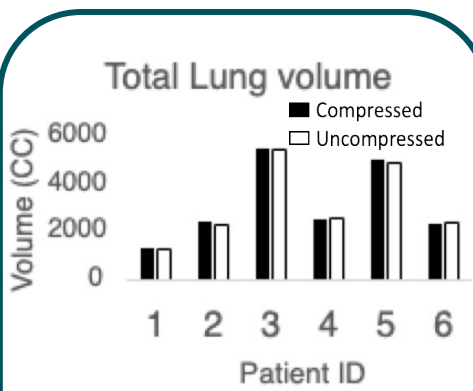
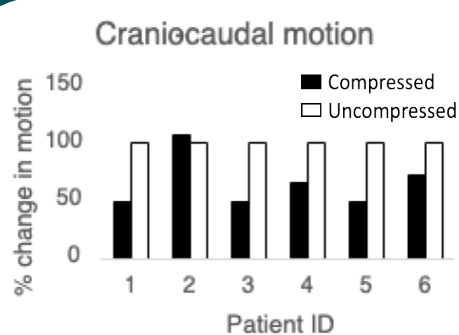


Figure 2: Approximate schematic showing size and location of tumours

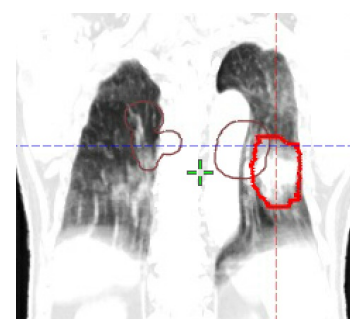
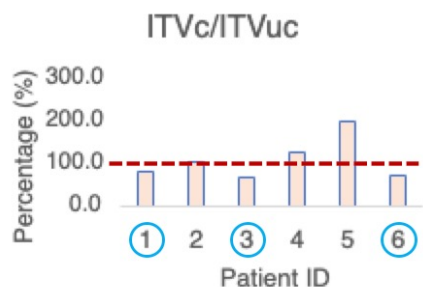
## Results:



**1.** Abdominal compression (AC) did not reduce total lung volume



**2.** AC mitigated crani-caudal motion in 5/6 patients, however ITV was reduced in 3/6 patients  
*ITV: internal target volume*



This figure shows ITV compressed (red) and proximal bronchial tree + 2 cm (brown). For the uncompressed plan, PTV D99% and D95% had to be compromised to meet bronchial tree constraint, which was not needed for the compressed plan.

**3.** For patient 6, whose PTV was within 2 cm of the bronchial tree, AC was essential to satisfy OAR constraints

**4.** No clinically relevant differences were found in OAR dosimetry: lung V12.5Gy, heart D0.5cc, chest wall D0.5cc and bronchial tree D0.5cc

**5.** AC was tolerated well by patients, but needed trained staff and additional scanner time

## Outcomes:

AC did not provide consistent dosimetric benefit for 5/6 patients undergoing SABR for lower zone lung tumours. However, it may be useful when GTV is within 2 cm of the bronchial tree.

## References:

- Bouilhol et al., Phys Med. 2013 Jun;29(4):333-40
- Knybel et al. Int J Radiat Oncol Biol Phys. 2016 Nov 15;96(4):751-758