






## The Floating Elbow: About 2 Cases and Review of the Literature

Mehdi Abakka \* , Yahya Baidriss, Hamza El Ouagari, Jalal Mekkaoui, Monsef Bouffetal, Rida-Allah Bassir , Mohamed Kharmaze, Moulay Omar Lamrani , Mohamed Saleh Berrada  
*Department of Orthopedic and Traumatological Surgery, Ibn Sina Hospital, Rabat, Morocco*

### Article Information

#### Suggested Citation:

Abakka, M., Baidriss, Y., El Ouagari, H., Mekkaoui, J., Bouffetal, M., Bassir, R.A., Kharmaze, M., Lamrani, M.O. & Berrada, M.S. (2023). The floating elbow: About 2 cases and review of the literature. *European Journal of Theoretical and Applied Sciences*, 1(3), 485-491.

DOI: [10.59324/ejtas.2023.1\(3\).46](https://doi.org/10.59324/ejtas.2023.1(3).46)

#### \* Corresponding author:

Mehdi Abakka

e-mail: mehdi.abakka@gmail.com

### Abstract:

The floating elbow represents an uncommon combination of lesions in traumatology. Few studies have described this lesion especially in adults. Over a period of 5 months, two floating elbows were reviewed retrospectively. Reduction and internal fixation using different implants were performed for our patients. Consolidation was obtained at the humerus at 4 months (3.5-4.5 months) on average, and 5 months (4-6 months) at forearm bones. According to the classification of Lange and Foster, our functional results were good in 100 %. Good functional prognosis of the upper limb requires rapid and adequate management of floating elbows. Internal fixation followed by early rehabilitation is recommended. The choice of surgical acts depends on the location of fractures. Our strategy gave satisfactory results.

**Keywords:** *Elbow, Humerus, Forearm, Fracture, Osteosynthesis.*

### Introduction

The floating elbow associates a fracture of the humerus and a fracture of the ipsilateral forearm. This staged fracture of the upper limb is uncommon in traumatology.

This complex and serious trauma was initially described in children by Staniski and Micheli, then in adults by Rogers.

Few works in the literature have been devoted to it, especially in adults.

The classifications, the therapeutic methods and the functional results of this staged trauma of the upper limb will be discussed through this retrospective work.

We report two cases treated in our department.

### Materiel and Methods

These are two men, aged 58 and 46 respectively, who presented trauma to the left upper limb, following a traffic accident for the first and a work accident for the second. In both cases, they were blunt traumas, uncomplicated by vasculonervous disorders. Radiologically, it is a mid-diaphyseal fracture of the humerus and the two bones of the forearm in both cases.

All the patients underwent emergency surgery, with internal osteosynthesis for all the fractures, associated with postoperative immobilization with a BABP splint or with an elbow sling to the body.



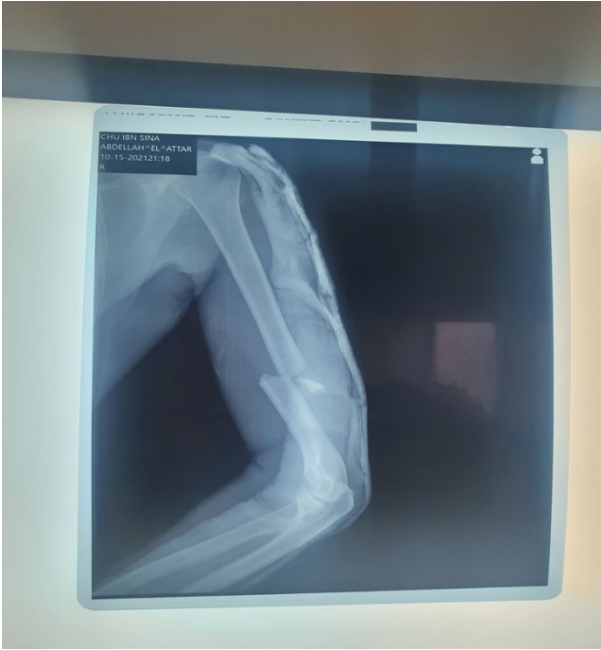

Figure 1. X-Ray of an Humerus Fracture

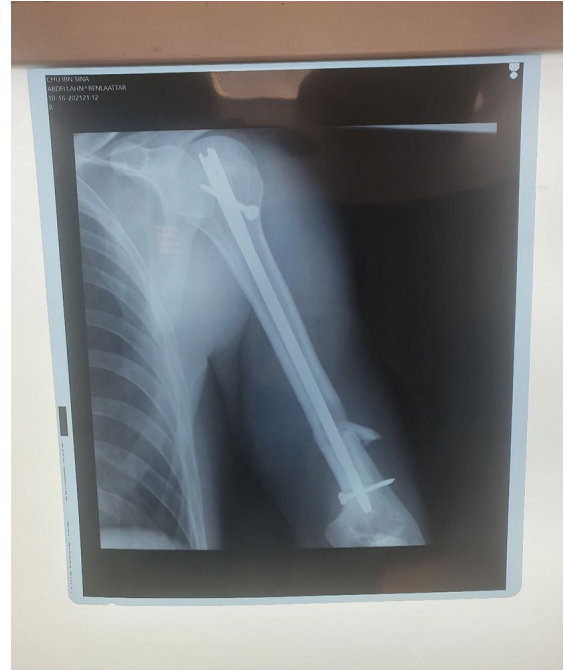

Figure 2. Humerus Nailing with a Locked Nail

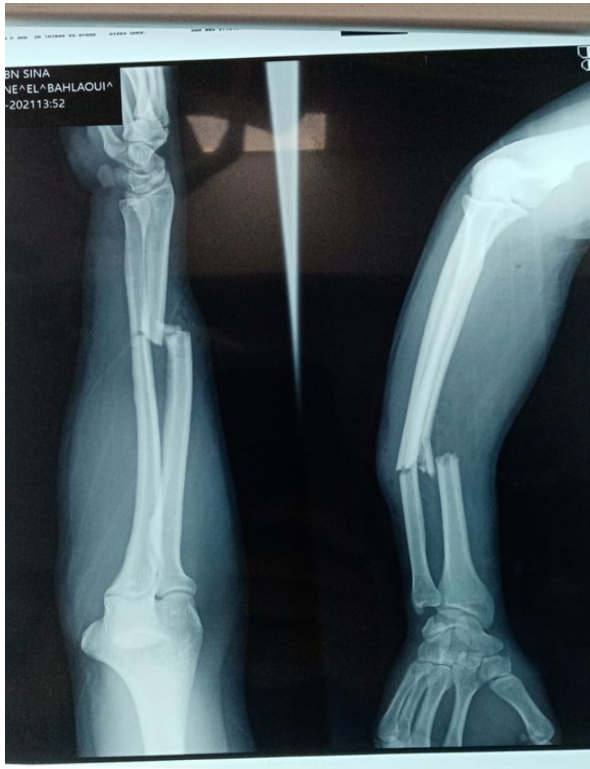

Figure 3. X-Ray of a Forearm Fracture

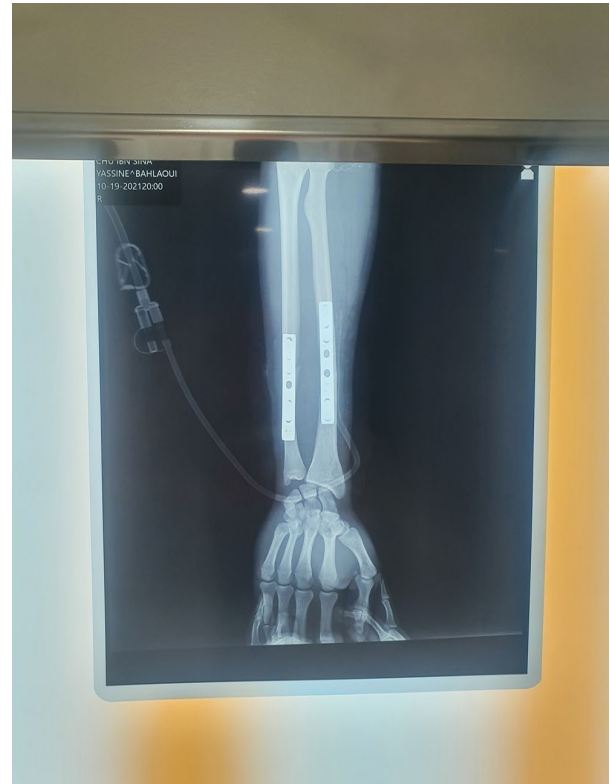

Figure 4. Osteosynthesis with Locked Plates

## Results

The immediate post-operative follow-up was simple, with no skin disorders, neurological deficit or sepsis. The splint was removed after 45

days. For the two patients, with a follow-up of 8 and 9 months respectively, there was a good clinical evolution, with complete recovery of the mobility of the various joints of the upper limb.

For the two patients, the treatment consisted of closed internal osteosynthesis of the humerus using an antegrade intramedullary nail and internal osteosynthesis using two special radius plates for the radius and ulna.

The two patients received analgesic treatment, antioedematous and antibiotic prophylaxis for 48 hours.

The removal of the redon drain was done after 2 days and the patients were then declared discharged. They are currently being followed in consultation.

Consolidation of bone lesions was assessed by depending on the location of the fracture. The consolidation of the humerus was an average of four months (3.5–3.5 months), and 5 months (4–6 months) in both forearm bones. No postoperative radial paralysis was noted. The Lange and Foster classification taking into account the fracture and functional restoration of the upper limb was used for the evaluation of our patients.

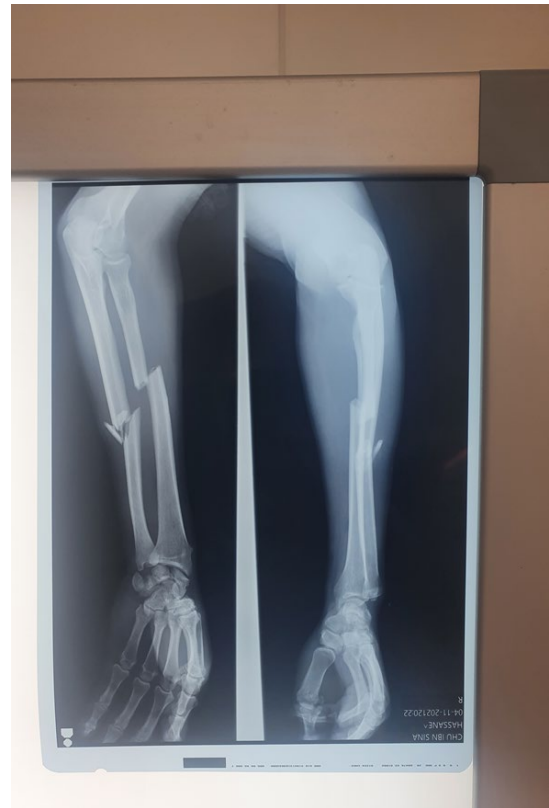

Figure 5. X-Ray of the Forearm Fracture of the Second Patient

## Fracture de la diaphyse de l'humérus

- Jeune, Agée
- AVP, Sport
- Suivant déplacée
- Ostéosynthèse
- Risque: voisinage dangereux du nerf radial

 A diagram illustrating the mechanisms of humerus fractures. It shows four types of fractures: 'Choc direct' (direct impact), 'Flexion' (bending), 'Torsion' (twisting), and 'Tracas' (twisting with impact). The radial nerve (N. Radial) is shown in red, highlighting its proximity to the fracture sites. An inset image shows a patient with a humerus fracture. A logo for 'CENTRE HOSPITALIER' is visible in the bottom right corner.

Figure 6. Mechanism of the Humerus Fractures

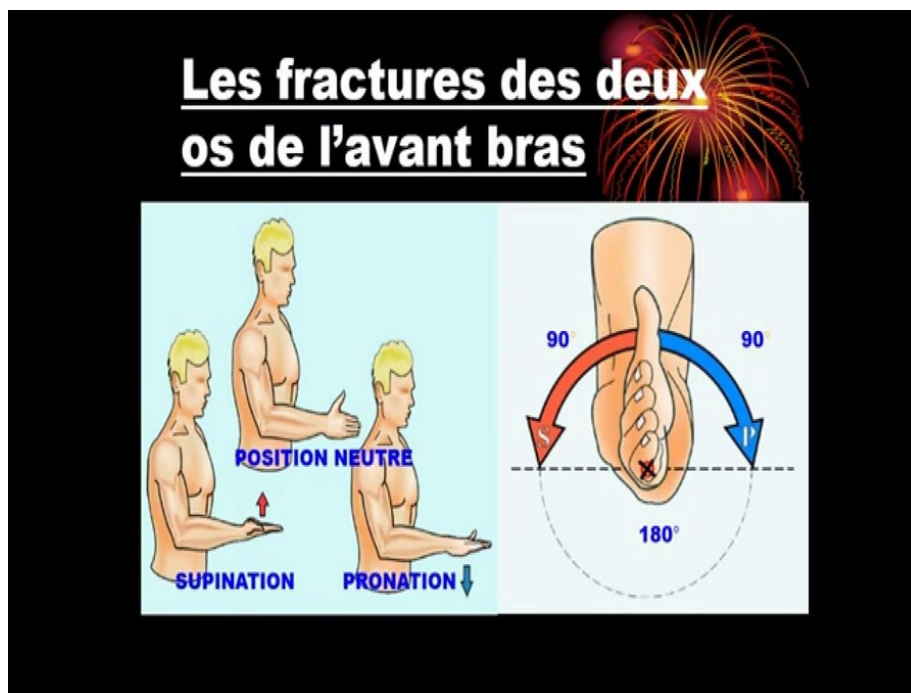


Figure 7. Mechanism of the Forearm Fractures

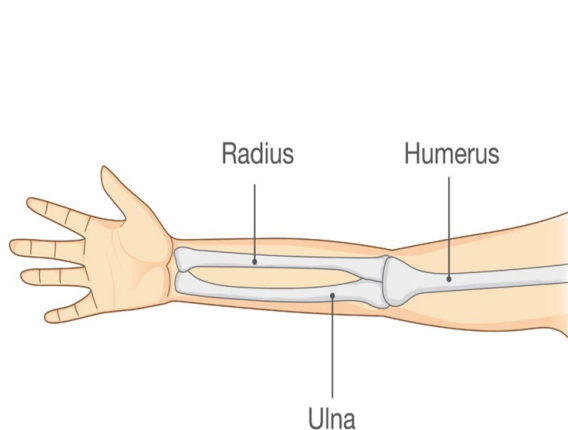


Figure 8. Elbow Anatomy

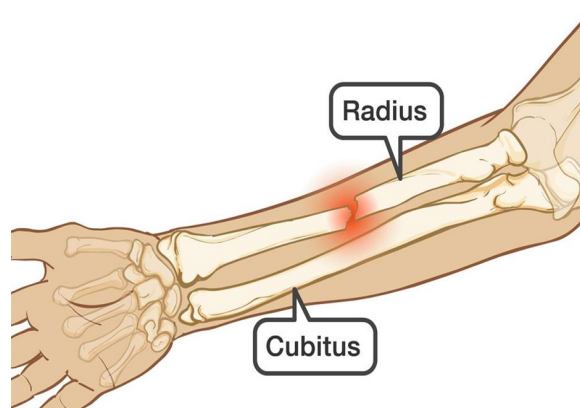


Figure 9. Radial Shaft Fracture

## Discussion

The floating elbow reflects an association of a fracture humerus to an ipsilateral fracture of one or both bones of the the forearm. Stanitsky and Micheli in 1980 were the first to use the term "floating elbow".

In general, it is established that the homolaterality of the lesions determines the

floating elbow. For some authors, at the fracture the diaphysis or the lower extremity of the two bones of the forearm must be associated with a fracture of the humerus pallet. This demonstrates the confusion that persists to find a unanimous and formal definition of the floating elbow.

This dissociation of the elbow from the rest of the upper limb constitutes the main element of recognition among a type of staged fractures of the upper limb. The first descriptions of this trauma have been reported in the child and the adolescent. This severe staged trauma of the upper limb is a rare occurrence in adults. This study confirms the rarity of these lesions.

The frequency of this trauma in adults is difficult to appreciate given the few series reported in the literature.

Brumback et al. (1986) in a context of polytrauma find six cases out of 61 humeral fractures, Kempf et al. (1994) one out of 41 cases and Heim et al. (1993) ten out of 127 humeral fractures from a general collective. Flynn et al. (1974) find a single floating elbow on 331 supracondylar and Palmer fractures et al. (1978) collected four cases out of 78 supracondylar fractures.

From an anatomopathological point of view, the main lesions listed in the floating elbow are varied depending on whether it is of children or adults. In children, it is often closed or even open humeral supracondylar fractures

displaced associated with displaced diaphyseal fractures of the two bones or one forearm bone (Galeazzi or Monteggia).

On the other hand, the two patients injuries of the floating elbow in our series were all closed diaphyseal fractures.

In adults, Rogers et al. distinguish two types injuries:

- Type I associating humeral diaphyseal, ulnar and radial fractures
- Type II is characterized by the association of an humeral diaphysis fracture and an antebrachial articular fracture.

This classification does not include metaphyseal locations. Gleizes et al. (1998) distinguish true floating elbows where the lesions are tridiaphyseal involving the humerus, ulna and radius of floating elbow derivatives where fractures are

bidiaphyseal interesting humerus and ulna or radius.

This classification also does not include metaphyseal locations and does not take into account joint involvement.

However, Agarwal and Chadha find that any description of a floating trauma regardless of its site must specify the site of the fracture, the joint damage and the soft lesions parts. This will help to predict better the long-term functional outcomes and make comparisons of the prognosis with other more precise and scientific centers.

Thus Agarwal and Chadha proposed a classification universal for floating injuries of the extremities incorporating.

For example, S1A000 represents a diaphyseal lesion with a minimal soft tissue damage with prognosis relatively good while S3A203c would indicate impairment severe limbs where there is a metaphyseal fracture with intra-articular extension at both fracture sites and extensive soft tissue involvement, including vascular with a serious prognosis.

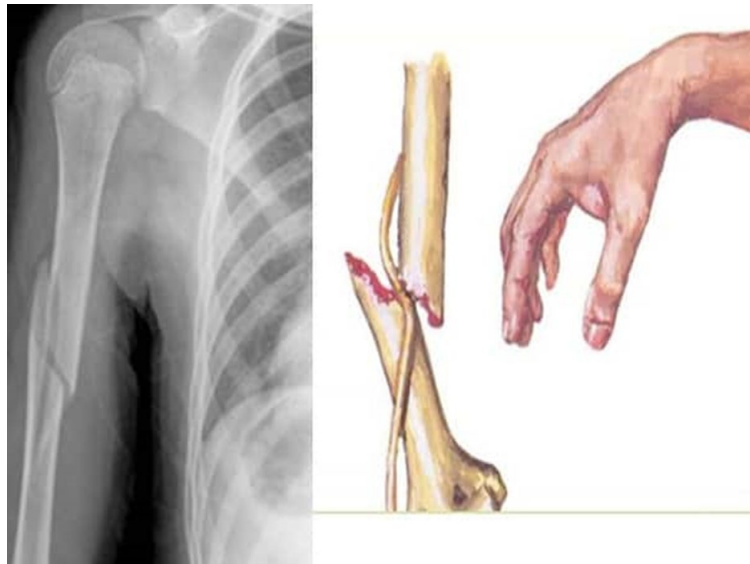
We agree with the authors who recommend this sequence: the humeral diaphysis must be osteosynthesised systematically and first. More incidentally, for the sake of technical simplicity, the same method of osteosynthesis is if possible to be preferred for the whole brachial and antebrachial foci. In front of a widely open lesion, external fixation may be required on both brachial and ulnar levels with temporary elbow bypass.

In front of a bidiaphyseal floating elbow without main skin lesion, the humeral then ulnar and finally radial fracture benefit from osteosynthesis by screwed compression plate, with patient arm in the supine position, in a single installation and this especially since there is radial paralysis. Humerus and ulna can also benefit from osteosynthesis by centromedullary nailing, possibly in a retrograde way for the first, and distaloproximal for the second from the same posterior approach.

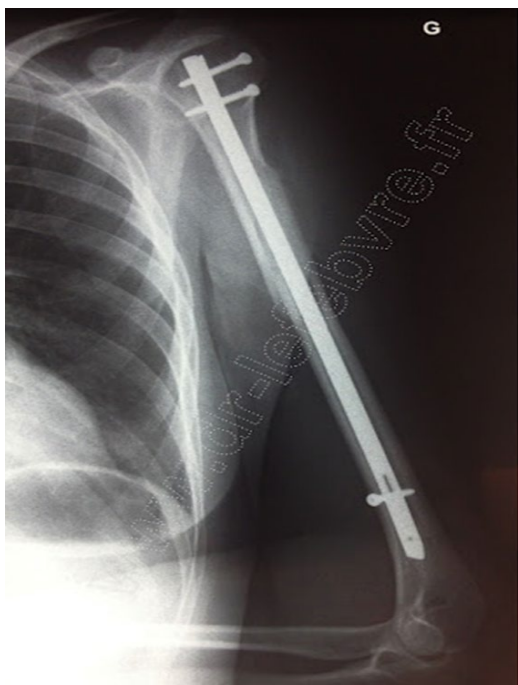
When the joint component is complex and/or comminuted (ulnar metaphyseal-epiphyseal

fracture, humeral pallet) a double installation is necessary. Supine dorsal are made the diaphyseal humeral fixations and radial, then lateral (or prone) reconstruction ulnar epiphysis. Yokoyama et al. point out that elbow injuries floating are providers of many complications such infection (one case), pseudarthrosis (two non-unions humeral and two pseudarthroses of

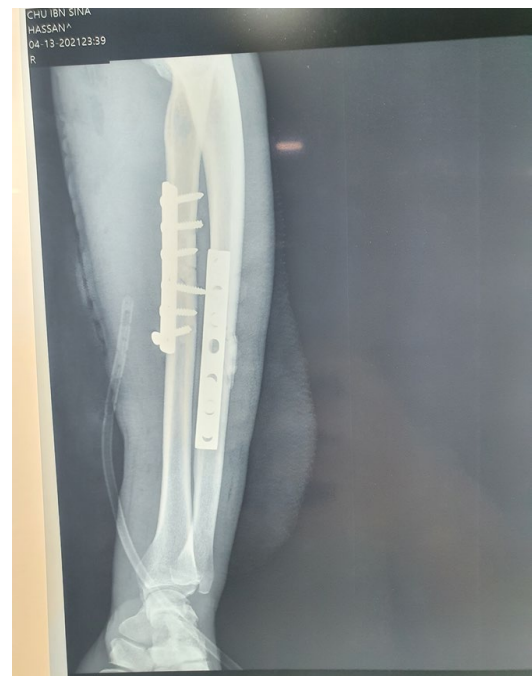the forearm), especially in case of association of lesions of the brachial plexus. Also, they have deplored a case of malunion in ulna varus and a case of forearm refracture. Rogers et al. note seven cases of humeral pseudarthrosis and a case of radial pseudarthrosis.



**Figure 10. Radial Nerve Lesion During an Humerus Fracture**



**Figure 11. X-Ray of an Humerus Nailing**



**Figure 12. Osteosynthesis of the Forearm Fracture with Two Locked Plates**

We observed a case of ulnar septic pseudarthrosis on a stage I open fracture which evolved well after a sequential treatment with self-induced membrane. On the other hand, Harington et al. report no case of infection in their series.

We have obtained satisfactory results with a rate of 67% good and excellent results, lower than that of Harington et al. with 83%, similar to that of Yokoyama et al. who found no prognostic factors that can influence functional results. However, our results were superior to those of the Solomon et al (2003).

whose poor results were correlated with the incidence high level of neurological damage.

Functional rehabilitation remains essential after taking in therapeutic management of this lesional combination; this rehabilitation concerns the joints of the shoulder and the elbow, the proximal and distal radioulnar joints, the wrist joint as well as muscle strength in the hope of recover a functional thoracic limb.

## Conclusion

The floating elbow represents a rare lesional association in traumatology and which poses major prognostic and functional problems. Hence the importance of an accurate diagnosis with rapid and adequate treatment of the injured. Stable osteosynthesis of all the lesions should be recommended, allowing early rehabilitation. The prioritization of the gestures is essential according to the anatomopathologic type of the lesions.

## References

- Brumback, R.J., Bosse, M.J., Poka, A. & Burgess, A.R. (1986). Intramedullary stabilization of humeral shaft fracture in patients with multiple trauma. *Journal of Bone and Joint Surgery. American Volume*, 68(7), 960-970.
- Flynn, J.C., Matthews, J.G. & Benoit, R.L. (1974). Blind pinning of displaced supracondylar fractures of the humerus in children: sixteen years' experience with long-term follow-up. *Journal of Bone and Joint Surgery. American Volume*, 56(A), 263-272.
- Gleizes, V., Camelot, C., Saillant, G. & Benazet, J.P. (1998). *Fractures homolatérales de l'humérus et des deux os de l'avant-bras. In: Le polytraumatisé, le polyfracturé. 4e Journée de traumatologie et d'Orthopédie de la Pitié.* Salpêtrière: Édition Sauramps Médical.
- Heim, D., Herkertf-Hess, P. & Regazzoni, P. (1993). Surgical treatment of humeral shaft fracture: the Basel experience. *Journal of Trauma*, 35, 226-232.
- Kempf, I., Heckel, T.H., Pidorz, L., Taglang, G. & Grosse, A. (1994). L'enclouage verrouillé selon Seidel des fractures diaphysaires humérales. *Revue de Chirurgie Orthopédique et Réparatrice de l'Appareil Moteur*, 80, 5-13.
- Palmer, E.E., Niemann, K.M., Vesely, D. & Armstrong, J.H. (1978). Supracondylar fracture of the humerus in children. *Journal of Bone and Joint Surgery. American Volume*, 60(5), 653-656. <https://doi.org/10.2106/JBJS.G.01354>
- Solomon, H.B., Zadnik, M. & Eglseider, W. (2003). A review of outcomes in 18 patients with floating elbow. *Journal of Orthopaedic Trauma*, 17(8), 563-570. <https://doi.org/10.1097/00005131-200309000-00004>