



PRECISION DENTAL MEDICINE

The effect of the interproximal creeping attachment with VISTA technique in the anterior mandible: A case report with 4 years follow up



Tiago Marques^{1*}, Nuno Santos¹, Manuel Sousa², Javier Montero³, André Correia¹

¹ Universidade Católica Portuguesa, Faculty of Dental Medicine, Center for Interdisciplinary Research in Health, Portugal.

² Universidade Católica Portuguesa, Faculty of Dental Medicine, Portugal.

³ Universidad de Salamanca, Faculty of Medicine, Department of Surgery, Salamanca, Spain

Background

Gingival recession is a common manifestation in most populations. The mechanism by which gingival recession occurs is not well understood but it seems to be complex and multifactorial. The main etiological factors are the accumulation of dental plaque biofilm with the resulting inflammatory periodontal diseases and mechanical trauma due to faulty oral hygiene technique, especially in thin biotypes.[1] Over the time, after periodontal surgery, a known phenomenon named creeping attachment occurs, which increases the attached gingiva width around the tooth and stops the progressive GR.

Case Report

This case report describes the treatment of a vestibular recession associated with interdental bone loss, with VISTA technique associated with a connective tissue graft. The case was evaluated at 3, 9 months and 48 months after the surgery clinically complete root coverage and increased thickness of keratinized tissue were achieved, and the interdental papilla was augmented improving the soft tissue quality for future orthodontic treatment.(Fig1)

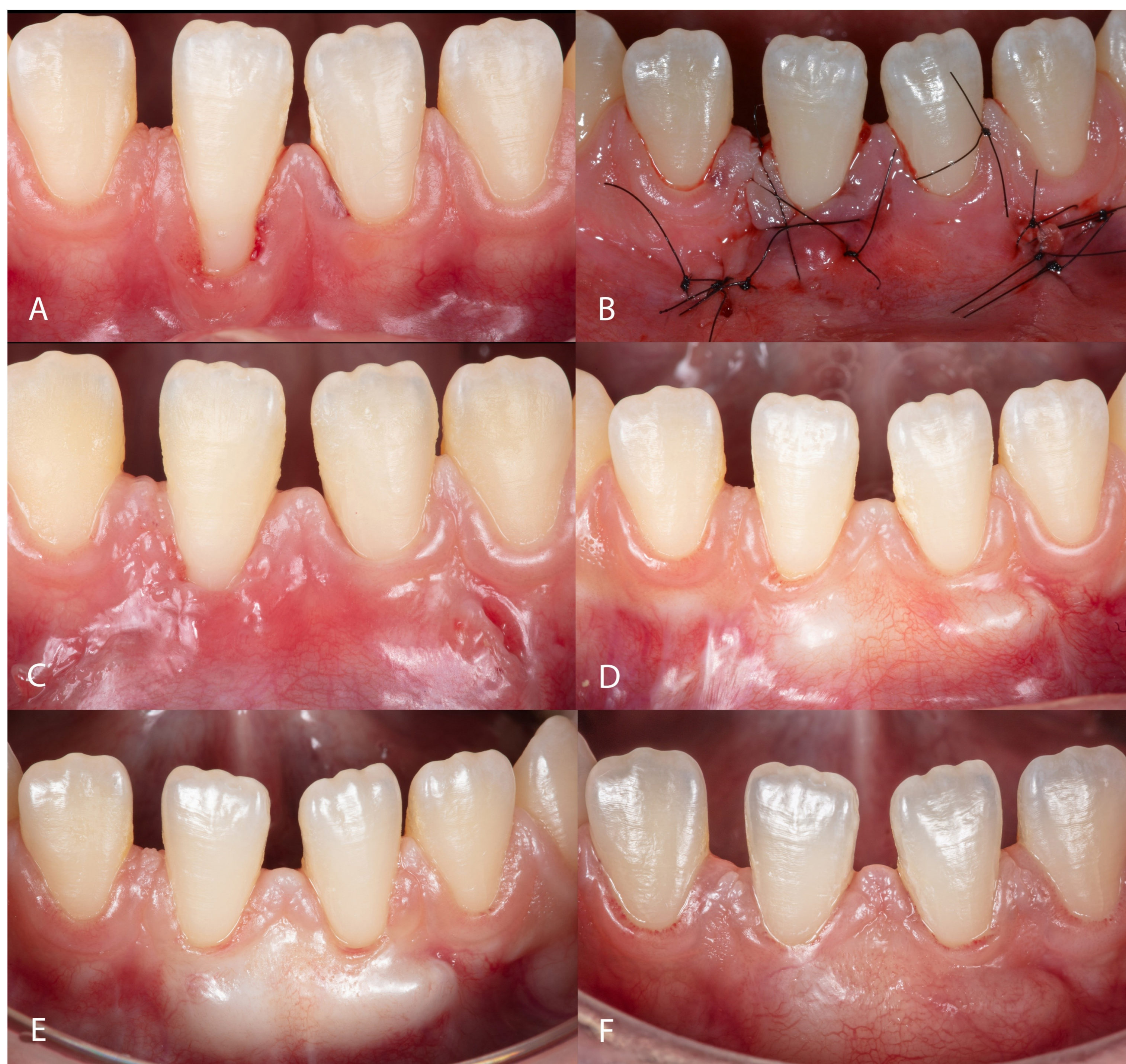

Figure 1: A)Initial image of buccal recession tooth 41; B) Suture end of the surgery; C) 14 days post operative D) Clinical outcome after 3 months; E) Clinical outcome after 6 months; F) Follow up 48 months

REFERENCES

1.Marques T, Santos NM, Fialho J, Montero J, Correia A. A new digital evaluation protocol applied in a retrospective analysis of periodontal plastic surgery of gingival recessions. Sci Rep. 2021 Oct 14;11(1):20399.

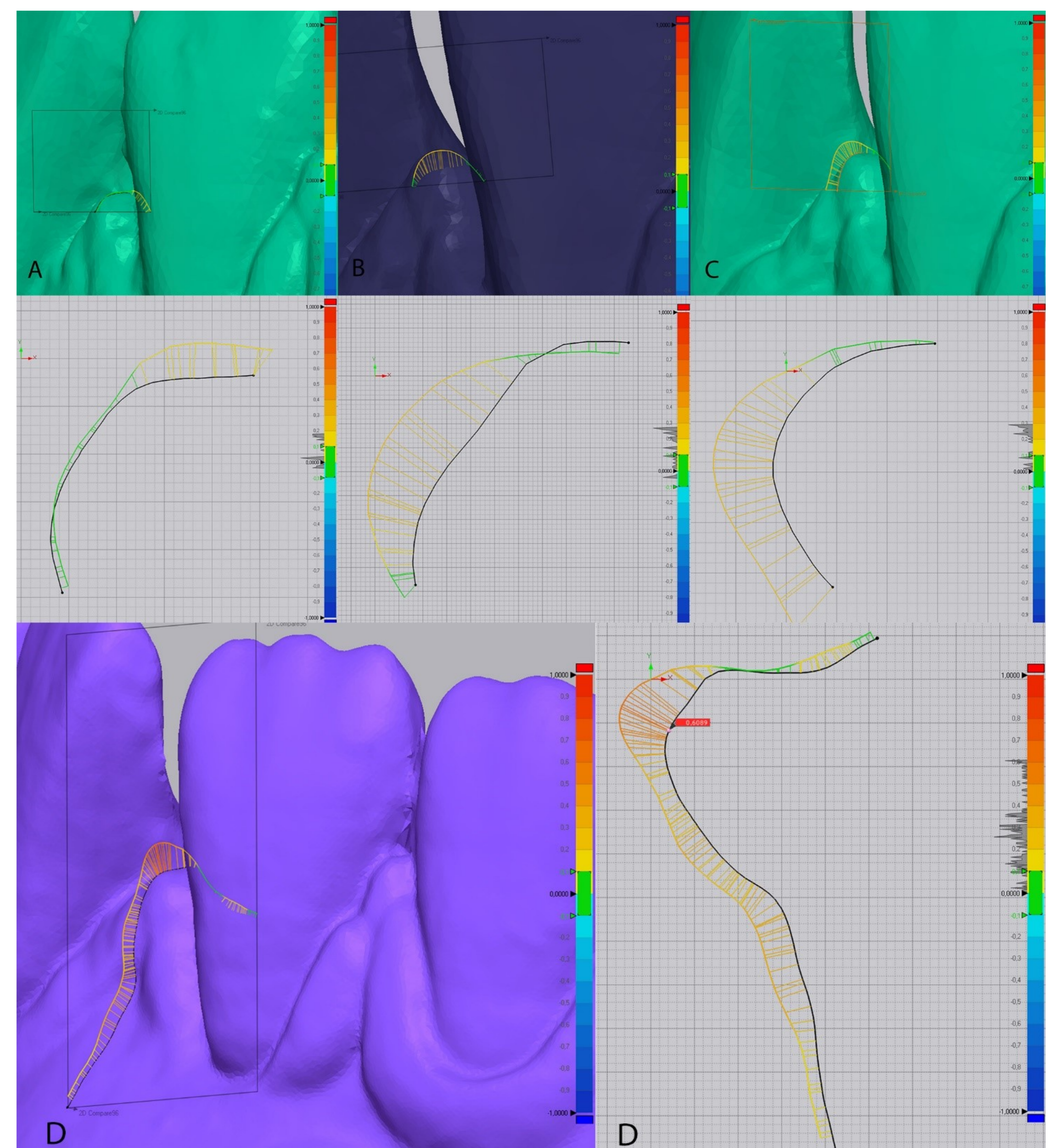


Fig. 2 - A) Interproximal creep attachment at 3 months, B) 3 months to 6 months C) 6 months to 48 Months, D) Interproximal creep attachment from 3 months to 48 Months E) Interdental Papilla Height Gain

Conclusion

The purpose of the current case report was to digitally evaluate the creep attachment effect, either in buccal as interproximal sites, assessed on long-term (48 months), and to present the clinicians with the result obtained with a minimally invasive treatment using the tunnel technique. VISTA technique associated with a connective tissue graft to reconstruct vertically papilla is a promising alternative for minimally invasive treatment and stable after 4 years.

