



10.5281/
zenodo.8230976

Treatment of symptomatic calcaneal lipoma with osseoscopy using a synthetic allograft

Emin Özkul¹ - Serhat Elçi² - Mehmet Onur Ziyadanoğulları³ - Mehmet Bulut⁴ - Ramazan Atıç¹

Correspondence

Serhat Elçi, Department of Orthopaedics and Traumatology, Sultan Private Hospital, Diyarbakır, Turkey.

e-mail

serhatelci@gmail.com

Received: 02 February 2023

Revised: 14 February 2023

Accepted: 25 February 2023

Published: 9 August 2023

Keywords

- ⇒ Calcaneus
- ⇒ Osseoscopy
- ⇒ Synthetic allograft

ORCID ID of the author(s):

EÖ: 0000-0003-2149-8154
SE: 0000-0002-3617-4227
MOZ: 0000-0001-5338-8000
MB: 0000-0002-0408-610X
RA: 0000-0002-7814-822X

1. Department of Orthopaedics and Traumatology, Dicle University Medical Faculty, Diyarbakır, Turkey.
2. Department of Orthopaedics and Traumatology, Sultan Private Hospital, Diyarbakır, Turkey.
3. Department of Orthopaedics and Traumatology, Gazi Yaşargil Training and Research Hospital, Diyarbakır, Turkey.
4. Department of Orthopaedics and Traumatology, Medical Park Hospital, Kocaeli, Turkey.

Abstract

Objective: This study evaluated the results of symptomatic calcaneal lipoma patients treated with a recently introduced minimally invasive arthroscopic method.

Materials and methods: Seven patients treated with osseoscopy in our clinic for calcaneal lipoma between 2013 and 2018 were evaluated. The median age of the patients was 37.7 years and five were male. The common complaint of the patients was pain that partially disrupted daily life. Surgery was utilized for patients who did not respond to conservative methods (sports restriction, partial weight bearing, and heel support) had persistent pain longer than 3 months and had a risk of impending fracture (>30% loss in trabecular bones).

Results: The mean follow-up period after surgery was 21 (12–33) months. In all patients, the location of the ICL was in Ward's triangle and the mean size was 28.8 (20–43) mm. According to Milgram's classification, three ICLs were stage I, two were stage II, and two were stage III. The radiological result was evaluated using the classification system of Glutting and Chang. There was no persistent cyst and no recurrence. The radiological success rate was 100%. The mean ankle-hindfoot scale score (max. 100 pts) increased from a preoperative 74.7 ± 5.3 points (range: 69–83) to a postoperative 96.7 ± 2.62 points (range: 93–100).

Conclusions: In the treatment of calcaneal lipoma, treatment with osseoscopy is easy and fast, has low complication rates, and is a cosmetically desirable alternative. The use of synthetic allografts to fill the cavity is a safe, inexpensive, and easy alternative.

Cite as: Özkul E, Elçi S, Ziyadanoğulları MO, et al. Treatment of symptomatic calcaneal lipoma with osseoscopy using a synthetic allograft. J Clin Trials Exp Investig. 2023;2(3):138-143.

Introduction

The incidence of calcaneal intraosseous lipomas is less than 1% of primary bone tumors. The etiology of the disease is unknown. Although it is thought to be a primary bone tumor, it may occur as a reaction after trauma or bone infarction. Although there is no consensus, it may be more common in men (1-4).

The calcaneus is the second most common location for intraosseous lipoma and is usually asymptomatic. These patients may have aching pain or swelling on their heels. It rarely presents as a pathologic fracture. Calcaneal lipomas are radiologically seen as well-circumscribed calcified masses that are flanked by a thin sclerosis (1,4,5).

Treatment options for asymptomatic calcaneal lipoma are controversial. Surgical treatment is recommended for painful lesions that are not responsive to a conservative approach and at risk for pathological fracture. In surgical treatment, open curettage and grafting are usually performed. The calcaneus is weakened more due to the opening of cortical window. In addition, wound problems and sural nerve damage often occur after surgery (6-9).

A minimally invasive arthroscopic method called osseoscopy is another surgical technique that we introduced here. With this method, the tumor can be reached through small incisions with the help of an arthroscope resulting in less scar tissue and better cosmetic results. Bone tissue is less damaged and subsequent pain after this method is less pronounced. The aim of the present study is to analyze the results

of symptomatic calcaneal lipoma patients treated with osseoscopy.

Materials and methods

Seven patients treated with osseoscopy in our clinic for calcaneal lipoma between 2013 and 2018 were evaluated. The median age of the patients was 37.7 years (range 21-63) and five were male. The common complaint of the patients was pain that partially disrupted daily life (**Table 1**).

We assessed tumor size and location, the onset of symptoms, image findings, Milgram’s classification, pain relief after surgery, and complications. Milgram classified intraosseous lipoma into three stages (11). Stage I lesions are purely radiolucent and contain viable lipocytes and bony trabeculae without any necrosis. Stage II lesions are partially radiolucent, have some calcification, and display a mixture of necrotic and viable lipocytes. Stage III lesions are larger calcifications and the fat component is fully necrotic.

Radiographs (anteroposterior and lateral), computed tomography (CT), and MRI were used for the diagnosis of calcaneal lipoma (**Figures 1, 2**). This was subsequently confirmed by histological examination. Surgery was used for patients (1) who did not respond to conservative methods (sports restriction, partial weight bearing, and heel support), (2) who had persistent pain longer than 3 months, and (3) who had a risk of impending fracture (>30% loss in the trabecular bones).

Table 1: AOFAS score of the patients

Patient	Age/Gender	Side	Milgram stage	Size (mm)	AOFAS Score (postop)	Follow-up (Months)
1	21/M	R	I	30	97	15
2	25/M	R	I	25	100	19
3	28/M	R	I	32	95	22
4	31/M	L	III	28	97	12
5	44/F	L	III	43	95	33
6	52/F	L	II	20	93	26
7	63/M	R	II	24	100	20

*AOFAS: American Orthopedic Foot and Ankle Society

Table 2: Advantages and Limitations of Calcaneal Osseoscopy

1. Minimally invasive procedure: less soft-tissue dissection, better cosmetic outcome, and lower risk for infection and iatrogenic sural nerve damage.
2. Synthetic allografts are cheaper than other allografts and can be obtained in the desired amount.
3. Compared with traditional open surgery for intraosseous lipoma, osseoscopy is a more demanding surgical procedure requiring experience in arthroscopic techniques, foot and ankle surgery, and tumor orthopedics.
4. Equipment for filling grafts into the cavity, like a speculum, is required.
5. It is more difficult to fill the cavity since the synthetic grafts disintegrated faster than autografts and allografts.

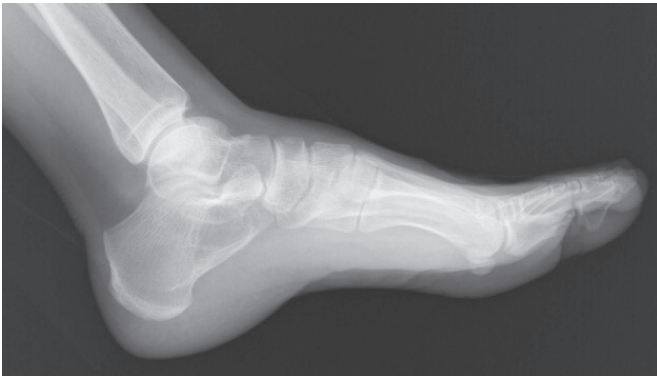

Figure 1: Lateral preoperative X-ray of a calcaneal lipoma

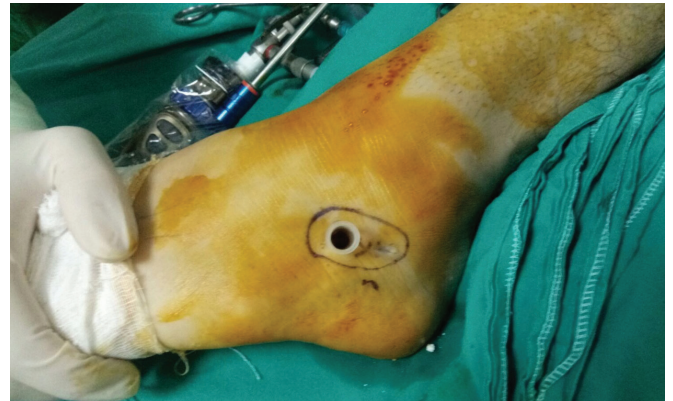


Figure 3: Endoscopic image of a calcaneal lipoma

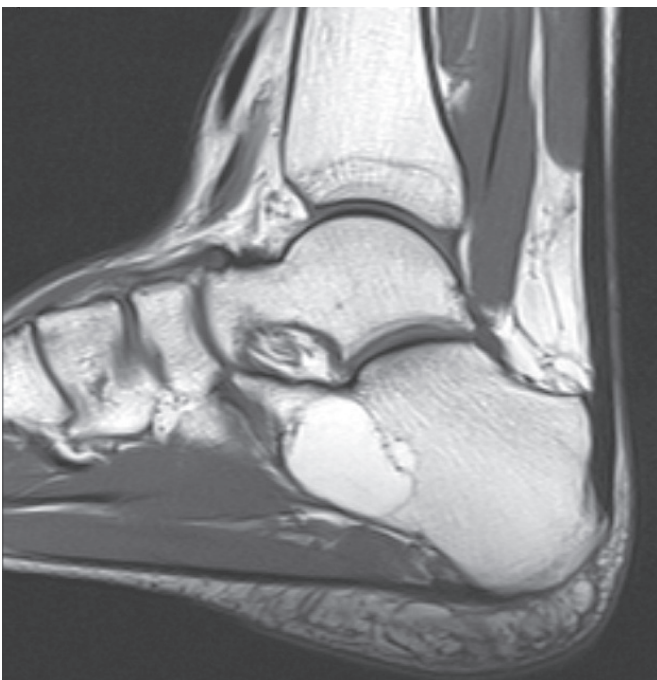

Figure 2: Sagittal T2 MRI image of a calcaneal lipoma

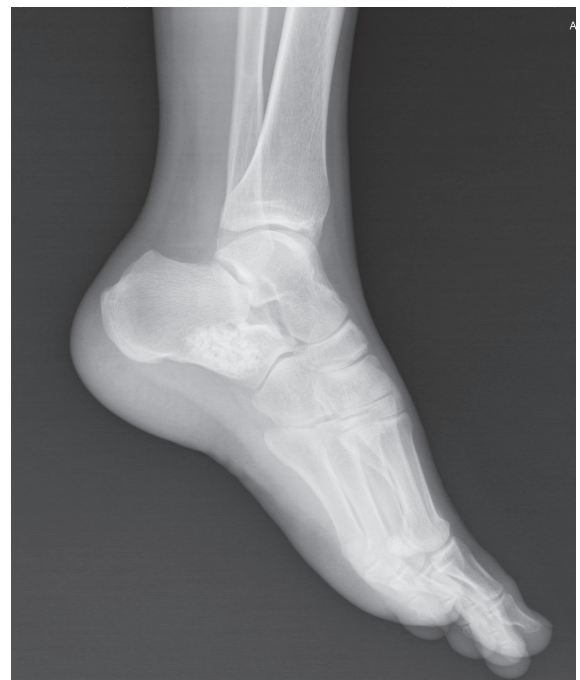

Figure 4: Lateral postoperative X-ray of a calcaneal lipoma

The surgery was applied under a tourniquet while the patients were in a semi-lateral position under spinal anesthesia. The borders of the lesion were determined using scopy and mapped with a sterile pen. After the incision, the skin and peroneal tendons were punctured using a 3.7 mm drill with caution. It was expanded with a semi-sharp obturator and portals were opened. Depending on the size of the bone lesion, an arthroscope ranging from 2.7 to 4.0 mm in diameter can be used. After the sample was taken, the cavity was cleaned with the help of an arthroscopic shaver. In the filling of the cavity, artificial bone substitute β -tricalcium phosphate, Powerbone Granule® (Bonegraft Biological Materials Izmir, Turkey) was used. An average graft of 20 cc (15-30 cc) was needed for each case. An ear speculum was used to fill the grafts. The histological work-up confirmed the suspected initial diagnoses in all cases (**Figure 3**). A short-term plaster splint was applied after the operation followed by semi-rigid short leg orthosis. Six weeks partial load was recommended. The patient was advised to avoid contact sports for three months. All patients were available for clinical and radiological examination and completed the functional analysis. Follow-up examinations were performed at 6 weeks, 12 weeks, 6 months, and 12 months with lateral and axial radiographies (**Figure 4**). CT and MRI were not ordered for follow-up. The functional outcome of all patients was measured using the American Orthopedic Foot and Ankle Society (AOFAS) Ankle-Hindfoot Scale both preoperatively and at final follow-up. The radiological result was evaluated using the classification system of Glutting and Chang (12).

Statistical analysis (average, standard deviation, and frequency) was carried out using SPSS (Statistical Package for the Social Sciences) 21.0 for Windows 7.

Statistical analysis

The data obtained in this study were analyzed with the licensed IBM SPSS 21 package program. Chi-Square analysis was applied when examining the relationships between groups of nominal variables. In 2x2 tables, Fisher's Exact Test was used in cases where the expected values in the cells did not have sufficient volume, and in RxC tables, Pearson Chi-Square analysis was applied with the help of Monte Carlo Simulation. (*Since 20% of the expected value in the cells was less than 5, chi-square analysis was performed with the help of Monte Carlo Simulation.) When interpreting the results, 0.05 was used as the

significance level; In the case of $p < 0.05$, it is stated that there is a significant relationship and in case of $p > 0.05$, it is stated that there is no significant relationship.

Results

The mean follow-up period after surgery was 21 (12–33) months. In all patients, the location of the ICL was in Ward's triangle and the mean size was 28.8 (20–43) mm. According to Milgram's classification (11), three ICLs were stage I, two were stage II, and two were stage III. The mean operation time in our study group was 45 minutes (35–80 minutes). Heel pain disappeared soon after surgery in all cases. The radiological result was evaluated using the classification system of Glutting and Chang (12). Radiographic examinations showed desirable bony solidification in all cases. There was no persistent cyst and no recurrence. The radiological success rate was 100%.

The mean ankle-hind foot scale score (max. 100 pts) improved from a preoperative 74.7 ± 5.3 points (range: 69–83) to a postoperative 96.7 ± 2.62 points (range: 93–100). Potential surgical complications such as infection, sural nerve injury, or delayed wound healing did not occur. All patients were allowed full weight bearing and were able to return to everyday activities without orthopedic aids 6 weeks after surgery.

Discussion

There are three theories about the etiology of intraosseous calcaneal lipomas (ICL), which constitute less than 1% of primary bone tumors (1–4). The first is that the tumor might be a posttraumatic bone reaction. This opinion has not garnered support because the majority of patients do not have a trauma history (13). The second theory is the healing of a bone infarct. This theory has also not been accepted because the bone infarct placement is mostly in the posterior part (14). According to the third most accepted theory, this lesion is a primary benign tumor of the bone (1,14,15). Only one of our patients had a trauma history.

The calcaneus is the second most common site of intraosseous lipoma in the body and the most common site of the foot bones. Although these patients are mostly asymptomatic, aching pain, swelling, and, rarely, a pathologic fracture can be seen in the heel. Calcaneal lipomas are radiologically seen as well-defined calcified masses surrounded by sclerosis without periosteal reaction. Differential diagnosis includes aneurysmal bone cyst, unicameral bone cyst, and other cystic lesions (1,4,5). Radiographic findings of intraosseous lipomas are typical, but not specific.

Therefore, the diagnosis requires not only x-rays, but also MRI and CT. MRI is very helpful for differential diagnosis especially with a unicameral bone cyst. A preoperative biopsy can be performed if there is doubt about the diagnosis (15-16).

In the treatment of this disease, while a conservative approach is preferred for asymptomatic patients, surgery is recommended for those with a pathologic fracture risk and who have painful lesions that do not respond to treatment. A critical size for ICL has been defined as a lesion that extends the full breadth of the calcaneus laterally to medially in the coronal plane, while occupying at least 30% of the anteroposterior length of the calcaneus (17).

Usually, curettage or open curettage and grafting are used in surgical treatment. The efficacy of alcohol and similar local adjuvant applications has not been shown. Although many successful results are obtained with this method, the calcaneus is weakened due to the cortical window opening and wound problems and sural nerve damage can be seen (6-9,11).

Osseoscopy, a minimally invasive method performed for cysts and lipomas seen in the calcaneus, reduces the incidence of wound problems and produces less scar tissue, resulting in better cosmetic results than open surgery. This method has been proposed as an alternative to open surgery for appropriate patients because it shortens the non-weight bearing period due to less cortical damage and reduces the risk of pathological fractures (10,17).

The need for arthroscopic and osseoscopy experience, non-standard procedures, can cause problems. Another disadvantage is that it is not suitable for small lesions. If used in such cases, the portals are close to each other and may unite and cause a fracture. Mini-open surgery, osseoscopy with a small-joint arthroscope of 2.7 mm, can be used to prevent this. In addition, supportive equipment unfamiliar to orthopedists like an ear speculum may be needed to fill the cavity after mass excision (Table 1). Because human-derived allografts cannot be supplied in our country, artificial bone substitute β -tricalcium phosphate, Powerbone Granule® (Bone graft Biological Materials Izmir, Turkey) was used to fill the formed cavity. The most important advantages of these grafts were their low cost and ready availability. Their reduced durability compared to human-derived allografts and easy disintegration after contact with fluid were the most important disadvantages. There was no delay in bone healing in our series of synthetic grafts. The patients returned to daily life at the same time as patients using other grafts. Another study

used synthetic grafts for the treatment of lipoma and calcaneal cysts. In that study, successful results were reported and the grafts were resorbed within 6 months (17). In the present study, the graft resorption took approximately one year.

A limitation of this study is that it consists of few cases because we examined a rare tumor, and therefore treatment methods cannot be readily compared.

Conclusions

Osseoscopy is an easy and fast alternative surgical method for the treatment of calcaneal lipoma with low complication rates and better cosmetic results than traditional methods. The use of a synthetic allograft to fill the cavity is an easy, safe, and inexpensive alternative.

Conflict of interest:

The authors report no conflict of interest.

Funding source:

There is no source of funding available.

Ethical approval:

The study protocols were approved by Dicle University Faculty of Medicine local ethics committee

Acknowledgment:

No

Peer-review:

Externally. Evaluated by independent reviewers working in at least two different institutions appointed by the field editor.

Contributions

Research concept and design: **EÖ, SE, MOZ**

Data analysis and interpretation: **MB, RA, SE**

Collection and/or assembly of data: **SE, RA, MOZ**

Writing the article: **EÖ, MB, SE**

Critical revision of the article: **RA, MOZ, MB**

Final approval of the article: **EÖ, MB, RA**

References

1. Unni K. Lipoma and liposarcoma. In: Unni K (ed). Dahlin's bone tumours. General aspects and data on 11087 cases, 5th ed, Lipponcott-Raven, Philadelphia, 1996;349-53.
2. Murphey MD, Carroll JF, Flemming DJ, Pope TL, Gannon FH, Kransdorf MJ. From the archives of the AFIP: benign

- musculoskeletal lipomatous lesions. *Radiographics*. 2004;24(5):1433-66.
3. Kapukaya A, Subasi M, Dabak N, Ozkul E. Osseous lipoma: eleven new cases and review of the literature. *Acta Orthop Belg*. 2006;72(5):603-14.
 4. Fletcher C, Bridge JA, Hogendoorn PCW, Mertens F. World Health Organization classification of tumours. Lyon, France: WHO, 2013.
 5. Freyschmidt JO, Ostertag H, Jundt G. Knochenutmoren mit Kiefertumoren: Klinik-Radiologie-Pathologie. Berlin: Springer, 2010.
 6. Weger C, Frings A, Friesenbichler J, Grimer R, Andreou D, Machacek F, et al. Osteolytic lesions of the calcaneus: results from a multicentre study. *Int Orthop*. 2013;37(9):1851-6.
 7. Toepfer A, Lenze U, Harrasser N. Calcaneal Ossoscopy. *Arthrosc Tech*. 2016;20(5):627-31.
 8. D'Hooghe P, Krivokapic B, Dzendrowskyj P, Hassoun K, Bukva B, Landreau P. Endoscopic surgery in athletes with a symptomatic calcaneal lipoma. *Knee Surg Sports Traumatol Arthrosc*. 2017;25(6):1873-77.
 9. Toepfer A, Lenze U, Gerdesmeyer L, Pohlig F, Harrasser N. Endoscopic resection and allografting for benign osteolytic lesions of the calcaneus. *Springerplus*. 2016;11(5):427.
 10. Futani H, Fukunaga S, Nishio S, Yagi M, Yoshiya S. Successful treatment of bilateral calcaneal intraosseous lipomas using endoscopically assisted tumor resection. *Anticancer Res*. 2007;27(6C):4311-14.
 11. Milgram JW: Intraosseous lipomas. A clinicopathologic study of 66 cases. *Clin Orthop Relat Res* 1988;1988(231):277-302.
 12. Chang CH, Stanton RP, Glutting J. Unicameral bone cysts treated by injection of bone marrow or methylprednisolone. *J Bone Joint Surg Br*. 2002;84(3):407-12.
 13. Bagatur AE, Yalcinkaya M, Dogan A, Gur S, Mumcuoglu E, Albayrak M. Surgery is not always necessary in intraosseous lipoma. *Orthopedics*. 2010;33(5):12.
 14. Hart JAL. Intraosseous lipoma. *J Bone Joint Surg Br*. 1973;55:624-32.
 15. Abraham-Zadeh R, Klein RM, Leslie D, Norman A. Characteristics of calcaneal bone infarction: an MR imaging investigation. *Skeletal Radiol*. 1998;27:321-4.
 16. Innami K, Takao M, Miyamoto W, Abe S, Nishi H, Matsushita T. Endoscopic surgery for young athletes with symptomatic unicameral bone cyst of the calcaneus. *Am J Sports Med*. 2011;39(3):575-81.
 17. Muramatsu K, Tominaga Y, Hashimoto T, Taguchi T. Symptomatic intraosseous lipoma in the calcaneus. *Anticancer Res*. 2014;34(2):963-6.

Publisher's Note: Unico's Medicine remains neutral with regard to jurisdictional claims in published maps and institutional affiliations.