

## Original Research Article

# Ultrasonographic evaluation of anatomical variations, of the first dorsal compartment of wrist, and its correlation with de Quervain's disease recurrence in Indian population: a hospital based longitudinal study

Soutrik Mukherjee\*, Amlan J. Roy, Prasun Mandal

Department of Orthopaedics, North Bengal Medical College and Hospital, West Bengal, India

**Received:** 04 June 2023

**Revised:** 03 July 2023

**Accepted:** 06 July 2023

### \*Correspondence:

Dr. Soutrik Mukherjee,

E-mail: [drsoutrikmukherjee@gmail.com](mailto:drsoutrikmukherjee@gmail.com)

**Copyright:** © the author(s), publisher and licensee Medip Academy. This is an open-access article distributed under the terms of the Creative Commons Attribution Non-Commercial License, which permits unrestricted non-commercial use, distribution, and reproduction in any medium, provided the original work is properly cited.

## ABSTRACT

**Background:** de Quervain's disease is a commonly encountered debilitating condition mostly treated conservatively. Cadaveric studies have revealed anatomical variations in the first dorsal compartment of the wrist; however, a causal association between the variants and recurrence of the disease has not been established. An ultrasonographic assessment of the first dorsal compartment of the wrist was done, to correlate the response to treatment, of the different anatomical variants.

**Methods:** 106 wrists were included in the study after clinically confirming de Quervain's disease. All were injected with 20mg of methylprednisolone acetate in the first dorsal compartment of the wrist and were followed up. Patients who were pain free for at least six months, as well as patients who did not respond or had a recurrence of disease within eight to twelve weeks, were all assessed with ultrasound.

**Results:** 57.54% of the wrists were cured with one injection most of which revealed a tendon arrangement of one abductor pollicis longus (APL) and one extensor pollicis brevis (EPB) and two APL and one EPB without any septation. 32.07% of the wrists did not respond to this treatment and most of them comprised of septations and aberrant compartments with presence of supernumerary tendons.

**Conclusions:** Ultrasonographic assessment of the first dorsal compartment of wrist, of all patients suffering from de Quervain's tenosynovitis must be done to predict the outcome of conservative therapy and customize an optimal treatment modality for the individual anatomical variant.

**Keywords:** de Quervain's tenosynovitis, Radial sided wrist pain, First dorsal compartment of wrist

## INTRODUCTION

de Quervain's disease or stenosing tenosynovitis of the first dorsal compartment of the wrist is a commonly encountered debilitating condition. The commonly used treatment modality is conservative, however with a recurrence of 15–20%.

Cadaveric studies have revealed anatomical variations in the first dorsal compartment of the wrist viz. supernumerary tendon slips, presence of septa, aberrant

compartments and variations in the insertion of tendon slips; which are thought to be important causative factors for the recurrence.<sup>1-10</sup> Abnormal septation of the compartment was first reported by Finkelstein in 1930.<sup>8,9</sup>

Many anatomical and clinical studies have shown the variations of the first dorsal compartment of the wrist and its contents, but a definite causal association between the anatomical variants and recurrence of de Quervain's disease has not been established.<sup>3-20</sup> To predict the recurrence, it is thus important to have a clear knowledge

about the presence of septations, aberrant compartments, aberrant tendons and their relations.

We have done an ultra-sonographic assessment of the anatomy of the first dorsal compartment of the wrist, in patients who have been treated conservatively for de Quervain's disease, with or without recurrence. The purpose was to establish a causal association of the different anatomical variations with recurrence of the symptoms and disease per se; and to provide a detailed information of the contents of the first dorsal compartment of the wrist. This would help to explain and predict the anatomical basis of recurrence of de Quervain's disease in patients who have been treated conservatively for the same; so that we can customize an optimum treatment modality for individuals instead of a universal protocol, and thus curtailing the prolonged morbidity.

## METHODS

A hospital based longitudinal study was done in the department of orthopaedics, North Bengal Medical College and Hospital in a span from October 2017 to November 2018, after proper clearance from the institutional ethics committee. A total of 106 wrists, with 37 bilateral and 32 unilateral wrists; were studied in a study population of 69 patients. There were 62 female patients and 7 male patients. The study population inclusion criteria were all patients within the age range of 30-50 years presenting to the outpatient department with radial sided wrist pain; were objectively diagnosed to be suffering from de Quervain's tenosynovitis by tip of radial styloid process tenderness elicitation and a positive Finkelstein test.<sup>21</sup> Exclusion criterias were any patient with clinical and/or radiographic features suggestive of rheumatoid arthritis, or arthritis in the trapeziometacarpal, scaphotrapeziotrapezoid and radiocarpal joints; patients with features of superficial radial nerve entrapment and intersection syndrome.

All the patients included in the study were treated conservatively with local corticosteroid injection using 20 mg of depot preparation of methylprednisolone acetate and 1 ml lidocaine after proper antiseptic precaution at the radial styloid process. All patients were followed up at four weeks, eight weeks and twelve weeks respectively and evaluated clinically for persistence of symptoms and disability and also to look for recurrence in those patients in whom the disease improved clinically after a single dose of steroid administration. For the wrists that did not show any objective and subjective improvement after the first dose of injection, a repeat injection of identical dosage was given at the radial styloid. A maximum of three injections were repeated in those that did not show any improvement even after two doses of corticosteroid injection. Also for those patients that did undergo remission after a single or two doses of injections but symptoms recurred, within a span of four to eight weeks were given up to a maximum of three injections. All the patients were divided into

smaller groups depending upon their response to the conservative treatment modality.

An ultra-sonographic assessment of the first dorsal compartment of the wrist was done using a 12 Htz probe for all the affected wrists viz. at the end of a six months of pain free duration for the wrists that were rendered completely free of symptoms with one, two or three injections. For the wrists that did not show any clinical improvement throughout as well as for the wrists that showed improvement with each injection however pain and disability recurred, assessment was done at the end of failed third injection.

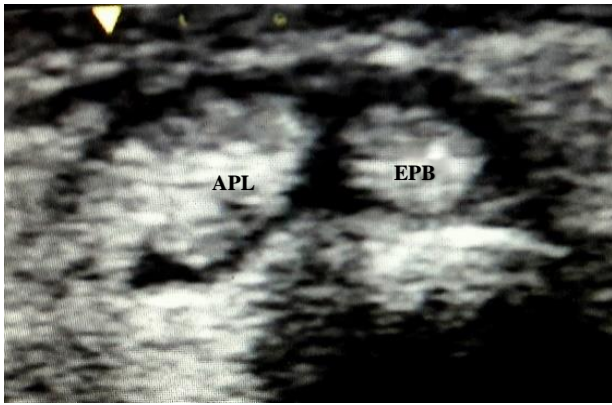
We assessed 106 wrists using 12 Htz ultrasonography probe and searched for the presence of septation(s) in the first dorsal compartment of the wrist and the relationship of the tendons. Extra/aberrant tendons are defined as those which have a separate definite origin and a separate insertion. Additional tendon slips are a part of tendons having only a separate insertion site. It was very much difficult to differentiate aberrant tendons from additional tendon slips using ultrasound, as the origin of the tendons and tendon slips were difficult to delineate due to technical difficulties.

So, aberrant tendons were counted as tendon slips. Tendons and tendon slips of the first dorsal compartment of the wrist were divided functionally into two groups. Tendons and tendon slips that moved with first metacarpophalangeal joint movement were considered as extensor pollicis brevis (EPB), and other tendons or slips were considered as abductor pollicis longus (APL). Septation of the first extensor compartment of the wrist was defined as any division between the tendons or slips extending from the extensor retinaculum to the periosteum of the radius.<sup>22</sup> Bilateral assessments was done in 37 patients (74 wrists) and unilateral assessment was done in 32 wrists. We assessed 60 right and 46 left wristsd.

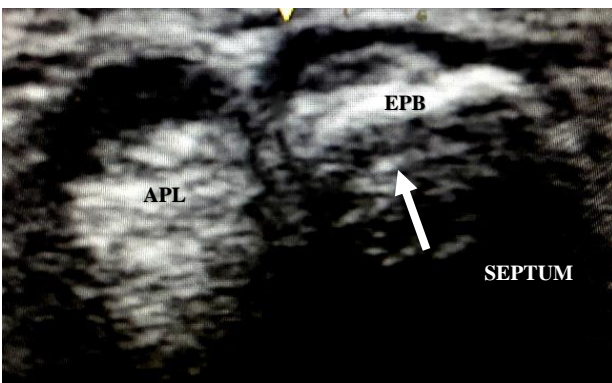
## RESULTS

The findings of our study were recorded, analysed, and is shown in Table 1 and the demographic data of the study population tabulated in Table 2. 61 out of 106 (57.54%) wrists were symptom free after a single dose of corticosteroid injection at the radial styloid process and were doing good at six months follow up without any further intervention being needed. Ultrasound assessment of these 61 wrists revealed 26 of them having one APL and one EPB in the dorsal compartment of which 2 wrists were having a transverse septum separating the two tendons (Figures 1 and 2).

32 of these 62 wrists showed two APL and one EPB arrangement of which 1 wrist with septation, separating the two APL from the EPB was found (Figures 3 and 4). The remaining 3 wrists had an arrangement of one APL and two EPB however without any septa.

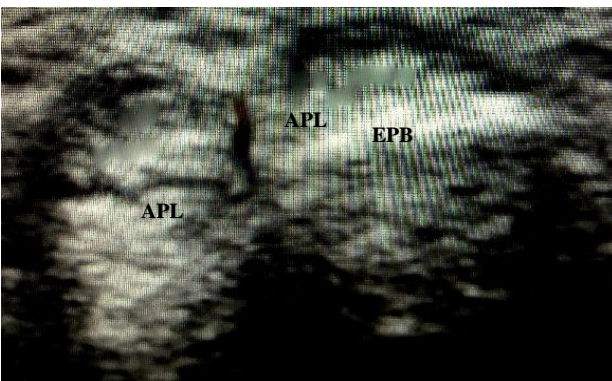


**Figure 1: First dorsal compartment of wrist showing one APL and one EPB without any intervening septum.**

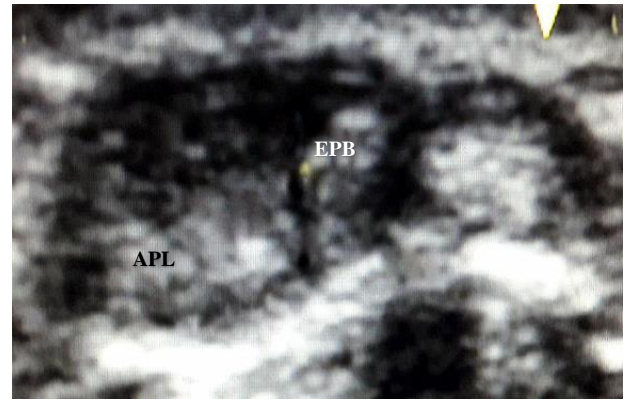


**Figure 2: First dorsal compartment of wrist showing one APL and one EPB with an intervening septum.**

A second dose of injection was needed for 9 wrists within a duration of six to twelve weeks after the first dose for cure. 1 of these 9 wrist had one APL and one EPB arrangement with an incomplete septum between the two tendons. 7 wrists had two APL and one EPB arrangement of which only 1 wrist showed an oblique septum. 1 wrist showed one APL and two EPB arrangement without any intracompartmental septa.



**Figure 3: First dorsal compartment of wrist showing two APL and one EPB without any intervening septum.**

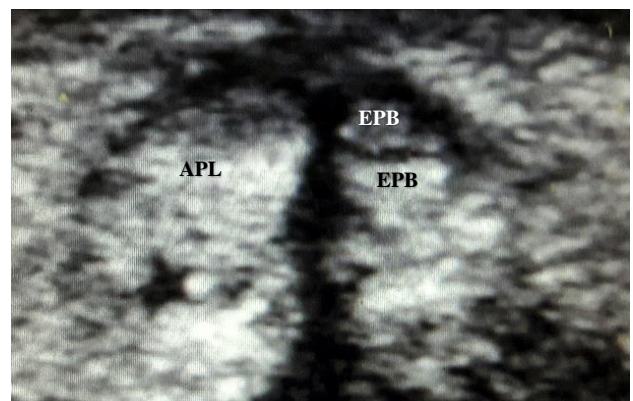


**Figure 4: First dorsal compartment of wrist showing two APL and one EPB with an intervening septum.**

Only 2 wrists needed a third injection for cure that revealed a one APL and two EPB arrangement without septation on ultrasound (Figure 5).

34 out of the 106 (32.07%) wrists were not cleared of symptoms; either in the form of persistent residual pain and disability or had a recurrence of symptoms at variable durations even after receiving two repeat dosages of corticosteroid injection at the radial styloid process. Of these, 31 wrists showed septation with variable tendon arrangements. 4 wrists with two tendon arrangement, one APL and one EPB (Figure 6).

22 wrists had two APL and one EPB. 3 wrists with one APL and two EPB. 2 wrists showed supernumerary APL with supernumerary EPB with an intervening septum between the abductor group of tendon slips and extensor group of tendon slips. 3 wrists had similar supernumerary arrangement of tendons but without septation (Figure 7).



**Figure 5: First dorsal compartment of wrist showing one APL and two EPB without any intervening septum.**

The presence of a septum was seen in 35 wrists (33%) and most of the septations were obliquely directed. Septations were more common in wrists with bilateral affection (28 of 74 wrists).

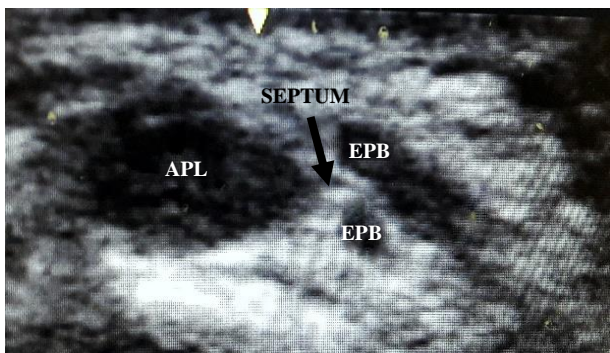
**Table 1: The different anatomical variations seen on ultrasound in the first dorsal compartment of the wrist and their response to corticosteroid injection.**

Response to steroid injection at RSP	1 APL+ 1 EPB (31)		2APL+1EPB (61)		1 APL + 2EPB (09)		Supernumerary APL+ supernumerary EPB (05)	
	No septum (25)	Septum (06)	No septum (37)	Septum (24)	No septum (06)	Septum (03)	No septum (03)	Septum (02)
Cure after 1st injection	24	02	31	01	03	-	-	-
Cure after 2 <sup>nd</sup> injection	01	-	06	01	01	-	-	-
Cure after 3 <sup>rd</sup> injection	-	-	-	-	02	-	-	-
No remission	-	04	-	22	-	03	03	02

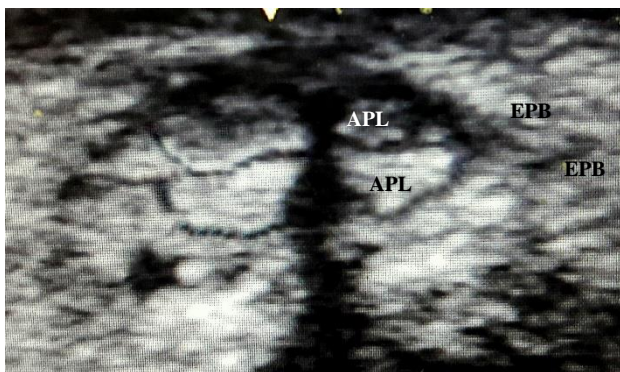
Figures in the bracket show the total number of cases of the respective category; RSP – radial styloid process

**Table 2: Demographic data of the study population.**

Parameters	Frequency
Total number of patients incorporated in the study	69
Total number of wrists incorporated in the study	106
Patients having unilateral wrist involvement	32
Patients having bilateral wrist involvement	37
Number of females	62
Number of males	07
Mean age of the study population	39.8 years



**Figure 6: First dorsal compartment of wrist showing one APL and two EPB with an oblique intervening septum.**



**Figure 7: First dorsal compartment of wrist showing supernumerary APL and supernumerary EPB without any intervening septum.**

## DISCUSSION

For the diagnosis of de Quervain’s tenosynovitis the history, patients’ occupation and clinical findings must all be considered. The Finkelstein test usually is positive: “on grasping the patient’s thumb and quickly abducting the hand ulnar ward, the pain over the styloid tip is excruciating.” Although Finkelstein stated that this test is “probably the most pathognomonic objective sign,” it is not diagnostic.<sup>21</sup>

Conservative management with splint wear immobilising the thumb or corticosteroid injections usually yield complete relief in almost 70% of the patients. However, literature shows that corticosteroid injection gives better outcome and a higher success rate compared to splinting. Also concomitant splinting after corticosteroid injection does not yield any added benefit.<sup>23</sup>

Cadaveric studies have shown the anatomical proximity between the superficial branch of radial nerve and the tendons of the first dorsal compartment of the wrist. It has been recommended that the EPB tendon, which has a low percentage of overlap with the nerve based on studies, be palpated before injection. The injection should be administered immediately above or immediately medial to the EPB during blind procedures.<sup>24</sup> We have used similar protocols for corticosteroid injection in our patients and there have been no reported incidence of any neural injury.

On ultrasonographic assessment, we found supernumerary tendons in the first dorsal compartment of the wrist in

70.75 % (75 out of 106 wrists) of cases. Other studies also have corroborative findings.<sup>2,9-11</sup> So, it can be counted as a rule rather than an exception. The most commonly found tendon arrangement was two APLs and one EPB. The presence of septations were seen in 33.01% of the wrists in our study and showed increased association with recurrences. It is nearly similar to the study of Lomis and Leslie.<sup>9,20</sup> Variations of insertion of APL has also been documented that may have an effect in increasing the tendon volume and producing potential extra friction.<sup>22</sup> Thus causing failure to conservative management and/or recurrence. Different tendinous insertions of the APL have different innervation patterns that produce more friction as described by Dos Remédios et al.<sup>18</sup> On ultrasound, most of the EPBs were found deeper and medial to the APL. And because it moves more than APL during thumb movement, it may be responsible for more friction and thus a greater contribution to the disease. The EPB compartment is often responsible for failed injections owing to its smaller and deeper location.<sup>15,16</sup> This difference in number and thickness may be responsible in determining laterality (unilateral or bilateral) and recurrence in one hand following treatment.

In our study, we found that almost all wrists with one APL and one EPB, and two APLs and one EPB arrangement of tendons, those that were without an intervening septum, were rendered symptom free after a single dose of steroid injection. Only one wrist with one APL and one EPB arrangement needed a second injection which could be attributed to a technical error during the first dose or an incomplete septa found on ultrasound could also be the undermining factor. Six wrists with two APL and one EPB needed a second dose of injection. This could be explained by the variations of insertion of the APL tendon slips, into the trapezium, into the abductor pollicis brevis tendon and thus attributing to difference in tendon volume and differential friction. Wrists with tendon arrangements of one APL and two EPB without a septum showed variable outcome. Three such wrists required one injection, one wrist needed two doses and three injections were needed in two wrists of same arrangement of tendons. This variation in outcome could well be explained firstly by the deeper location of the EPB tendons in the wrist; and also, different diameters of EPB tendon slips have been noted in cadaveric studies where increased thickness may be responsible for increased friction causing increased recurrence.<sup>22</sup>

32.07% (34 out of 106 wrists) cases were found to be non-responsive to corticosteroid injection at the radial styloid process. Of these, 31 wrists showed septations, with different tendon arrangements. There were also 3 wrists with supernumerary APL and supernumerary EPB without any intervening septum that did not show remission with three injections, perhaps attributable to all the anatomical factors individually responsible for recurrence viz. variation in tendon insertions, arrangements, tendon thickness all leading to increased volume and friction.

Only 4 wrists out of 35 (11.42%) with septations, had undergone a remission with steroid injections, two of them revealed one APL, one EPB arrangement on ultrasonography and two having two APL and one EPB arrangement on ultrasound. Whereas, 31 wrists with septations (88.57%) had no improvement clinically with three doses of steroid injections and had a recurrence. So it can be interpreted that presence of a septum is one of the most important aetiology behind the recurrence of de Quervain's tenosynovitis and is usually not amenable to cure by steroid injection. The very few wrists with septum, that showed remission with steroid had a relatively simple and underpopulated first dorsal compartment of the wrist. This could possibly make provision for ultrasound guided injection of steroids in each compartment as an ideal treatment modality for wrists with stenosing tenosynovitis with an intracompartmental septum; however, that could only hold true for a simpler arrangement of tendons. Most of them would need surgical interventions.

We had also found variations between wrists in bilateral cases, of tendon arrangements and in the presence of septa which may be responsible for recurrence in one hand after injection though the other hand becomes cured.

## CONCLUSION

The presence of supernumerary tendons/tendon slips and the presence of septum/aberrant compartments, in the first dorsal compartment of the wrist are thus the two major reasons behind failure of conservative management and the recurrence in de Quervain's disease. We have also seen from our study the utility of ultrasound in detecting these variations; which would predict the response of a particular variant to steroid injections. Thus all patients suffering from de Quervain's disease must first undergo an ultrasonographic assessment of the anatomy of their wrists' first dorsal compartment; in order to elicit the anatomical variation present in them. And then the best treatment modality suitable to cure the disease of that particular variant, must be advocated. Compartments with simpler and common variants will do away with conservative management; those with septum and a two-tendon arrangement may be given a trial of an ultrasound guided steroid injection to both the compartments. The remaining variants with supernumerary tendons with or without septations which we now know are resistant to conservative can be approached with surgical interventions right away, instead of repeated failed conservative trials, thus decreasing the morbidity.

*Funding: No funding sources*

*Conflict of interest: None declared*

*Ethical approval: Not required*

## REFERENCES

1. Anson BJ. An atlas of human anatomy, 2nd edition. Saunders, Philadelphia. 1963.

2. Baba MA. The accessory tendon of the abductor pollicis longus muscle. *Anat Rec.* 1954;119:541-7.
3. Bahm J, Szabo Z, Foucher G. The anatomy of de Quervain's disease. A study of operative findings. *Int Orthop.* 1995;19(4):209-11.
4. Bouchlis G, Bhatia A, Asfazadourian H, Touam C, Vacher C, Oberlin C. Distal insertions of abductor pollicis longus muscle and arthritis of the first carpometacarpal joint in 104 dissections. *Ann Chir Main Memb Super.* 1997;16(4):326-38.
5. Brown GD 3rd, Roh MS, Strauch RJ, Rosenwasser MP, Ateshian GA, Mow VC. Radiography and visual pathology of the osteoarthritic scaphotrapezio-trapezoidal joint, and its relationship to trapeziometacarpal osteoarthritis. *J Hand Surg.* 2003;28(5):739-43.
6. Brunelli GA, Brunelli GR. Anatomical study of distal insertion of the abductor pollicis longus. Concept of a new musculo tendinous unit: the abductor carpi muscle. *Ann Chir Main Memb Super.* 1991;10(6):569-76.
7. Eaton RG, Littler JW. Ligament reconstruction for the painful thumb carpometacarpal joint. *J Bone Joint Surg.* 1973;55(8):1655-66.
8. Finkelstein H. Stenosing tendovaginitis at the radial styloid process. *J Bone Joint Surg.* 1930;12:509-40.
9. Lomis LK. Variations of stenosing tenosynovitis at the radial styloid process. *J Bone Joint Surg.* 1951;33-A:340-6.
10. Muckart RD. Stenosing tendovaginitis of abductor pollicis longus and extensor pollicis brevis at the radial styloid (de Quervain's disease). *Clin Orthop.* 1964;33:201-8.
11. Zancolli EA. The trapeziometacarpal joint. Tenotomy of the accessory tendons in early osteoarthritis. *Hand Clin.* 2001;17(1):13-43.
12. Saehle T, Sande S, Finsen V. Abductor pollicis longus tendon interposition for arthrosis in the first carpometacarpal joint: 55 thumbs reviewed after 3 (1–5) years. *Acta Orthop Scand.* 2002;73(6):674-7.
13. Rousset P, Vuillemin-Bodaghi V, Laredo JD, Parlier-Cuau C. Anatomic variation in the first extensor compartment of the wrist: accuracy of US. *Radiology.* 2010;257(2):427-33.
14. Yuasa K, Kiyoshige Y. Limited surgical treatment of de Quervain's disease: decompression of only the extensor pollicis brevis sub compartment. *J Hand Surg [Am].* 1998;23(5):840-3.
15. Zingas C, Failla JM, Holsbeeck MV. Injection accuracy and clinical relief of de Quervain's tendinitis. *J Hand Surg.* 1998;23(1):89-96.
16. Nayak SR, Hussein M, Krishnamurthy A. Variation and clinical significance of extensor pollicis brevis: a study in South Indian cadavers. *Chang Gung Med J.* 2009;32(6):600-4.
17. Cho KO. Translocation of the abductor pollicis longus tendon. A treatment for chronic subluxation of the thumb carpometacarpal joint. *J Bone Joint Surg Am.* 1970;52(6):1166-70.
18. Dos Remédios C, Chapnikoff D, Wavreille G, Chantelot C, Migaud H, Fontaine C. The abductor pollicis longus: relation between innervation, muscle bellies and number of tendinous slips. *Surg Radiol Anat.* 2005;27(3):243-8.
19. Bianchi S, Martinoli C, Abdelwahab IF. High-frequency ultrasound examination of the wrist and hand. *Skeletal Radiol.* 1999;28(3):121-9.
20. Leslie BM, Ericson WB Jr, Morehead JR. Incidence of a septum within the first dorsal compartment of the wrist. *J Hand Surg [Am].* 1990;15(1):88-91.
21. Azar FM, Beaty JH, Canale ST. *Campbell's operative orthopaedics.* Philadelphia, PA: Elsevier. 2017;3765-6.
22. Roy AJ, Roy AN, De C, Banerji D, Das S, Chatterjee B, et al. A cadaveric study of the first dorsal compartment of the wrist and its content tendons: anatomical variations in the Indian population. *J Hand Microsurg.* 2012;4(2):55-9.
23. Mallick SK, Jha DK, Majumdar A, Mahapatra S. A Comparative Study between Splinting Versus Corticosteroid Injection in De-Quervain's Disease. *Int J Orthop Sci.* 2018;4(3):22-6.
24. Cheong IY, Rhyu IJ, Kim KH, Chung PW, Kim D, Park BK, et al. Anatomical Basis for Injection around First Dorsal Compartment of the Wrist: A Fresh Cadaveric Study. *Pain Physician.* 2016;19(6):E893-900.

**Cite this article as:** Mukherjee S, Roy AJ, Mandal P. Ultrasonographic evaluation of anatomical variations, of the first dorsal compartment of wrist, and its correlation with de Quervain's disease recurrence in Indian population: a hospital based longitudinal study. *Int J Res Orthop* 2023;9:xxx-xx.