


## Original Research Article

# Clinical characteristics and management of odontogenic necrotizing fasciitis: a retrospective study

Imen Mehri Turki 

Stomatology Maxillofacial Reconstructive and Aesthetic Surgery Department, Mohamed Tahar Maamouri University Hospital, Nabeul, Tunisia

(Received: 11 May 2023, accepted: 12 July 2023)

**Keywords:**  
Computed  
tomography /  
necrotizing fasciitis  
/ polymicrobial  
Infection

**Abstract – Background:** Life-threatening illnesses like necrotizing fasciitis (NF) from dental origin arise suddenly and unexpectedly as a result of the debilitating condition and frequent self-medicating behaviour. This article aims to report the medical and therapeutic characteristics of 15 patients while discussing risk factors, pathogenetic mechanisms and management of this disease. **Method:** From 2012 up to 2022, a retrospective chart study of patients with odontogenic NF was carried out. Demographic, medical and therapeutic data were collected and analysed, using the Excel program. **Results:** Fifteen patients were identified with retrievable medical records. There was a male predominance, and the age ranged from 13 to 82 years with a majority over 40 years. Preadmission delay was  $\leq 4$  days in 40% of patients with self-medication of non-steroid anti-inflammatory drugs. 53.85% of patients had previous dental treatment without antibiotic coverage. Rheumatoid arthritis was the predominant comorbidity followed by diabetes mellitus and anaemia. Multispace involvement was found in 73.33% of patients. Preoperative computed tomography was performed for 60% of patients. **Conclusion:** Prompt and efficient treatment is required for NF, a polymicrobial odontogenic infection that is lethal even in healthy people. Self-medication and debilitating condition should be considered. Early diagnosis and therapy may reduce mortality and morbidity.

## Introduction

Necrotizing fasciitis (NF) is still a rare but potentially fatal disease which in most cases originates from dental origin. Its dangerous behaviour is due to the synergistic relationship of the oral cavity's microbiome, particularly in patients with co-morbidity and delayed therapy. Early-stage NF does not have distinct clinical characteristics, making it susceptible to misdiagnosis. Once the condition takes a turn for the worse, the treatment becomes challenging requiring a lengthy hospital stay and carrying a substantial risk of morbidity and mortality [1,2]. This report aims to study retrospectively the characteristics related to demographic data, and medical and therapeutic management of patients with odontogenic NF handled in our university hospital and discuss factors that contribute to this devastating infection while the rescue could be obtained.

## Method

We performed a retrospective chart review of all patients admitted to our department from 2012 up to 2020 for the management of necrotizing fasciitis originating from a dental

infection. All Patients who had a non-odontogenic infectious origin were excluded from the studied sample.

Ethics approval and consent to participate: This study has been performed in accordance with the Declaration of Helsinki. The Institutional Ethics Committee of Mohamed Tahar Maamouri University Hospital approved this study. Informed written consent to participate in the study was provided by the patients or legal guardians of participating children included informed written consent for the publication of images.

From patient records, we gathered the following information:

- Demographic data: gender, co-occurring systemic condition, and age which was divided into the following categories:  $\leq 19$ , 20–39, 40–59, and  $\geq 60$  years.
- Medical history: Prior dental procedure, self-medication, Prior antibiotic use, and preadmission delay.
- Clinical symptoms: general health alteration, trismus, dyspnea, pain, the primary site of infection, dental origin, and skin-related symptoms.
- Radiologic features.
- Medical and surgical management: Surgical procedures, antibiotic association, pus culture findings, usage of corticotherapy, postoperative mechanical ventilation, hospital stay, and outcome.

\* Correspondence: [turkiymen@yahoo.fr](mailto:turkiymen@yahoo.fr)

The collected data were organized using the Excell spreadsheet program in an electronic format.

## Results

### Demographic data and medical history

There were 17 patients identified however only 15 had retrievable medical records. Among the 15, there were 10 male patients and 5 female whose ages ranged from 13 to 82 years with a mean of 55.2 years. The majority of cases were older than 40 years (Fig. 1).

The preadmission delay since the onset of the disease varied from 3 to 10 days with a mean of 4.3 days and a standard deviation of 1.5 days. This delay was  $\leq 4$  days for 6 (40%) patients whose medical history suggested self-medication with non-steroid anti-inflammatory drugs in both healthy and immunocompromised subjects. The majority of dental procedures performed before the infection disease were invasive in 10 cases including the extraction of the third and second mandibular molar, and non-invasive procedures in 3 cases including endodontic treatment or removal of calculus. Two patients, however, still lacked treatment for their premolar abscess and radicular cysts. The pre-existent systemic disease was found in 53.33% of patients where rheumatoid arthritis (37.5%) was the predominant co-morbidity followed by type 2 diabetes mellitus that was in an unbalanced state (25%), anaemia (25%), and renal insufficiency (12.5%). Patients with rheumatoid arthritis were medicated with methotrexate. However, 7 (46.66%) patients had no prior medical history. About half of the patients (53.85%) had undergone previous dental treatment without a prescription for adjuvant antibiotics. For the others, antibiotic therapy was indicated allowing to the nature of the procedure and the associated comorbidities (Tab. I).

### Clinical and radiological characteristics

Five patients had septicemic syndrome at the time of admission. Among them, a woman with type 2 diabetes mellitus had additional dyspnea, trismus and sore throat. A female patient with rheumatoid arthritis who underwent endodontic treatment and self-medicated with a non-steroid anti-inflammatory drug also showed signs of dyspnea. Almost all the patients had trismus, and 8 patients experienced excruciating pain even for two of them who had taken non-steroid anti-inflammatory drugs. However, 4 patients who used these drugs for self-medication immediately after the dental procedure had no pain. The initial site of infection was mainly the submandibular space (46.67%), sublingual space (26.67%), vestibular (13.33%) and parapharyngeal space (13.33%). The infection involvement interested more than 3 anatomical spaces, including facial and cervical areas, in 73.33% of patients. The extension of the fasciitis to the subcutaneous tissue of the upper chest was observed in 20% of patients without any mediastinal extent. Hence, the intervention of a thoracic surgeon was neither mandatory nor necessary.

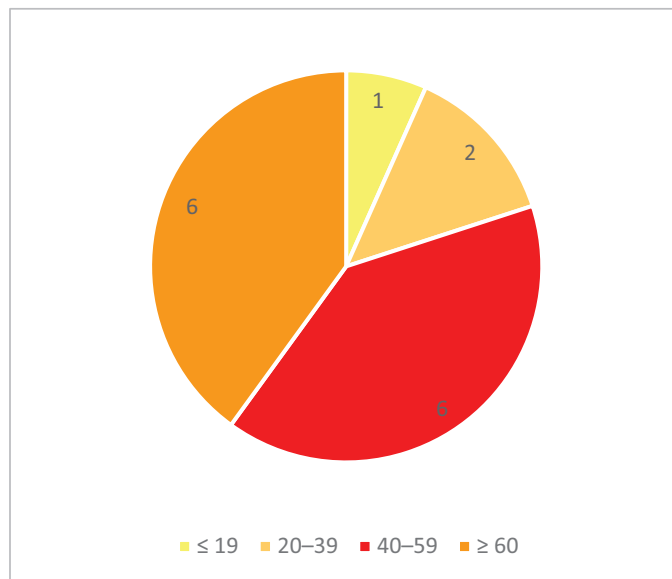


Fig. 1. Patient distribution by age group.

Erythematous skin was associated with crepitus on palpation in 6 (40%) cases. Skin necrosis, however, was not documented in this series (Tab. II).

Preoperative cervicofacial computed tomography (CT) was performed for only 9 patients (60%), those without septic shock or hemodynamic instability. Enhanced CT identified the dental origin and localized spaces of infection while showing the airway condition. No case of mediastinitis was found. However, gas formation and cutaneous undermining with the loss of the fascial planes were found in practically all radiological studies. Among 9 patients in whom CT was conducted, 5 patients had abscess formation, and 3 patients had airway impairment (Figs. 2 and 3).

### Medical and surgical management

Within 24 h of being admitted, a surgical debridement with drainage of pus and necrotic debris was performed on all 15 patients under general anaesthesia with nasotracheal intubation by fiberoptic guidance (Figs. 4 and 5). After intubation, the incision was made either in front of a subcutaneous collection or on a natural fold. Fibrotic septa were cut easily with dissectors and drainage of purulent collection and necrotic debris was made. Nevertheless, in some cases despite the absence of pus, necrotic tissue was resected until natural bleeding was obtained. Without resorting to a tracheotomy, postoperative mechanical ventilation was provided for Three patients with impaired airways. For 8 patients, there were two surgical procedures, while one patient required three surgical debridement. Postoperatively, washing and scrubbing of the surgical area were done twice a day until the perfect cleaning of the wound.

The average duration for inpatient treatment was 27.21 days, ranging from 17 to 42 days. Ten of the 15 patients needed intensive care which usually took 7 days. A broad-spectrum

**Table I.** Demographic data, risk factors, premedication and preadmission delay.

Patient	Gender	Age	Health status	Self-medication	Preadmission antibiotic	Preadmission delay	Dental aetiology
1	M	48	Healthy	-	Amoxicillin	7 days	Extraction 48
2	M	54	Anaemia	NSAI drug	-	4 days	Endodontal treatment 37
3	F	38	Rheumatoid Arthritis	-	Rodogyl	5 days	Removal of calculus + 47 root extraction
4	M	44	Renal Insufficiency	-	Rodogyl	7 days	Multiple extractions
5	M	67	Healthy	-	-	6 days	Extraction 13
6	M	66	Healthy	-	-	10 days	Abscess 45
7	F	82	Type 2 diabetes mellitus	-	-	5 days	Extraction 25
8	M	57	Healthy	-	Amoxicillin-clavulanic acid	7 days	Extraction 18
9	F	39	Rheumatoid Arthritis	NSAI drug	-	3 days	Implant placement
10	M	13	Anaemia	-	-	5 days	Endodontal treatment 46
11	M	65	Healthy	-	Amoxicillin	8 days	Radicular cyst 38
12	M	74	Healthy	NSAI drug	Rodogyl	4 days	Extraction 37
13	M	52	Type 2 diabetes mellitus	NSAI drug	Amoxicillin	3 days	Extraction 48
14	F	59	Healthy	NSAI drug	-	3 days	Endodontal treatment 45
15	F	70	Rheumatoid Arthritis	NSAI drug	-	4 days	Multiple extractions

intravenous antibiotherapy was administered based on amoxicillin and clavulanic acid (2 g three times a day) associated with metronidazole (0.5 g three times a day) and ofloxacin (0.2 g twice a day). In cases of -lactam allergy, clindamycin (0.6 g three times a day) was utilized. For the child, 50 mg/kg of amoxicillin and clavulanic acid were administered daily associated with 20 mg/kg of metronidazole. An antifungal (Fungizone 50 mg twice a day) was also associated in one patient where microbiological analyses revealed the presence of *Candida albicans*. Otherwise, most bacteria species isolated in pus, blood and necrotic tissue were as follows: *hemolytic streptococcus*, *Streptococcus intermedius*, *Enterococcus*, *Prevotella*, *F. nucleatum*, *Actinomyces*, and *Bacteroides fragilis*. However, pus culture was negative in 40% of cases.

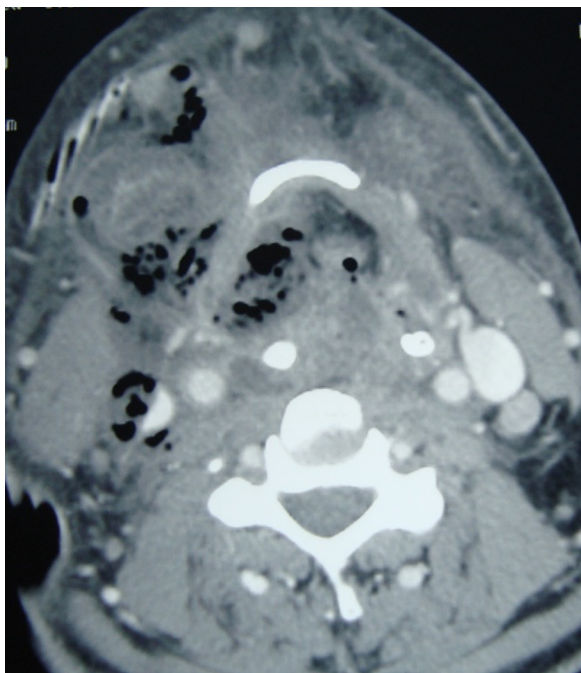
In all cases, additional intravenous corticotherapy (dexamethasone 8 mg) was administered daily preoperatively and for the next 5 days for all patients. All of the patients were discharged in good general condition, without skin defects requiring plastic reconstruction.

### Discussion

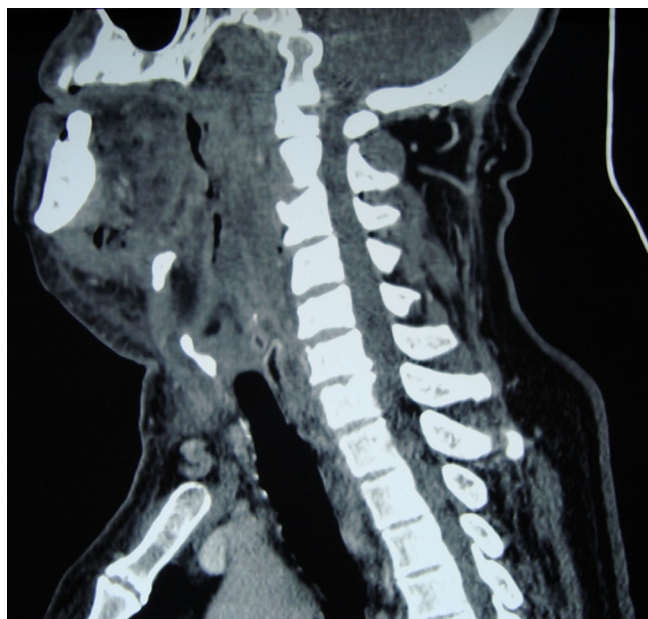In the 5th century, Hippocrates described « a new disease » as « a severe inflammation » with “ubiquitous and rapid spread”, similar to erysipelas, with putrefaction formation giving a loss of extremities, and perineum involvement with frequent death [3]. This dangerous condition was coined by Wilson using the term “necrotizing fasciitis” (NF) in 1952 [4]. NF typically manifests in the extremities, abdominal wall, and perineum. whether the incidence of 2.6% indicates that the cervicofacial location is unusual [5]. This low incidence is likely caused by the rich vascular supply of facial tissue, allowing greater resistance to necrosis and better coverage of antibiotics. This life-threatening infection progresses rapidly and can be confused with common cellulitis or abscess at an early stage. Diagnostic challenges arise when signs of systemic shock symptoms and a confused state are present at an advanced stage [6]. Our emphasis on the imbalance between intensive pain and deceptive clinical symptoms in conjunction with systemic toxicity should highly sensitize clinicians to suspect necrotizing fasciitis, requiring swift radiological investigation and immediate surgical treatment with broad-spectrum antibiotherapy. This could be a guarantee of the patient’s rescue. In this study, intensive pain was found in 8 patients. In contrast, the discomfort was absent in 4 others, likely because they were using a non-steroid anti-inflammatory drug. The latter also decreases inflammatory reaction, delaying diagnosis while necrotic infection spreads sufficiently to present fulminantly. Another factor explaining the harmfulness of non-steroid anti-inflammatory drugs in odontogenic infections is the immunosuppressive action due to the inhibition of granulocyte adherence, activation of phagocytosis, and augmentation of cytokine production (tumour necrosis factor) [7]. Nevertheless, the preadmission delay was shorter in patients who took these drugs because their infectious state worsened more than the others, and the spread of the infection was faster.

**Table II.** Clinical signs and space involvement with the dental origin.

Patient	General health signs	Trismus	Pain	First infected space	Space involvement
1	Sore throat Dysphagia Dyspnea Swelling Trismus Fever	Yes	Intense	Submandibular	3
2	Swelling Trismus	Yes	Slight	Submandibular	3
3	Septicaemia- Dysphagia Swelling Fistula Trismus	Yes	Intense	Submandibular	3
4	Septicaemia Pelvibuccal- hardening Sialorrhoea Trismus	No	Moderate	Sublingual	2
5	Fever Swelling Palpebral oedema	Yes	Intense	Vestibular	4
6	Pelvibuccal- hardening Fistula Trismus Fever	Yes	Moderate	Sublingual	2
7	Dyspnea Sore throat Septicaemia Fever Palpebral oedema Swelling	Yes	Moderate	Submandibular	4
8	Fever- Dysphagia Discharge of pus Swelling	Yes	Intense	Parapharyngeal	3
9	Septicaemia Swelling Pelvibuccal hardening	No	Inexistent	Sublingual	2
10	Fever Swelling Fistula	Yes	Intense	Sublingual	2
11	Fever Swelling Trismus	Yes	Intense	Vestibular	3
12	Sore throat Dysphagia Trismus Swelling	Yes	Intense	Submandibular	4
13	Trismus Swelling	Yes	Intense	Parapharyngeal	3
14	Septicaemia Swelling Pelvibuccal hardening	Yes	Inexistent	Submandibular	3
15	Dyspnea- Dysphagia Trismus Swelling	Yes	Inexistent	Submandibular	3

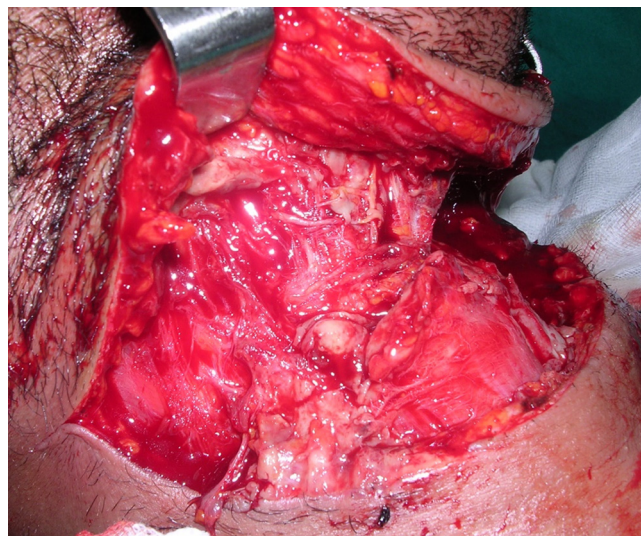


**Fig. 2.** Axial view of computed tomography at the level of the mandibular border showing extensive Gas formation, cutaneous undermining and masseter swelling.

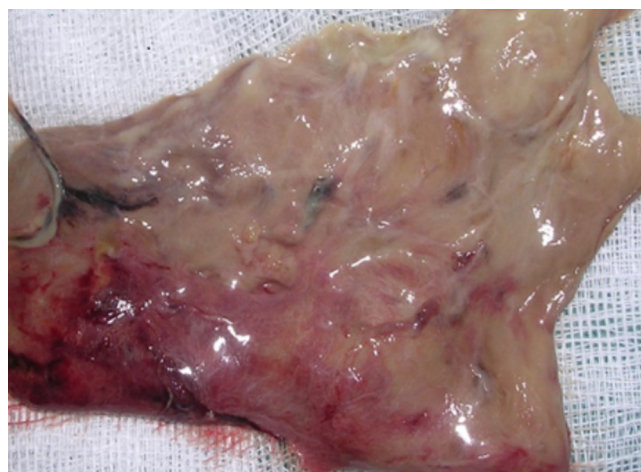


**Fig. 3.** Sagittal view of computed tomography showing subcutaneous oedema, sublingual emphysema and airway obstruction.

This current study included a child and adults in the age group of 38–82 years. This confirms the reports of previous studies that although children may acquire maxillofacial infections [8] while the majority occur in adults with poorly controlled oral health and a higher prevalence of systemic diseases that compromise immunity. Generally, women are more attentive to their oral health and meticulous about teeth



**Fig. 4.** Preoperative photo showing the achievement of normal bleeding after surgical debridement.



**Fig. 5.** Photos of the necrotic tissue.

appearance, explaining the predominance of odontogenic infections in men. This prevalence is demonstrated in this study. It has been shown that medically compromised patients with underlying diseases such as diabetes mellitus appear to be at higher risk of developing infectious complications and sequelae requiring longer hospital stays and even fatal outcomes may occur more often than in previously healthy patients [2,9]. In this present study, 53.33% (8/15) of patients had co-morbidity particularly dominated by rheumatoid arthritis (3/15), followed equally by type 2 diabetes mellitus (2/15) and anaemia (2/15). The hyperglycemic state of a patient with diabetes mellitus impairs the leukocyte function and thus suppresses the host’s immune system. Therefore antibody response and polymorphonuclear cell function are compromised, and the infection becomes uncontrolled and worsens. In some reports, diabetes mellitus was predominant, and in others, anaemia was the most reported systemic

condition as described in Tanzania where 43 cases were identified in only one year, ten times more than in Nigeria [10,11]. As seen in 7 of our previously healthy patients, some authors revealed that head and neck NF may occur in anyone, even if they do not have a particular disease [12]. Therefore, we underline the odontogenic infection's uncertain course especially when dyspnea and dysphagia are present. These symptoms should be taken into consideration as important warning indications of a serious infection [13]. Otherwise, the presence of trismus indicates that the infection had involved the masticatory spaces and could disturb the upper airway abruptly leading to dyspnea. Among these patients, 23.07% also had dyspnea suggesting that airway compromise had already set in.

In our study, the most commonly infected site began in the submandibular space (46.67%) and the sublingual space (26, 67%), then, after the spread of the infection, multi-space involvement of more than three anatomical areas were found in 73.33% of patients. Although space involvement varies according to several reports, the submandibular space has been reported to be the most affected one. Multiple space involvement has already been significantly linked to life-threatening complications [14,15].

Moreover, the clinical variability and the disparity between the clinical signs and the systemic toxicity, especially in an aged patient with an immunosuppressive state should raise a high index of suspicion for NF and require radiological investigations. The advantage of CT is its superior hard tissue contrast that enables the identification of odontogenic infection foci, a crucial step in the management of odontogenic infections. CT is also more readily available, and considerably a faster modality than MRI, which is critical for patients who need quick surgical treatment. It was highlighted that CT can provide pathognomonic features of NF such as fascia damage and gas collection which is the hallmark of necrosis. The absence of these features does not, however, rule out this diagnosis. Additionally, it is possible to see a simple undermining of the cutaneous layer as well as muscle swelling and abscess formation. In addition, CT confirms the dental aetiology, provides a mapping of involved infected sites, detects remote complications and guides airway management [16–18]. However, the radiological examination should not delay the surgical treatment, especially for critically ill patients with airway obstruction. This explains why it was achieved for only 9 patients in this study.

The precise pathogenetic mechanism of NF is not yet established. Several research suggests the synergy of myriad bacteria in the oral cavity ecosystem leading to this devastating odontogenic infection. The microbial flora includes anaerobic and aerobic bacteria species that interact synergistically increasing their virulence while decreasing the immune host's response. It has been stated that streptococci may play a crucial role in promoting tissue oxygen reduction favourable to anaerobes invasion [2,19]. Nevertheless, this concept of bacterial synergism has been used to support the use of penicillin, against aerobes (*streptococcus*), at the early

stage of cellulitis to avoid abscess formation. As for anaerobes, they possess immunosuppressive and abscessogenic properties among cell surface constituents such as capsular polysaccharides that protect against phagocytosis, while the production of toxins and proteolytic enzymes, such as collagenases and hyaluronidases causes tissue damage and inflammatory reactions. Moreover, anaerobic bacteria produce volatile sulfur compounds, such as methyl mercaptan and hydrogen sulfide, giving more oxidative stress, and proinflammatory activity [20–23]. They cause the putrid smell of pus and reflect gas formation which causes crepitous on palpation of the affected area and is often visualized as soft tissue emphysema during radiological explorations. Although the wide range of implicated bacteria species, streptococcus dominates these infections, and multiple microorganisms initiate endodontic infections such as *Fusobacterium*, *Treponema* and *Prevotella* [19]. This current study found a mixture of aerobes and anaerobes bacteria species, and *Candida albicans* in one patient. Candidal cellulitis is exceptional and should be considered when the patient with cellulitis has no improvement after receiving standard antibiotic therapy, most often when the patient is immunosuppressed [24].

The management of severe odontogenic infection of the face and neck is challenging. It necessitates early recognition followed by a mandatory prompt surgical drainage and debridement with initial broad-spectrum antibiotic therapy, up to microbiological culture and sensitivity testing. The combination of penicillin with metronidazole should provide efficacy against both streptococci and anaerobes species. Other reports, as revealed in this study, have demonstrated the effectiveness of clindamycin, fluoroquinolone, amoxicillin and clavulanic acid in NF [13,16,25,26].

We emphasize the treatment of the odontogenic focus including tooth extraction or socket curettage concurrently with surgical debridement to eradicate the bacterial biofilm around tooth structures. It is well known that layers of bacteria, growing together in the biofilm in a cooperative manner, demonstrate resistance to host defences and the penetration of antibiotics that kill only the superficial layers of bacteria. Thus tooth extraction and socket curettage are the only mechanical ways to get rid of the biofilm's bacterial species. Otherwise, antibiotic resistance might develop lengthening hospital stays. This current study revealed a hospital stay ranging from 17 to 42 days. This corroborates with other experiences in surviving patients where the hospital stay lasted more than 22 days, while it did not exceed 7 days in deceased patients [10,27]. It is attributed that the use of antibiotics before admission was associated with an increase in hospital stay which is practically similar in this study and other reports [28–31]. It has been shown that the use of spiramycin-metronidazole (Rodogyl) has the same efficiency as amoxicillin in the treatment of pericoronitis [32]. In this study, preadmission antibiotherapy employing rodogyl and amoxicillin has evenly distributed.

We believe that removing the odontogenic focus at an early stage combined with surgical debridement while ensuring broad-spectrum antibiotics and adequate resuscitation with

airway freedom offers better outcomes and rescues the patient. The fiberoptic nasotracheal intubation was performed for all our patients which is considered to be a more suitable procedure for many anesthesiologists when dealing with a cooperative patient who has an upper airway obstruction [33]. Complications and morbidity such as skin necrosis, mediastinitis, pleural and pericardial effusion, and also mortality appear to be related to the promptness and efficacy of medical and surgical treatment. According to reports, the death rate ranged from 19% to 40% [11]. In the current study, all patients were discharged in good health without skin defects requiring surgical repair. In our university hospital, the close collaboration between dentists and emergency physicians who seek specialist advice from the maxillofacial surgeon for any odontogenic infection spreading in facial soft tissue makes the diagnosis delay shorter.

## Conclusion

Necrotizing fasciitis of odontogenic origin is a life-threatening condition. Despite the patients with immunosuppressive conditions are prone to this devastating infection, previously healthy patients could also be affected. The key to the rescue is prompt and efficient medical and surgical treatment. Hence, the awareness and high index of diagnosis suspicion at an early stage is mandatory. However, patients generally consult emergency doctors or dentists who must be aware of this serious and unpredictable pathology to avoid any delay in handling. Otherwise, the treatment becomes more challenging to both maxillofacial surgeons and anaesthesiologists if the patient presents septic shock, dyspnea, multi-space involvement, skin necrosis and airway obstruction.

Trismus, dysphagia and submandibular space involvement are clinical signs of serious odontogenic polymicrobial infections, particularly in patients with the immunosuppressive condition. Thus, the infection can spread rapidly in depth with multi-space involvement and tissular damage which are well demonstrated in contrast-enhanced CT of the head and neck. The synergism between aerobic and anaerobic bacteria species in the dental biofilm, which is responsible for the fulminant nature of the necrotic process, should be considered for empiric antibiotic therapy.

## Conflict of Interests

None

## Funding

This research did not receive any specific grant from funding agencies in the public, commercial, or not-for-profit sectors.

## Ethical approval

This study was approved by the institutional ethical committee, in accordance with principles stated in the Declaration of Helsinki for Medical Research Involving 'Human Subjects'.

## Informed consent

Written informed consent was provided by all patients or children's legal guardians.

## Author's contribution

Conceptualisation, Methodology, Investigation, Writing original draft preparation, Reviewing and Editing: Imen Mehri Turki. The author has read and agreed to the published version of the manuscript.

## References

- Böttger S, Zechel-Gran S, Schmermund D, Streckbein P, Wilbrand JF, Knitschke M, *et al.* Odontogenic cervicofacial necrotizing fasciitis: microbiological characterization and management of four clinical cases. *Pathogens* 2022;11:78.
- Gore MR. Odontogenic necrotizing fasciitis: a systematic review of the literature. *BMC Ear Nose Throat Disord* 2018;18:14.
- Descamps V, Aitken J, Lee Martin G. Hippocrates on necrotising fasciitis. *Lancet* 1994;344:556.
- Wilson B. Necrotizing fasciitis. *Am Surg* 1952;18:416–431.
- Hohlweg-Majert B, Weyer N, Metzger MC, Schön R. Cervicofacial necrotizing fasciitis. *Diabetes Res Clin Pract* 2006;72:206–208.
- Hasham S, Matteucci P, Stanley PRW, Hart NB. Necrotising fasciitis. *BMJ* 2005;330:830–833.
- Bennani-Baïti AA, Benbouzid A, Essakalli-Hossyni L. Cervicofacial cellulitis: the impact of non-steroidal anti-inflammatory drugs. A study of 70 cases. *Eur Ann Otorhinolaryngol Head Neck Dis* 2015;132:181–184.
- King E, Chun R, Sulman C. Pediatric cervicofacial necrotizing fasciitis. *Arch Otolaryngol Head Neck Surg.* 2012;138:372–375.
- Seppänen L, Lauhio A, Lindqvist C, Suuronen R, Rautemaa R. Analysis of systemic and local odontogenic infection complications requiring hospital care. *J Infect* 2008;57:116–122.
- Mtenga AA, Kalyanyama BM, Owibingire SS, Sohal KS, Simon ENM. Cervicofacial necrotizing fasciitis among patients attending the Muhimbili National Hospital, Dar es Salaam, Tanzania. *BMC Infect Dis* 2019;19:642.
- Subhashraj K, Jayakumar N, Ravindran C. Cervical necrotizing fasciitis: an unusual sequel of odontogenic infection. *Med Oral Patol Oral Cir Bucal* 2008.
- Umeda M, Minamikawa T, Komatsubara H, Shibuya Y, Yokoo S, Komori T. Necrotizing fasciitis caused by dental infection: a retrospective analysis of 9 cases and a review of the literature. *Oral Surg Oral Med Oral Pathol Oral Radiol Endodontology* 2003;95:283–290.
- Stefanopoulos PK, Kolokotronis AE. The clinical significance of anaerobic bacteria in acute orofacial odontogenic infections. *Oral Surg Oral Med Oral Pathol Oral Radiol Endodontology* 2004;98:398–408.

14. Boscolo-Rizzo P, Da Mosto MC. Submandibular space infection: a potentially lethal infection. *Int J Infect Dis* 2009;13:327–333.
15. Mathew GC, Ranganathan LK, Gandhi S, Jacob ME, Singh I, Solanki M, *et al.* Odontogenic maxillofacial space infections at a tertiary care center in North India: a five-year retrospective study. *Int J Infect Dis* 2012;16:e296–e302.
16. Becker M, Zbären P, Hermans R, Becker CD, Marchal F, Kurt AM, *et al.* Necrotizing fasciitis of the head and neck: role of CT in diagnosis and management. *Radiology* 1997;202:471–476.
17. Tovi F, Fliss DM, Zirkin HJ. Necrotizing soft-tissue infections in the head and neck: a clinicopathological study. *Laryngoscope* 1991;101:619–625.
18. Rautaportas N, Uittamo J, Furuholm J, Gava MM, Snall J. Deep odontogenic infections – Computed tomography imaging-based spreading routes and risk for airway obstruction. *J Stomatol Oral Maxillofac Surg* 124:101424. doi: 10.1016/j.jormas.2023.101424
19. George N, Flamiatos E, Kawasaki K, Kim N, Carriere C, Phan B, *et al.* Oral microbiota species in acute apical endodontic abscesses. *J Oral Microbiol* 2016;8(1):30989.
20. Piovano S. Bacteriology of most frequent oral anaerobic infections. *Anaerobe* 1999;5:221–227.
21. Duerden BI. Virulence factors in anaerobes. *Clin Infect Dis* 1994;18(Suppl 4):S253–S259.
22. Wu DD, Ngowi EE, Zhai YK, Wang YZ, Khan NH, Kombo AF, *et al.* Role of hydrogen sulfide in oral disease. *Oxid Med Cell Longev* 2022;2022:1886277.
23. Deganello A, Gallo O, Gitti G, De Campora E. Necrotizing fasciitis of the neck associated with Lemierre syndrome. *Acta Otorhinolaryngol Ital* 2009;29:160–163.
24. Kwak OS, Kang MI, Kim JB, Kim MW, Kim YK. A rare case of facial *Candida albicans* cellulitis in an uncontrolled diabetic patient. *Mycoses* 2009;52:379–381.
25. Flynn TR. The swollen face. Severe odontogenic infections. *Emerg Med Clin North Am* 2000;18:481–519.
26. Delbet-Dupas C, Devoize L, Depeyre A, Mulliez A, Barthélémy I, Pham Dang N. Are routine microbiological samplings in acute dental infections justified? Our 10-year real-life experience. *J Stomatol Oral Maxillofac Surg* 2019;120:397–401.
27. Panda NK, Sridhar, Sridhara SR. Cervicofacial necrotizing fasciitis: can we expect a favourable outcome? *J Laryngol Otol* 2004;118:771–777.
28. Igoumenakis D, Giannakopoulos NN, Parara E, Mourouzis C, Rallis G. Effect of causative tooth extraction on clinical and biological parameters of odontogenic infection: a prospective clinical trial. *J Oral Maxillofac Surg* 2015;73:1254–1258.
29. Khalifa L, Shlezinger M, Beyth S, Houry-Haddad Y, Copenhagen-Glazer S, Beyth N, *et al.* Phage therapy against *Enterococcus faecalis* in dental root canals. *J Oral Microbiol* 2016;8:32157.
30. Larsen T, Fiehn NE. Dental biofilm infections – an update. *APMIS* 2017;125:376–384.
31. Gams K, Shewale J, Demian N, Khalil K, Banki F. Characteristics, length of stay, and hospital bills associated with severe odontogenic infections in Houston, TX. *J Am Dent Assoc* 2017;148:221–229.
32. Mello G de, Sixou JL, Jeandot J, Duran D, Feki A, Roche Y, *et al.* Etude comparative de l'association spiramycine-métronidazole et de l'amoxicilline dans le traitement des péricoronarites de l'adulte. *Méd Buccale Chir Buccale* 2003;9:159–165.
33. Basi SK, Cooper M, Ahmed FB, Clarke SG, Mitchell V. Reluctance of anaesthetists to perform awake intubation. *Anaesthesia* 2004;59:918.