



Conjunctival Impression Cytology and Tear Film Changes in Sarcoidosis: A Subjective and Objective Diagnosis Study

Özgür Eroğul*, Aydın Balcı**, Hamidu Hamisi Gobeka*, Neriman Efe*, Müberra Akdoğan*, Ayşe Yeşim Oral*, Mustafa Doğan*, Çiğdem Özdemir***, Murat Kaşıkçı****, Sinan Saraçlı*****

*Afyonkarahisar University of Health Sciences Faculty of Medicine, Department of Ophthalmology, Afyonkarahisar, Türkiye

**Afyonkarahisar University of Health Sciences Faculty of Medicine, Department of Chest Diseases, Afyonkarahisar, Türkiye

***Afyonkarahisar University of Health Sciences Faculty of Medicine, Department of Pathology, Afyonkarahisar, Türkiye

****Muğla Sıtkı Koçman University Training and Research Hospital, Clinic of Ophthalmology, Muğla, Türkiye

*****Afyonkarahisar Kocatepe University Faculty of Arts and Sciences, Department of Statistics, Afyonkarahisar, Türkiye

Abstract

Objectives: To evaluate sarcoidosis-induced tear film changes using subjective and objective diagnostic tests, particularly conjunctival impression cytology (IC), and to compare the results with healthy individuals.

Materials and Methods: This study evaluated clinical data collected between January 2019 and January 2021 from 57 right eyes of 57 sarcoidosis patients without ocular involvement (Group 1) and 33 right eyes of 33 healthy individuals with similar demographic characteristics (Group 2). The Schirmer I test, tear break-up time (TBUT), fluorescein staining, and conjunctival IC were all performed as part of the conjunctival and corneal examinations following a thorough ophthalmological examination. The Ocular Surface Disease Index (OSDI) was used to assess subjective ocular symptoms.

Results: The mean ages in Groups 1 and 2 were 49.26 ± 3.18 and 51.91 ± 2.89 years, respectively ($p=0.720$). The mean Schirmer I test, TBUT, and OSDI scores differed significantly ($p<0.05$ for all), with Group 1 having a significantly higher percentage of dry eyes than Group 2. Group 1 had significantly higher Nelson's grading system grades than Group 2 based on conjunctival IC analysis ($p=0.001$). There were no significant differences in visual acuity ($p=0.17$) or intraocular pressure ($p=0.14$) between groups.

Conclusion: Sarcoidosis patients had significantly higher Nelson grades in conjunctival IC, as well as significantly higher percentages of dry eye as determined by the Schirmer I test, TBUT, and OSDI. Reduced tear quantity and quality may destabilize the tear film layer, resulting in a variety of ocular symptoms.

Keywords: Impression cytology, Ocular Surface Disease Index, Nelson grading system, Sarcoidosis, Schirmer I test

Cite this article as: Eroğul Ö, Balcı A, Gobeka HH, Efe N, Akdoğan M, Oral AY, Doğan M, Özdemir Ç, Kaşıkçı M, Saraçlı S. Conjunctival Impression Cytology and Tear Film Changes in Sarcoidosis: A Subjective and Objective Diagnosis Study. *Turk J Ophthalmol* 2023;53:200-205

Address for Correspondence: Özgür Eroğul, Afyonkarahisar University of Health Sciences Faculty of Medicine, Department of Ophthalmology, Afyonkarahisar, Türkiye
E-mail: ozgur_erogul@hotmail.com ORCID-ID: orcid.org/0000-0002-0875-1517

Received: 18.07.2022 Accepted: 15.11.2022

DOI: 10.4274/tjo.galenos.2022.58153

Introduction

Sarcoidosis is a systemic disease of unknown etiology characterized by the presence of non-caseating granulomas.¹ It is most common in people under the age of 40, with clinical manifestations that are either diffuse or limited to one or two organs.² The diagnosis of sarcoidosis is generally complicated by the fact that symptoms may be absent or variable, and clinical and radiological signs may be confused with infections and/or malignancies.¹ After excluding other potential pathologies, sarcoidosis is diagnosed based on clinical, radiological, and laboratory findings, as well as the presence of non-caseating granulomatous inflammation.³

Sarcoidosis-induced granulomatous inflammation may involve all ocular structures, resulting in ocular sarcoidosis, which is one of the most important complications and has a prevalence of 13% to 79%.^{4,5} Ocular findings, however, are typically asymptomatic. If sarcoidosis is suspected, a routine ocular examination is therefore recommended.⁶ While the cause of sarcoidosis-induced dry eye symptoms is currently unknown, objective tests show that it could occur as a result of lacrimal gland inflammation and decreased tear production.^{7,8} Moreover, other etiologically similar systemic inflammatory diseases, such as rheumatoid arthritis, have been linked to an increased prevalence of dry eye.⁹ This could explain the decreased tear production caused by autoantibody-induced inflammation.

Conjunctival impression cytology (IC) is a minimally invasive technique that enables ocular examination, particularly for dry eye, in a clinical setting. This technique may be used for



diagnosis, understanding the disease mechanism, and assessing therapeutic efficacy. Over the last few years, conjunctival IC research has contributed to a better understanding of dry eye disease pathophysiology, as well as helping to confirm that ocular surface inflammation is clearly associated with clinical manifestations of this disease. Conjunctival IC research has also begun to elucidate the mechanism of action of inflammation, with studies indicating that dry eye disease is a Th1-mediated process and that local surface cells (e.g., conjunctival epithelial cells) rather than systemic cells play an important role in ocular inflammation. Cytokines released by infiltrating Th1 cells disrupt the normal cytokine balance on the ocular surface, resulting in ocular surface epithelial pathology. The results of conjunctival IC analysis have also provided justification for considering new treatments.¹⁰

This study was designed to evaluate sarcoidosis-induced tear film and ocular surface changes using subjective and objective diagnostic tests, particularly conjunctival IC, and to compare the results with those of healthy individuals.

Materials and Methods

Study Design and Participants

This retrospective observational study was conducted in accordance with the principles of the Helsinki Declaration and all applicable regulations and was approved by the Afyonkarahisar Health Sciences University Faculty of Medicine Ethics Committee (approval number: 2020/4-2011-KAEK-2). Each participant signed a written informed consent form. This study was supported by Afyonkarahisar Health Sciences University Scientific Research Project Commission (project number 21.KARİYER.005).

Clinical data collected between January 2019 and January 2021 from 57 sarcoidosis patients and 33 healthy individuals with similar demographic characteristics were evaluated. Sarcoidosis was diagnosed in the Chest Diseases Department based on findings from radiological (chest X-ray and computed tomography), clinical, and laboratory examinations, along with the presence of non-caseating granulomatous inflammation.

Inclusion and Exclusion Criteria

Sarcoidosis patients with no evidence of ocular involvement who were initially treated with corticosteroids and azathioprine (Imuran; ASPEN Europe GmbH, Feucht, Germany) in the Chest Diseases Department before discontinuing treatment for one year were included in the study. However, patients with features including (a) uveitis-related systemic diseases other than sarcoidosis that might also impact anterior segment characteristics; (b) current or recent (within 30 days) use of drugs affecting tear production such as antihistamines or tricyclic antidepressants or drugs used to treat sarcoidosis such as corticosteroids that may have an impact on anterior segment parameters; (c) a history of ocular surgery, trauma, or uveitis sequelae; (d) a history of other ocular pathologies, including pterygium, symblepharon, entropion, lagophthalmos, keratitis, corneal dystrophies and ectasia, glaucoma, and diabetic

retinopathy; (e) active vernal, allergic, infectious, and/or cicatricial conjunctivitis; (f) a nasal obstruction; (g) pregnancy; (h) contact lens use; and (i) heavy smoking (>10 cigarettes/day) or alcohol use (>2 standard drinks/week) were excluded from the study.

Ophthalmological Examination

All participants underwent a comprehensive ophthalmological examination. This included measurements of autorefractometry (Tonoref III; NIDEK, Japan, Tokyo), best-corrected visual acuity in logarithm of the minimum angle of resolution (logMAR), and intraocular pressure by Goldmann applanation tonometry (Goldmann; Haag-Streit AG, Köniz, Switzerland), as well as anteroposterior slit-lamp biomicroscopy. Anterior segment parameters such as anterior chamber angle (ACA), anterior chamber depth (ACD), anterior chamber volume (ACV), and central corneal thickness (CCT) were also measured using Sirius CSO® (Costruzione Strumenti Ophthalmici, Florence, Italy) corneal topography.

Furthermore, the Schirmer I test, tear break-up time (TBUT), corneal and conjunctival fluorescein staining, and conjunctival IC were performed as part of the conjunctival and corneal examinations, with a 10-minute break between each test. The Ocular Surface Disease Index (OSDI) was used to assess subjective ocular symptoms.

Schirmer I Test

In this test, performed with both eyes open without anesthesia, a standard filter paper (35x5 mm) was placed in the lower fornix between the outer and middle thirds of the lower eyelid to avoid any contact between the filter paper and cornea. Dry eye severity was determined based on the length of filter paper wetted as follows: normal (>10 mm), mild-moderate (6-10 mm), and severe (<5 mm).¹¹

Tear Break-up Time

In this test, a drop of fluorescein (0.375% proparacaine +0.25% sodium fluorescein) was initially instilled into the eye and dispersed by blinking. The quality of the tear film layer was then assessed at the slit-lamp using a wide beam and cobalt blue filter. Disease severity was classified based on the average time to the first dark spot as follows: normal (≥10 seconds), mild-moderate (5-9 seconds), and severe (<5 seconds).¹¹

Ocular Surface Staining

Corneal and conjunctival fluorescein staining was assessed using the Oxford grading scheme in another biomicroscopic examination of the ocular surface using a wide beam and cobalt blue filter. A score of zero denoted normal, 1-2 mild-moderate, and >2 severe disease.¹²

Conjunctival Impression Cytology

This minimally invasive technique for collecting cells from the ocular surface has recently gained popularity in the diagnosis of ocular surface diseases, contributing to a better understanding of ocular surface disease pathophysiology and providing biomarkers for use as outcome measures in clinical trials. The superficial layers of the epithelium are removed using cellulose acetate filters or Biopore membranes, and cells can then

be analyzed using a variety of methods depending on the purpose of the study or the pathology involved.

During the procedure, 0.5% proparacaine hydrochloride (Alcaine; Alcon Couvreur, Puurs, Belgium) was first instilled into the eye for optimal measurement.¹³ Cellulose acetate filter paper with pore sizes of 0.022 and 0.025 µm (11107-47-ACN, Sartorius Lab Instruments GmbH & Co. KG, Goettingen, Germany) was applied to the temporal bulbar conjunctiva for 3-5 seconds. To ensure the objectivity of the results, no pressure was applied to the cellulose acetate paper while sampling from the ocular surface. After that, the paper was slowly removed and immersed in the fixation solution (95% ethyl alcohol), which was kept in a refrigerator at +4 °C. Periodic acid-Schiff (PAS) and hematoxylin-eosin staining was then performed. A blinded operator used the Nelson classification system to assign a grade of 0, 1, 2, or 3 based on the following criteria:¹⁴

- Grade 0: Small and round epithelial cells, large nuclei, and an abundance of full, oval goblet cells.
- Grade 1: Slightly larger and more polygonal epithelial cells with smaller nuclei, fewer goblet cells, but still plump and oval in shape.
- Grade 2: Larger polygonal and occasionally multinucleated epithelial cells with smaller nuclei. Goblet cells are significantly fewer in number and smaller in size, with well-defined cellular boundaries.
- Grade 3: Larger and more polygonal epithelial cells with smaller and pycnotic nuclei. Goblet cells are completely absent.

Subjective Ocular Symptom Assessment

The OSDI scoring system was used to subjectively assess the symptoms of ocular irritation associated with dry eye disease. This system includes 12 questions divided into three sections: ocular symptoms (5 questions), visual functions (4 questions), and environmental trigger factors (3 questions). The score range is 0 to 4 (0 never, 4 always). The OSDI score is obtained by multiplying the total score of the answered questions by 25 and dividing by the number of answered questions. Symptoms are interpreted as absent (OSDI 0-12), mild (OSDI 13-32), and severe (OSDI 33-100).¹⁵ Higher total OSDI scores strongly correlate with dry eye severity.

Statistical Analysis

The entire data set was collected solely from the participants' right eyes. SPSS version 20 (IBM Corp., Armonk, NY, USA) was used for statistical analyses. In addition to descriptive statistics, the independent samples t-test was used to determine whether there were significant differences between groups for the related variables. The Pearson chi-square test was used to analyze the relationship between group and Nelson grade. A p value of <0.05 was considered statistically significant.

Results

This study evaluated data of 57 right eyes of 57 sarcoidosis patients (group 1) and 33 right eyes of 33 healthy individuals (group 2). Females outnumbered males in both groups, with female-to-male ratios of 41:16 (71.9%:28.1%) and 19:14

(57.6%/42.4%) in groups 1 and 2, respectively. Group 1 had mean disease and prior therapy durations of 3.87±0.13 and 1.49±0.08 years, respectively. [Table 1](#) shows the demographic characteristics of the participants.

Anterior Segment Parameter Analysis

There were no significant differences in ACD, ACV, ACA, or CCT between groups 1 and 2 (p>0.05) ([Table 2](#)).

Subjective and Objective Test Analysis

The mean Schirmer I test, TBUT, and OSDI scores differed significantly between groups 1 and 2 (p<0.05, for all) ([Table 3](#)). The percentages of dry eyes determined by Schirmer I test, TBUT, and OSDI were also significantly different, as shown in [Table 4](#), with group 1 having significantly higher percentages than group 2.

Conjunctival Impression Cytology Analysis

Epithelial changes were graded from 0 to 3 using Nelson's grading system for conjunctival IC ([Figure 1](#)). Group 1 had significantly higher grades relative to group 2 (p=0.001).

Table 1. Demographic characteristics of the participants

Parameters	Group 1, n=57, (mean ± SD)	Group 2, n=33, (mean ± SD)	p value
Age (years)	49.26±3.18	51.91±2.89	0.720
Best-corrected visual acuity (logMAR)	2.16±3.00	2.23±2.77	0.170
Intraocular pressure (mmHg)	13.87±2.65	14.28±2.76	0.140

Group 1: Sarcoidosis patients, Group 2: Healthy individuals, SD: Standard deviation, n: Number of participants

Table 2. Anterior segment parameters

Parameters	Group 1, n=57, (mean ± SD)	Group 2, n=33, (mean ± SD)	p value
Anterior chamber depth (mm)	290.16±34.37	289.03±21.42	0.865
Anterior chamber volume (µL)	144.49±29.50	142.88±13.63	0.768
Anterior chamber angle (degrees)	41.28±5.77	41.39±3.93	0.921
Central corneal thickness (µm)	536.44±34.93	535.24±27.54	0.867

Group 1: Sarcoidosis patients, Group 2: Healthy individuals, SD: Standard deviation, n: Number of participants

Table 3. Subjective and objective test results

Parameters	Group 1, n=57, (mean ± SD)	Group 2, n=33, (mean ± SD)	p value
Schirmer I test (mm)	6.67±2.84	13.97±1.38	<0.001
TBUT (s)	8.32±1.45	11.67±1.71	<0.001
OSDI	14.21±1.15	9.69±1.45	<0.001

Group 1: Sarcoidosis patients, Group 2: Healthy individuals, SD: Standard deviation, n: Number of participants, TBUT: Tear break-up time, OSDI: Ocular Surface Disease Index

Furthermore, group 1 had the most participants with grade 2 (47.4%), while group 2 had the most participants with grade 1 (60.6%) (Table 5). Pearson’s chi-square test revealed a statistically significant relationship ($p < 0.001$).

Table 4. Percentage of dry eyes in each group based on the respective ocular surface test

Parameters	Group 1 (n=57)	Group 2 (n=33)	p value
Schirmer I test	64.9%	11.2%	<0.001
TBUT	72.2%	27.3%	<0.001
OSDI	68.2%	25.2%	<0.001

Group 1: Sarcoidosis patients, Group 2: Healthy individuals, SD: Standard deviation, n: Number of participants, TBUT: Tear break-up time, OSDI: Ocular Surface Disease Index

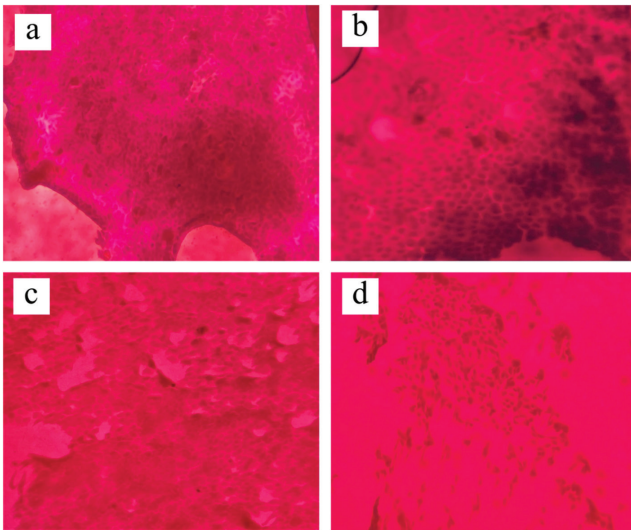


Figure 1. Nelson’s grading system for epithelial changes in conjunctival impression cytology. a) Grade 0: Epithelial changes in healthy individuals depicting the arrangement of conjunctival epithelial cells in dense clusters and the presence of many goblet cells with round nuclei and dark staining. b) Grade 1: A mild loss of cohesion in conjunctival epithelial cells, decreased goblet cell count, and polygonal-shaped cell nuclei in a sarcoidosis patient. c) Grade 2: A moderate loss of cohesion in conjunctival epithelial cells, the presence of goblet cells, shrinkage of cell nuclei, and more polygonal-shaped cells in a sarcoidosis patient. d) Grade 3: Severe loss of cohesion in conjunctival epithelial cells, absence of goblet cells, and presence of polygonal-shaped and pycnotic nuclei in a sarcoidosis patient (periodic acid-Schiff x200)

Table 5. Distribution of Nelson grading of conjunctival impression cytology in each group

	Group 1	Group 2
Grade 0	0	12 (36.4%)
Grade 1	7 (12.3%)	20 (60.6%)
Grade 2	27 (47.4%)	1 (3%)
Grade 3	23 (40.4%)	0
Total	57 (100%)	33 (100%)

Group 1: Sarcoidosis patients, Group 2: Healthy individuals

Discussion

Dry eye is a tear film disorder that damages the ocular surface in the palpebral fissure and is frequently associated with subjective complaints.^{16,17,18} This disorder is a common but frequently overlooked symptom that usually persists even after controlling sarcoidosis. Although biopsy is a simple technique for ruling out conjunctival granulomatous inflammation, its efficacy in diagnosing sarcoidosis is debatable, with low yields reported in some studies (directed and blind biopsies) and clinically visible areas of non-caseating granulomas being difficult to identify.¹⁹

On the other hand, conjunctival IC has been successfully used to investigate many aspects of dry eye disease, including the pathophysiology, monitoring clinical studies to determine the efficacy of various treatments, developing animal models of dry eye disease, and linking dry eye disease to other systemic diseases.²⁰ This method is primarily based on cell harvesting and processing, as well as subclinical inflammation detection methods such as flow cytometry and immunocytochemistry.^{21,22} Larmande and Timsit²³ reported in 1954 that conjunctival IC could be used to diagnose ocular surface squamous neoplasia. Egbert et al.²⁰ also reported in 1977 the use of IC with absorbent filter paper to obtain cells in the same manner that is still used today.

Our study revealed significantly higher IC grades in sarcoidosis patients versus healthy individuals using Nelson’s grading system, with the majority of patients displaying moderate loss of cohesion in conjunctival epithelial cells, a scarcity of goblet cells, shrinkage of cell nuclei, and more polygonal-shaped cells.¹⁴

The use of conjunctival IC to detect ocular surface changes has revealed that dry eye disease-specific changes are associated with a wide range of systemic and local conditions, indicating that this technique could be useful for assessing ocular surface changes in different conditions. This minimally invasive technique has the potential to provide detailed cytological data in both dry eyes and systemic diseases with ocular involvement, confirming the diagnosis of squamous metaplasia/dry eye.^{22,23}

Significant cellular modifications have been detected in conjunctival IC with severe dry eye, suggesting the efficacy of conjunctival IC in evaluating squamous metaplasia and monitoring treatment response.²⁴ Dry eye has been shown to be unaffected by the duration of inflammatory bowel disease (IBD), although IBD patients had three times the rate of dry eyes as controls.²⁵ In other studies, conjunctival IC did not distinguish between smokers and nonsmokers in terms of goblet cell density, nor did it distinguish between sarcoidosis and dry eye, both of which showed signs of ocular surface disease.^{26,27}

IC has typically been used to detect morphological changes in ocular surface disease, most notably squamous metaplasia, in dry eye disease. Conjunctival squamous metaplasia and subsequent goblet cell loss may result in decreased tear production, both in quantity and quality, as well as destabilization of the tear film layer, resulting in different ocular symptoms. In our study, goblet cell loss and conjunctival squamous metaplasia were more

common in sarcoidosis patients, in addition to conjunctival IC-confirmed ocular inflammation, demonstrating a positive correlation of this technique with other dry eye tests. Hence, conjunctival IC has become a valuable tool for assessing ocular surface changes and will almost certainly continue to provide valuable information for diagnosing and treating patients with ocular surface disorders.

Sarcoidosis-induced tear film disorder is commonly categorized as an aqueous phase tear film disorder.^{15,16,28,29} The most likely cause of lacrimal gland disorder is lymphocytic infiltration of the lacrimal gland during the acute inflammatory phase, but it could also be due to glandular tissue atrophy later on.³⁰ Low Schirmer I test levels and positive rose bengal tests have been recorded in 70% of sarcoidosis patients.²⁹ Likewise, the Schirmer I test values in our study were lower in 64.9% of sarcoidosis patients, highlighting the prevalence of aqueous phase disorders in this group and implying that many sarcoidosis patients could have disturbances in various phases of tear film disorder.

The aqueous phase tear film may collapse abruptly as a result of decreased lacrimal gland production. Since the expression of growth factors required for surface epithelial differentiation and function is reduced in the lacrimal glands, mucin phase dysfunction may also occur. Furthermore, in addition to clinically manifested conjunctival involvement, there could be subclinical diffuse subepithelial infiltration that impairs mucin production in the goblet cells of the conjunctival epithelium. Subclinical infiltration could also be to blame for meibomian gland dysfunctions (lipid phase). An improper lipid composition may cause increased epithelial proliferation or altered bacterial flora in the ostia of the meibomian glands.²⁸ The fluorescein test and conjunctival IC used in our study revealed clinically significant surface epithelial damage, but were insufficient to detect subepithelial infiltration.

The majority of sarcoidosis patients in our study had symptomatic dry eye, implying that tear film disorders could be much more common in sarcoidosis patients than is clinically presumed. Aside from all anterior segment parameters, the mean values of many dry eye parameters, including signs of blepharitis, TBUT, Schirmer I test, corneal and conjunctival fluorescein staining, OSDI scores, as well as conjunctival IC were significantly different in sarcoidosis patients versus healthy individuals. TBUT is the most sensitive parameter for detecting tear film instability and is commonly used to detect epithelial lesions.³⁰ This parameter was significantly shorter in sarcoidosis patients, who also had significantly higher grade in Nelson conjunctival IC analysis. Since almost all tests revealed the presence of significant dry eye in sarcoidosis patients, it is possible that sarcoidosis is associated with decreased tear production and tear film quality. The significantly higher rate of dry eye in sarcoidosis patients suggests that our findings correspond to prior reports. Moreover, tear film tests have been shown to be age-related, and dry eye becomes more common with aging. Given the findings in our study, where the mean age of sarcoidosis patients was 49.26 ± 3.18 years, it is reasonable

to assume that many sarcoidosis patients will develop dry eye symptoms later in life.

Study Limitations

There are some drawbacks to our study. The activation status of sarcoidosis patients with dry eye symptoms could not be determined. Thus, no statistical analysis was performed to determine whether there was a link between dry eye and sarcoidosis activity. Apart from ocular sarcoidosis-related dry eye symptoms, there was no record of other sarcoidosis manifestations, implying that the relationship between dry eye and other non-ocular sarcoidosis manifestations could not be assessed. It should also be noted that conjunctival IC has a number of drawbacks, including (a) a lack of standardization in the methodology used (i.e., type of membrane, fixation procedures, areas sampled, and processing/removal techniques), (b) sampling is generally limited to the outermost tissue layers, and (c) the effects of topical anesthetics on subsequent testing have not been thoroughly studied.

Despite its drawbacks, IC has several advantages, including being less invasive than conjunctival biopsies, scraping, or brush cytology; the ability to sample specific (or multiple) conjunctival areas; simultaneous demarcation of morphological data with biomarker analysis; the absence of basement membrane disruption; and providing a biochemical "snapshot" of tissue at that point in the disease course.

Conclusion

Both subjective and objective tests revealed significant differences between sarcoidosis patients and healthy individuals. Dry eye percentages determined by the Schirmer I test, TBUT, and OSDI were significantly higher in sarcoidosis patients. Nelson grades in conjunctival IC were also significantly higher in sarcoidosis patients. Decreased quantity and quality of tear production could ultimately destabilize the tear film layer, leading to different ocular symptoms, as evidenced by our findings that dry eye was significantly associated with sarcoidosis.

Ethics

Ethics Committee Approval: Afyonkarahisar University of Health Sciences Clinical Research Ethics Committee (no: 2011-KAEK-2/date: 03.04.2020).

Informed Consent: Obtained.

Peer-review: Externally and internally peer reviewed.

Authorship Contributions

Surgical and Medical Practices: Ö.E., A.B., N.E., Ç.Ö., M.K., Concept: Ö.E., A.B., N.E., M.D., H.H.G., M.M.K., Design: Ö.E., A.B., N.E., M.D., H.H.G., M.M.K., M.A., A.Y.O., S.S., Data Collection or Processing: Ö.E., A.B., H.H.G., M.K., S.S., Analysis or Interpretation: Ö.E., A.B., N.E., M.D., H.H.G., M.M.K., M.A., A.Y.O., S.S., Literature Search: Ö.E., A.B., H.H.G., Ç.Ö., M.K., Writing: Ö.E., A.B., H.H.G., M.D., Ç.Ö., M.K., S.S.

Conflict of Interest: No conflict of interest was declared by the authors.

Financial Disclosure: The study was supported by Afyonkarahisar Health Sciences University Scientific Research Project Commission (project no: 21.KARİYER.005).

References

- Soto-Gomez N, Peters JI, Nambiar AM. Diagnosis and Management of Sarcoidosis. *Am Fam Physician*. 2016; 93:840-848.
- Lill H, Kliiman K, Altraja A. Factors signifying gender differences in clinical presentation of sarcoidosis among Estonian population. *Clin Resp J*. 2016;10:282-290.
- Hunninghake GW, Costabel U, Ando M, Baughman R, Cordier JF, du Bois R, Eklund A, Kitaichi M, Lynch J, Rizzato G, Rose C, Selroos O, Semenzato G, Sharma OP. ATS/ERS/WASOG statement on sarcoidosis. American Thoracic Society/European Respiratory Society/World Association of Sarcoidosis and other Granulomatous Disorders. *Sarcoidosis Vasc Diffuse Lung Dis*. 1999;16:149-173.
- Heuser K, Kerty E. Neuro-ophthalmological findings in sarcoidosis. *Acta Ophthalmol Scand*. 2004; 82:723-729.
- Rothova A. Ocular involvement in sarcoidosis. *Br J Ophthalmol*. 2000;84:110-116.
- Lobo A, Barton K, Minassian D, du Bois RM, Lightman S. Visual loss in sarcoid-related uveitis. *Clin Exp Ophthalmol*. 2003; 31:310-316.
- Palm Ø, Moum B, Gran JT. Estimation of Sjögren's syndrome among IBD patients. A six year post-diagnostic prevalence study. *Scand J Rheumatol*. 2002;31:140-145.
- Hwang IP, Jordan DR, Acharya V. Lacrimal gland inflammation as the presenting sign of Crohn's disease. *Can J Ophthalmol*. 2001;36:212-213.
- Piper H, Douglas KM, Treharne GJ, Mitton DL, Haider S, Kitas GD. Prevalence and predictors of ocular manifestations of RA: is there a need for routine screening? *Musculoskeletal Care*. 2007;5:102-117.
- Nelson JD, Havener VR, Cameron JD. Cellulose acetate impressions of the ocular surface. Dry eye states. *Arch Ophthalmol*. 1983;101:1869-1872.
- Leung EW, Medeiros FA, Weinreb RN. Prevalence of ocular surface disease in glaucoma patients. *J Glaucoma*. 2008;17:350-355.
- Bron AJ, Evans VE, Smith JA. Grading of corneal and conjunctival staining in the context of other dry eye tests. *Cornea*. 2003;22:640-650.
- Calonge M, Diebold Y, Sáez V, Enríquez de Salamanca A, García-Vázquez C, Corrales RM, Herreras JM. Impression cytology of the ocular surface: a review. *Exp Eye Res*. 2004;78:457-472.
- Nelson JD. Impression cytology. *Cornea*. 1988;7:71-81.
- Karma A, Taskinen E, Kainulainen H, Partanen M. Phenotypes of conjunctival inflammatory cells in sarcoidosis. *Br J Ophthalmol*. 1992;76:101-106.
- Bron AJ. The Doyne Lecture. Reflections on the tears. *Eye (Lond)*. 1997;11:583-602.
- Nicolaidis N, Kaitaranta JK, Rawdah TN, Macy JI, Boswell FM 3rd, Smith RE. Meibomian gland studies: comparison of steer and human lipids. *Invest Ophthalmol Vis Sci*. 1981;20:522-536.
- Pflugfelder SC, Tseng SC, Sanabria O, Kell H, Garcia CG, Felix C, Feuer W, Reis BL. Evaluation of subjective assessments and objective diagnostic tests for diagnosing tear-film disorders known to cause ocular irritation. *Cornea*. 1998;17:38-56.
- Hunter DG, Foster CS. Ocular manifestations of sarcoidosis. In: Albert DM, Jakobiec FA, eds. *Principles and Practice of Ophthalmology*. Philadelphia: WB Saunders. 1994;1217-1224.
- Egbert PR, Lauber S, Maurice DM. A simple conjunctival biopsy. *Am J Ophthalmol*. 1977;84:798-801.
- Baudouin C, Brignole F, Becquet F, Pisella PJ, Goguel A. Flow cytometry in impression cytology specimens. A new method for evaluation of conjunctival inflammation. *Invest Ophthalmol Vis Sci*. 1997;38:1458-1464.
- Brignole-Baudouin F, Ott AC, Warner JM, Baudouin C. Flow cytometry in conjunctival impression cytology: a new tool for exploring ocular surface pathologies. *Exp Eye Res*. 2004;78:473-478.
- Larmande A, Timsit E. L'intérêt du cyto-diagnostic en ophtalmologie: communication préliminaire à propos de huit cas de tumeurs du limbe scléro-cornéen [Importance of cytodagnosis in ophthalmology: preliminary report of 8 cases of tumors of the sclero-corneal limbus]. *Bull Soc Ophtalmol Fr*. 1954;5:415-419.
- Jirsova K, Brejchova K, Krabcova I, Filipec M, Al Fakih A, Palos M, Vesela V. The application of autologous serum eye drops in severe dry eye patients; subjective and objective parameters before and after treatment. *Curr Eye Res*. 2014;39:21-30.
- Doğan M, Özcan S, Acartürk G, Özdemir Ç. Conjunctival Impression Cytology and Tear-Film Changes in Patients With Inflammatory Bowel Disease. *Eye Contact Lens*. 2018;44:420-425.
- Altınors DD, Akça S, Akova YA, Bilezikçi B, Goto E, Dogru M, Tsubota K. Smoking associated with damage to the lipid layer of the ocular surface. *Am J Ophthalmol*. 2006;141:1016-1021.
- Heiligenhaus A, Wefelmeyer E, Schrenk M. Tränenfilmstörungen bei Patienten mit Sarkoidose - eine klinische Studie an 56 Patienten [Tear-film deficiencies in patients with sarcoidosis; clinical study of 56 patients]. *Klin Monbl Augenheilkd*. 2002;219:502-506.
- Bron AJ. Duke-Elder lecture. Prospects for the dry eye. *Trans Ophthalmol Soc U K*. 1985;104:801-826.
- Crick RP, Hoyle C, Smellie H. The Eyes In Sarcoidosis. *Br J Ophthalmol*. 1961;45:461-481.
- Smith JA, Chan CC, Egwuagu CE, Whitcup SM. Immunohistochemical examination of lacrimal gland tissue from patients with ocular sarcoidosis. *Adv Exp Med Biol*. 1998;438:599-602.