



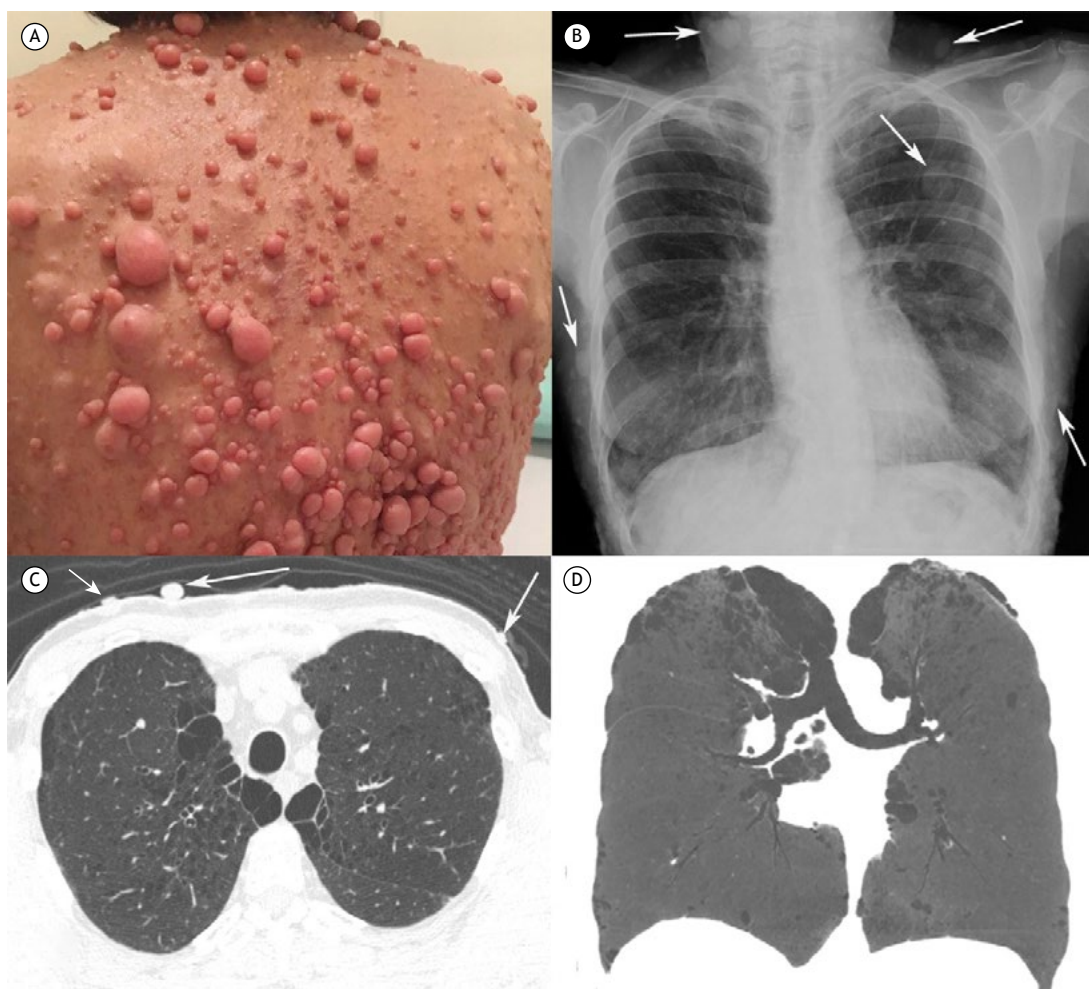
## Pulmonary emphysema associated with skin nodules

Luciana Volpon Soares Souza<sup>1</sup>, Arthur Soares Souza Jr<sup>1,2</sup>, Edson Marchiori<sup>3</sup>

A 55-year-old nonsmoking female patient with a known diagnosis of neurofibromatosis type 1 (NF1) since adolescence presented with a two-month history of dyspnea and cough. During adolescence, she developed subcutaneous and cutaneous neurofibromas predominantly on the chest wall (Figure 1A). In addition, she had café au lait spots on the skin. The patient's brother also had NF1. She denied fever. Laboratory test findings, including alpha-1 antitrypsin levels, were normal. No pulmonary function testing was performed. A chest X-ray showed multiple soft-tissue nodules on

the chest wall (Figure 1B). Chest CT demonstrated bilateral emphysematous changes with subpleural bullae, predominantly in the upper lobes, along with several cutaneous and subcutaneous nodules (Figures 1C and 1D). A diagnosis of neurofibromatosis-associated diffuse lung disease was established.

NF1 or von Recklinghausen's disease is a genetic disorder characterized by multiple tumors of ectodermal and mesodermal tissues. The disease has a varied clinical presentation, with subcutaneous and cutaneous neurofibromas, café au lait spots on the skin, and iris



**Figure 1.** In A, a photograph of the dorsal region of the chest showing multiple cutaneous neurofibromas. In B, a chest X-ray shows multiple soft-tissue nodules on the chest wall (arrows). In C and D, respectively, an axial chest CT image (lung window) at the level of the upper lobes and a coronal minimum intensity projection image show emphysematous lesions predominantly in the upper lobes. Note also nodules (neurofibromas) on the chest wall (arrows in C).

1. Ultra X, São José do Rio Preto (SP) Brasil.  
2. Faculdade de Medicina de Rio Preto, São José do Rio Preto (SP) Brasil.  
3. Universidade Federal do Rio de Janeiro, Rio de Janeiro (RJ) Brasil.

hamartomas (Lisch nodules) being most common. Diffuse lung disease associated with NF1 consists of an emphysematous, cystic, or bullous process with upper lobe predominance. Varying amounts of fibrosis and ground-glass opacity are also present.<sup>(1-3)</sup>

## AUTHOR CONTRIBUTIONS

The authors equally contributed to this work.

## CONFLICTS OF INTEREST

None declared.

---

## REFERENCES

1. Zamora AC, Collard HR, Wolters PJ, Webb WR, King TE. Neurofibromatosis-associated lung disease: a case series and literature review. *Eur Respir J*. 2007;29(1):210-214. <https://doi.org/10.1183/09031936.06.00044006>
2. Shino MY, Rabbani S, Belperio JA, Lynch JP 3rd, Weigt SS. Neurofibromatosis-associated diffuse lung disease: case report. *Semin Respir Crit Care Med*. 2012;33(5):572-575. <https://doi.org/10.1055/s-0032-1325165>
3. Ueda K, Honda O, Satoh Y, Kawai M, Gyobu T, Kanazawa T, et al. Computed tomography (CT) findings in 88 neurofibromatosis 1 (NF1) patients: Prevalence rates and correlations of thoracic findings. *Eur J Radiol*. 2015;84(6):1191-1195. <https://doi.org/10.1016/j.ejrad.2015.02.024>