



# The Effect of Carvacrol Plus Treadmill Exercise on Testis Structure and Oxidative Stress in Streptozotocin-Induced Diabetic Rats

Ramesh Bradaran Bagheri<sup>1\*</sup>, Jamal Shadman<sup>2</sup>, Amir Afshin Khaki<sup>3</sup>

## Abstract

**Objectives:** This study aimed to evaluate the effect of carvacrol and treadmill exercise on oxidative stress and testis structure in streptozotocin (STZ)-induced diabetic rats.

**Materials and Methods:** In this experimental study, the diabetes was induced using a single intraperitoneal (IP) injection of STZ (50 mg/kg). The rats were assigned to five groups, namely a control group, a diabetic control group, a diabetic group receiving daily carvacrol at a dose of 75 mg/kg, diabetic groups performing treadmill exercise, and a diabetic group performing daily treadmill exercise and receiving carvacrol. After covering the treatment period, all rats were anesthetized and their blood sample were taken. Then the serum levels of oxidative stress markers were measured, the testicles and epididymis were removed, and the sperm parameters were assessed.

**Results:** The treatment of diabetic rats with carvacrol and treadmill exercise effectively improved testis tissue damage, sperm parameters, glucose, and insulin plasma levels ( $P=0.001$ ). In diabetic rats, the level of malondialdehyde (MDA) increased while the activity of superoxide dismutase (SOD) and catalase (CAT) enzymes decreased in the testes tissue ( $P=0.001$ ). However, when carvacrol administration (75 mg/kg) was combined with treadmill exercise, these parameters were significantly rectified ( $P<0.05$ ).

**Conclusion:** In sum, administering carvacrol and performing treadmill exercise were effective in improving the sperm parameters and testicular oxidative damage caused by diabetes.

**Keywords:** Oxidative stress, Diabetes, Treadmill exercise, Carvacrol, Testis, Sperm parameters

## Introduction

Diabetes mellitus, a chronic metabolic disorder characterized by hyperglycemia, has become a global health concern with increasing prevalence rates. It is well established that diabetes can lead to various complications affecting multiple organ systems, including the reproductive system. Diabetes-induced oxidative stress, in particular, has been implicated in the pathogenesis of testicular dysfunction. Oxidative stress occurs when the balance between reactive oxygen species (ROS) production and antioxidant defense mechanisms is disrupted, resulting in an excess of ROS. This imbalance can lead to cellular damage, impairing the structure and function of the testis (1-3).

Carvacrol, a phenolic compound present in various plants such as oregano and thyme, has shown promising antioxidant and anti-inflammatory properties. Several studies have reported the beneficial effects of carvacrol in mitigating the oxidative stress and reducing the complications associated with diabetes. Furthermore, exercise has been recognized as an effective strategy for managing diabetes and its complications. Regular physical activity, such as treadmill exercise, has been found to

improve the glycemic control, enhance the antioxidant capacity, and ameliorate the testicular dysfunction in diabetic animals (4-6).

However, the effect(s) of carvacrol supplementation combined with treadmill exercise on testis structure and oxidative stress in streptozotocin (STZ)-induced diabetic rats have not been extensively investigated. STZ is a chemical compound widely used to induce experimental diabetes due to its ability to selectively destroy pancreatic beta cells. Therefore, understanding the potential synergistic effects of carvacrol and exercise in the context of diabetes-induced testicular dysfunction is of great importance (7,8).

This study, therefore, aimed to evaluate the effect of carvacrol supplementation combined with treadmill exercise on testis structure and oxidative stress in STZ-induced diabetic rats. The assessment of testicular structure required histopathological examinations, including an examination of parameters such as seminiferous tubule diameter, epithelial thickness, and germ cell population. Additionally, markers of oxidative stress, such as lipid peroxidation levels and antioxidant enzyme activity, were evaluated to determine the effectiveness of carvacrol

Received 10 January 2023, Accepted 11 July 2023, Available online 20 July 2023

<sup>1</sup>Department of Obstetrics and Gynecology, Faculty of Medicine, Kamali Hospital, Alborz University of Medical Sciences, Karaj, Iran.

<sup>2</sup>Clinical Research Development Unit of Tabriz Valiasr Hospital, Tabriz University of Medical Sciences, Tabriz, Iran.

<sup>3</sup>Women's Reproductive Health Research Center, Tabriz University of Medical Sciences, Tabriz, Iran.

\*Corresponding Author: Ramesh Bradaran Bagheri, Email: r.bradaranbagheri@yahoo.com



## Key Messages

- ▶ Diabetes can cause the testis damage.
- ▶ Treatment with carvedilol and treadmill exercise may have improved this damage.

plus exercise in ameliorating oxidative damage. Our study findings may have provided valuable insights into the potential therapeutic benefits of using carvedilol and performing exercise for preventing the diabetes-induced testicular dysfunction and oxidative stress.

## Materials and Methods

### Animals and Experimental Design

A total of 40 adult male Wistar rats weighing between 200-250 g were included in this experimental study. The rats were housed in standard cages under controlled environmental conditions, including a room temperature of  $23 \pm 2^\circ\text{C}$ , 40-50% humidity, and a 12/12-hour light-dark cycle. Free access to water and standard rat chow was provided to all animals throughout the study.

The rats were randomly assigned to five groups, each of which consisted of eight rats. The groups included a healthy control group (G1), a diabetic control group (G2), a diabetic group treated daily with 75 mg/kg of carvedilol for 8 weeks (G3), a diabetic group performing treadmill exercise for 8 weeks and receiving daily carvedilol (G4), and a group of Wistar rats from diabetic group undergoing training for eight weeks and receiving 75 mg/kg of carvedilol (G5). Diabetes was induced in the experimental groups by administering a single intraperitoneal injection of 50 mg/kg of STZ solution in 0.01 M citrate buffer (pH=4.5), as practiced in previous studies (1). The blood glucose levels of the rats were checked 72 hours after the STZ injection, and the rats with blood glucose levels higher than 250 mg/dL were considered diabetic.

In summary, 40 male Wistar rats were included in this study and assigned to different experimental groups in order to investigate the effects of carvedilol supplementation and treadmill exercise on diabetic-induced conditions. The induction of diabetes was achieved by STZ injection, and the blood glucose levels were monitored to confirm the development of diabetes in the rats (1).

### Treadmill Exercise Protocol

After covering a 72-hour period of adaptation, the Treadmill Exercise Protocol (TEM) was followed for a duration of eight weeks, with a frequency of 1 hour per day, five days per week, and no slope ( $0^\circ$ ). The first week of the protocol was aimed at acclimating the rats to moderate-intensity exercise, gradually increasing both the duration and speed of the exercise sessions. After a week, each exercise session was designed to consist of three periods: (a) a 5-minute warm-up period at 30% of the maximum speed ( $S_{\text{max1}}$ ), (b) a 50-minute period of moderate-intensity exercise at 60% of  $S_{\text{max1}}$ , and (c) a

recovery period ranging from 5 minutes to 30% of  $S_{\text{max1}}$ . To provide the rats with additional stimulation, a low-intensity electric stimulus (ranging from 1.5-2.0 mA) was applied to the back of each lane where they ran (9).

### Histopathological Examination of Testis

To assess the histopathological changes in the seminiferous tubules of the testicles, the tissue samples were fixed and then subjected to a series of procedures. First, the samples were dehydrated to remove water content. Subsequently, the samples were cleared to remove any remaining solvents, and then embedded in paraffin to facilitate sectioning. Thin slices of the testicular tissue were prepared on slides. These tissue slides were then examined under a microscope at a magnification of 400x. The histopathological damage to the seminiferous tubules was assessed, and the number of germ cells present in the tubules was counted. This analysis provided valuable information about the structural changes and cell population within the seminiferous tubules of the testicles. The assessment at high magnification facilitated the detailed examination of the tissue and the accurate quantification of germ cells. The counting of germ cells served as an indicator of the overall health and function of the testicular tissue.

### Measurement of Lipid Peroxidation

To measure the level of lipid peroxidation in the testis tissue, the concentration of malondialdehyde (MDA) was determined. To this end, a solution of thiobarbituric acid (TBA), hydrochloric acid (HCl), and trichloroacetic acid (TCA) was prepared. Firstly, 375 mg of TBA was dissolved in 2 mL of HCl to create the TBA-TCA-HCl solution. This solution was then added to 100 mL of 15% TCA. To ensure the complete dissolution of sediment, the mixture was heated in a  $50^\circ\text{C}$  water bath.

Next, a slice of the testis tissue was weighed and immediately homogenized with a 5.1% potassium chloride solution to obtain a 10% homogenized mixture. Subsequently, 1 cc of the homogenized tissue mixture was added to 2 mL of the TBA-TCA-HCl solution, and the obtained mixture was heated in boiling water for 45 minutes, resulting in a pink-orange solution. After cooling, the mixture was centrifuged at 1000 rpm for 10 minutes. The absorbance (A) of the resulting supernatant was measured using a spectrophotometer at a wavelength of 535 nm.

### Determination of SOD and GPX activity

The concentrations of superoxide dismutase (SOD) and glutathione peroxidase (GPX) in the testis tissue were measured using an ELISA reader (Antus) following the manufacturer's instructions provided by the Ransod kit (UK). The ELISA reader facilitated the quantitative determination of SOD and GPX levels in the testis tissue samples. The specific protocols provided by the

manufacturer were followed to ensure the accuracy and reliability of the measurements. This assay provided valuable information about the antioxidant enzyme activity in the testicular tissue, as SOD and GPX are key enzymes involved in the defense against oxidative stress. The results obtained from the ELISA reader provided quantitative data on the concentrations of SOD and GPX, shedding light on the antioxidant status of the testis tissue in the experimental setting.

#### Evaluation of Sperm Parameters

The epididymis of all rats was dissected from both testes and washed before being placed in 5 mL of HAMS F10 medium. The epididymis was then finely chopped and incubated in a CO<sub>2</sub> incubator at 37 °C for 30 minutes. After incubation, 100 microliters of the solution were taken and mixed with 900 µL of HAMS F10 medium. This process was repeated for each sample. One drop of the resulting solution was placed into Neubauer's chamber for sperm counting, following the standard protocol. The total number of sperms was calculated by multiplying the count by the appropriate correction factor,  $\times 10^6/\text{mL}$  (10).

For assessing sperm morphology, smears of sperm were prepared on slides. The slides were fixed with 96% alcohol and air-dried, which facilitated the morphological examination of sperm. All slides were stained with hematoxylin and eosin (H&E) staining. A total of 100 sperm were counted on each slide, and the number of normal and abnormal sperm was determined and expressed as a percentage. This analysis provided valuable insights into the quality and morphology of the sperms, facilitating the evaluation of reproductive function and potential fertility issues in the experimental rats (10).

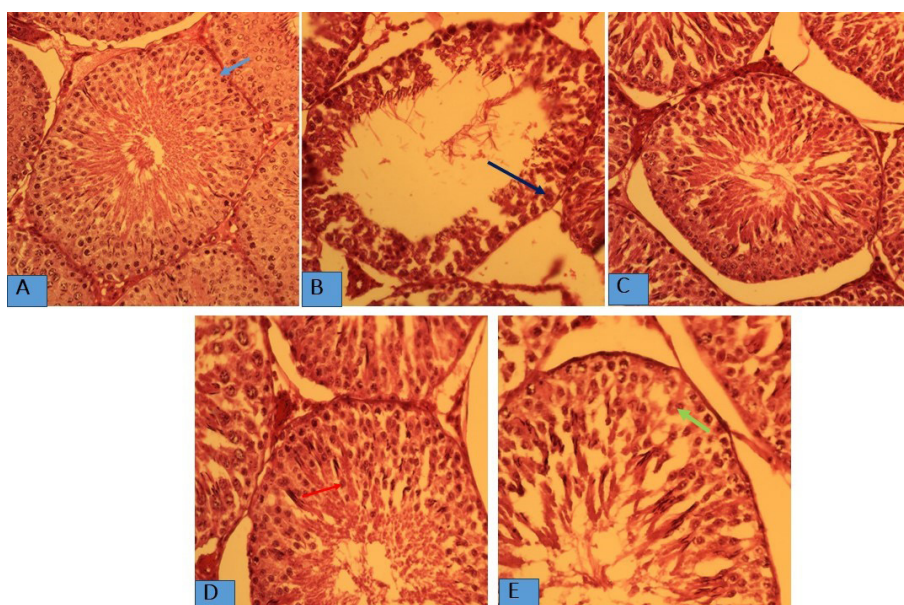
#### Statistical Analysis

Statistical analyses were performed using the SPSS software, version 19. The results were presented as mean  $\pm$  standard deviation (SD). One-way analysis of variance (ANOVA) followed by Tukey's range test was conducted to analyze the data. A *P* value of  $\leq 0.05$  was considered statistically significant, indicating a significant difference between the groups being compared. This statistical approach facilitated the assessment of significant variations and comparisons between the experimental groups, providing insights into the effects of the interventions on the measured parameters.

#### Results

##### The Histological Finding

The results of germ cell counting revealed a significant decrease in the number of germ cells in the diabetic group compared to the control group ( $P < 0.05$ ). However, in the treated groups, including the diabetic rats receiving 75 mg/kg carvacrol and performing treadmill exercise, the number of germ cells was significantly higher than that in the diabetic control group ( $P < 0.05$ ). Histopathological examination of the seminiferous tubules in the diabetic group showed irregularities in their structure, reduced diameter and thickness, and presence of hemorrhage. In the groups treated with carvacrol and treadmill exercise, in contrast, these damages were attenuated, and the seminiferous tubules exhibited improved histopathological features. These findings suggested that the combined intervention of carvacrol supplementation and treadmill exercise exerted a protective effect on testicular structure and preserved the population of germ cells in STZ-induced diabetic rats (Figure 1, Table 1).



**Figure 2.** Histological Assessment of Testicle in Study Groups. A: sham group; B: diabetic group; C: diabetic+ carvacrol; D: diabetic+ exercise; and E: diabetic +exercise+ carvacrol. Blue arrow indicates spermatogonia, black arrow indicates Sertoli cell, green arrow indicates primary spermatocyte, and red arrow indicates round spermatid.

**Table 1.** The Count of Germ Cell in Study Groups

Groups	Round Spermatic	Primary Spermatocytes	Spermatogonia Cells	Sertoli Cells
Control	210.01±2.85	105.41±4.25	36.41±1.05	28.20±2.17
Diabetic	95.41±4.07	70.12±2.60	15.87±2.35	18.22±1.65
Diabetic + carvacrol	182.65±7.45 <sup>a,b</sup>	95.15±3.17 <sup>a,b</sup>	25.18±2.03	23.45±4.35
Diabetic + exercise	180.34±3.90 <sup>a,b</sup>	97.18±4.36 <sup>a,b</sup>	23.54±1.42 <sup>a</sup>	22.50±3.15
Diabetic+ carvacrol + exercise	175.55±2.35 <sup>a,b</sup>	100.50±2.45 <sup>a,b</sup>	27.45±1.09	23.66±1.18

<sup>a</sup> shows significant difference between control group and diabetic group, and <sup>b</sup> shows significant difference between diabetic group and diabetic treatment groups ( $P<0.05$ ).

### The Oxidative Stress Markers

A significant increase in the levels of MDA was observed in the testis of diabetic rats compared to those from the control group ( $P=0.001$ ). However, the treatment of diabetic rats with carvacrol and treadmill exercise significantly reduced the elevated levels of MDA in the testicular tissue caused by diabetes ( $P=0.001$ ). These findings indicated that diabetes significantly decreased the activity of the catalase (CAT) enzyme compared to the control group ( $P=0.001$ ). Treatment of diabetic rats with carvacrol and treadmill exercise resulted in notable differences compared to the untreated diabetic group ( $P=0.001$ ). Furthermore, the activity of SOD showed a significant decrease in the diabetic group compared to the control group ( $P=0.001$ ). When comparing the therapy groups with the diabetic group, however, a significant increase was observed in the activity of the SOD enzyme ( $P=0.001$ ) (Table 2).

### The Sperm Count, Morphology, and Motility

The diabetic group exhibited a significant decrease in the number of sperms compared to the control group ( $P=0.001$ ). In both therapeutic groups (i.e., groups receiving carvacrol and treadmill exercise), however, the number of sperms was significantly increased compared to that in the diabetic group ( $P=0.001$ ). In the diabetic group, the number of abnormal sperm increased compared to the control group ( $P=0.001$ ). The number of abnormal sperms was significantly reduced in the group treated with carvacrol and treadmill exercise compared to the diabetic group ( $P=0.001$ ). Furthermore, the motility of sperm was significantly decreased in the diabetic group compared to the control group ( $P=0.001$ ) (Table 3).

### Discussion

In the present study, the potential protective effects of carvacrol supplementation and treadmill exercise

**Table 2.** The Concentration of MDA, CAT, and SOD in Rat's Testes Tissues of Four Groups

Groups	MDA Mean ± SE	GPX Mean ± SE	SOD Mean ± SE
Control	0.65 ± 0.15	1.85 ± 0.057	1.68 ± 0.12
Diabetic	1.80 ± 0.35 <sup>a</sup>	0.72 ± 0.048 <sup>a</sup>	0.60 ± 0.08 <sup>a</sup>
Diabetic + carvacrol	0.92 ± 0.17 <sup>a,b</sup>	1.22 ± 0.072 <sup>b</sup>	1.15 ± 0.15 <sup>a,b</sup>
Diabetic + exercise	1.00 ± 0.12 <sup>a</sup>	1.05 ± 0.10 <sup>b</sup>	1.35 ± 0.14 <sup>a,b</sup>
Diabetic+ carvacrol + exercise	0.89 ± 0.08 <sup>a</sup>	1.32 ± 0.084 <sup>b</sup>	1.25 ± 0.22 <sup>a,b</sup>

<sup>a</sup> In comparison with control group ( $P=0.001$ ) and <sup>b</sup> in comparison with diabetic group ( $P=0.001$ ).

**Table 3.** The Comparison of Sperm Parameters After Treatment Period

Groups	Sperm Count Mean ± SE (x10 <sup>6</sup> )	Morphology Mean ± SE	Sperm motility Mean ± SE
		Normal	Motile
Control	45.60 ± 3.48	75.4 ± 4.2	73.6 ± 4.8
Diabetic	18.5 ± 1.59 <sup>a</sup>	25.2 ± 2.54 <sup>a</sup>	11.25 ± 3.03 <sup>a</sup>
Diabetic + carvacrol	30.45 ± 5.98 <sup>a,b</sup>	46.12 ± 3.2 <sup>a,b</sup>	51.45 ± 2.24 <sup>a,b</sup>
Diabetic + exercise	28.85 ± 3.18 <sup>a,b</sup>	42.62 ± 2.5 <sup>a,b</sup>	46.5 ± 5.2 <sup>a,b</sup>
Diabetic+ carvacrol + exercise	32.60 ± 4.48 <sup>a,b</sup>	48.4 ± 2.07 <sup>a,b</sup>	47.6 ± 3.13 <sup>a,b</sup>

<sup>a</sup> shows significant difference between control group and diabetic group, and <sup>b</sup> shows significant difference between diabetic group and diabetic treatment groups ( $P<0.05$ ).

on diabetes-induced injuries in the male reproductive system were investigated. Diabetes is known to cause dysfunctions in the male reproductive organs; however, the treatment with carvacrol accompanied by exercise in this study was found to improve these functional deficiencies, which may have been attributed to the antioxidant and anti-diabetic properties of carvacrol. Furthermore, continuous treadmill exercise was detected to regulate the oxidative stress markers and enhance the activity of antioxidant enzymes. These findings suggested that carvacrol supplementation plus treadmill exercise had the potential to ameliorate the negative effects of diabetes on the male reproductive system and to exert beneficial effects on reproductive function (11,12). The results of the present study also demonstrated that carvacrol and treadmill exercise reduced the blood glucose levels in diabetic rats. Additionally, the levels of oxidative stress markers in the testis were decreased. This hypoglycemic effect of carvacrol and treadmill exercise may have been due to the increased sensitivity of tissues to insulin. By enhancing insulin sensitivity, carvacrol and exercise can improve glucose uptake and utilization by cells, resulting in lower blood glucose levels. Furthermore, the reduction in oxidative stress markers suggested that carvacrol and exercise may have exerted antioxidant effects, helping to counteract the detrimental effects of diabetes-induced oxidative stress on the testis. These findings highlighted the potential of carvacrol supplementation plus exercise as a therapeutic approach for managing diabetes and its associated complications in the male reproductive system (13,14).

In individuals with diabetes, there is not only an elevated level of blood glucose but also an interruption in the equilibrium between the production and resolution of "free radicals". Consequently, free radicals accumulate and trigger oxidative stress. Oxidative stress leads to cellular injury through mechanisms such as "lipid peroxidation" and oxidative damage to DNA and proteins. Our research findings revealed that diabetes significantly increased the levels of MDA (i.e., a marker of lipid peroxidation) in the testes of diabetic rats. These findings were consistent with the results of several earlier studies investigating the oxidative stress in the testes of diabetic rats (5,15,16). Therefore, the observed elevation of MDA in the testes of the diabetic group highlighted the increased occurrence of "lipid peroxidation". In this study, the diabetic rats receiving carvacrol (i.e., a compound found in certain plants) and continuous exercise experienced a noteworthy reduction in MDA levels within their testicular tissue. Previous research has indicated that the flavonoids present in carvacrol possess the ability to neutralize the free radicals generated during the lipid peroxidation (17,18). The observed decrease in MDA concentration in the testes of the treated groups receiving carvacrol and performing treadmill exercise may have been attributed to the antioxidant properties of carvacrol as well as to

the impact of continuous exercise using a treadmill. Both carvacrol's antioxidant effects and physiological effects of the regular exercise contributed to the reduction of the MDA levels.

According to our research findings, the activity of SOD was significantly decreased in the diabetic rats, which was consistent with the results from previous studies reporting a decline in SOD activity in diabetic conditions (15). SOD, as an integral component of the antioxidant system, plays a crucial role in catalyzing the conversion of superoxide anion radicals into hydrogen peroxide ( $H_2O_2$ ). This enzymatic process effectively reduces the toxicity associated with superoxide and prevents the generation of additional free radicals from superoxide. Thus, SOD acts as a vital enzyme in maintaining the balance of ROS and preserving cellular health (19). According to our study findings, moreover, the activity of SOD was significantly increased in the testes of diabetic rats treated with carvacrol and treadmill exercise compared to the diabetic group. This finding suggested that a combination of carvacrol treatment and treadmill exercise was positively effective in enhancing SOD activity in diabetic conditions.

Additionally, another important antioxidant enzyme known as GPX has been reported to exhibit detoxification effects against free radicals (20). In our study, a significant decrease was observed in the activity of GPX enzyme in diabetic rats compared to the control group. However, the activity of GPX was significantly increased in the therapy groups treated with carvacrol and exercise compared to the diabetic group.

The observed decline recorded for the CAT activity in this study may have been attributable to the increased generation of  $H_2O_2$  resulting from the autoxidation of glucose and the process of non-enzymatic protein glycation. These factors contribute to the production of oxygen-free radicals, which can interfere with the normal functioning of CAT (21). In effect, it is well-established that antioxidant therapy and continuous exercise can lead to an increased activity of GPX. This finding was consistent with that of our study, documenting a notable enhancement in GPX activity following the antioxidant therapy with carvacrol and continuous exercise. These interventions likely contribute to the improvement of antioxidant defense mechanisms, leading to an increased activity of GPX. Our study results demonstrated that diabetes had a detrimental effect on various sperm parameters such as count, motility, and morphology. However, the treatment with carvacrol and treadmill exercise produced positive effects by enhancing the sperm count and improving the sperm motility and morphology in diabetic rats. These improvements may have been due to the antioxidant capacity of carvacrol and the impact of continuous exercise, which can activate the antioxidant enzymes to counteract the damaging effects of the free radicals.

These findings were in line with the results from

previous research indicating that those medicinal plants containing flavonoid components had the potential to enhance the sperm quality and increase the testosterone levels. The beneficial effects observed in our study further supported the effectiveness of natural compounds (e.g., carvacrol) and regular exercise in improving the sperm parameters and overall reproductive health in the context of diabetes (5,16,22,23).

The possible mechanisms underlying the improvement of testicular oxidative stress in diabetic rats through the administration of carvacrol and exercise were outlined as follows: carvacrol possessed antioxidant properties, lowered the blood glucose levels, and promoted the insulin secretion. Moreover, continuous exercise facilitated the activation of antioxidant enzymes (4,17,18,24,25).

### Conclusion

It was concluded that diabetes negatively influenced the testes and sperm quality by inducing oxidative stress. However, administering carvacrol and performing treadmill exercise were found highly effective in activating the antioxidant system, thereby reducing the oxidative stress caused by diabetes. It was recommended that further research should be carried out in order to confirm our study results.

### Authors' Contribution

**Conceptualization:** Ramesh Bradaran Bagheri.

**Data curation:** Ramesh Bradaran Bagheri.

**Formal analysis:** Ramesh Bradaran Bagheri, Jamal Shadman, and Amir Afshin Khaki.

**Funding acquisition:** Ramesh Bradaran Bagheri.

**Investigation:** Ramesh Bradaran Bagheri, Jamal Shadman, and Amir Afshin Khaki.

**Methodology:** Ramesh Bradaran Bagheri, Jamal Shadman, and Amir Afshin Khaki.

**Project administration:** Ramesh Bradaran Bagheri, Jamal Shadman, and Amir Afshin Khaki.

**Resources:** Ramesh Bradaran Bagheri, Jamal Shadman, and Amir Afshin Khaki.

**Software:** Ramesh Bradaran Bagheri, Jamal Shadman, and Amir Afshin Khaki.

**Supervision:** Ramesh Bradaran Bagheri, Jamal Shadman, and Amir Afshin Khaki.

**Validation:** Ramesh Bradaran Bagheri, Jamal Shadman, and Amir Afshin Khaki.

**Visualization:** Ramesh Bradaran Bagheri, Jamal Shadman, and Amir Afshin Khaki.

**Writing—original draft:** Ramesh Bradaran Bagheri, Jamal Shadman, and Amir Afshin Khaki.

**Writing—review & editing:** Ramesh Bradaran Bagheri, Jamal Shadman, and Amir Afshin Khaki.

### Conflict of Interests

Authors have no conflict of interest.

### Ethical Issues

Ethical approval for all experimental procedures was obtained from the Ethical Committee of Tabriz University of Medical Sciences (IR.TBZMED.VCR.REC.1398.347).

### Financial Support

This research was founded by the authors.

### References

1. Abtahi-Evari SH, Shokoohi M, Abbasi A, Rajabzade A, Shoorei H, Kalarestaghi H. Protective effect of *Galega officinalis* extract on streptozotocin-induced kidney damage and biochemical factor in diabetic rats. *Crescent J Med Biol Sci.* 2017;4(3):108-114.
2. Shokoohi M, Gholami Farashah MS, Khaki A, Khaki AA, Ouladsahebmadarek E, Aref Nezhad R. Protective effect of *Fumaria parviflora* extract on oxidative stress and testis tissue damage in diabetic rats. *Crescent J Med Biol Sci.* 2019;6(3):355-360.
3. Almalki DA, Alghamdi SA, Al-Attar AM. Comparative study on the influence of some medicinal plants on diabetes induced by streptozotocin in male rats. *Biomed Res Int.* 2019;2019:3596287. doi:10.1155/2019/3596287
4. Shoorei H, Khaki A, Shokoohi M, et al. Evaluation of carvacrol on pituitary and sexual hormones and their receptors in the testicle of male diabetic rats. *Hum Exp Toxicol.* 2020;39(8):1019-1030. doi:10.1177/0960327120909525
5. Shoorei H, Khaki A, Khaki AA, Alihemmati AA, Moghimian M, Shokoohi M. The ameliorative effect of carvacrol on oxidative stress and germ cell apoptosis in testicular tissue of adult diabetic rats. *Biomed Pharmacother.* 2019;111:568-578. doi:10.1016/j.biopha.2018.12.054
6. Mohammadi M, Zare Z. Effects of treadmill exercise on cognitive functions and anxiety-related behaviors in ovariectomized diabetic rats. *Physiol Behav.* 2020;224:113021. doi:10.1016/j.physbeh.2020.113021
7. Zhou Z, Wang M, Huang C, et al. Treadmill exercise training alleviates diabetes-induced depressive-like behavior and cognitive impairment by improving hippocampal CA1 neurons injury in db/db mice. *Brain Res Bull.* 2022;190:84-96. doi:10.1016/j.brainresbull.2022.09.018
8. Hamidi H, Tofighi A, Toluei Azar J, Khaki AA, Razi M. Effect of crocin and treadmill exercise on spermatogenesis and testis structure in streptozotocin-induced diabetic rats: an experimental study. *Crescent J Med Biol Sci.* 2023;10(2):98-104.
9. de Lacerda Brito AC, Martins WA, da Silva Queiroz PC, et al. Standardization of a treadmill exercise intensity protocol in rats with diabetes mellitus. *J Exerc Physiol Online.* 2019;22(2):5-16.
10. Ameli M, Moghimian M, Saeb F, et al. The effect of clomiphene citrate and human chorionic gonadotropin on the expression of CatSper1, CatSper2, LHCGR, and SF1 genes, as well as the structural changes in testicular tissue of adult rats. *Mol Reprod Dev.* 2019;86(6):738-748. doi:10.1002/mrd.23151
11. Lu K, Wang L, Wang C, Yang Y, Hu D, Ding R. Effects of high-intensity interval versus continuous moderate-intensity aerobic exercise on apoptosis, oxidative stress and metabolism of the infarcted myocardium in a rat model. *Mol Med Rep.* 2015;12(2):2374-2382. doi:10.3892/mmr.2015.3669
12. Hajighasem A, Farzanegi P, Mazaheri Z. Effects of combined therapy with resveratrol, continuous and interval exercises on apoptosis, oxidative stress, and inflammatory biomarkers in the liver of old rats with non-alcoholic fatty liver disease. *Arch Physiol Biochem.* 2019;125(2):142-149. doi:10.1080/13813455.2018.141872
13. Altinoz E, Oner Z, Elbe H, Cigremis Y, Turkoz Y. Protective effects of saffron (its active constituent, crocin) on nephropathy in streptozotocin-induced diabetic rats. *Hum Exp Toxicol.* 2015;34(2):127-134. doi:10.1177/0960327114538989
14. Samarghandian S, Azimi-Nezhad M, Farkhondeh T. Crocin attenuate tumor necrosis factor-alpha (TNF- $\alpha$ ) and interleukin-6 (IL-6) in streptozotocin-induced diabetic rat aorta. *Cytokine.* 2016;88:20-28. doi:10.1016/j.cyto.2016.08.002
15. Shokri F, Shokoohi M, Niazkhar HR, Roudi Rasht Abadi A, Kalarestaghi H, Ahin M. Investigation the spermatogenesis and testis structure in diabetic rats after treatment with *Galega officinalis* extract. *Crescent J Med Biol Sci.* 2019;6(1):31-36.

16. Shoorei H, Khaki A, Shokoohi M, et al. Evaluation of carvacrol on pituitary and sexual hormones and their receptors in the testicle of male diabetic rats. *Hum Exp Toxicol*. 2020;39(8):1019-1030. doi:10.1177/0960327120909525
17. Yaribeygi H, Mohammadi MT, Sahebkar A. Crocin potentiates antioxidant defense system and improves oxidative damage in liver tissue in diabetic rats. *Biomed Pharmacother*. 2018;98:333-337. doi:10.1016/j.biopha.2017.12.077
18. Wang Y, Wang Q, Yu W, Du H. Crocin attenuates oxidative stress and myocardial infarction injury in rats. *Int Heart J*. 2018;59(2):387-393. doi:10.1536/ihj.17-114
19. Ameli M, Hashemi MS, Moghimian M, Shokoohi M. Protective effect of tadalafil and verapamil on testicular function and oxidative stress after torsion/detorsion in adult male rat. *Andrologia*. 2018;50(8):e13068. doi:10.1111/and.13068
20. Tremellen K. Oxidative stress and male infertility--a clinical perspective. *Hum Reprod Update*. 2008;14(3):243-258. doi:10.1093/humupd/dmn004
21. Perez-Gutierrez RM, Muñoz-Ramirez A, Gomez YG, Ramírez EB. Antihyperglycemic, antihyperlipidemic and antiglycation effects of *Byrsonima crassifolia* fruit and seed in normal and streptozotocin-induced diabetic rats. *Plant Foods Hum Nutr*. 2010;65(4):350-357. doi:10.1007/s11130-010-0181-5
22. Shokoohi M, Khaki A, Shoorei H, Khaki AA, Moghimian M, Abtahi-Eivary SH. Hesperidin attenuated apoptotic-related genes in testicle of a male rat model of varicocele. *Andrology*. 2020;8(1):249-258. doi:10.1111/andr.12681
23. Cicalău GIP, Babes PA, Calniceanu H, et al. Anti-inflammatory and antioxidant properties of carvacrol and magnolol, in periodontal disease and diabetes mellitus. *Molecules*. 2021;26(22):6899. doi:10.3390/molecules26226899
24. da Costa RO, Gadelha-Filho CVJ, da Costa AEM, et al. The treadmill exercise protects against dopaminergic neuron loss and brain oxidative stress in parkinsonian rats. *Oxid Med Cell Longev*. 2017;2017:2138169. doi:10.1155/2017/2138169
25. Lu Y, Dong Y, Tucker D, et al. Treadmill exercise exerts neuroprotection and regulates microglial polarization and oxidative stress in a streptozotocin-induced rat model of sporadic Alzheimer's disease. *J Alzheimers Dis*. 2017;56(4):1469-1484. doi:10.3233/jad-160869

**Copyright** © 2023 The Author(s); This is an open-access article distributed under the terms of the Creative Commons Attribution License (<http://creativecommons.org/licenses/by/4.0>), which permits unrestricted use, distribution, and reproduction in any medium, provided the original work is properly cited.