

Original Article



Effect of watercress seed mucilage (*Lepidium sativum* L.) on the wound healing in New Zealand rabbits

Faezeh Dehestani Ardakani¹, Elham Salehi¹, Majid Morovati-Sharifabad¹, Amin Paidar Ardakani², Mohammad Saeed Heydarnejad³

¹Department of Basic Sciences, Faculty of Veterinary Medicine, Ardakan University, Ardakan, Iran

²Department of Clinical Sciences, Faculty of Veterinary Medicine, Ardakan University, Ardakan, Iran

³Department of Animal Sciences, Faculty of Basic Sciences, Shahrekord University, Shahrekord, Iran

*Corresponding Author: Elham Salehi, Email: esalehi@ardakan.ac.ir

Abstract

Background and aims: Wound healing is one of the most important issues in medical science. Synthetic drugs have long been introduced and used to speed up the healing process of wounds, but most of them have many side effects. The present study was performed to evaluate the healing efficiency of watercress seed mucilage (*Lepidium sativum* L.) on wounds.

Methods: In this study, the animals were randomly divided into five groups. The treatment groups were (1), (2), (3), sham (4), and control (5). The treatment groups were treated with 20%, 10%, and 5% watercress seed mucilage in the Eucerin base, respectively, and the sham was treated with Eucerin, while the control received no treatment. Then, 5 pairs of full-thickness wounds with a diameter of 7 mm were created on both sides of the rabbit's spine. Macroscopic and wound area studies were performed on days 4, 7, and 14 after surgery.

Results: According to the analysis of variance, there was a significant difference between groups 1, 2, 3, sham, and control ($P=0.001$), but no significant difference was observed between group 3, sham group, and control group ($P=0.993$). Based on these findings, at the end of the treatment period, group 1 had the highest healing rate and the lowest wound area (1.12 ± 0.77) compared to group 2 (4.42 ± 0.30) and 3 (7.05 ± 0.35), as well as the sham (8.34 ± 1.10) and control (8.50 ± 1.90) groups. Thus, the treatment method of this group has been more effective in wound healing than that of the other treatment groups.

Conclusion: It seems that watercress seed mucilage can treat wounds due to its important compounds such as flavonoids, phenols, and vitamins A and C.

Keywords: Mucilage, *Lepidium sativum* seed, Wound healing, Surgery

Received: April 30, 2022 Accepted: September 26, 2022 ePublished: April 25, 2023

Introduction

The skin is the first and most important organ of the human body that prevents disease and infection from penetrating into the body. The skin is made up of different tissues, each of which has a specific function, thus it can be considered an organ, and for some reason, it is considered the largest organ in the body (1). Wounds or injuries in medical knowledge are any separation, rupture, and loss of connection and integration of the skin epidermis alone or with the underlying connective tissues for reasons such as trauma, pressure, injury, and heat (2). Regenerative wound healing is a new and rapidly evolving area in biomedical research. Its purpose is to restore the skin to its original function and to repair damaged cells and tissues without scarring (3). The study of effective compounds in wound healing and healing mechanisms in terms of effective mechanisms in damaged tissue has long been the subject of research by researchers. In recent years, medicinal plants have been widely used in the world by doctors and patients. With advances in traditional medicine, Iran has always employed medicinal plants or

plant extracts to treat a variety of diseases such as cuts, burns, and infections (4). *Lepidium sativum* L. is a plant of the *Brassicaceae* family that is mostly cultivated in Iran. Watercress seed mucilage contains D-arabinose and D-xylose, D-galactose and L-rhamnose, and D-glucuronic acid (5). Watercress is rich in important biological compounds, including fatty acids, tocopherol, carotenoids, phytosterols, and campesterol and phenolic compounds. It also has antimicrobial, antihypertensive, antioxidant, antispasmodic, anti-diarrheal, anti-asthmatic, and hypoglycemic effects (6). Vitamin C plays an important role in the synthesis of collagen, which makes up about 30-40% of the body's total protein (7). Vitamin C also acts as a cofactor, regulating collagen genes and increasing collagen formation in the wound area (8). Preclinical studies have shown that vitamin C has the ability to accelerate the healing of bone fractures, increase collagen production, and reduce oxidative stress (9). The purpose of this study was to investigate whether watercress seed mucilage is effective in healing surgical wounds in rabbits.

Materials and Methods

Animal preparation and grouping

Overall, 6 white male rabbits weighing about 1000 g were evaluated in this study. The studied animals were prepared from the animal care center and kept in separate cages. Special food and water were freely available to the animals. Standard conditions were provided as a 12-hour cycle of light and dark. In addition, room temperature and humidity were kept at $24 \pm 2^\circ\text{C}$ and 50%.

In the current study, the animals were randomly assigned to five groups. In each rabbit, 5 pairs of full-thickness wounds were created on both sides of the spine, and each pair of wounds represented one of the groups (groups 1, 2, and 3, as well as the sham and control groups). Each group had 12 wounds, thus there were 60 wounds in total.

- Group 1: The animals of this group were treated with watercress seed mucilage in the Eucerin base with a concentration of 20%.
- Group 2: In this group, the rabbits were treated with watercress seed mucilage at the base of Eucerin with a concentration of 10%.
- Group 3: The animals in this group were treated with watercress seed mucilage in the Eucerin base with a concentration of 5%.
- Sham group: In this group, the rabbits were treated with Eucerin as a base.
- Control group: The animals received no medicine.

In each rabbit, the first, second, third, fourth, and fifth wounds were considered as groups 1, 2, and 3, as well as sham and control groups, respectively.

Preparation of watercress seed

Watercress seeds were obtained from a reputable store and identified by the botanist of the University of Tehran with the code herbarium 17566.

Preparation of watercress seed mucilage

To clean watercress seeds, 300 g of these seeds were completely immersed in distilled water and stirred for 10 minutes at 40°C . The seeds were then mixed with distilled water in a ratio of 1-30 with a pH rate of 10 and stirred for 2 hours at 35°C . All the mucilage obtained from the watercress seeds was centrifuged at 6000 rpm for 5 minutes

at environmental conditions to separate the impurities. The mucilage obtained by the oven was then dried in an oven at 40°C , and the dried mucilage powder was mixed with Eucerin to prepare 20, 10, and 5% ointment.

Preparation of watercress seed mucilage ointment

To prepare 20%, 10%, and 5% ointment of watercress seed mucilage, 6, 3, and 1.5 g of watercress seed mucilage with 12, 13.5, and 14.25 g of glycerin, as well as 12, 13.5, and 14.25 g Eucerin were thoroughly mixed and prepared as an ointment, respectively.

Making a wound

First, the animals entered a coma by intramuscular injection of 2% xylazine (0.2 mg/kg) and 10% ketamine (30 mg/kg). After the induction of anesthesia, the animal was placed on its thorax in a supine position, and the hairs on the back were completely shaved on both sides of the spine and disinfected with betadine scrub. In this study, 5 pairs of full-thickness wounds (7 mm in diameter) were created by a biopsy punch on the side of each spine of each rabbit (Figure 1).

Macroscopic examination

The left wounds were used for macroscopic examinations. Wounds were photographed on days 4, 7, and 14 using a digital camera with a calibrated ruler next to the wound as a reference for wound size. Digital calipers were also employed to accurately measure wound diameters. The images were then transferred to a computer, and the wound area in each wound was calculated in square millimeters by the J image software program.

Microscopic examinations

The wounds on the right side were utilized for microscopic examinations. On days 7 and 14 of the treatment period, after anesthesia and wound creation, a tissue sample including the wound area and adjacent healthy tissue was removed by scalpel incision. Tissue passage, molding, and cutting steps were performed, and the slides prepared for histological examinations were hematoxylin-eosin stained. They were also stained with Mason Trichrome-specific staining to measure collagen synthesis.

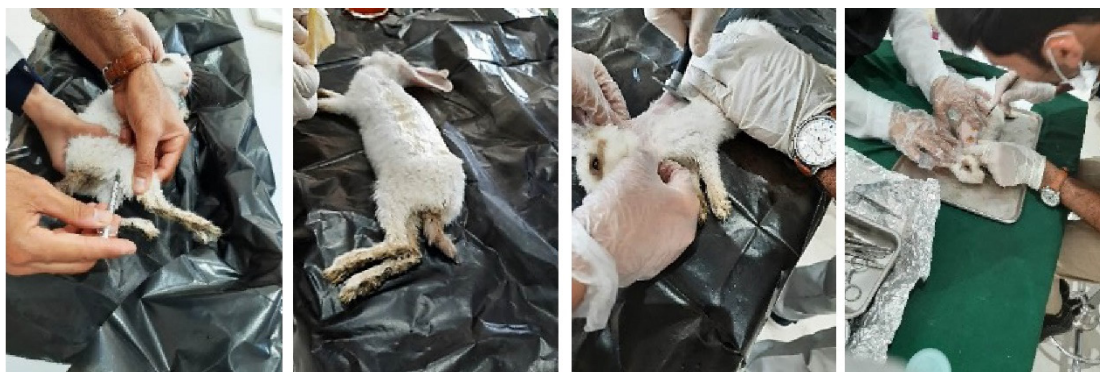

Figure 1. Pre-operative Preparation

Statistical analysis

Data were analyzed by SPSS software (version 23) using a one-way analysis of variance and Tukey's test. In addition, paired sample *t* test was used to compare the wound area in the groups before and after treatment, and *P* values < 0.05 were considered statistically significant.

Results

The information obtained from macroscopic studies is presented as the wound area in all five treatment groups (Table 1). Further, the pictures of wounds on days 4, 7, and 14 are shown in Figure 2.

In the control group, the tissue is hyperemic and the granulation tissue is visible on the seventh day. The layers of the epidermis are forming but not fully formed. A stratum corneum is forming in some areas. No traces of hair follicles and sebaceous glands are found, and collagen fibers have an irregular arrangement.

In the same group, the epidermal tissue is almost formed on the fourteenth day, but the number of layers of the epidermis is still small in some places. The stratum corneum is also forming. Collagen fibers are being regulated, but their natural makeup is not observable. Fibrocytes and fibroblasts, as well as tissue hyperemia and inflammatory cells, are detected in this tissue (Figure 3).

On the seventh day, the tissue is hyperemic and the

granulation tissue is visible in the sham group. White blood cell infiltration is also detectable. The layers of the epidermal tissue are forming but not fully formed. In some areas, a stratum corneum is forming. However, no traces of hair follicles and sebaceous glands are observed, and collagen fibers are found with an irregular arrangement.

In the same group, the epidermis layer is almost completely formed on day 14. The stratum corneum of the epidermis is formed as well. Sebaceous glands and hair follicles penetrated the epidermis and were formed, and collagen fibers are nearly regular, and in some places, their density is low. Inflammatory cells and the granulation tissue, as well as fibrocyte cells, are also visible. Moreover, blood vessels are observed, but the process of angiogenesis represents a reduction (Figure 4).

On day 7, epidermis formation began in treatment group 3, but the number of layers was incomplete. The granulation tissue is visible. The number of blood vessels increases, and the frequency of angiogenesis is detectable. However, there are no traces of sebaceous glands and hair follicles. Fibroblasts are highly visible. Collagen fibers are found with low density and irregularity.

In the same group, the covering tissue is forming, the layers are repairing from under the epidermis, and the stratum corneum is also formed in some parts on day 14. Angiogenesis and an increase in the number of blood

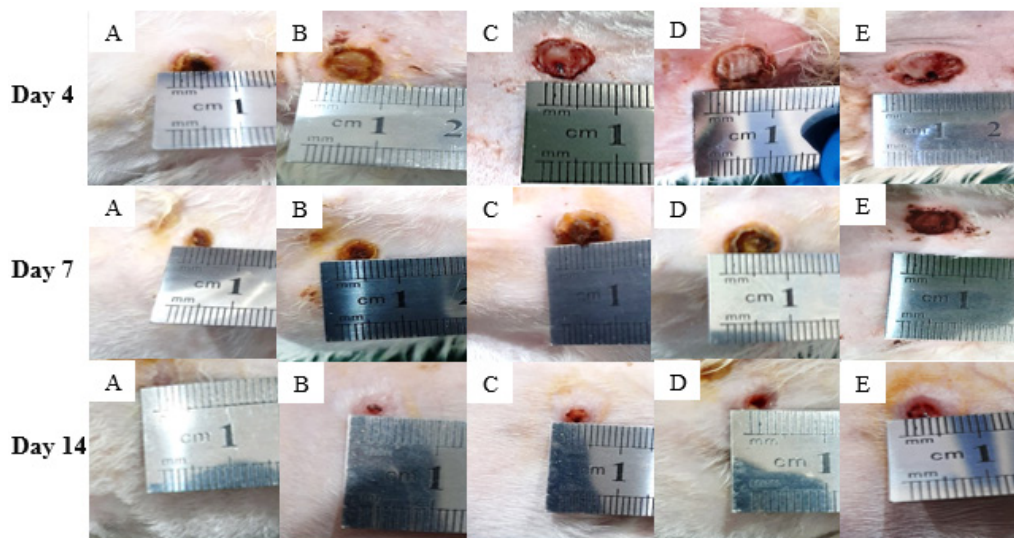


Figure 2. Results of macroscopic examinations: Group 1 (A), group 2 (B), group 3 (C), Sham group (D), and control group (E) on days 4, 7, and 14

Table 1. Mean and standard deviation of the wound area (mm²) and comparison of between groups and within groups in treatment groups 1, 2, 3, sham, and control on days 4, 7, and 14

Groups	Days			Within groups
	Day 4	Day 7	Day 14	<i>P</i> value
Control group Wound area (mm ²)	56.68 ± 2.6 ^c	40.21 ± 1.49 ^c	8.50 ± 1.90 ^c	0.037
Sham group wound area (mm ²)	55.33 ± 3.49 ^c	39.35 ± 1.48 ^c	8.34 ± 1.10 ^c	0.009
Group 3 Wound area (mm ²)	54.51 ± 0.75 ^c	37.40 ± 2.19 ^c	7.05 ± 0.35 ^c	0.006
Group 2 Wound area (mm ²)	37.11 ± 2.45 ^b	27.75 ± 1.38 ^b	4.42 ± 0.30 ^b	0.012
Group 1 Wound area (mm ²)	21.16 ± 0.59 ^a	14.72 ± 2.0 ^a	1.12 ± 0.77 ^a	0.001
Between groups	<i>P</i> value	< 0.001	< 0.001	< 0.001

Note. Dissimilar letters show a significant difference (*P* < 0.05).

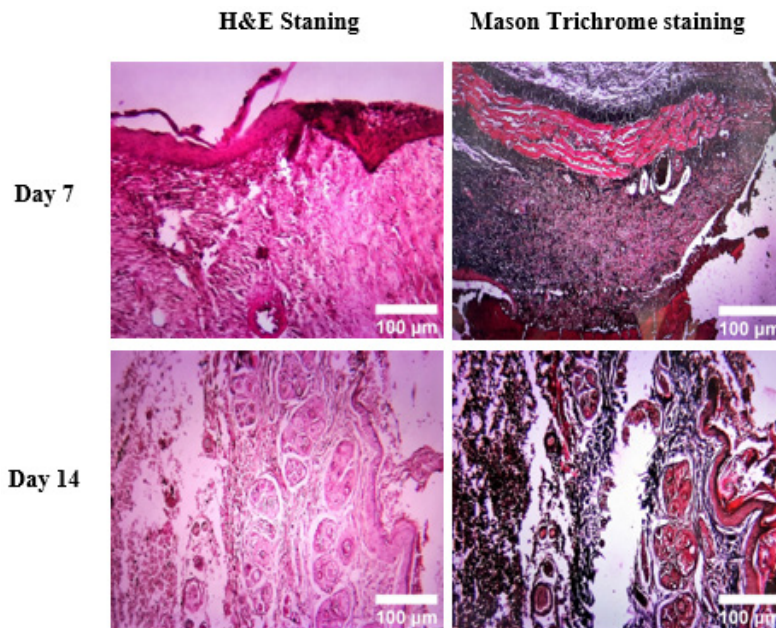


Figure 3. Microscopic graphs of wounds on days 7 and 14 of control group (H&E and Mason trichrome staining, 10X)

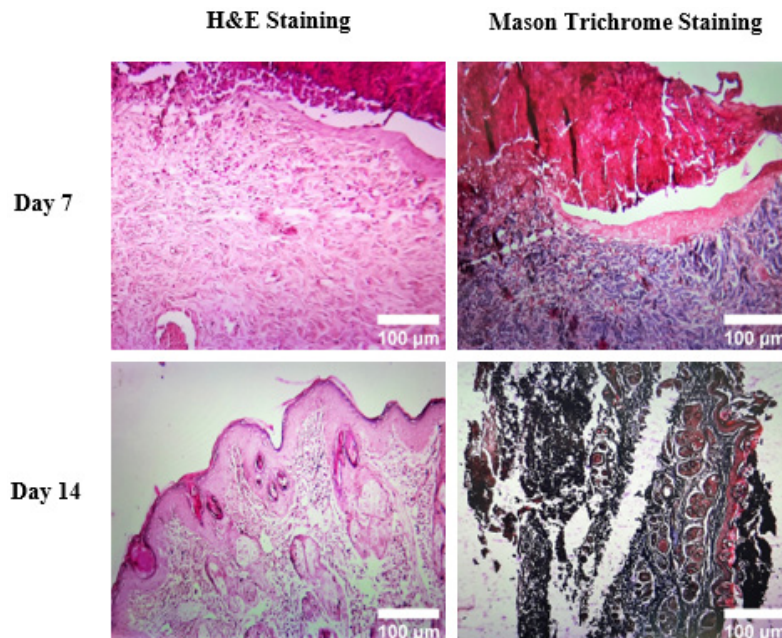


Figure 4. Microscopic graphs of wounds on days 7 and 14 of Sham group (H&E and Mason trichrome staining, 10X)

vessels under the epidermis are observable. There are no inflammatory cells in this tissue. The granulation tissue is visible, and hair follicles are forming. Collagen fibers are not yet fully regulated. Fibrocytes and fibroblasts can be detected, and there is an increase in the number of fibroblasts. An increase in blood vessels is also evident (Figure 5).

On the seventh day, in group 2, the epidermal tissue was almost formed, but the number of layers is not yet complete. Hyperemia and angiogenesis are visible in the tissue. The penetration of white blood cells and the presence of fibroblast cells in the tissue are observable. Collagen fibers are found in low density and are irregular in the dermis tissue. No traces of hair follicles and sebaceous glands are detectable.

In the same group, a covering tissue is formed on day 14, and stratum corneum is formed as well. Hair follicles and sebaceous glands are also forming. However, there are no traces of the granulation tissue. Angiogenesis and the formation of blood vessels are visible under the epidermis. Collagen fibers are not yet fully regulated and are less abundant than the healthy tissue visible under the epidermis. The purpose of this slide is to illustrate fibroblast cells and collagen fibers that are still irregular (Figure 6).

On day 7, the epidermal tissue or epidermis is formed in treatment group 1, but the number of layers is not yet complete. The stratum corneum is formed in some parts, while it is not detected in others. Hair follicles and sebaceous glands can be found, and fibroblasts are

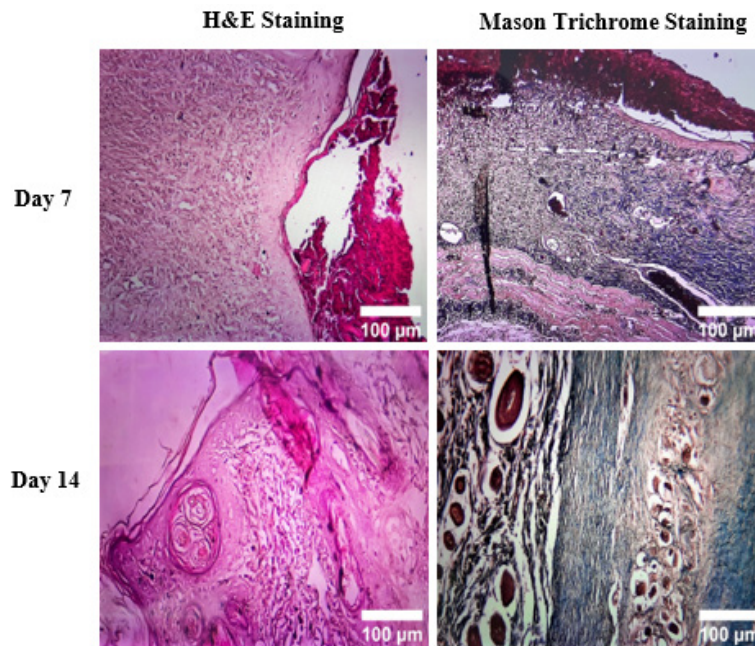


Figure 5. Microscopic graphs of wounds on days 7 and 14 of group 3 (H&E and Mason trichrome staining, 10X)

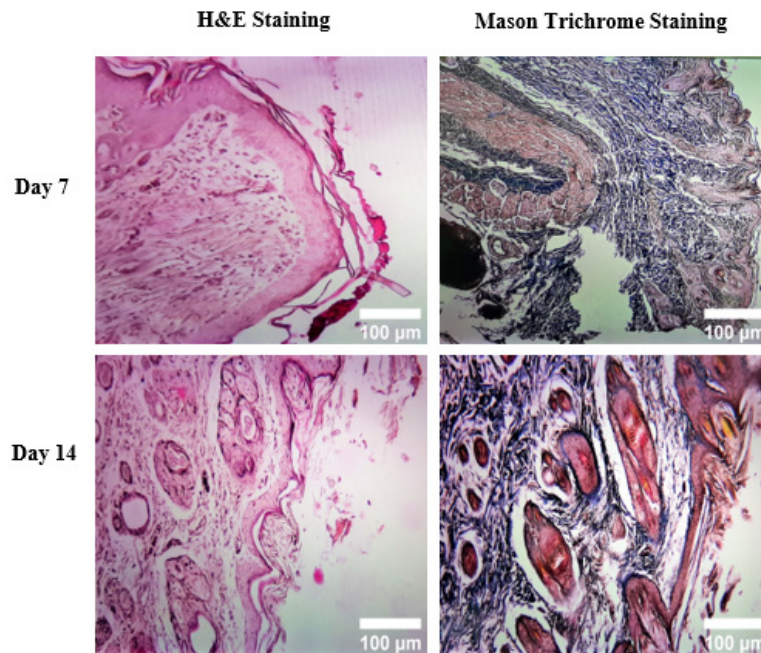


Figure 6. Microscopic graphs of wounds on days 7 and 14 of group 2 (H&E and Mason trichrome staining, 10X)

abundant. The arrangement of collagen fibers is not complete.

On the fourteenth day, the epithelial tissue is formed in the same group, and its layers demonstrate an increase. Additionally, a stratum corneum is formed, and the number of hair follicles is increasing. Conversely, the number of blood vessels has decreased as the healing process is almost complete. There are also no traces of the granulation tissue. Fibroblast cells are present, and collagen fibers have a regular arrangement (Figure 7).

Statistical Analysis

Table 1 presents the size and standard deviation of the wound area (mm^2) and comparison between and within

groups on days 4, 7, and 14. The P value indicates the level of significance, and the significance level is checked to find if the difference between groups is significant. On days 4, 7, and 14, the significance level is less than 0.001, 0.001, and 0.001, respectively. Therefore, the difference between the groups on days 4, 7, and 14 is significant (Table 1).

On the fourth day after creating a wound

By examining changes in the wound area in the animals of the control group and other groups, it was found that the average area of the wound in groups 1 and 2 had a significant decrease ($P=0.013$) compared with the control group. This decrease in the wound area in group 3 ($P=0.064$) and the sham group ($P=0.418$) was

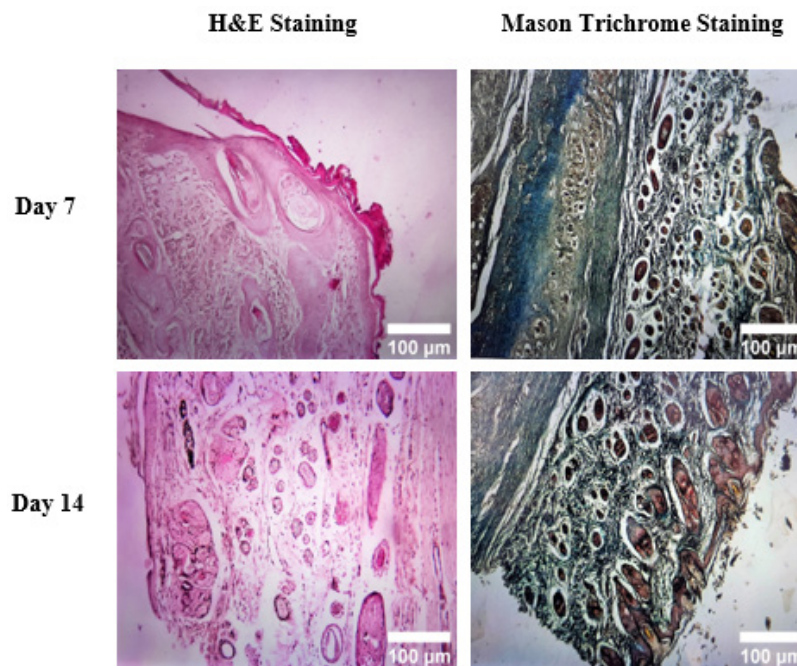


Figure 7. Microscopic graphs of wounds on days 7 and 14 of group 1 (H&E and Mason Trichrome Staining, 10X)

not significant in comparison with the control group. It should be noted that on day 4, the average wound area in group 1, compared to group 2, had a significant difference ($P=0.008$), thus group 1 had a greater effect on wound healing and covered less wound surface. Moreover, group 3 numerically had a greater effect on wound healing than the sham and control groups and occupied a smaller wound area, but there was no significant difference ($P=0.064$) between them.

As a result, the average wound area in the control group on day 4 (56.68 ± 2.67) had the highest value compared to other groups. On the other hand, the lowest wound area belonged to group 1 (21.16 ± 0.59).

On the 7th day after creating a wound

The investigation of changes in the wound area in the animals of the control group and other groups represented that the average area of the wound in groups 1 and 2 had a significant reduction ($P=0.005$) in comparison with the control group. This decrease in the wound area in group 3 ($P=0.069$) and the sham group ($P=0.911$) was not significant compared to the control group. It should be noted that on day 7, the average wound area in group 1 had a significant difference ($P=0.017$) compared to groups 2 and 3, thus group 1 had a higher effect on wound healing and could cover less wound surface. Additionally, group 3 numerically had a greater impact on wound healing compared to the sham and control groups and occupied a smaller wound area, but there was no significant difference ($P=0.069$) between them.

Accordingly, the average wound area on the seventh day in the control group (40.21 ± 1.49) had the highest value in comparison to the other groups. However, the lowest wound area was related to group 1 (14.72 ± 2.01).

On day 14th after creating a wound

Based on the results related to examining alterations in the wound area in the animals of the control group and other groups, the average area of the wound in groups 1 and 2 had a significant decline ($P=0.023$) in comparison with the control group. This decrease in the wound area in group 3 ($P=0.067$) and the sham group ($P=0.998$) was not significant compared to the control group. It is noteworthy that on day 14, the average wound area in group 1, compared to groups 2 and 3, had a significant difference ($P=0.019$), thus group 1 had a higher impact on wound healing and covered less wound surface. Furthermore, group 3 numerically had a greater effect on wound healing than the sham and control groups and occupied a smaller wound area; nonetheless, there was no significant difference ($P=0.067$) between them.

Hence, on day 14, the average wound area had the highest value in the control group (8.50 ± 1.90) compared to the other groups. Conversely, the lowest wound area belonged to group 1 (1.12 ± 0.77 , Table 1).

The wound surface of treatment groups 1, 2, 3, sham, and control were drawn on days 0 (beginning of wound formation), 4, 7, and 14. The amount of wound surface before and after treatment was obtained using the paired-sample T test. The wound surface size in all groups was 70 on day 0 or before treatment. $P < 0.05$ is considered statistically significant.

The average wound area in group 1 in the days after treatment was 12.33, which is significantly different from the average wound area before treatment ($P=0.010$).

Likewise, in group 2, the average wound area was 23.09 on the days after treatment, which significantly differs from the average wound area before treatment ($P=0.040$).

Based on the data, the average wound area in group 3 was 32.98 on the days after treatment, which was not

significantly different from the average wound area before treatment ($P=0.117$).

Likewise, the wound area in the sham group was 34.34 on days after treatment, which was not significantly different from the average wound area before treatment ($P=0.123$).

In days after treatment, the average wound area in the control group was 35.13, which did not significantly differ from the average wound area before treatment ($P=0.132$).

According to the above results, the average area of the wound in group 1 decreased significantly compared to other groups on all days, indicating the effectiveness of this treatment (Figure 8).

Discussion

This study investigated the effect of cress seed mucilage on the skin wound healing process in rabbits. According to variance analysis, there was a significant difference between groups 1, 2, 3, sham, and control ($P=0.001$), but no significant difference was observed between group 3, sham group, and control group ($P=0.993$). Based on these findings, at the end of the treatment period, group 1 had the highest healing rate and the lowest wound area (1.12 ± 0.77) compared to group 2 (4.42 ± 0.30), group 3 (0.35 ± 7.05), and the sham group (1.10 ± 8.34) and the control group (1.90 ± 8.50), thus the treatment method of this group was more effective in wound healing than the other treatment groups. In addition, in the microscopic examination conducted in this study, wound healing was evaluated histologically during days 7 and 14, and it was found that the speed and process of wound healing in group 1, which was treated with 20% watercress mucilage ointment was more than the other groups.

Discussion and care are important in health and treatment issues, and mankind has always been looking for the best way to treat and care for wounds. The goal of methods considered in wound healing is to use medicinal compounds that create a favorable environment for the healing of the damaged tissue and shorten the healing period while also causing the least side effects. For this reason, drugs based on natural compounds have received much attention in wound healing (10). Several studies have shown the positive effects of herbal medicines in

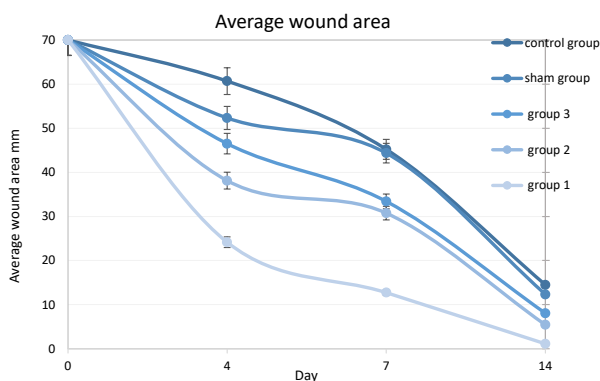


Figure 8. Comparison of the average wound surface in treatment groups 1, 2, 3, sham, and control on days 0 (beginning of wound formation), 4, 7, and 14

wound healing, some of which are explained below. Wound healing is a highly complex and active mechanism that consists of various regulatory cells and molecules that combine to complete the wound epithelialization process (11). As the skin layer is damaged, cellular and molecular materials in the skin layers improve in the steps set to initiate the healing mechanism. Although skin wound healing is a systematic process, its stages represent an overlap. Therefore, wound healing is known as one of the most complex biological processes in the human body (12). Howarth et al compared the oral and topical effects of watercress and the standard drug mupirocin on the healing of diabetic ulcers in mice. Experimental diabetic rats showed a decrease in collagen, but the watercress treatments group significantly increased hydroxyproline levels, leading to more collagen deposition, granulation tissue formation on the wound, improvement of blood parameters, inhibition of lipid peroxidation, and thus wound healing (13). In the present study, watercress seed mucilage ointment increased the rate of epithelial cell proliferation, collagen fiber synthesis, and seed tissue formation while reducing inflammation in the treated wounds and had a positive effect on wound healing. In a study, Tamri et al investigated the effect of Quince seed mucilage in the form of ointments formulated in Eucerin base with 5%, 10%, and 20% on wounds. The findings demonstrated that on most days, there was a statistically significant difference in wound contraction between the treatment groups with 10 and 20% Quince seed mucilage ointment and the control group ($P<0.05$). The best results were related to the rabbits that were treated with 20% Quince seed mucilage ointment (14), which is consistent with the results of the present study. In a research conducted by Azhdari-Zarmehri et al on the effects of the hydroalcoholic extract of *Scrophularia striata* on the healing of burn wounds in rats, it was observed that the granule tissue and blood family of the treated group significantly differed ($P<0.05$) from the control group. The findings revealed that the hydroalcoholic extract of this plant accelerates the healing process (15), which corroborates the results of this study. In another study, Yadav et al examined the ability of the ethanolic extract of watercress seeds to heal bone fractures by femoral osteotomy in rats. Based on the results, the broken bones of the animals in the experimental group were completely connected, while the ones in the control group were not connected. This finding represented that the ethanolic extract of watercress seeds plays a major role in accelerating callus formation in fractures and has significant fracture repair ability (16). It was also found that groups treated with watercress seed mucilage ointment in a dose-dependent manner were able to accelerate the wound healing process by increasing the granulation tissue and collagen deposition at the wound site. According to these results, watercress seed mucilage ointment can improve the wound healing process by increasing collagen production and accelerating the

regeneration of the epithelial tissue. Researchers have recently reported that mucilage (mostly marshmallow extract) is a carbohydrate compound that increases epithelialization on the surface of damaged tissue and thus accelerates wound healing (17). The results of the present study also indicated that group 1 regenerated epithelial cells by creating a state of contraction at the wound site. Salem et al studied the effect of the watercress extract on alveolar bone repair after periodontitis induction in rats and concluded that watercress systematically accelerates alveolar bone healing in mice with induced periodontitis and increases osteoblast activity and new bone formation. The positive effect of watercress on bone-forming cells is due to the antioxidant properties of phenolic compounds in watercress seeds. Therefore, it can be used as a symptomatic treatment along with the usual treatment of periodontitis (18). The use of medicinal plants in healing wounds has found a special place in subsequent studies. According to the findings of this research, it seems that watercress mucilage can heal wounds due to the presence of important substances such as flavonoids, phenolic compounds, tannins, and vitamins A and C, but among the groups, the treatment method of group 1 was more successful.

Conclusion

Our findings in the wound healing process revealed that in the group treated with 20% watercress seed mucilage ointment, the wound healing process significantly increased in rabbits, and the days required for complete healing reduced compared to the ointment groups of 10% and 5% watercress seed mucilage and Eucerin and without treatment. Therefore, it is suggested that the effect of watercress seed mucilage be compared with another medicinal compound in future research.

Acknowledgments

This article was the result of the dissertation of Ms. Faezeh Dehestani Ardakani (No. 2799294) with the date of Defense 2021.12.20 for obtaining a master's degree in cell-developmental biology from Ardakani University. The authors would like to thank Mr. Mohsen Rashidi for providing histological facilities.

Authors' Contribution

Conceptualization: Faezeh Dehestani Ardakani, Elham Salehi, Majid Morovati-Sharifabad, Amin Paidar Ardakani, Mohammad Saeed Heydarnejad.

Data curation: Faezeh Dehestani Ardakani, Elham Salehi, Majid Morovati-Sharifabad, Amin Paidar Ardakani, Mohammad Saeed Heydarnejad.

Formal analysis: Faezeh Dehestani Ardakani, Elham Salehi, Majid Morovati-Sharifabad.

Funding acquisition: Faezeh Dehestani Ardakani, Elham Salehi.

Investigation: Faezeh Dehestani Ardakani, Elham Salehi, Majid Morovati-Sharifabad.

Methodology: Faezeh Dehestani Ardakani, Elham Salehi, Majid Morovati-Sharifabad.

Project administration: Faezeh Dehestani Ardakani, Elham Salehi, Majid Morovati-Sharifabad, Amin Paidar Ardakani, Mohammad Saeed Heydarnejad.

Resources: Faezeh Dehestani Ardakani.

Supervision: Elham Salehi, Majid Morovati-Sharifabad.

Validation: Faezeh Dehestani Ardakani, Elham Salehi, Majid Morovati-Sharifabad, Amin Paidar Ardakani, Mohammad Saeed Heydarnejad.

Visualization: Faezeh Dehestani Ardakani, Elham Salehi, Majid Morovati-Sharifabad.

Writing—original draft: Faezeh Dehestani Ardakani, Elham Salehi.

Writing—review & editing: Elham Salehi, Majid Morovati-Sharifabad.

Competing Interests

The authors declared that there is no conflict of interests.

Ethical Approval

This study was Approved by the Ethics Committee of Ardakan University (IR.YAZD.REC.1399.032).

Funding

None.

References

1. Yazdanbakhsh MF, Rashidi A, Rahimi MK, Khajavi R, Shafaroodi H. The effect of impregnated alpha-cellulose nanofibers with ciprofloxacin hydrochloride on *Staphylococcus aureus* in vitro and healing process of wound in rat. *Regen Eng Transl Med*. 2018;4(4):247-56. doi: 10.1007/s40883-018-0066-y.
2. Ahmed J, Gultekinoglu M, Edirisinghe M. Bacterial cellulose micro-nano fibres for wound healing applications. *Biotechnol Adv*. 2020;41:107549. doi: 10.1016/j.biotechadv.2020.107549.
3. Boyce ST, Lalley AL. Tissue engineering of skin and regenerative medicine for wound care. *Burns Trauma*. 2018;6:4. doi: 10.1186/s41038-017-0103-y.
4. Bagher Z, Ehterami A, Safdel MH, Khastar H, Semiari H, Asefnejad A, et al. Wound healing with alginate/chitosan hydrogel containing hesperidin in rat model. *J Drug Deliv Sci Technol*. 2020;55:101379. doi: 10.1016/j.jddst.2019.101379.
5. Gharanjig H, Gharanjig K, Farzi G, Hosseinneshad M, Jafari SM. Novel complex coacervates based on Zedo gum, cress seed gum and gelatin for loading of natural anthocyanins. *Int J Biol Macromol*. 2020;164:3349-60. doi: 10.1016/j.ijbiomac.2020.08.218.
6. Abo El-Maati MF, Labib SM, Al-Gaby A, Ramadan MF. Antioxidant and antibacterial properties of different extracts of garden cress (*Lepidium sativum* L.). *Zagazig J Agric Res*. 2016;43(5):1685-97. doi: 10.21608/zjar.2016.98127.
7. Maxfield L, Crane JS. Vitamin C deficiency. In: *StatPearls*. Treasure Island, FL: StatPearls Publishing; 2020.
8. Pullar JM, Carr AC, Vissers MCM. The roles of vitamin C in skin health. *Nutrients*. 2017;9(8):866. doi: 10.3390/nu9080866.
9. DePhillipo NN, Aman ZS, Kennedy MI, Begley JP, Moatshe G, LaPrade RF. Efficacy of vitamin C supplementation on collagen synthesis and oxidative stress after musculoskeletal injuries: a systematic review. *Orthop J Sports Med*. 2018;6(10):2325967118804544. doi: 10.1177/2325967118804544.
10. Kaboli H, Haghight S. Evaluation of Borrigo topical effects on wound healing of cutting wounds in mice. *J Shahid Sadoughi Univ Med Sci*. 2017;25(4):311-21. [Persian].
11. Han G, Ceilley R. Chronic wound healing: a review of current management and treatments. *Adv Ther*. 2017;34(3):599-610. doi: 10.1007/s12325-017-0478-y.
12. Rodrigues M, Kosaric N, Bonham CA, Gurtner GC. Wound healing: a cellular perspective. *Physiol Rev*. 2019;99(1):665-

706. doi: [10.1152/physrev.00067.2017](https://doi.org/10.1152/physrev.00067.2017).
13. Howarth FC, Jacobson M, Shafiullah M, Adeghate E. Long-term effects of streptozotocin-induced diabetes on the electrocardiogram, physical activity and body temperature in rats. *Exp Physiol*. 2005;90(6):827-35. doi: [10.1113/expphysiol.2005.031252](https://doi.org/10.1113/expphysiol.2005.031252).
 14. Tamri P, Hemmati A, Boroujerdnia MG. Wound healing properties of quince seed mucilage: in vivo evaluation in rabbit full-thickness wound model. *Int J Surg*. 2014;12(8):843-7. doi: [10.1016/j.ijvsu.2014.06.016](https://doi.org/10.1016/j.ijvsu.2014.06.016).
 15. Azhdari-Zarmehri H, Nazemi S, Ghasemi E, Musavi Z, Tahmasebi Z, Farsad F, et al. Assessment of effect of hydro-alcoholic extract of *Scrophularia striata* on burn healing in rat. *J Babol Univ Med Sci*. 2014;16(5):42-8. doi: [10.18869/acadpub.jbums.16.5.42](https://doi.org/10.18869/acadpub.jbums.16.5.42). [Persian].
 16. Yadav YC, Jain A, Srivastava DN, Jain A. Fracture healing activity of ethanolic extract of *Lepidium sativum* L. seeds in internally fixed rats' femoral osteotomy model. *Int J Pharm Pharm Sci*. 2011;3(2):193-7.
 17. Hemmati AA, Houshmand G, Ghorbanzadeh B, Nemati M, Behmanesh MA. Topical vitamin K1 promotes repair of full thickness wound in rat. *Indian J Pharmacol*. 2014;46(4):409-12. doi: [10.4103/0253-7613.135953](https://doi.org/10.4103/0253-7613.135953).
 18. Salem EM, Karam SS, Kawana KY, Khalil NM, Lotfy ME. Effect of garden cress on alveolar bone healing in rats with ligature induced periodontitis (histological& ultrastructural study). *Alex Dent J*. 2020;45(2):79-83. doi: [10.21608/adjalexu.2020.88442](https://doi.org/10.21608/adjalexu.2020.88442).