

The effects of alone and combined treatment of *Tarantula cubensis* alcoholic extract and Methenolone Enanthate on two long bones of young Rats

Los efectos del tratamiento solo y combinado de extracto alcohólico de *Tarantula cubensis* y enantato de metenolona en dos huesos largos de ratas jóvenes

Mustafa Sedat Arslan* , Kamil Besoluk 

Selcuk University, Faculty of Veterinary Medicine, Department of Anatomy, Konya, Turkey.

*Corresponding author: msedatarслан@hotmail.com

ABSTRACT

The aim of this study was to determine the effects of alone and combined treatment of *Tarantula cubensis* alcoholic extract (TCAE) and Methenolone Enanthate (ME) on morphometric parameters of humerus and femur in young rats. In this study, 36 five-week-old Wistar Albino rats were used. The animals were divided into 4 groups; Control group (n:6, normal saline solution, 0.2 mL·rat⁻¹, subcutaneously -SC-), TCAE group (*Tarantula cubensis* alcoholic extract, 0.2 mL·rat⁻¹, SC), ME group (Methenolone Enanthate), 10 mg·kg⁻¹, intramuscularly -IM-) and TCAE + ME group (*Tarantula cubensis* alcoholic extract, 0.2 mL·rat⁻¹, SC + Methenolone Enanthate, 10 mg·kg⁻¹, IM). Drug treatments were done once a week for 7 weeks. At the end of the experiment, all the animals were euthanized and their humerus and femur bones were resected and their morphometric parameters were determined. No statistical differences were determined ($P>0.05$) between the groups in terms of the anatomical reference points (length, corpus thickness, cavum medullare diameter, and cortex thickness) of humerus and femur bones. In conclusion, it was found that alone and combined treatments of *Tarantula cubensis* alcoholic extract and ME (at normal dose) had no effects on morphometric parameters of humerus and femur bones in rats in the growing period. However, these effects may not be observed at high-dose and long-term treatments in rats.

Key words: Alcoholic extract, femur, humerus, methenolone enanthate, rat, *Tarantula cubensis*

RESUMEN

El objetivo de este estudio fue determinar los efectos del tratamiento solo y combinado de extracto alcohólico de *Tarantula cubensis* y enantato de metenolona (EM) sobre parámetros morfométricos de húmero y fémur en ratas jóvenes. En este estudio, se utilizaron 36 ratas Wistar Albino de cinco semanas de edad. Los animales se dividieron en 4 grupos; Grupo control (n:6, solución salina normal, 0,2 mL·rata⁻¹, por vía subcutánea -SC-), grupo TCAE (extracto alcohólico de *Tarantula cubensis*, 0,2 mL·rata⁻¹, por vía SC), grupo ME (enantato de metenolona, 10 mg·kg⁻¹, por vía intramuscular -IM-) y TCAE + grupo ME (extracto alcohólico de *Tarantula cubensis*, 0,2 mL·rata⁻¹, por vía SC + enantato de metenolona, 10 mg·kg⁻¹, por vía IM). Los tratamientos farmacológicos se realizaron una vez por semana durante 7 semanas. Al final del experimento, todos los animales fueron sacrificados y sus huesos húmero y fémur fueron resecados y se determinaron sus parámetros morfométricos. No se determinaron diferencias estadísticas ($P>0,05$) entre los grupos en cuanto a los puntos de referencia anatómicos (longitud, grosor del cuerpo, diámetro del cavum medular y grosor de la corteza) de los huesos húmero y fémur. En conclusión, se encontró que los tratamientos solos y combinados de extracto alcohólico de *Tarantula cubensis* y EM (a dosis normal) no tuvieron efectos sobre los parámetros morfométricos de los huesos del húmero y fémur en ratas en el período de crecimiento. Sin embargo, es posible que estos efectos no se observen con dosis altas y tratamientos a largo plazo en ratas.

Palabras clave: Extracto alcohólico, fémur, húmero, enantato de metenolona, rata, *Tarantula cubensis*

INTRODUCTION

The alcoholic extract obtained from the spider *Tarantula cubensis* has been licensed and offered for sale as a Homeopathic Medicine in Veterinary Medicine. *Tarantula cubensis* alcoholic extract (TCAE) is a product that has been frequently preferred in Veterinary Medicine in the recent times for many diseases. In the product's package insert the target species are defined as horse (*Equus caballus*), cattle (*Bos taurus*), dog (*Canis lupus familiaris*), cat (*Felis catus*), pig (*Sus scrofa domestica*), sheep (*Ovis aries*), and goat (*Capra hircus*). It has been stated that TCAE produces demarcation, regeneration, antiphlogistic and resolutive effects in septic cases, dermatitis, inflammatory nail diseases, phlegmons, ulcers, boils, purulent lesions and cases with purulent necrosis and pathologically varying proliferative and necrotic tissues [1]. The studies with TCAE have reported that it may be safe to make use of during pregnancy [2] and expedites healing in oral lesions [3] and tendon ruptures [4]. It has also been reported that it may exert antioxidant activity [5], reduce the formation of aberrant cryptal foci (ACF) and polyps in experimental colon cancer [6, 7]. In addition, TCAE has been reported to have an antiproliferative effect in experimental colon cancer [8]. It has been reported that TCAE administration in the first period following birth in cattle can increase the rate of uterus involution [9] and does not cause significant side effects in horses [10].

Preparations containing Anabolic Androgenic Steroids (AAS) are licensed by the authorized institutions of the Countries and produced and sold by pharmaceutical companies for the treatment of hypogonadism in men, delayed puberty, and suppression of lactation, post-menopausal loss of libido, and aplastic anaemia in women, as well as treatment of conditions with increased catabolism and hereditary angioedema with a physician's prescription [11]. In males, 95% of Testosterone is secreted from Leydig cells in the testes, its small amounts are secreted from Sertoli and epididymis cells and the adrenal gland cortex. In females, it is secreted from the ovaries and very little from the adrenal gland cortex [12, 13]. These effects of Testosterone, which acts by binding to androgen receptors (AR) are observed in the penis, accessory genital glands, genital ducts, skin, bone, bone marrow, muscle, brain, adipose tissue and liver, in which the receptors are concentrated [14, 15]. AASs can be abused by athletes to improve performance in tasks related to endurance by developing muscle quantity and strength. Significant side effects can be seen as a result of the prolonged use of these hormones [16]. Many derivatives of Testosterone, which was discovered in 1935, have been produced so far [17].

There is an anatomical structure called as epiphysis which promotes growth and development in the proximal and distal parts of the long bones of the body. This formation assumes a significant role in extending the length of the bone during the growth period of the organism [18]. One of the most important side effects of AASs is the premature closure of bone growth plates (epiphyseal plate) during the growth period. Therefore, prolonged use of these substances may cause short stature in livestock. Some researchers have also reported that the use of AAS has a negative effect on the healing of injuries. Therefore, it is recommended to be used with caution in clinical treatment [19]. Methenolone Enanthate (ME), a Testosterone-like synthetic commercial product, is recommended to be used especially in the therapy of bone marrow failure-associated anemia, wasting syndromes, osteoporosis, and sarcopenia [20]. The high-dose administration of ME to rats (*Rattus norvegicus*) may arrest the growth of these bones by causing early epiphyseal closure in

femur and humerus bones, and in consequence, it may cause negative effects on bone development, especially in athletes and sedentary individuals who use AAS at a young age [21].

In the present study, given the negative effects of AASs on bone development [19] and the regeneration effect of TCAE [1], it was hypothesised that the administration of ME to growing male rats may slow down bone development, while TCAE administration may prevent this drawback.

The aim of this study was to determine the effects of TCAE, ME, and the combined use of the two drugs on the humerus and femur lengths and corpus thickness, cavum medullare diameter and cortex thickness of these bones in growing male rats.

MATERIALS AND METHODS

The study was conducted on a total of 36 5-week-old male Wistar Albino rats procured from the Experimental Medicine Application and Research Centre of Selcuk University. During the study, the animals were accommodated in a total of eight polysulfone cages (Tecniplast, 1354G Eurostandard Type IV, Italy), with a maximum of five animals in each cage, at $24 \pm 1^\circ\text{C}$, 60% atmospheric humidity and 12 h of light and 12 h of darkness. Standard rat feed and water were supplied *ad libitum*. Before the study, permission was obtained from the "Local Ethics Committee for Animal Experiments" (Approval number: 2021/3).

Experimental design and animal studies

Control group (n: 6)

In this group, the feed and water needs of the animals were supplied *ad libitum* during the experiment. Normal saline solution (NS) was administered subcutaneously (SC) once a week for 7 weeks at a dose of $0.2 \text{ mL}\cdot\text{rat}^{-1}$.

TCAE group (n:10)

This group was subjected to the same care and feeding conditions as the animals in group 1. TCAE (Theranekron D6^{inj}, Richter Pharma, Austria) was administered SC once a week for 7 weeks at a dose of $0.2 \text{ mL}\cdot\text{rat}^{-1}$.

ME group (n:10)

This group was subjected to the same care and feeding conditions as the animals in group 1. ME (Rimobolan^{ampul}, Bayer Türk Kimya, Istanbul, Turkey) was administered intramuscularly (IM) once a week for 7 weeks at the recommended dose of $10 \text{ mg}\cdot\text{kg}^{-1}$ (diluted in ricinus communis seed oil).

TCAE + ME group (n:10)

This group was subjected to the same care and feeding conditions as the animals in group 1. TCAE was administered SC at a dose of $0.2 \text{ mL}\cdot\text{rat}^{-1}$ and ME was administered IM at the recommended dose of $10 \text{ mg}\cdot\text{kg}^{-1}$ (diluted in ricinus communis seed oil) once a week for 7 weeks.

The body weights of all animals in the groups were measured and recorded with a precision balance (Kern PFB 6000, Germany) before the beginning of the study and once a week during the study. Weekly group averages were taken and necessary ME dose adjustments were made. Animals in the groups were anaesthetised with Ketamine ($95 \text{ mg}\cdot\text{kg}^{-1}$, SC) + Xylazine ($5 \text{ mg}\cdot\text{kg}^{-1}$, SC) and sacrificed by cervical dislocation

1 week after the last administration (at the end of the 8th week) by measuring their final weights with a precision balance. Following sacrifice, femur and humerus bones were resected from all groups of animals. Extremity bones were dissected and the obtained bones were cleaned from soft tissues and dried. The anatomical reference points [A= Length, B= Corpus Thickness, $(C1+C2)/2$ = Cavum Medullare Diameter, $(D1+D2)/2$ = Cortex Thickness of the femur and humerus bones on the right and left sides (FIGS. 1 and 2) were identified and necessary morphometric values were measured from those points with a 0.01 mm accuracy digital calliper (Mitutoyo CD-15APX Digital Calliper, Japan) [22, 23, 24, 25, 26]. The obtained materials were captured with a digital camera (Nikon D200, China) (FIGS. 1 and 2). "Nomina Anatomica Veterinaria" was used for anatomical terms [27].

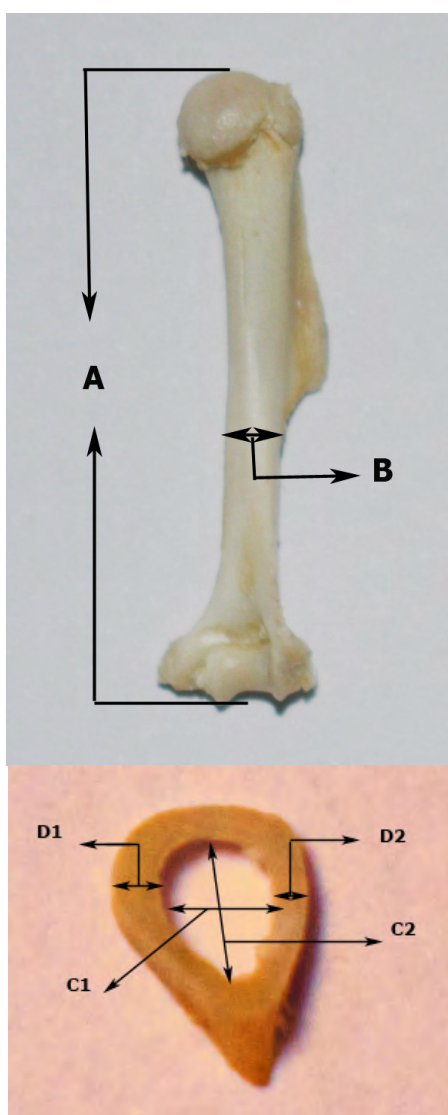


FIGURE 1. Length (A), Corpus thickness (B), Cavum medullare diameter $\{(C1+C2)/2\}$ and Cortex thickness $\{(D1+D2)/2\}$ reference points of the femur (Right medial side). A: Distance between the endpoints of the caput ossis femoris and trochlea ossis femoris, B: Medio-lateral thickness of the corpus of the femur (lower border level of the trochanter tertius), C1-C2: Medio-lateral and cranio-caudal mean diameter of the cavum medullare at the level of the corpus of the femur, D1-D2: Mean thickness of the cortex (cortical bone - substantia compacta) at the level of the corpus of the femur

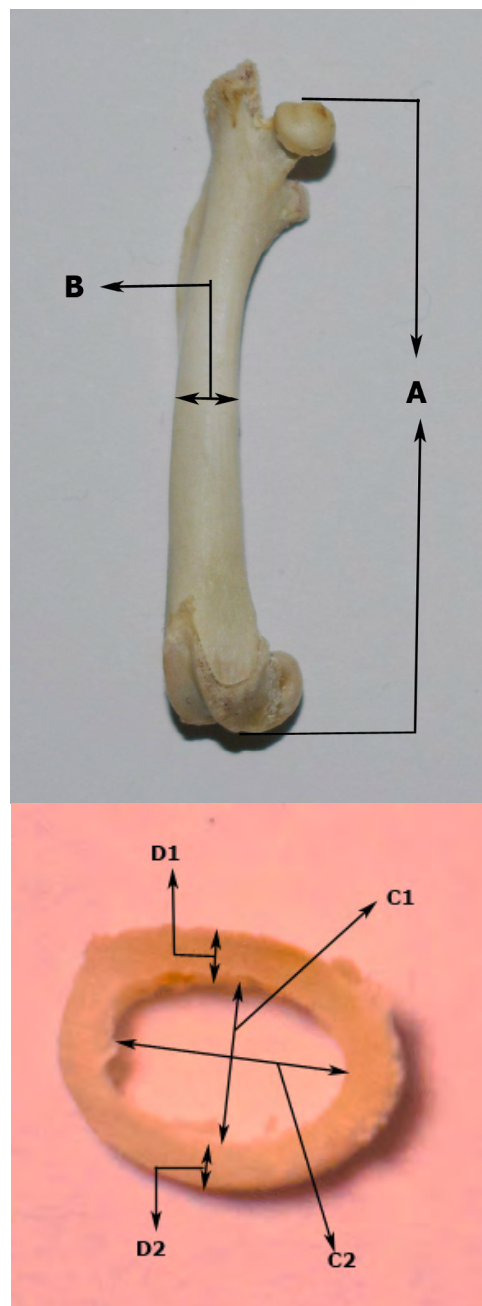


FIGURE 2. Length (A), Corpus thickness (B), Cavum medullare diameter $\{(C1+C2)/2\}$ and Cortex thickness $\{(D1+D2)/2\}$ reference points of the humerus (Right medial side). A: The distance between the endpoints of the caput humeri and trochlea humeri. B: Medio-lateral thickness of the corpus of the humerus (lower border level of the tuberositas deltoidea). C1-C2: Medio-lateral and cranio-caudal mean diameter of the cavum medullare at the level of the corpus of the humerus. D1-D2: Mean thickness of the cortex (cortical bone - substantia compacta) at the level of the corpus of the humerus

The data were statistically analysed using SPSS 22.0 software. The data were compared by ANOVA and Duncan test as post-hoc test. The results were represented as mean ± SD (SPSS 22.0 for Windows/SPSS® Inc, Chicago, USA). The value of $P < 0.05$ was considered as statistically significant.

RESULTS AND DISCUSSION

During the experiment, one animal from the ME group died in the second week and one animal from the TCAE group died in the third week.

FIGS. 3 and 4 presented the femur and humerus length measures obtained from the study. No statistical difference was determined between the bone lengths in the groups ($P > 0.05$).

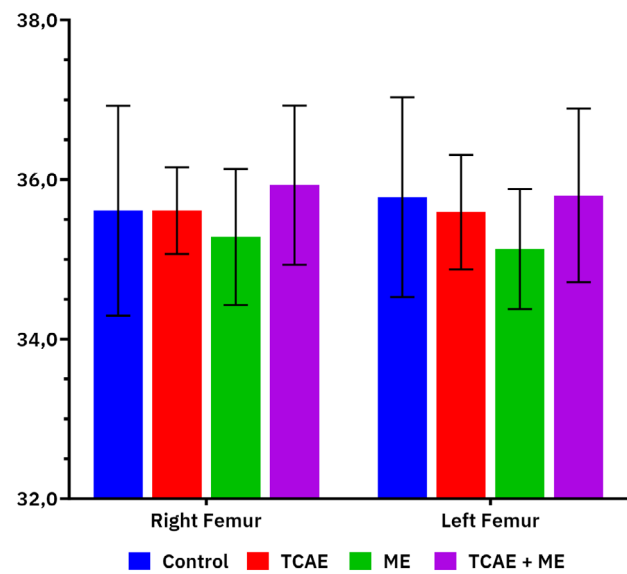


FIGURE 3. Lengths of right and left femurs between groups (mm)

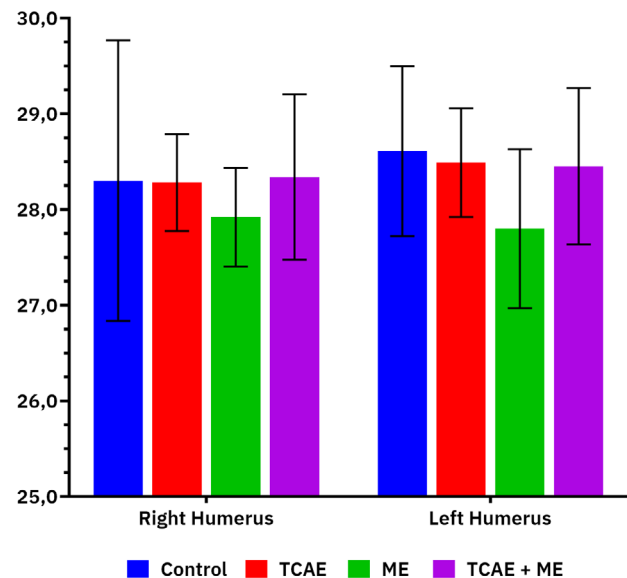


FIGURE 4. Lengths of right and left humerus between groups (mm)

FIGS. 5 and 6 presented the corpus thicknesses of the femur and humerus obtained from the study. No statistical difference was determined between the corpus thicknesses in the groups ($P > 0.05$).

FIGS. 7 and 8 presented the cavum medullare diameters of the femur and humerus obtained from the study. No statistical difference was determined between the cavum medullare diameters in the groups ($P > 0.05$).

FIGS. 9 and 10 presented the cortex thicknesses of the femur and humerus obtained from the study. No statistical difference was determined between the cortex thicknesses in the groups ($P > 0.05$).

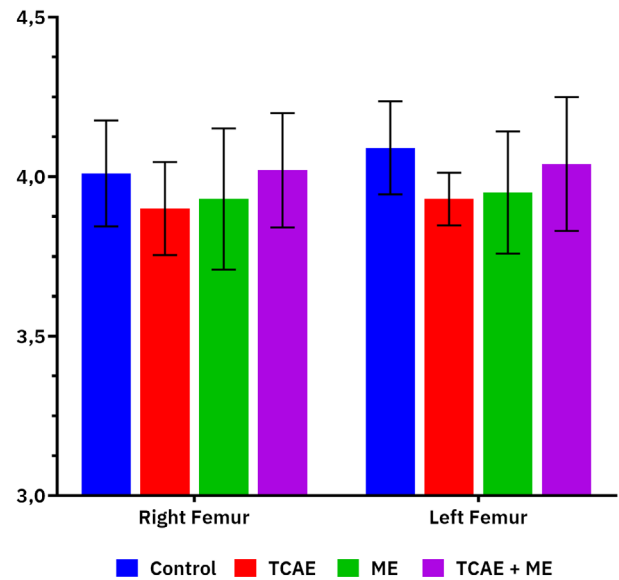


FIGURE 5. Corpus thicknesses of right and left femurs between groups (mm)

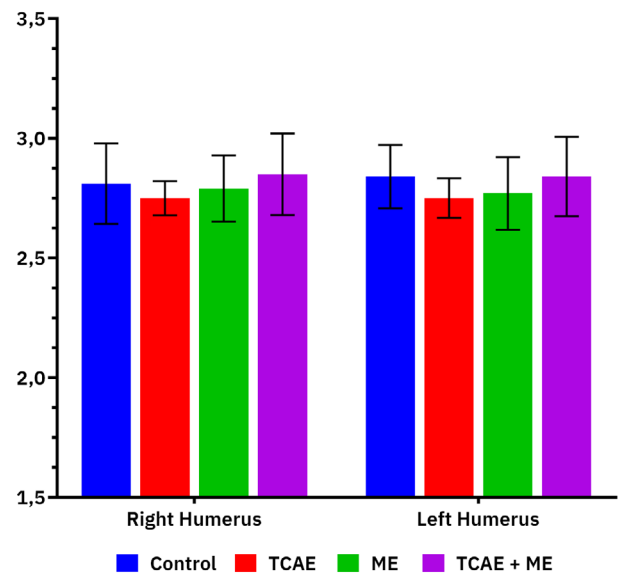


FIGURE 6. Corpus thicknesses of right and left humerus between groups (mm)

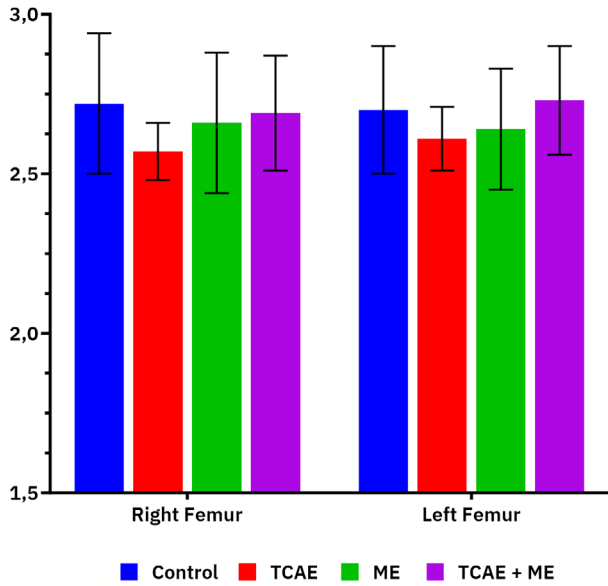


FIGURE 7. Cavum medullare diameters of right and left femurs between groups (mm)

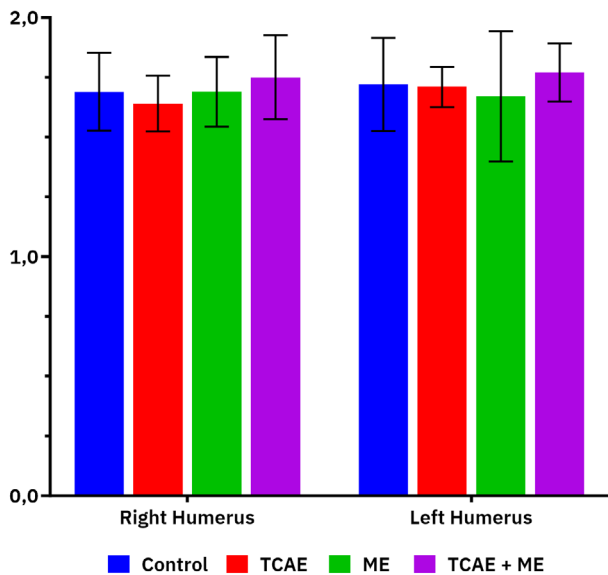


FIGURE 8. Cavum medullare diameters of right and left humerus between groups (mm)

TABLE I shows the weekly body weight gains observed in the animals throughout the study. In the sixth week of the study, statistical differences between the groups started to be determined ($P < 0.05$). At the end of the experiment, the body weight values of the control group were higher than those of the other 3 groups ($P < 0.05$).

It has been reported that the continuous use of AAS has very serious side effects except for the medical use of Testosterone for its known normal physiological effects [28]. In this study, no statistical difference was determined between femur length ($P > 0.05$, FIG. 3), corpus thickness ($P > 0.05$, FIG. 5), cavum medullare diameter ($P > 0.05$, FIG. 7) and cortex thickness ($P > 0.05$, FIG. 9) among control, TCAE, ME, and TCAE + ME groups at the end of the experiment in 5-week-old

Wistar albino male rats. No information on the effect of TCAE on bone development was found in the literature review. However, TCAE application to embryo chicken eggs was reported to have no effect on development [2]. It has been reported that intraperitoneal (IP) administration of Methenolone Enanthate to 40-day-old Sprague-Dawley male and female rats at a dose of $5 \text{ mg}\cdot\text{kg}^{-1}$, five days a week for four weeks caused shortening of femur length in males, and longer femur in females, as well as a decrease in corpus thickness in males and an increase in females, and no difference was observed in cavum medullare diameter in both sexes, and while no difference was determined in cortex thickness in males, it caused an increase in females [22].

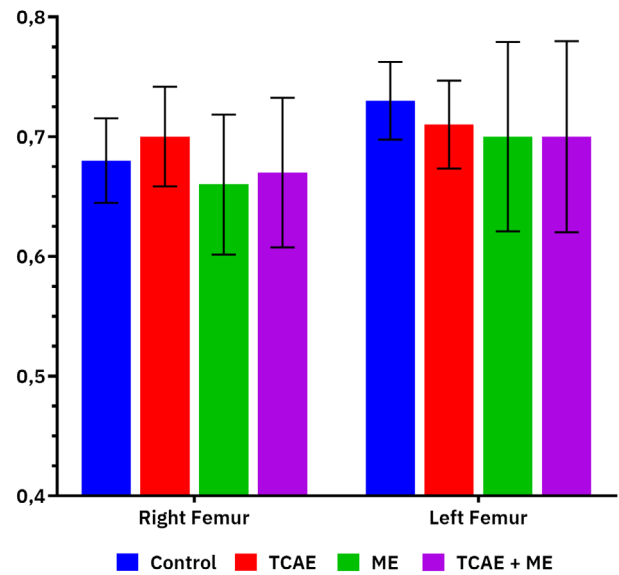


FIGURE 9. Cortex thicknesses of right and left femur between groups (mm)

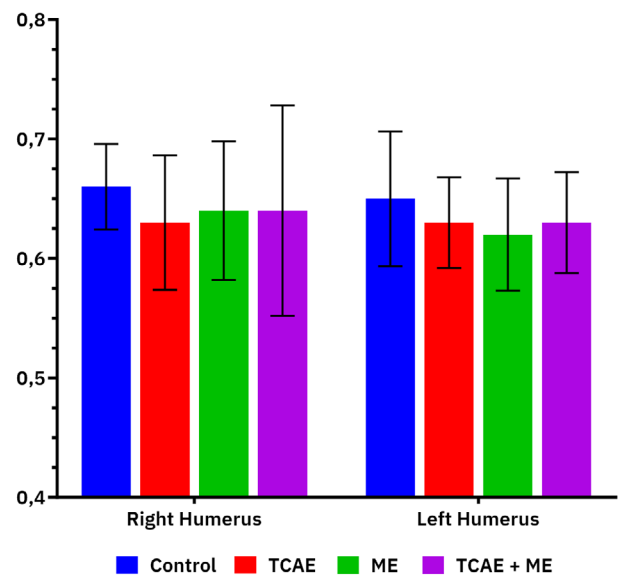


FIGURE 10. Cortex thicknesses of the right and left humerus between groups (mm)

TABLE I
Body weight gain (g) of the rats by weeks (mean±SD)

Groups	Control	TCAE	ME	TCAE+ME
1st Week	126.38±15.63	126.22±11.04	125.89±13.36	126.10±9.05
2nd Week	183.25±17.27	180.22±15.83	179.78±13.32	182.80±13.07
3rd Week	237.00±21.88	229.11±17.95	220.00±14.97	232.60±19.60
4th Week	291.75±25.01	278.89±17.47	271.56±19.54	274.00±27.63
5th Week	338.25±27.20	316.22±16.51	311.78±25.31	312.00±33.49
6th Week	367.25±28.20 ^a	341.11±16.34 ^{ab}	334.22±29.74 ^b	342.00±37.45 ^{ab}
7th Week	401.50±31.58 ^a	367.33±18.00 ^{ab}	349.78±46.97 ^b	371.40±41.22 ^{ab}
8th Week	431.50±33.58 ^a	394.67±19.65 ^b	382.50±32.86 ^b	396.60±48.07 ^b

^{a, b}: Different letters in the same row were statistically significant ($P < 0.05$)

Lok and Yalcin [23] reported that when Nandrolone, another AAS derivative, was administered to 30-day-old male and female rats at a dose of 10 mg·kg⁻¹, IP, five days a week for four weeks, femur length was shortened compared to the control group, and no difference was identified in femur corpus thickness, cavum medullare diameter and cortex thickness. Another study reported that when Testosterone was administered SC to 50-day-old Sprague-Dawley rats at a dose of 5 mg·kg⁻¹ five days a week for 10 weeks, it shortened femur length in males and caused extension in females, thinning in corpus thickness in males but no effect in females, and no difference in cavum medullare diameter in males, narrowing in females and no effect on cortex thickness in both sexes [24]. Ozdemir and Lok [21] stated that when ME was administered IM to 28-day-old Wistar male rats with and without exercise at a dose of 10 mg·kg⁻¹ five days a week for five weeks, the femur length of both groups was shorter than the control group, and no difference was found in corpus thickness, cavum medullare diameter and cortex thickness. When the data of the present study and the literature were examined, it was observed that TCAE application had no effect on femur development during the growth period and AAS applications caused no fixed and definite effects.

In the present study, no statistical difference was determined between humerus length ($P > 0.05$, FIG. 4), corpus thickness ($P > 0.05$, FIG. 6), cavum medullare diameter ($P > 0.05$, FIG. 8) and cortex thickness ($P > 0.05$, FIG. 10) in the Control, TCAE, ME and TCAE + ME groups at the end of the study. As stated above, no information on the effect of TCAE on bone development was found in the literature reviews, however, its effect was not reported on growth in the embryonal period in poultry [2]. It has been reported that the IP administration of ME to 40-day-old male and female Sprague-Dawley rats at a dose of 5 mg·kg⁻¹, five days a week for four weeks caused shortening of humerus length in males, an extension of the humerus in females, a decrease in corpus thickness in males but an increase in females, no effect on cavum medullare diameter in males but an increase in females, a decrease in cortex thickness in males but no effect in females [25].

Lok and Yalcin [26] reported that when Nandrolone, another AAS derivative, was administered IP to 30-day-old Sprague-Dawley rats at a dose of 10 mg·kg⁻¹ five days a week for four weeks, there was no change in humerus length in males, but shortening in females, and no change was observed in corpus thickness, while cavum medullare diameter had no change in males, but increased in females, and no difference was observed in cortex thickness in males, but a decrease

in females. In another study, it was reported that when 50-day-old Sprague-Dawley rats were administered Testosterone SC at a dose of 5 mg·kg⁻¹ five days a week for 10 weeks, humerus length shortened in males and increased in females, corpus thickness decreased in both sexes, cavum medullare diameter showed no difference in both sexes, cortex thickness had no effect in males but an increase in females [24]. Ozdemir and Lok [21] reported that when ME was administered IM to a 28-day-old Wistar male rats at a dose of 10 mg·kg⁻¹ five days a week for five weeks, the humerus length was shorter than the control group, and no difference was found in corpus thickness, cavum medullare diameter and cortex thickness.

The present study indicated no change in the parameters of the femur and humerus. This may be associated with the use of different AAS derivatives as well as dose, route of administration, duration of administration, breed, sex, and age differences. Although the study revealed no statistical difference between the body weights of the groups at the beginning of the experiment, a statistical difference was observed in the sixth week and the control group was heavier than the other three groups at the end of the experiment ($P < 0.05$, TABLE I). In a study in which a 10 mg·kg⁻¹ of Nandrolone was administered IP to 30-day-old Sprague-Dawley rats 5 days a week for 4 weeks, it was reported that no statistical difference was determined between the experimental groups in terms of weights at the end of the study [23]. Ozdemir and Yalcin [29] reported no difference between body weights of the control group and the Testosterone group at the end of the experiment when Testosterone at a dose of 5 mg·kg⁻¹ was administered SC to 50-day-old Sprague-Dawley rats 5 days a week for 10 weeks. It was also reported that Testosterone may enhance lean muscle mass [30]. No study was directly available to prove that TCAE increases body weight in rats. However, it was reported that it had no effect on body weight in rats with colon cancer [6]. The loss of body weight observed in the experimental groups may be associated with the stress imposed by the application.

CONCLUSION

It can be stated that administration of ME at the recommended doses in rats in the growth period had no effect on femur and humerus development and slowed down the body weight gain, TCAE administration had no effect on femur and humerus development and slowed down the body weight gain. When the studies conducted with AAS are examined, it can be stated that no similar results could be obtained and the differences between the studies may be due to the derivative of the drug used, dose, route and duration of administration, experimental animal breed, sex, and age differences.

ACKNOWLEDGEMENTS

This study was supported by SUBAPK (21212022)

Conflict of Interest

The authors declare that they have no conflict of interest.

Data availability statement

The data that support the findings of this study are available from the corresponding author upon reasonable request.

BIBLIOGRAPHIC REFERENCES

- [1] Coşkun D. Veteriner Destek Tedavi: *Tarantula Cubensis* Alkolik Ekstraktı, İnaktif Parapoxvirüs Ovis ve *Corynebacterium Cutis* Lizatı. Dicle Üniversitesi Veteriner Fakültesi Dergisi. [Internet]. 2017 [cited 24 April 2023]; 10(1):30–37. Available in: <https://bit.ly/45AgxZx>.
- [2] Canbar R, Akcakavak G, Uslu M, Bas AL. Determination of embryotoxic effects of *Tarantula cubensis* alcoholic extract with in ovo model. Magy. Allatorvosok Lapja. [Internet]. 2021 [cited 18 April 2023]; 143(8):497–504. Available in: <https://bit.ly/47EIXM4>.
- [3] Albay MK, Sahinduran S, Kale M, Karakurum MC, Sezer K. Influence of *Tarantula cubensis* extract on the treatment of the oral lesions in cattle with blue tongue disease. Kafkas Univ. Vet. Fak. Derg. [Internet]. 16(4):593–96. doi: <https://doi.org/kp7n>
- [4] Bonamin LV, Cardoso TN, de Carvalho AC, Amaral JG. The use of animal models in homeopathic research – a review of 2010–2014, PubMed indexed papers, Homeopathy. [Internet]. 2015; 104(04):283–91. doi: <https://doi.org/f744t2>
- [5] Dik B, Er A, Corum O. Effect of alcoholic extract of *Tarantula cubensis* (TheraneKron®) on serum thiobarbituric acid–reactive species concentrations in sheep. Eurasian J. Vet. Sci. [Internet]. 2014 [cited 18 April 2023]; 30(2):68–71. Available in: <https://bit.ly/45y3e31>.
- [6] Er A, Ozdemir O, Coskun D, Dik B, Bahcivan E, Faki HE, Yazar E. Effects of *Tarantula cubensis* alcoholic extract and *Nerium oleander* distillate on experimentally induced colon cancer. Rev. Med. Vet. [Internet]. 2019 [cited 18 April 2023]; 170(1–3):15–21. Available in: <https://bit.ly/3P1rlIc>.
- [7] Akcakavak G, Ozdemir O. Effect of *Tarantula cubensis* alcoholic extract on tumour pathways in azoxymethane–induced colorectal cancer in rats. Acta Vet. Brno. [Internet]. 2023; 92(1):79–88. doi: <https://doi.org/kp7q>
- [8] Özdemir Ö, Akçakavak G, Tuzcu M. Effect of *Tarantula cubensis* alcoholic extract and *Nerium oleander* distillate on cell proliferation markers in colon carcinogenesis. Rev. Cientif. FCV-LUZ. [Internet]. 2022; 32(1):1–8. doi:10.52973/rcfcv-e32150.
- [9] Kacar C, Kaya S. Uterine Infections in cows and effect on reproductive performance. Kafkas Univ. Vet. Fak. Derg. [Internet]. 2014; 20(6):975–82. doi: <https://doi.org/kp7r>
- [10] Sardari K, Mohri M, Sabzevari S, Fathi B. Effects of the TheraneKron® an alcoholic extract of the *Tarantula cubensis* on hematology and serum biochemical properties in horses. Iran. J. Vet. Sci. Technol. [Internet]. 2014; 3(2):9–16. doi: <https://doi.org/kp7s>
- [11] Gok R, Yalcin AD, Tural U. Abuse of Anabolic Steroids–Review. Bagim. Derg. [Internet]. 2016 [cited 11 May 2023]; 17(4):172–80. Available in: <https://bit.ly/3KSk44D>.
- [12] Mycek MJ, Harvey RA, Champe PC. Farmakoloji. 2nd ed. Ankara (Turkey): Günes Kitapevi; 2001. p 270–1.
- [13] Kayaalp SO. Rasyonel Tedavi Yonunden Tibbi Farmakoloji. 11th ed. Ankara (Turkey): Feryal Matbaasi; 2005. p 1126–57.
- [14] Bokesoy TA, Cakici I, Melli M. Farmakoloji Ders Kitabı. Ankara (Turkey): Gazi Kitabevi; 2000. p 380–5.
- [15] Guyton AC, Hall JE. Textbook of Medical Physiology. 9th ed. Philadelphia (PA): WB Saunders Company; 2001. p 1011–3.
- [16] Koc H, Yuksel O. Kadinlarda fiziksel ve fizyolojik performansin degerlendirilmesi. Dumlupinar Uni. Sos. Bil. Der. [Internet]. 2007 [cited 11 May 2023]; 9:1–12. Available in: <https://bit.ly/3qGiE6A>.
- [17] Maravelias C, Dona A, Stefanidou M, Spiliopoulou C. Adverse effects of anabolic steroids in athletes: A constant threat. Toxicol. Lett. [Internet]. 2005; 158(3):167–75. doi: <https://doi.org/fth3pp>
- [18] Dursun N. Veteriner Anatomi. Ankara (Turkey): Medisan Yayinlari; 2000. p 67–85.
- [19] Goldfarb AF, Napp EE, Stone ML, Zuckerman MB, Simon J. The anabolic effects of norethandrolone, a 19–nortestosterone derivative. Obstet. Gynecol. 1958; 11(4):454–8. PMID: 13517756.
- [20] Tauchen J, Jurasek M, Huml L, Rimpelova S. Medicinal use of testosterone and related steroids revisited. Molecules. [Internet]. 2021; 26(4):1032. doi: <https://doi.org/gjpmn7>
- [21] Ozdemir M, Lok S. The effects of methenolone enanthate supplement with exercise on rats’ bones. Turkish J. Sport Exercise. [Internet]. 2019; 21(2): 276–80. doi: <https://doi.org/kp7v>
- [22] Bozkurt I, Pepe K, Ozdemir M, Ozdemir O, Coskun A. Morphometric evaluation of the effect of methenolone enanthate on femoral development in adolescent rats. Sci. Res. Essays. [Internet]. 2011 [cited 11 May 2023]; 6(7): 1634–8. Available in: <https://bit.ly/30GWagg>.
- [23] Lok S, Yalcin H. Morphometric effect of nandrolone decanoate used as doping in sport on femur of rats in puberty period. Arch. Budo. [Internet]. 2010 [cited 11 May 2023]; 6:218–220. Available in: <https://bit.ly/3E4eoAl>.
- [24] Ozdemir M, Yalcin H. The morphometric effects of testosterone, used as a doping agent, on the humerus and femur of pubescent male and female rats. Selcuk Univ. Beden Egit. Spor. Bilim. Derg. [Internet]. 2011; 13(2):172–7. doi: <https://doi.org/kp7x>
- [25] Bozkurt I, Ozdemir M, Pepe K, Ozdemir O, Coskun A. Morphometric evaluation of the effect of methenolone enanthate on humeral development in adolescent rats. Sci. Res. Essays. [Internet]. 2011 [cited 11 May 2023]; 6(13):2676–81. Available in: <https://bit.ly/47lcNOP>.
- [26] Lok S, Yalcin H. Morphometric Effect of Nandrolone on Humerus of the Pubertal Term Rats. J. Anim. Vet. Adv. [Internet]. 2010; 9:1771–1775. doi: <https://doi.org/dmrrhm>
- [27] Nomina Anatomica Veterinaria. International committee on veterinary gross anatomical nomenclature. 6th ed. Editorial Committee Hanover (Germany), Ghent (Belgium), Columbia, MO (U.S.A.), Rio de Janeiro (Brazil); 2017; p 11–29.
- [28] Quaglio G, Fornasiero A, Mezzelani P, Moreschini S, Lugoboni F, Lechi A. Anabolic steroids: dependence and complications of chronic use. Intern Emerg. Med. [Internet]. 2009; 4(4):289–96. doi: <https://doi.org/btzx4f>
- [29] Ozdemir M, Yalcin H. The effects of testosterone, a prohibited substance, on the body and organ weights of pubescent rats. Ovidius Univ. Ann. Ser. Phys. Educ. Sport. Sci. Mov. Health. [Internet]. 2012 [cited 15 May 2023]; 12(1):83–8. Available in: <https://bit.ly/30NdOPt>.
- [30] Bhasin S, Storer TW, Berman N, Callegari C, Clevenger B, Phillips J, Bunnell T, Tricker R, Shirazi A, Casaburi R. The effects of supraphysiologic doses of testosterone on muscle size and strength in normal men. N. Engl. J. Med. 1996; 335:1–7. [Internet]. doi: <https://doi.org/d3678s>