

# Fecal Microbiota Transplantation for Immune Checkpoint Inhibitor-Induced Colitis Is Safe and Contributes to Recovery: Two Case Reports

Bas Groenewegen,\* Elisabeth M. Terveer,\* Arjen Joosse,†  
 Marieke C. Barnhoorn,‡§ and Romy D. Zwittink\*

**Summary:** Immune checkpoint inhibitors (ICIs) have improved the prognosis in multiple cancer types. However, ICIs can induce immune-related adverse events such as immune-mediated enterocolitis (IMC). The gut microbiota may be implicated in IMC development. Therefore, we investigated fecal microbiota transplantation (FMT) as a treatment option for 2 patients with metastatic cancer suffering from refractory IMC. The patients were treated with, respectively, 1 and 3 FMTs after vancomycin pre-treatment. We monitored defecation frequency, fecal calprotectin, and microbiota composition. After FMT, both patients improved in defecation frequency, were discharged from the hospital, and received lower dosage of immunosuppressive therapy. Patient 1 developed an invasive pulmonary aspergillosis deemed to be related to prolonged steroid exposure. Patient 2 suffered from a *Campylobacter jejuni* infection after the first FMT and was treated with meropenem, resulting in a low-diversity microbiota profile and increased calprotectin levels and defecation frequency. After a second and third FMT, bacterial diversity increased and defecation frequency and calprotectin levels decreased. Pre-FMT, both patients showed low bacterial richness, but varying bacterial diversity. After FMT, diversity and richness were similar to healthy donor levels. In conclusion, FMT resulted in improvement of IMC symptoms and corresponding microbial changes in 2 cancer patients with refractory IMC. While more

research is warranted, microbiome-modulation could be a promising new therapeutic option for IMC.

**Key words:** gut microbiome, fecal microbiota transplantation, immune checkpoint inhibitor-induced colitis, immune-mediated colitis, immune checkpoint inhibitors

(*J Immunother* 2023;46:216–220)

## BACKGROUND

Immune checkpoint inhibitors (ICIs) have improved the prognosis in several types of metastasized cancer. ICIs are monoclonal antibodies that enhance the cytotoxic T-cell anti-tumor response by blocking T-cell immune checkpoints, which act as a brake on the immune response. Currently, widely used ICIs target the immune checkpoints cytotoxic T-lymphocyte-associated antigen 4 (CTLA-4), programmed death 1 receptor (PD-1), or its ligand (PDL-1). ICI treatment can induce several immune-related adverse events (irAEs).<sup>1</sup> Although the underlying mechanisms of irAEs are not fully understood, ICI-mediated disturbance of self-tolerance is thought to play a major role. A prevalent irAE following ICI therapy is immune-mediated enterocolitis (IMC): an intestinal condition phenotypically resembling inflammatory bowel disease. A proposed mechanism for IMC development is the (re)activation of tissue resident memory T cells in the gut by ICI-mediated blockage of CTLA-4 and/or PD-1 receptors, leading to inflammation.<sup>1</sup> Evidence, although preliminary, indicates an association between IMC development and differential abundance of specific gut bacterial genera.<sup>2</sup> The link between microbial disbalance and development of IMC has been an incentive for studying microbiome-modifying therapies like fecal microbiota transplantation (FMT) for treatment of IMC.<sup>3–5</sup> To further investigate the treatment potential of FMT, we determined defecation frequency, fecal calprotectin, and microbiota composition in 2 patients with therapy-refractory IMC treated with FMT, with the aim to acquire insight into the clinical and microbial course after FMT treatment.

## CASE PRESENTATIONS

### Patient One

A male in his 60s with metastasized melanoma was treated with 3 cycles of nivolumab (PD-1 inhibitor) combined with ipilimumab (CTLA-4 inhibitor). One month after his final treatment cycle, a CT-scan showed partial response with a reduction in size of all metastases. After the third ipilimumab-nivolumab cycle, the patient presented with severe diarrhea. A colonoscopy showed a pancolitis with biopsies negative for cytomegalovirus and

Received for publication September 9, 2022; accepted April 8, 2023.

From the \*Department of Medical Microbiology, Leiden University Medical Center, Albinusdreef 2, 2333ZA Leiden, The Netherlands; †Department of Oncology, Erasmus Medical Center, Doctor Molewaterplein 40, 3015GD Rotterdam, The Netherlands; ‡Department of Gastroenterology and Hepatology, Haga Hospital, Els Borst-Eilersplein 275, 2545AA The Hague, The Netherlands; and §Department of Gastroenterology and Hepatology, Leiden University Medical Center, Albinusdreef 2, 2333ZA Leiden, The Netherlands.

M.C.B. and R.D.Z. are contributed equally.

Upon publication, the raw data for this report are made available in the European Nucleotide Archive (ENA) at EMBL-EBI under accession number PRJEB51242 (<https://www.ebi.ac.uk/ena/browser/view/PRJEB51242>).

This study conforms to the ethical guidelines of the 1975 Declaration of Helsinki as reflected in a priori approval by the institution's Human Research Committee, and was approved on December 16<sup>th</sup> 2015 by the METC of the LUMC (P15.154). Donors and patients provided written informed consent for collection and analysis of clinical data and feces samples. Both patients' next of kin provided written informed consent for publication.

Reprints: Bas Groenewegen, Albinusdreef 2, 2333 ZA Leiden, the Netherlands (e-mail: [b.groenewegen@lumc.nl](mailto:b.groenewegen@lumc.nl)).

Supplemental Digital Content is available for this article. Direct URL citations are provided in the HTML and PDF versions of this article on the journal's website, [www.immunotherapy-journal.com](http://www.immunotherapy-journal.com).

Copyright © 2023 The Author(s). Published by Wolters Kluwer Health, Inc. This is an open access article distributed under the Creative Commons Attribution License 4.0 (CCBY), which permits unrestricted use, distribution, and reproduction in any medium, provided the original work is properly cited.

histology compatible with IMC. The patient was subsequently treated with oral prednisone (b.i.d. 60 mg), 5 courses infliximab (4 courses 5 mg/kg, one 10 mg/kg), tacrolimus (b.i.d. 4 mg, escalated to b.i.d. 8 mg), and 2 courses vedolizumab (300 mg). All therapies had no clinical effect and the patient received 1 FMT via the compassionate use program of the Netherlands Donor Feces Bank.

The patient was pre-treated with vancomycin for 4 days and subsequently received an FMT containing 60g of donor feces (Supplement 1, Supplemental Digital Content 9, <http://links.lww.com/JIT/A747>, Supplemental Table 1, Supplemental Digital Content 1, <http://links.lww.com/JIT/A739>). Three days after FMT, he was discharged home with prednisone b.i.d. 40 mg. After an initial temporary deterioration of defecation consistency and frequency after FMT, coinciding with cefuroxime prophylaxis (due to a concurrent urolithiasis intervention), there was gradual improvement from 16 days post-FMT onwards to 2-to-4 times defecation of mushy or normal consistency per day (Fig. 1A, F). In contrast, fecal calprotectin never reached normal levels (< 50 µg/g) (Fig. 1B) and no particular patterns were present in C-reactive protein (CRP) or leukocyte levels that could be attributed to FMT (Supplemental Fig. 6, Supplemental Digital Content 2, <http://links.lww.com/JIT/A740>). Interestingly, microbiota analysis indicated an increase in bacterial diversity and richness after vancomycin treatment pre-FMT (Fig. 1D). Post-FMT, the diversity further increased and richness persisted at an elevated level. Both slightly exceeded the donor values 1 and a half month post-FMT.

The first month after FMT, microbiota composition resembled the donor sample more than prior FMT (Fig. 1C; Supplemental Fig. 1, Supplemental Digital Content 3, <http://links.lww.com/JIT/A741>). Relative abundances of Proteobacteria (*Escherichia-Shigella*) and Firmicutes (*Enterococcus*, *Lactococcus*, *Streptococcus*, and *Lactobacillus*) decreased the first month after FMT, whereas Actinobacteria (*Collinsella*, *Eggerthella Bifidobacterium*) and Bacteroidetes (*Bacteroides*, *Parabacteroides*, *Prevotella*, *Paraprevotella*) increased (Fig. 1E, Supplemental Fig. 2, Supplemental Digital Content 4, <http://links.lww.com/JIT/A742>, 4, Supplemental Digital Content 5, <http://links.lww.com/JIT/A743>). In contrast to the overall decreased relative abundance of Proteobacteria and Firmicutes post-FMT, the genera *Bilophila*, and *Faecalibacterium*, *Blautia*, *Fusicatenibacter*, *Subdoligranulum*, *Christensenellaceae*, *Oscillospiraceae* UCG-002, and *Dialister* slightly increased. The microbiota of the final sample (47 days post-FMT) seemingly reversed towards patient baseline level, with dominant *Enterococcus* and *Streptococcus*.

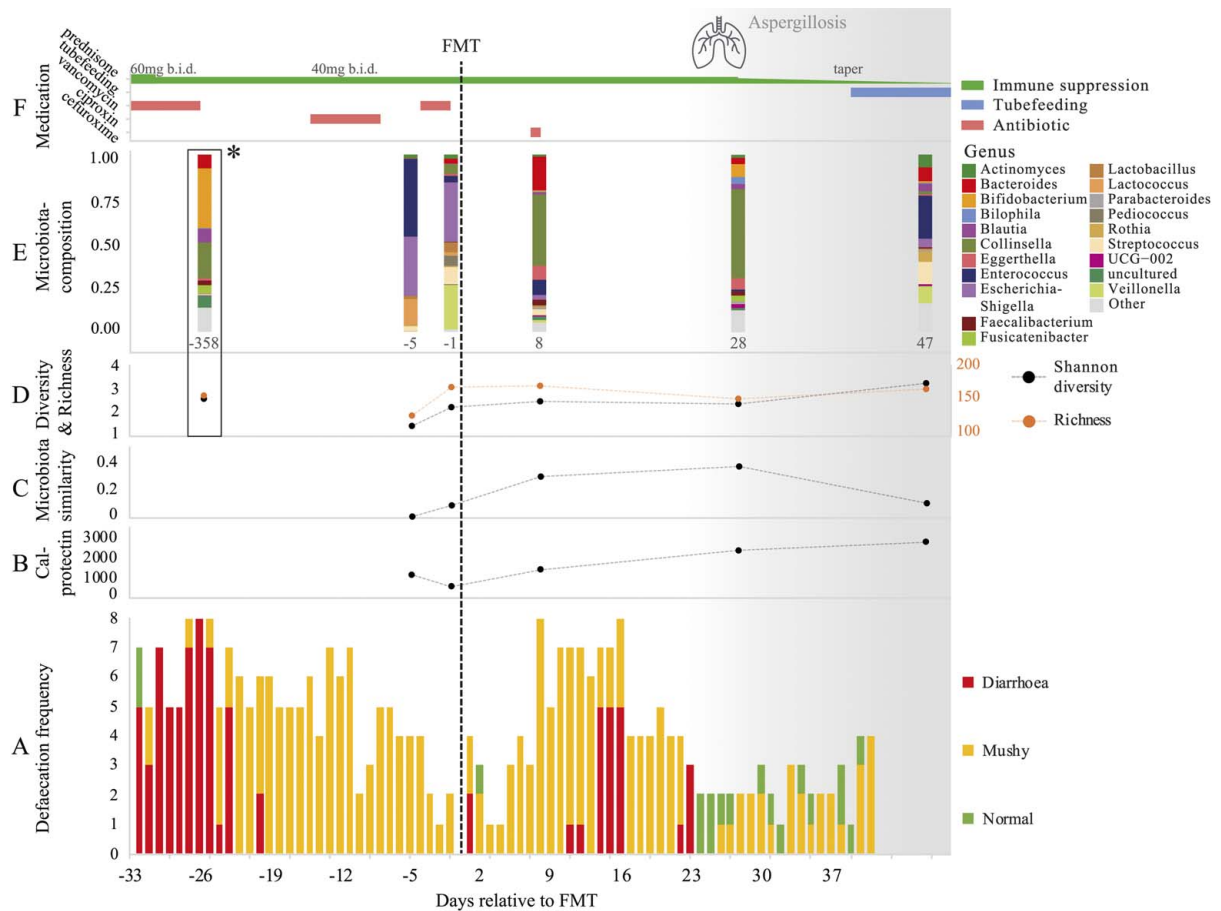
Prednisone dosage was not immediately tapered after FMT, as the diarrhea only improved gradually from day 16 onwards. The patient showed no recurrence of malignant disease on multiple CT-scans before and after the FMT until his death. Three weeks post-FMT, the patient was re-admitted with an invasive pulmonary aspergillosis with large cavitating pulmonary lesions most likely due to long-term use of immunosuppressive medication. At this point, the diarrhea had improved substantially (Fig. 1A) and prednisone was quickly tapered from b.i.d 40 mg to q.d. 10 mg within 3 weeks. Despite this, the patient's condition deteriorated quickly due to a tension pneumothorax caused by one of the cavitating lesions, after which he waived invasive treatment options, opted for best supportive care, and died 2 months post-FMT.

## Patient Two

A male in his 50s with a previous myocardial infarction and metastasized lung carcinoma was treated with pembrolizumab (PD-L1 inhibitor), combined with chemotherapy (pemetrexed and carboplatin). Treatment was stopped after 3 cycles, because of endoscopically confirmed IMC, with positive histology and exclusion of common infectious agents. Oral prednisone (q.d. 80 mg) was initiated without clinical efficacy, followed by 2 courses infliximab (5 mg/kg), intravenous prednisone (80 mg, 5 days) and tacrolimus (b.i.d. 4 mg, 3 weeks). In the absence of clinical improvement, the patient received 3 FMTs, of which the first and second FMT (60g donor feces) were performed 1 month apart (after respectively 6 and 5 days of vancomycin pre-treatment), followed 1 week later by the third FMT (30g donor feces) (Supplement 1, Supplemental Digital Content 9, <http://links.lww.com/JIT/A747>, Supplemental Table 1, Supplemental Digital Content 1, <http://links.lww.com/JIT/A739>).

The first FMT treatment resulted in rapid improvement of defecation frequency. Immunosuppressive therapy (tacrolimus b.i.d. 4 mg) was stopped 3 days after FMT (Fig. 2F) and the patient was discharged from the hospital. However, 5 days after FMT, the patient presented with diarrhea and increased defecation frequency caused by *Campylobacter jejuni* infection (Fig. 2A). A quality control of the used donor suspension tested negative for *C. jejuni* by culture and PCR. The infection was treated with meropenem. (Fig. 2F). As expected, the feces sample taken 15 days after FMT and during meropenem treatment contained a disturbed microbiota with low bacterial richness and diversity (Fig. 2D, E). Eradication of *C. jejuni* did not result in reduced defecation frequency and, therefore, 1 course of vedolizumab (300 mg) was given (Fig. 2F). In the absence of clinical response after vedolizumab, a second and third FMT were given respectively 36 and 50 days after the first FMT. Afterward, defecation frequency improved, calprotectin levels decreased and bacterial richness and diversity reached donor level (Fig. 2A, B, D). CRP and leukocyte levels were also (initially) decreased, but likely confounded by the *C. jejuni* infection and pneumonitis (Supplemental Fig. 7, Supplemental Digital Content 6, <http://links.lww.com/JIT/A744>). The overall microbiota composition of the patient did not become more similar to the donor (Fig. 2C, Supplemental Fig. 1, Supplemental Digital Content 3, <http://links.lww.com/JIT/A741>).

Compared to pre-FMT, feces after the second and third FMT showed a decrease in relative abundance of Bacteroidetes (*Bacteroides*, *Parabacteroides*), despite a slight increase in *Barnesiella* (Fig. 2E, Supplemental Fig. 3, Supplemental Digital Content 7, <http://links.lww.com/JIT/A745>, 5, Supplemental Digital Content 8, <http://links.lww.com/JIT/A746>). Relative abundance of the Actinobacteria phylum remained similar after FMT, with increased *Collinsella*, but decreased *Eggerthella*, *Actinomyces*, *Rothia*, and *Bifidobacterium*. An increase in Firmicutes was observed after the second FMT (*Faecalibacterium*, *Enterococcus*, *Dorea*, *Lachnospiraceae*, *Flavonifractor*, *Eubacterium hallii* group), and after the third FMT (mainly *Enterococcus*, *Lactococcus*, and *Faecalibacterium*), in both cases combined with a small increase in *Dialister* and *Paraprevotella*, but decrease in *Blautia*, *Streptococcus*, *Fusicatenibacter*, *Erysipelotrichaceae* UCG-003, *Ruminococcus gauvreaui*, and *Lachnospira*. Relative abundance of Proteobacteria (*Escherichia-Shigella*, *Sutterella*) decreased after the second



**FIGURE 1.** Overview of clinical and microbiota data of patient one in the course of fecal microbiota transplantation for immune-mediated colitis. \*Donor microbiota composition and diversity; A, Defecation frequency (times/day); B, Fecal calprotectin levels ( $\mu\text{g/g}$ ); C, Microbiota similarity to donor (1-Bray-Curtis dissimilarity); D, Microbial alpha-diversity, where Shannon diversity reflects the number and relative distribution of bacteria (operational taxonomic units (OTUs)) and richness reflects the total count of different bacteria (OTUs); E, Microbiota composition profiles, depicted as relative abundance of bacterial genera; F, Medication.

FMT, despite a minor increase of *Bilophila* and *Parasutterella*. *Escherichia-Shigella* markedly increased after the third FMT, leading to an *Enterococcus* and *Escherichia-Shigella* dominant microbiota.

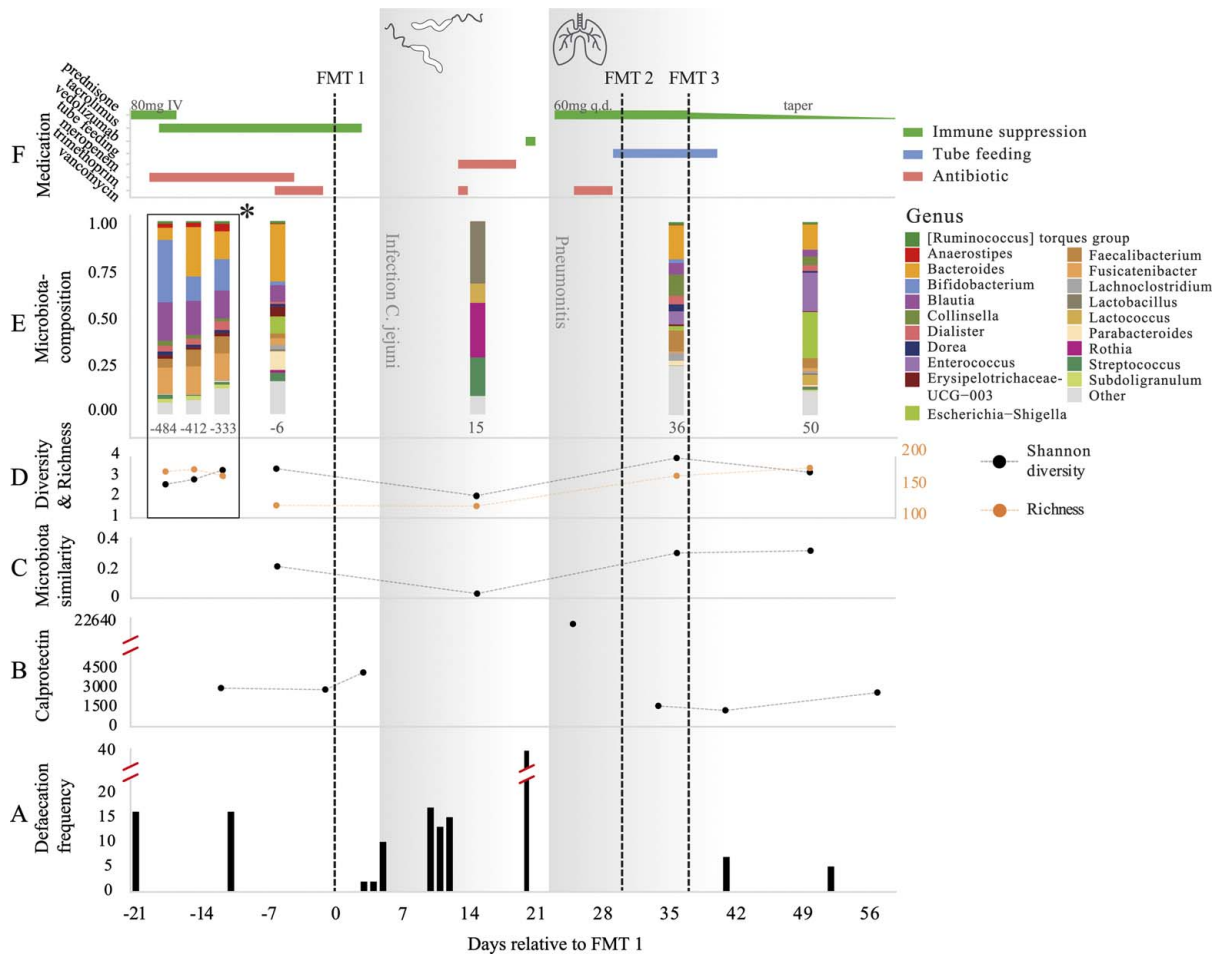
After the FMT treatments, gastrointestinal symptoms and general well-being improved and the patient was discharged from the hospital. Prednisone treatment (started due to development of pneumonitis) was decreased from q.d 60 mg to q.d 40 mg after the third FMT, and was tapered in the following weeks. Three months after the first FMT, the patient died due to progression of his lung cancer.

**DISCUSSION**

We present 2 cases of treatment-refractory IMC treated with FMT, resulting in reduced defecation frequency, tapering of immunosuppressive therapy, discharge from the hospital, and changes in gut microbiota composition, richness, and diversity. Furthermore, recovery of bacterial richness and diversity upon FMT treatment following an intercurrent *C. jejuni* infection and subsequent meropenem treatment was shown. Our results add to 3 previously published case reports of 4 cases in total, describing clinical improvement of IMC symptoms following one or multiple FMT treatments.<sup>3-5</sup>

Gut microbial richness and diversity are associated with human health. A rich and diverse microbiome is thought to reflect resilience, reduced inflammation, and colonization resistance against pathogens through complex microbe-microbe and microbe-host interactions.<sup>6</sup> Pre-FMT, we observed low bacterial richness in both patients, and varying diversity. After FMT, bacterial diversity and richness were similar to healthy donor levels in both patients. This is partly in accordance with a prior case series, where increases in richness were found after FMT, but no particular trends for diversity.<sup>3</sup> Interestingly, bacterial richness and diversity increased in patient one before FMT, shortly after broad-spectrum vancomycin pre-treatment. This could potentially be explained by vancomycin-induced loss of dominance of *Enterococcus*, leading to a more diverse overall composition.

Shortly after FMT, only patient one displayed a microbiota composition more similar to the corresponding donor, which became less apparent in later samples. The final fecal samples taken from both patients (respectively 47 and 13 days after the final FMT) did not reflect the respective donor samples well, displaying relatively high proportions of *Enterococcus* and in patient 2 also high proportions of *Escherichia-Shigella*. Nevertheless, microbiome richness and



**FIGURE 2.** Overview of clinical and microbiota data of patient 2 in the course of fecal microbiota transplantation for immune-mediated colitis. \*Donor microbiota composition and diversity; A, Defecation frequency (times/day); B, Fecal calprotectin levels (µg/g); C, Microbiota similarity to donor (1-Bray-Curtis dissimilarity); D, Microbial alpha-diversity, where Shannon diversity reflects the number and relative distribution of bacteria (operational taxonomic units (OTUs)) and richness reflects the total count of different bacteria (OTUs); E, Microbiota composition profiles, depicted as relative abundance of bacterial genera; F, Medication.

diversity still matched donor levels and gastrointestinal symptoms of the 2 patients remained improved. This indicates that (long-term) full donor microbiota engraftment may not be necessary for FMT to improve microbiome richness and diversity and to induce a clinical and meaningful effect on IMC.

Both patients demonstrated decreased relative abundance of *EscherichiaShigella* and *Streptococcus* shortly after FMT, increased relative abundance of *Collinsella* and *Faecalibacterium*, and although to a lesser extent, increase of *Paraprevotella*, *Dialister*, and *Bilophila*. Previous research has shown increased relative abundance of *Collinsella* in ICI responders.<sup>7</sup> *Faecalibacterium* is generally known for its anti-inflammatory properties,<sup>8</sup> and increased relative abundance after FMT could potentially play a role in mitigating IMC symptoms. Contradictory, in development (rather than treatment) of IMC, *Faecalibacterium* dominance may predispose patients for IMC.<sup>2</sup> Overall, linking abundances of specific bacteria to clinical outcomes is undesirable in this case report. Limitations in sample size and the use of 16S rRNA gene amplicon sequencing, not allowing for taxonomic classification to species level, provide estimates too

crude to give sufficient insight in the complex host-microbiota interactions at play.

A final important observation is that both patients developed an infection, including a lethal invasive aspergillosis in patient one. Patient 2 developed a *C. jejuni* infection shortly after the first FMT, which has been reported before in ICI-treated patients.<sup>9</sup> These infections were likely related to the prolonged and severe immunosuppressive therapy both patients received and not to FMT. Infectious diseases are a well-known complication in patients with irAEs and their subsequent immunosuppressive treatments and the presented cases exemplify once more that vigilance for infectious diseases remains very important in this patient population.<sup>10</sup>

This report adds to preliminary evidence on the value of FMT for IMC, but underlying (microbial/immunological) working mechanisms remain to be elucidated. Future studies investigating safety, clinical efficacy, and mechanism of action of FMT will allow for a better risk/benefit consideration of FMT as compared to further immunosuppressive therapy in patients suffering from refractory IMC. In our 2 patients, FMT was used as a last resort treatment, after multiple and prolonged immunosuppressive therapies.

Potentially, earlier administration of FMT in this patient group may help prevent life threatening, immunosuppressive therapy-induced infections in the future.

#### ACKNOWLEDGMENTS

The authors thank technicians Eric K. L. Berssenbrugge, Anocim R. Geelen, and Maryam el Hamdioui for FMT preparation, sample processing and DNA extraction. Furthermore, we want to thank involved members of the Study Group of the Netherlands Donor Feces Bank for their contribution in evaluating patient eligibility, facilitating FMT treatment, ensuring adequate follow-up, and occasional evaluation of the manuscript.

Involved (other) members of the Study Group of the Netherlands Donor Feces Bank:

- Emilie van Lingen, Department of Gastroenterology and Hepatology, Leiden University Medical Center (LUMC), Leiden, the Netherlands
- Rogier Ooijevaar, Department of Gastroenterology and Hepatology, Amsterdam University Medical Centers, VU University Medical Center, Amsterdam, The Netherlands
- Eline Boeije-Koppenol, Department of Medical Microbiology, LUMC, Leiden, The Netherlands
- Joffrey van Prehn, Department of Medical Microbiology, LUMC, Leiden, The Netherlands
- Hein W. Verspaget, Department of Gastroenterology and Hepatology, LUMC, Leiden, the Netherlands; Department of Biobanking, LUMC, Leiden, the Netherlands
- Ed J. Kuijper, Department of Medical Microbiology, LUMC, Leiden, The Netherlands; Reference Laboratory for *C. difficile*, LUMC and RIVM (Center for Infectious Disease Control, National Institute for Public Health and the Environment), Bilthoven, The Netherlands
- Josbert J. Keller, Department of Gastroenterology and Hepatology, LUMC, Leiden, the Netherlands, Department of Gastroenterology, Haaglanden Medical Center, Den Haag, the Netherlands

#### Conflicts of Interest/Financial Disclosures

The authors report no competing interests to declare. The Netherlands Donor Feces Bank has received an unrestricted grant from Vedanta Biosciences, Inc. (MA, USA). The funding source was not involved in study design; the collection, analysis and interpretation of data; the writing of the report; or in the decision to submit the article for publication.

#### REFERENCES

1. Dougan M, Luoma AM, Dougan SK, et al. Understanding and treating the inflammatory adverse events of cancer immunotherapy. *Cell*. 2021;184:1575–1588.
2. Chaput N, Lepage P, Coutzac C, et al. Baseline gut microbiota predicts clinical response and colitis in metastatic melanoma patients treated with ipilimumab. *Ann Oncol*. 2017;28:1368–1379.
3. Wang Y, Wiesnoski DH, Helmink BA, et al. Fecal microbiota transplantation for refractory immune checkpoint inhibitor-associated colitis. *Nat Med*. 2018;24:1804–1808.
4. Fasanello MK, Robillard KT, Boland PM, et al. Use of fecal microbial transplantation for immune checkpoint inhibitor colitis. *ACG Case Rep J*. 2020;7:e00360.
5. Dai C, Liu WX. Refractory immune checkpoint inhibitor-induced colitis improved by fecal microbiota transplantation: a case report. *Inflamm Bowel Dis*. 2022;28:e43–e44.
6. Lawley TD, Walker AW. Intestinal colonization resistance. *Immunology*. 2013;138:1–11.
7. Matson V, Fessler J, Bao R, et al. The commensal microbiome is associated with anti-PD-1 efficacy in metastatic melanoma patients. *Science*. 2018;359:104–108.
8. Sokol H, Pigneur B, Watterlot L, et al. Faecalibacterium prausnitzii is an anti-inflammatory commensal bacterium identified by gut microbiota analysis of Crohn disease patients. *Proc Natl Acad Sci*. 2008;105:16731–16736.
9. Lee KA, Shaw H, Bataille V, et al. Campylobacteriosis following immunosuppression for immune checkpoint inhibitor-related toxicity. *J Immunother Cancer*. 2020;8:e000577.
10. Del Castillo M, Romero FA, Argüello E, et al. The spectrum of serious infections among patients receiving immune checkpoint blockade for the treatment of melanoma. *Clin Infect Dis*. 2016;63:1490–1493.