

2023

Median Arcuate Ligament Syndrome: A Rare Cause of Abdominal Pain That is Difficult to Identify

Mark E. Eskander
Lake Erie College of Osteopathic Medicine, meskander123@gmail.com

Matthew Thrall
Rochester Regional Health, Matthew.Thrall@rochesterregional.org

Joel P. Thompson
Rochester Regional Health, Joel.Thompson@rochesterregional.org

Follow this and additional works at: <https://scholar.rochesterregional.org/advances>



Part of the [Medical Anatomy Commons](#), [Medical Education Commons](#), and the [Radiology Commons](#)



This work is licensed under a [Creative Commons Attribution-NonCommercial 4.0 International License](#)

Recommended Citation

Eskander ME, Thrall M, Thompson JP. Median Arcuate Ligament Syndrome: A Rare Cause of Abdominal Pain That is Difficult to Identify. *Advances in Clinical Medical Research and Healthcare Delivery*. 2023; 3(3). doi: 10.53785/2769-2779.1167.

ISSN: 2769-2779

This Imaging-Video-Audio Media is brought to you for free and open access by RocScholar. It has been accepted for inclusion in *Advances in Clinical Medical Research and Healthcare Delivery* by an authorized editor of RocScholar. For more information, please contact Advances@rochesterregional.org.

Median Arcuate Ligament Syndrome: A Rare Cause of Abdominal Pain That is Difficult to Identify

Abstract

Median arcuate ligament syndrome (MALS) is a rare disease that occurs when the celiac artery is compressed by the median arcuate ligament. Patients with MALS typically present with non-specific symptoms that overlap with more common diseases. As a result, patients may undergo extensive workup and unnecessary treatments before being properly diagnosed with MALS. In this case we present a 23-year-old female with chronic postprandial abdominal pain that persisted despite undergoing a cholecystectomy. This case highlights the symptoms and imaging findings needed to diagnose MALS and thus prevent unnecessary surgical interventions.

Keywords

Median Arcuate Ligament Syndrome, Celiac artery compression syndrome, abdominal pain, postprandial epigastric pain

Creative Commons License



This work is licensed under a [Creative Commons Attribution-NonCommercial 4.0 International License](https://creativecommons.org/licenses/by-nc/4.0/)

Conflict of Interest Statement

No conflict of interest.

IMAGING-VIDEO-AUDIO MEDIA

Median Arcuate Ligament Syndrome: A Rare Cause of Abdominal Pain That is Difficult to Identify

Mark E. Eskander ^{a*}, Matthew M. Thrall ^b, Joel P. Thompson ^b

^a Lake Erie College of Osteopathic Medicine, USA

^b Rochester Regional Health, USA

Abstract

Median arcuate ligament syndrome (MALS) is a rare disease that occurs when the celiac artery is compressed by the median arcuate ligament. Patients with MALS typically present with non-specific symptoms that overlap with more common diseases. As a result, patients may undergo extensive workup and unnecessary treatments before being properly diagnosed with MALS. In this case we present a 23-year-old female with chronic postprandial abdominal pain that persisted despite undergoing a cholecystectomy. This case highlights the symptoms and imaging findings needed to diagnose MALS and thus prevent unnecessary surgical interventions.

Keywords: Median arcuate ligament syndrome, Celiac artery compression syndrome, Abdominal pain, Postprandial epigastric pain

1. Introduction

Median arcuate ligament syndrome (MALS) is a rare disease that occurs when the celiac artery is compressed by the median arcuate ligament. It is estimated that two per 100,000 cases of non-specific abdominal pain can be attributed to MALS.¹ Patients with MALS typically present with non-specific symptoms including postprandial abdominal pain, nausea, vomiting, and/or weight loss. In this case we present a 23-year-old female with postprandial epigastric pain that persisted despite undergoing a cholecystectomy. The patient was later correctly diagnosed with and treated for MALS. This case highlights the symptoms and imaging findings needed to diagnose MALS early in a patient's disease course, and thus prevent unnecessary workup and treatments.

2. Case presentation

A 23-year-old female with a past medical history of ectopic pregnancy presented to the ED with

postprandial epigastric pain, weight loss, nausea, and vomiting for the past several months. Her symptoms were first noted after an ectopic pregnancy several months prior. Physical exam was remarkable for epigastric tenderness upon palpation without rebound or guarding. Laboratory values including liver function tests and complete metabolic panel were within normal limits. Contrast enhanced CT of the abdomen and pelvis showed no significant abnormalities. After an abnormal HIDA scan suggestive of biliary hyperkinesia, a laparoscopic cholecystectomy was performed. However, the patient continued to have chronic postprandial epigastric pain for three months after the operation, causing her to return to the ED for further evaluation. Physical exam was notable for epigastric tenderness and a faint bruit in the epigastric region. Closer examination of the patient's history, including appreciation of celiac artery stenosis on CT, led to the diagnosis of MALS. Laparoscopic release of the median arcuate ligament was performed, resulting in resolution of the patient's symptoms.

Accepted 12 May 2023.
Available online ■■■

* Corresponding author.
E-mail address: meskander123@gmail.com (M.E. Eskander).

<https://doi.org/10.53785/2769-2779.1167>
2769-2779/© 2023 Rochester Regional Health.

Table 1. Most common signs and symptoms in patients with MALS, adapted from Ho et al.⁶

Signs and Symptoms	Percentage of Patients (N = 43)
Abdominal pain	91
Postprandial	62
Unprovoked	33
Post-exertional	30
Epigastric bruit	47
Weight loss	40
Nausea	30

3. Discussion

The celiac artery normally arises from the aorta at the T12 level, just below the origin of the median arcuate ligament.¹ MALS occurs when either the median arcuate ligament arises lower than usual or if the celiac artery arises higher than usual, leading to celiac artery compression. The disease is more common in individuals with thin body habitus and in females between 30 and 50 years old.²

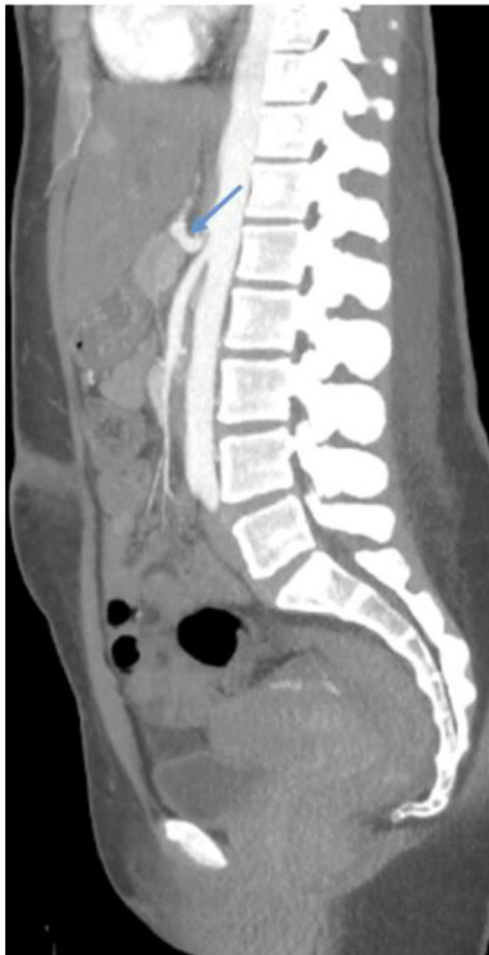

Fig. 1. Sagittal contrast enhanced CT through the abdomen and pelvis reveals the classic hooked celiac sign with post-stenotic dilation (blue arrow), indicating compression of the celiac artery.

The low incidence and nonspecific symptoms of MALS that overlap with more common diseases make it difficult to diagnose (Table 1). As a result, the diagnosis of MALS is sometimes made only after extensive workup and unnecessary treatments are performed. The classic “hooked celiac sign” created by sharp angulation of a compressed celiac artery on CT imaging is very common in patients with MALS (Fig. 1). However, this is not always recognized or appreciated as significant since many patients with this imaging finding are asymptomatic.³ Spectral Doppler ultrasound may be the best noninvasive imaging modality to assess for MALS.⁴ Findings consistent with MALS include an elevated peak systolic velocity above 350 cm/s in the proximal celiac artery due to an increase in vascular resistance from external compression (Fig. 2A and B). The elevated peak systolic velocity rises even further upon expiration as the celiac artery is further compressed due to upward movement of the diaphragm⁵ (Fig. 2B).

In this case, the patient's demographic, normal laboratory values, a narrowed celiac artery on CT,

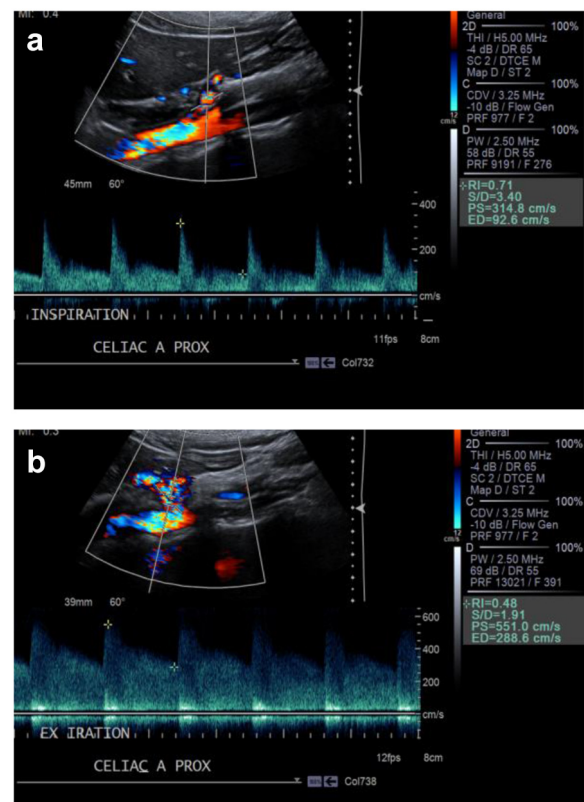


Fig. 2. a. Doppler ultrasound obtained from a different patient with MALS. Spectral waveform of the proximal celiac artery upon inspiration shows elevated PSV of 314.8 cm/s consistent with stenosis. b. Spectral waveform of the proximal celiac artery upon expiration shows PSV of 551.0 cm/s consistent with more severe stenosis.

and pain persisting despite cholecystectomy resulted in the diagnosis of MALS. Cholecystectomy could have been prevented if there was a lower threshold for suspicion of MALS as a cause of abdominal pain.

Conflict of interest

The authors report no conflict of interest.

References

1. Horton KM, Talamini MA, Fishman EK. Median arcuate ligament syndrome: evaluation with CT angiography. *Radiographics*. 2005;25(5):1177–1182. <https://doi.org/10.1148/rg.255055001>.
2. Kim EN, Lamb K, Relles D, Moudgill N, DiMuzio PJ, Eisenberg JA. Median arcuate ligament syndrome-review of this rare disease. *JAMA Surg*. 2016;151(5):471–477. <https://doi.org/10.1001/jamasurg.2016.0002>.
3. Rongies-Kosmol M, Jakimowicz T. Celiac artery compression syndrome. mini-review. *Acta Angiol*. 2015;21(1):21–24. <https://doi.org/10.5603/aa.2015.0005>.
4. Gruber H, Loizides A, Peer S, Gruber I. Ultrasound of the median arcuate ligament syndrome: a new approach to diagnosis. *Med Ultrason*. 2012;14(1):5–9.
5. Prabhakar D, Venkat D, Cooper GS. Celiac Axis compression syndrome: a syndrome of delayed diagnosis? *Gastroenterol Hepatol*. 2017;13(3):192–194.
6. Ho KKF, Walker P, Smithers BM, et al. Outcome predictors in median arcuate ligament syndrome. *J Vasc Surg*. 2017;65(6):1745–1752.