



REPORT TO PHYSICIANS

NOV./DEC. 2010 VOL. 55, NO. 11/12

Oncology

Desmoid Tumors

Multidisciplinary treatment for an enigmatic disease


By Joe Munch

Desmoid tumors are among the rarest of tumors—they occur in only 2–4 people per million per year in the United States. Although desmoids have a benign histologic appearance and lack the ability to metastasize, they can invade locally—often aggressively—and recur repeatedly. Physicians therefore face challenges in both the diagnosis and treatment of these tumors. At The University of Texas MD Anderson Cancer Center, a multidisciplinary team is working to address these challenges.

A question of malignancy

Desmoid tumors, also known as aggressive fibromatoses, are soft-tissue tumors that arise from connective tissue and typically present as a single, slowly growing mass. Most desmoids are sporadic tumors, but some occur in the setting of Gardner syndrome, a variant of familial adenomatous polyposis. Desmoids can occur anywhere in the body but generally occur in the root of the mesentery (intraabdominal desmoids), in the abdominal

(Continued on page 2)



Dr. Raphael Pollock, head of the Division of Surgical Oncology, meets with other specialists to plan treatments for patients with desmoid tumors.

Desmoid Tumors

(Continued from page 1)

wall (abdominal desmoids), and outside the abdomen, primarily in the shoulder or pelvic girdles (extraabdominal desmoids).

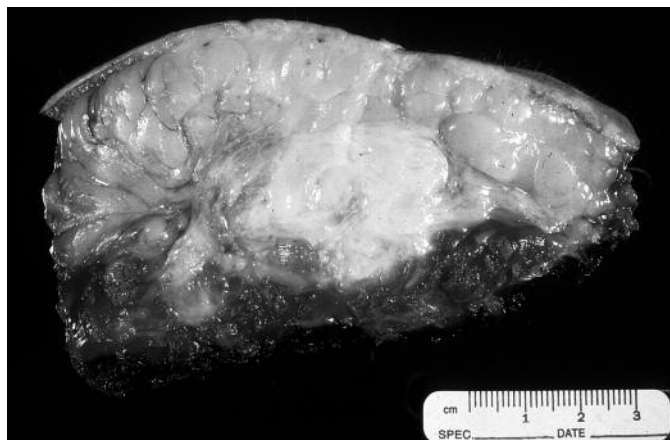
Dina Chelouche Lev, M.D., an assistant professor in the Department of Cancer Biology, said that until about a decade ago, it was unclear whether desmoids should be considered a reactive proliferation—a “scarring process that has gone wild”—or a neoplastic process. Once it was determined that desmoids could be considered neoplasms, the question became whether to classify them as benign or malignant. A universally accepted answer has not yet been established. Some oncologists, citing the tumors’ inability to metastasize, consider desmoids to be benign. But at MD Anderson Cancer Center, desmoids are viewed as a malignant disease, a designation, Dr. Lev said, that hinges on the definition of malignancy.

“Per the book, malignant cells are cells that can metastasize from the primary tumor to a different site. If that’s how you characterize malignancy, then desmoid tumors are not malignant,” Dr. Lev said. “But if you consider desmoids based on the patient outcomes—death, deformity, effects on quality of life, significant recurrences mandating hospitalization, and so forth—in my mind, I would call that a malignant disease.”

Their benign histologic appearance and lack of metastatic potential notwithstanding, desmoids can be highly infiltrative, invading along fascial planes, destroying adjacent vital structures and organs, and obstructing blood vessels and ureters. Intraabdominal desmoids, for example, can grow so large that they compress the small bowel, causing abdominal pain, changes in bowel habits, and rectal bleeding.

Treatment options

According to Raphael Pollock, M.D., Ph.D., a professor in and head of the Division of Surgical Oncology, each of the major treatment modalities—systemic therapy, radiation therapy, and surgery—plays a potential role in the treatment of desmoid tumors, and finding the right therapy or combination of therapies for each patient involves an



This typical desmoid is a firm, white-to-tan tumor with infiltrative borders.

entire team. “All desmoid cases are presented at our weekly soft tissue sarcoma planning conference so that treatment plans can be discussed by specialists in each treatment modality before we embark on any specific therapeutic approach for the patient,” Dr. Pollock said. “What comes out of the conference is a truly integrated multidisciplinary approach that represents our best collective thinking.”

Surgery, the mainstay of therapy for most desmoid tumors, is performed with the goal of obtaining tumor-free—negative—margins while preserving functionality. However, obtaining negative margins can be difficult.

“Desmoids tend to be very infiltrative on a microscopic level,” Dr. Pollock said, “and a surgeon can be fooled into thinking that there is an adequate margin of resection when in fact there might be microscopic disease that’s just penetrated up to the edge of the resected specimen.” Positive surgical margins increase the risk of recurrent disease; if the desmoid recurs, repeat surgeries may lead to excessive scarring or even amputation in some patients. For this and other reasons, the role of surgery in some patients with desmoid tumors is being reevaluated.

“Rather than performing an operation that could damage the patient’s quality of life, we would try to use other types of treatments prior to surgery in the hope that we could avoid such a quality-of-life-defining situation,” Dr. Pollock said.

The natural history of desmoids varies from patient to patient: some desmoids grow unceasingly; others grow, stop growing, and then start growing again; still others grow and then regress without intervention. Because the tumors cannot metastasize, there may be a role for observing the patient if the lesion is not causing functional difficulty. And if the

lesion is causing functional difficulty, there may be a role for nonsurgical therapy before surgery is considered. For example, in patients in whom surgical resection is not feasible, radiation therapy can be given as the definitive therapy.

“We can give radiation therapy as the sole treatment modality and expect to achieve local control in 75% of patients, which is similar to the control rate for surgical patients,” said Ashleigh Guadagnolo, M.D., M.P.H., an assistant professor in the Department of Radiation Oncology. “For instance, we would give radiation therapy to treat a desmoid in the neck, where it would be difficult to take out the tumor with negative margins, or to treat a desmoid deep in the low pelvis, which would require a full pelvic exenteration to extirpate the tumor.”

In rare cases, radiation therapy is given to shrink a tumor prior to surgery; more often, radiation therapy is administered after surgery to reduce the risk of recurrence in patients with positive surgical margins. Although desmoids are sensitive to radiation, the tumors’ slow cell cycle ensures that the effects of radiation therapy will not be seen until 6–8 months after treatment, with tumors continuing to shrink for years in some cases.

Good imaging and avoidance of critical structures are always important in delivering radiation therapy, Dr. Guadagnolo said. She added, “Radiation therapy for desmoid tumors needs to be done by someone who is familiar with

the disease because it's a rare tumor with distinctive behavior and potential to be locally aggressive."

Medical treatment usually comes to the forefront when surgery and radiation cannot be used or have failed. Occasionally, however, systemic therapy is given before surgery to shrink large, potentially resectable desmoids that would otherwise incur excessive surgery-related morbidity in patients for whom radiation therapy would be inappropriate—for example, in patients with a desmoid deep in the pelvis or abdomen, sites prone to high radiation toxicity.

Medical therapy for desmoids usually involves individualized combinations of antihormone agents, typically tamoxifen or raloxifene; nonsteroidal anti-inflammatory drugs such as ibuprofen or naproxen; targeted chemotherapy with imatinib mesylate; and/or traditional cytotoxic chemotherapy.

"The major question in treating patients with desmoids is, how urgently do you need a response to therapy? If the tumor is not causing significant morbidity, then we'll take a very conservative approach," said Robert Benjamin, M.D., a professor in and chair of the Department of Sarcoma Medical Oncology. "But if we need a response to therapy right away, then we'll give more intensive chemotherapy to start with, typically doxorubicin and dacarbazine."

Although it is generally avoided because of its high toxicity, cytotoxic chemotherapy has a surprisingly high rate of success in treating desmoids.

"Desmoids can be considered very-low-grade sarcomas. Conventional wisdom would indicate that such tumors would not respond to chemotherapy at all, but that is anything but the case," Dr. Benjamin said. "Chemotherapy that is effective in treating high-grade sarcomas is also effective in treating desmoids, particularly those associated with Gardner syndrome, and that's not something I think anyone would have predicted."

Owing to this team approach, the rate of recurrence in desmoid patients treated at MD Anderson is less than 20%, which is on the low side of the 20%–40% rates reported in the literature, even though most desmoid patients

“The major question in treating patients with desmoids is, how urgently do you need a response to therapy?”

– Dr. Robert Benjamin

referred to MD Anderson have already undergone surgery and experienced a recurrence necessitating a more aggressive approach to therapy.

Exploring new pathways

Desmoid tumors are difficult to diagnose for several reasons. Because desmoids can arise anywhere in the body, their location does not provide any clues to their identity. In addition, the type of cell from which desmoids arise is unknown. Most confounding, especially in the setting of suspected recurrent disease, is desmoids' resemblance to scar tissue, which effectively eliminates frozen-section analysis as a method for evaluating the surgical margins of resected desmoids. And because virtually any mass that grows will have a rind of fibrosis that looks like scar tissue and has features of a desmoid, it is sometimes unclear whether a mass biopsied to establish or confirm additional disease in the setting of desmoid fibromatosis was inadequately biopsied (i.e., the fibrous rind surrounding the mass, not the mass itself, was biopsied) or is in fact a desmoid.

Investigating the molecular mechanisms underlying desmoid tumors may provide better ways to identify and treat the disease. About 85% of sporadic desmoids (i.e., desmoids not associated with Gardner syndrome) harbor mutations of the *CTNNB1* gene encoding β -catenin, a cell adhesion cofactor and nuclear signaling factor that is part of the Wnt signaling pathway. The dysregulation of the Wnt pathway is implicated in the tumorigenesis of a number of cancers.

Seeking to confirm these findings, Dr. Lev, along with Dr. Pollock and Alexander Lazar, M.D., Ph.D., an associ-

ate professor in the Department of Pathology, and other MD Anderson researchers, began sequencing desmoids for β -catenin mutations and identified three specific mutations in two different codons of *CTNNB1*. The researchers then looked for correlations between specific mutations and clinical outcomes.

"To our surprise, we found that tumors that had one particular mutation, S45F, showed a remarkable propensity to recur very rapidly," Dr. Lazar said. "If this finding can be corroborated, β -catenin sequencing can be a prognostic tool. There are more and less aggressive ways to treat desmoids, so if we know that a patient has a particular mutation associated with more aggressive disease, we may make different decisions in terms of whether to suggest surgery, radiation, or other treatments."

Dr. Lev and her colleagues are working to validate the study's findings, which have already proven valuable in definitively diagnosing desmoid tumors in some patients. Dr. Lazar said, "If we're not sure whether a case is a desmoid tumor but can demonstrate a characteristic *CTNNB1* mutation in it, we can be highly confident that it is in fact a desmoid."

Desmoids do not become genetically complex; that is, they do not seem to acquire more mutations with time.

"This suggests to me that β -catenin is the only thing, or the major thing, that is disrupted in the tumor," Dr. Lev said. "Once we find a way to manipulate this pathway, we can find more effective treatments for these tumors."

For the time being, Dr. Lazar said, "The team approach we take to treating patients with desmoids—the pathological analysis to get the right diagnosis, genotyping, and involving surgeons, radiation oncologists, and medical oncologists—appears to make a real difference in how well these patients do." ●

For more information, contact Dr. Benjamin at 713-792-3626, Dr. Guadagnolo at 713-563-8400, Dr. Lazar at 713-563-1843, Dr. Lev at 713-792-1637, or Dr. Pollock at 713-792-6928.

Endoscopic Surgery for Skull Base Tumors

Patient selection is the key to success for the minimally invasive procedure

By Bryan Tutt

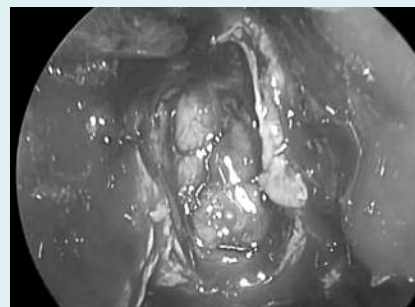
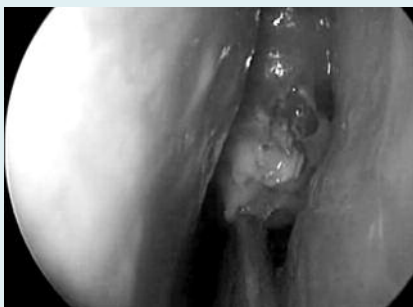Surgery for skull base tumors results in a cure for many patients. For most of these patients, traditional open craniofacial surgery is the safest approach with the best chance of success. In recent years, however, endoscopy-assisted surgery, which leaves no visible scars, has been found to be effective for the resection of some skull base tumors.

Benign or malignant tumors of various types—including squamous cell carcinoma, melanoma, adenocarcinoma, sarcoma, olfactory neuroblastoma, and others—may originate from or extend into the skull base. Chemotherapy and/or radiation can be used to effectively treat some malignant skull base tumors, and many benign skull base tumors require observation only. However, most malignant skull base tumors and any benign tumors that threaten vital structures must be removed surgically.

Traditional open surgery for skull base tumors may require facial and scalp incisions and movement of the facial bones or part of the cranium. In contrast, during endoscopy-assisted surgery, the endoscope and surgical instruments are inserted through the nose and approach the skull base tumor from below, without the need for incisions.

The endoscopic procedure

When surgeons prepare for an endoscopic procedure, they also make a plan for an open procedure to be used if tumor-free margins or adequate skull base reconstruction cannot be achieved using the endoscopic procedure. “We always tell the patient that we will be ready to switch to open surgery and use time-honored surgical techniques if endoscopic surgery is not able to achieve



Intraoperative endoscopic images show a tumor before its complete removal through the nose (left) and a view of the skull base and exposed brain after complete endoscopic tumor resection (right).

the ultimate goal, which is to cure the patient of his or her cancer,” explained Ehab Hanna, M.D., a professor in the Department of Head and Neck Surgery at MD Anderson Cancer Center.

In the operating room, images obtained earlier by computed tomography or magnetic resonance imaging are loaded into a computer-based image guidance system. Surgeons use an infrared sensor to point to anatomic landmarks, such as the nose or right eye, on both the patient and the image. The image guidance system then correlates these locations on the image, or map, to be displayed during surgery. “During surgery, this is used to query and find our exact location, much like a surgical GPS,” Dr. Hanna said.

The surgeons begin the procedure by introducing the endoscope through a natural opening, usually a nostril. This allows access to the skull base without retracting critical structures such as the brain. For tumor resection, various instruments can be introduced alongside the endoscope. For example, surgeons may use a high-speed debriider, adapted from arthroscopic technology, to debulk the tumor and to expose the tumor’s point of attachment. One surgeon uses the instruments while the other manipulates the endoscope to ensure adequate visualization.

The roles of the neurosurgeon and the head and neck surgeon are complementary. “When the tumor is in the intracranial cavity, it is primarily the neurosurgeon operating and the head

and neck surgeon providing the view with the endoscope,” said Nicholas Levine, M.D., an assistant professor in the Department of Neurosurgery. “But when the tumor is primarily in the sinus, the neurosurgeon may use the endoscope, freeing the head and neck surgeon’s hands to operate the instruments.”

“It’s important that the neurosurgeon and I are on the same page,” added Michael Kupferman, M.D., an assistant professor in the Department of Head and Neck Surgery. “If the neurosurgeon is resecting the tumor, I have to know where he’s going so I can provide proper visualization to facilitate the resection.”

Once the surgeons are satisfied that they have removed the tumor with clear margins, tissue grafts harvested from other parts of the patient’s body are used for a multilayered reconstruction of the skull base. The tissues are packed into place and held together with tissue glue. The inability to suture the dural membrane is an important limitation of the endoscopic approach, and as a result, the approach’s most common complication is spinal fluid leakage, which carries the risk of meningitis.

To minimize the risk of spinal fluid leakage, the patient may be kept on bed rest for 1–2 days following surgery. A typical hospital stay for a patient after an endoscopic procedure is 2–3 days.

Patient selection

Although the number and types of tumors that can be removed using the en-

doscopy approach have increased dramatically over the past decade, less than half of skull base tumor resections can be performed using the endoscopic approach.

“The key to success in endoscopic surgery is selecting it for the right patient,” said Dr. Hanna. The choice of surgical technique is determined by the ability to meet the primary treatment goals—negative surgical margins, protection of critical neurovascular structures, and reconstruction of the skull base. Patients with tumors that invade the skull base without massive invasion of the brain are the best suited candidates for the endoscopic approach.

“Usually, if a tumor can be approached endoscopically, it can also be approached through an open procedure,” Dr. Levine said. “In that case, the choice of surgical approach is largely a matter of which procedure gives us better visualization. When we do an open procedure, we use an operating microscope. The microscope gives us three-dimensional visualization but less illumination than the endoscope, which is brighter but two dimensional.”

Dr. Kupferman added that the surgi-

cal microscope offers only direct line-of-sight visualization, while the endoscope allows the surgeon to see around corners.

“The critical issue is what happens at the end of the visualization path using either the microscope or the endoscope,” said Franco DeMonte, M.D., a professor in the Department of Neurosurgery. “Philosophically, it’s nice to think that it’s better to go in through the nose without making the incisions required for an open procedure. But the risk is not the incision; the risk is associated with the critical structures in the region where you’re operating.” For example, some skull base tumors cannot be removed endoscopically without destroying much of the sinus anatomy; an open procedure would result in less morbidity for patients with such tumors.

At MD Anderson Cancer Center, treatment decisions for patients with skull base tumors are made by a multidisciplinary team of surgeons, radiation oncologists, and medical oncologists who meet each week at an in-house head and neck tumor conference. “Skull base tumor pathologies are

diverse,” Dr. Levine said, “and they need to be evaluated using a team approach.”

The pathologic type of the skull base tumor is the most important factor influencing treatment decisions. “There’s no cookie-cutter approach,” Dr. Hanna said. “Gamma knife, radiosurgery, proton therapy, intensity-modulated radiation therapy, chemotherapy—we have the full gamut of therapies available to complement, precede, or replace surgery.”

Another therapy that may one day be available to treat skull base tumors is robotic surgery. In 2007, surgeons at MD Anderson conducted a proof-of-concept study showing that the da Vinci Surgical System, a robotic system already in use for laparoscopic surgery, could be used for the endoscopic removal of skull base tumors. However, Dr. Hanna said that smaller, more precise instruments must be developed before the robot can be used for skull base surgery.

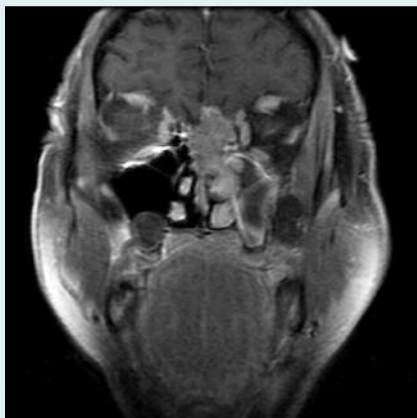
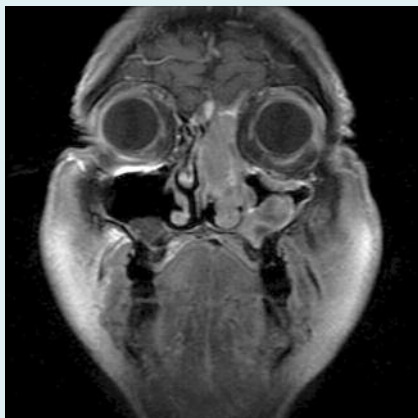
The da Vinci system, when and if it is ready for clinical use to treat skull base tumors, will offer three-dimensional binocular visualization and the ability to endoscopically suture the dural covering of the skull base. These advantages over existing endoscopic techniques might make endoscopic surgery an option for more patients.

The importance of careful patient selection was substantiated by a 2009 retrospective study of sinonasal and skull base malignancies removed by endoscopic surgery at MD Anderson. It was the largest U.S. study of such tumors, and the researchers found no difference in survival rates between well-selected patients whose tumors were removed endoscopically and patients who underwent craniotomy. For all patients in the study, 5-year and 10-year disease-specific survival rates were 87% and 80%, respectively.

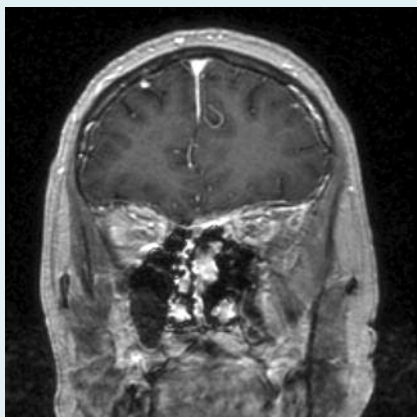
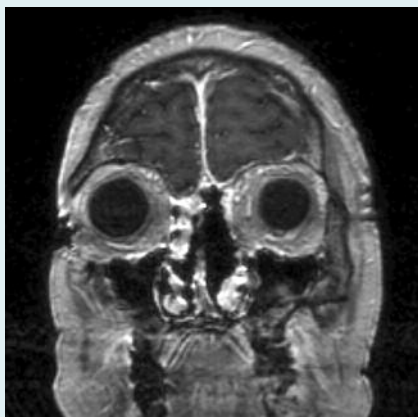Dr. DeMonte said the consistent survival rates reflect a commitment to using whichever technique provides the highest degree of resection.

“Endoscopic surgery is an option, but it is not the only option,” Dr. Levine said. “The overall evaluation of the patient dictates the kind of treatment the patient needs.” ●

For more information, contact Dr. Hanna at 713-745-1815, Dr. DeMonte at 713-563-8705, Dr. Levine at 713-563-8706, or Dr. Kupferman at 713-794-1910.



Magnetic resonance images show a skull base malignancy involving the left nasal cavity, ethmoid sinus, and septum (above). No evidence of recurrence was seen in the same patient 1 year after endoscopic surgery and radiation therapy (below).



Earlier Breast Cancer Screening Recommended for Hispanic Women

Women of Mexican origin should be considered at high risk for early-onset, premenopausal breast cancer, according to researchers at The University of Texas MD Anderson Cancer Center.

The researchers surveyed 714 Hispanic women in the Houston area who were drawn from an ongoing, population-based cohort study. One hundred nineteen of these women reported having been diagnosed with breast cancer, and 50% of these had been diagnosed before age 50 years.

The U.S. Preventive Services Task Force guidelines were revised in 2009 to recommend that breast cancer screening, including mammograms, begin at age 50 years for the general population. These guidelines have been controversial, and MD Anderson continues to recommend screening beginning at age 40 years for women at average risk or at a younger age for women with certain risk factors.

“If a one-size-fits-all screening program is implemented as the task force recommends, we fear a large number of breast cancer cases won’t be picked up at an early stage, especially with the growth of the Hispanic population in this country,” said Melissa Bondy, Ph.D., a professor in the Department of Epidemiology and the senior author of the study’s report in the journal *Cancer*.

“We fear a large number of breast cancer cases won’t be picked up at an early stage.”

— Dr. Melissa Bondy

A multivariate analysis of the women’s survey responses revealed that the strongest risk factors for breast cancer were a family history of the disease, level of acculturation, and having been born in Mexico. The researchers noted that the level of acculturation was

based on whether the participants mostly spoke English, which is one aspect of an acculturation process that includes other lifestyle changes that might affect breast cancer risk. Other breast cancer risk factors found by the analysis included being single and being without health insurance.

The researchers wrote that their results—along with those of previous studies showing that Hispanic women are more likely to be diagnosed with an advanced stage of breast cancer and more likely to die of breast cancer than are non-Hispanic white women—demonstrate the need for policies that target screening, education, and treatment in the Hispanic population. ●

SUMO Is Important for DNA Damage Repair

The small protein SUMO (small ubiquitin-related modifier) is an important component in the mechanism that repairs DNA damage caused by chemotherapy in cancer cells, according to a new study done by a research team at MD Anderson Cancer Center.

In the study led by Edward T. H. Yeh, M.D., a professor in and chair of the Department of Cardiology, investigators determined how SUMO modification alters the activity of RPA70, a component of the replication protein A (RPA) complex that protects and maintains DNA.

In the August 13 issue of *Molecular Cell*, the investigators showed that the modification of RPA70 by SUMO is essential to repair DNA double-strand breaks. These breaks in DNA are one of the ways that ionizing radiation and chemotherapeutic drugs like camptothecin kill cancer cells.

In undamaged cells, RPA70 is accompanied by a protein called SENP6 that prevents SUMO modifications. Upon DNA damage, RPA70 leaves this inhibitory partner and begins to accumulate SUMO. This SUMO modification allows RPA70 to initiate DNA damage repair.

To understand the interaction be-

tween RPA70 and SUMO, researchers modified RPA70 to eliminate its SUMO conjugation sites. Dr. Yeh said, “If a mutant protein that cannot be modified by SUMO is substituted for RPA70, the cells are much more sensitive to chemotherapy and ionizing radiation.”

Without SUMO modification, RPA70 has difficulty initiating DNA repair. This mechanism could be particularly important in cancers that resist standard treatments. Understanding the role of SUMO and RPA70 in cancer cells may offer new therapeutic targets. ●

Regional Care Centers Make Cancer Treatment Easily Accessible

In an effort to make cancer care easily accessible to patients, MD Anderson Cancer Center now provides treatment at six regional care facilities in the greater Houston area in addition to its main campus in the Texas Medical Center.

Peter Pisters, M.D., who serves as medical director of the regional care centers and as a professor in the Department of Surgical Oncology, said the goals of the regional care center initiative are to increase the convenience and accessibility of cancer treatment for patients while maintaining the same level of quality as MD Anderson’s facilities in the Texas Medical Center. “We’re offering laboratory and medical oncology services, radiotherapy, and—soon—surgical services,” he said.

At the regional care facilities, patients receive treatment from MD Anderson faculty physicians who work directly with referring physicians to tailor individual patients’ treatment plans.

These regional care facilities include multidisciplinary clinics in the Bay Area, Sugar Land, Katy, and the Woodlands and radiation treatment centers in Richmond and Bellaire. MD Anderson also has domestic and international radiation treatment facilities in Albuquerque, New Mexico, and in Istanbul, Turkey. ●



Books Provide Comfort, Guidance, Relaxation

A recent survey of cancer survivors from the Anderson Network, MD Anderson's patient support program, asked what inspirational, comforting, or helpful books they would recommend for someone facing a serious illness.

More than 100 members responded, citing their favorite spiritual books, biographies of cancer survivors, books that diverted them and made them laugh, and books that gave them information about their disease or helped them cope better.

The book most often cited was the Bible. Many respondents said it provided guidance, inspiration, faith, hope, peace, and strength.

The second most often mentioned book was Lance Armstrong's *It's Not About the Bike*. One man wrote, "As I was facing surgery, the book gave me hope that I was going to handle all the challenges ahead—and I did." Another cancer survivor described the book as a "lifeline to me [that] made me believe in my recovery."

Another favorite author was Bernie S. Siegel. Several respondents found his books funny, comforting, hopeful, and encouraging. Siegel's *Love, Medicine, and Miracles* was described by one survivor as "a demonstration of the power of the human spirit and its ability to heal the body." Another popular book by Siegel was *How to Live Between Office Visits*.

Guidance

Many people said reading books about cancer helped them. Numerous respondents mentioned *Dr. Susan Love's Breast Book* by Susan M. Love, *Anti-Cancer* by David Servan-Schreiber, and three books published by the Bloch Cancer Foundation. *Dr. Susan Love's Breast Book* was described as an easy-to-read, understandable reference for questions related to breast cancer and as "a manual that explained everything I went through and made me less afraid." One network member wrote that *Anti-Cancer* provided "good ideas on how to fight cancer with food and supplements and how to keep one's spirits positive and strong while dealing with cancer."

One member recommended all three Bloch Cancer Foundation books: *Fighting Cancer*, *Cancer—There's Hope*, and *Guide for Cancer Supporters*. "Working as a volunteer on the Anderson Network hotline, I hear from many, many people how much those books helped them and their families," she wrote. "The books have given people hope when they only found pessimism and negativity from others."

Comfort

Several respondents recommended books on meditation they found helpful, including *Wherever You Go There You Are* by Jon Kabat-Zinn and *The Relaxation Response* by Herbert Benson and Miriam Z. Klipper. Others wrote that they benefited from self-help books such as *Loving What Is: Four Questions That Can Change Your Life* by Byron Katie and Stephen Mitchell, *You Can Heal Your Life* by Louise L. Hay, *The Secret* by Rhonda Byrne, *The Gift of Change* by Marianne Williamson, and *The Power of Positive Thinking* by Norman Vincent Peale. *Man's Search for Meaning* by Viktor E. Frankl also was praised.

Among the books that made network members feel better were several *Chicken Soup for the Soul* books by Jack Canfield and Mark Victor Hansen, *There's No Place Like Hope* by Vickie Girard, and *Cancer Has Its Privileges: Stories of Hope and Laughter* by Christine Clifford.

A favorite book, *The Last Lecture* by Randy Pausch and Jeffrey Zaslow, was mentioned by several respondents, one of whom described it as "very inspiring, giving one hope until the end." Others cited *Talking About Death* by Virginia Morris, *On Death and Dying* by Elisabeth Kübler-Ross, and *How We Die* by Sherwin B. Nuland.

Relaxation

Many people recommended books



having nothing to do with illness or cancer. One found refuge from her illness in "the wonderfully imaginative and cleverly written Harry Potter adventures." Another enjoyed finally reading "the classic books I never read in school: Dickens, Swift, Tolstoy." Others found respite and distraction in reading mystery novels, Jane Austen novels, poetry, books about their hobbies, Erma Bombeck books and "anything that made me laugh," or "the very funny Discworld books by Terry Pratchett." A network member from Minnesota loved *Oddball Texas* by Jerome Pohlen.

One network member wrote, "I wanted to read exciting Dan Brown books (*The Da Vinci Code*) or get lost in a good western (Larry McMurtry's *Lonesome Dove*), or start on those classic novels I'd always wanted to read (*Huckleberry Finn*, *The Picture of Dorian Gray*, *Wuthering Heights*)." One woman found inspiration in the novel *Bel Canto* by Ann Patchett, which showed her that "even in a terrible situation, potential will flower." ●

Be sure to consult your physician before making any diet or treatment changes based on your reading.

The Anderson Network is MD Anderson Cancer Center's support group of more than 1,700 current and former cancer patients. Their patient and caregiver support line is 800-345-6324.

OncoLog, November/December 2010
K. Stuyck

ADDRESS SERVICE REQUESTED

IN BRIEF

SIK2 Plays Critical Role in Chemotherapy Resistance

Salt-inducible kinase 2 (SIK2) is important for cell division and may control chemotherapy response in some ovarian cancers, according to research conducted at The University of Texas MD Anderson Cancer Center. Although many ovarian cancers respond to taxane-based chemotherapy, others do not respond for reasons that are poorly understood.

Robert C. Bast, Jr., M.D., vice president of translational research at MD Anderson and the senior author of the study's report, has been searching for new ways to enhance chemotherapy sensitivity in tumors. "In our search for proteins that are responsible for that sensitivity, we found that SIK2 was required for cell division and that its inhibition offers a novel approach to improving chemotherapy for ovarian cancer," Dr. Bast said.

In the report published in the August issue of *Cancer Cell*, Dr. Bast and Ahmed Ashour Ahmed, M.D., Ph.D., a former postdoctoral fellow in Dr. Bast's lab and now a faculty member at Oxford University, conducted a large siRNA screen to identify proteins that can alter sensitivity to the taxane paclitaxel. The researchers identified SIK2 as a taxane resistance factor. Generally, taxanes kill cancer cells by inhibiting mitosis.

During normal cell division, centro-

somes move to opposite ends of the cell and serve as anchor points for microtubules. These microtubules then pull chromosomes into each daughter cell. Closer analysis revealed that SIK2 controls this process. Since taxanes inhibit mitosis by affecting microtubule function, this finding agrees with the theory that SIK2 is a taxane resistance factor. Previously, SIK2 was known primarily as a modulator of glucose metabolism during recovery from starvation.

The researchers identified SIK2 as a taxane resistance factor.

Besides offering the possibility of improving the response of some cancers to taxanes, these findings add to the emerging body of evidence that cancer cell metabolism and mitosis functions are coupled.

An understanding of this coupling may provide many new targets for cancer therapeutics. SIK2 is overexpressed in approximately 30% of ovarian cancers and is associated with a poor prognosis. Reducing SIK2 protein enhances paclitaxel's antitumor activity in cell culture and in xenografts. The next step is to develop SIK2 inhibitors for laboratory studies of ovarian cancer therapy. ●

OncoLog

The University of Texas
MD Anderson Cancer Center

President

John Mendelsohn, M.D.

Provost and Executive Vice President

Raymond DuBois, M.D., Ph.D.

Senior Vice President for Academic Affairs

Stephen P. Tomasovic, Ph.D.

Director, Department of Scientific Publications

Walter J. Pagel

Managing Editor

Bryan Tutt

Assistant Managing Editor

Joe Munch

Contributing Editors

Melissa G. Burkett Lionel Santibañez
Zach Bohannon Karen Stuyck
Ann M. Sutton

Design

Janice Campbell, The Very Idea®

Photography

Barry Smith

Editorial Board

Michael Fisch, M.D., Chair
Lyle Green, Vice Chair
Therese Bevers, M.D.
Robert Gagel, M.D.
Beverly Handy, M.D.
Patrick Hwu, M.D.
Charles Koller, M.D.
Shreyaskumar Patel, M.D.
David Schwartz, M.D.
Rena Sellin, M.D.
Randal Weber, M.D.
Christopher Wood, M.D.

Physicians: To refer a patient or learn more about MD Anderson, please contact the Office of Physician Relations at 713-792-2202, 1-800-252-0502, or www.physicianrelations.org.

Patients: To refer yourself to MD Anderson or learn more about our services, please call 1-877-632-6789 or visit www.mdanderson.org.

For questions or comments about *OncoLog*, please e-mail scientificpublications@mdanderson.org or call 713-792-3305. Current and previous issues are available online in English and Spanish at www.mdanderson.org/oncolog.

Made possible in part by a gift from the late Mrs. Harry C. Weiss.



A Comprehensive Cancer
Center Designated by the
National Cancer Institute