

DOI: <https://doi.org/10.46502/issn.2710-995X/2023.9.02>

Cómo citar:

Pérez Arias, Y., Mora Tassé, Y., & Fong Lores, O. (2023). Crystal violet in the histochemical diagnosis of *Helicobacter pylori*. *Orange Journal*, 5(9), 16-22. <https://doi.org/10.46502/issn.2710-995X/2023.9.02>

## Crystal violet in the histochemical diagnosis of *Helicobacter pylori*

### El Cristal violeta en el diagnóstico histoquímico del *Helicobacter pylori*

Recibido: 21 de abril de 2023      Aceptado: 5 de mayo de 2023

Escrito por:

**Yadira Pérez Arias<sup>1</sup>**<https://orcid.org/0000-0005-0509-9331>**Yoandra Mora Tassé<sup>2</sup>**<https://orcid.org/0000-0001-8544-1501>**Onel Fong Lores<sup>3</sup>**<https://orcid.org/0000-0001-8595-3107>

#### Abstract

*Helicobacter pylori* infection is the main causative agent of gastric cancer worldwide. With the objective of evaluating the effectiveness of the use of the histochemical technique of Crystal violet in the determination of *H. pylori* in stomach biopsies, a retrospective study of technological development was carried out in the Pathological Anatomy departments of the General Hospital "Dr. Juan Bruno Zayas Alfonso" and TOXIMED, using samples obtained in the period from January to December 2018 from patients with a gastric biopsy with positive *H. pylori* by the Giemsa method, treated at the Gastroenterology Clinic of the General Hospital "Dr. Juan Bruno Zayas Alfonso". In the investigation, the value of Sensitivity, Specificity, Positive and Negative Predictive Value of the Crystal violet technique and the Accuracy corresponded to 1. The results obtained with the Crystal violet technique, in comparison with the Giemsa technique, have shown that this diagnostic test It has similar accuracy and feasibility parameters, so it can be used as an alternative diagnostic method.

**Key words:** *Helicobacter Pylori*, histochemistry, Crystal violet stain, Giemsa stain.

#### Resumen

La infección por *Helicobacter pylori* es el principal agente causal de cáncer gástrico a nivel mundial. Con el objetivo de evaluar la efectividad del uso de la técnica histoquímica del Cristal violeta en la determinación del *H. pylori* en biopsias de estómago se realizó un estudio retrospectivo, de desarrollo tecnológico, en los departamentos de Anatomía Patológica del Hospital General "Dr. Juan Bruno Zayas Alfonso" y de TOXIMED, utilizando muestras obtenidas en el período comprendido de enero a diciembre del 2018 procedentes de pacientes con biopsia gástrica con *H. pylori* positivo por el método de Giemsa, atendidos en la Consulta de Gastroenterología del Hospital General "Dr. Juan Bruno Zayas Alfonso". En la investigación el valor de Sensibilidad, Especificidad, Valor Predictivo Positivo y Negativo de la técnica Cristal violeta y la Exactitud correspondió a 1. Los resultados obtenidos con la técnica de Cristal violeta, en comparación con la de Giemsa, han mostrado que esta prueba diagnóstica posee similares parámetros de exactitud y factibilidad, por lo que puede ser empleada como método diagnóstico alternativo.

**Palabras claves:** *Helicobacter pylori*, histoquímica, tinción con Cristal violeta, tinción con Giemsa.

<sup>1</sup> Licenciada en Tecnología de la Salud en Citohistopatología. Máster en Medios Diagnóstico. Centro de Toxicología y Biomedicina (TOXIMED) de la Universidad de Ciencias Médicas de Santiago de Cuba, Cuba.

<sup>2</sup> Licenciada en Tecnología de la Salud en Citohistopatología. Máster en Medios Diagnóstico. Centro de Toxicología y Biomedicina (TOXIMED) de la Universidad de Ciencias Médicas de Santiago de Cuba, Cuba.

<sup>3</sup> Licenciado en Bioquímica. Centro de Toxicología y Biomedicina (TOXIMED) de la Universidad de Ciencias Médicas de Santiago de Cuba, Cuba.

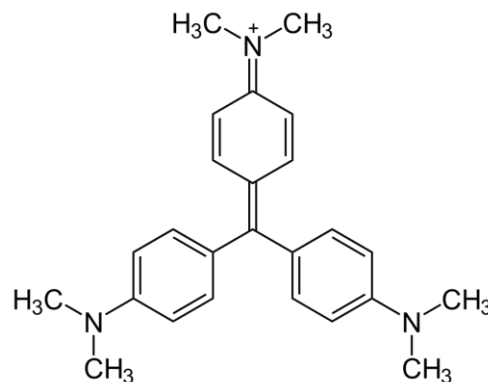


## Introduction

Histochemical tests are essential for the diagnosis of certain infections, such is the case of *Helicobacter pylori*, a bacterium that affects 60% of the world population, reaching 80% in less developed countries. *H. pylori* is currently the only bacterium with a proven carcinogenic action, and it has been estimated that each year it produces around one million deaths from ulcers, cancer and other digestive pathologies (Lee, Dore & Graham, 2022). In Cuba, there are few studies on the prevalence of *H. pylori*, with infection rates between 30% and 80% in patients with gastric disorders. In terms of morbidity and mortality, the gastroduodenal disease caused by this bacterium represents a health problem in the country, with 301 deaths from digestive ulcers being reported in 2008 and a mortality rate from gastric cancer of 7.4 per 100,000 inhabitants (Valdés, Rodríguez, Reyes & Pérez, 2020).

The study of chronic gastritis is essentially histological and represents the definitive diagnosis in most gastric conditions. The simple rate of *H. pylori* infection, the degree of inflammation of the mucosa, the presence of ulcerations, and the existence of pre-malignant lesions and malignant neoplasms can be determined using simple techniques at a moderate cost (Amuri & Al-Nuaimy, 2022).

Crystal violet, a triami-notriphenyl or rosaniline methane, is a basic dye with a strong affinity for nuclear chromatin and other strong anionic groups along with an iodine mordant. This dye stains bacteria blue / black due to its affinity for peptidoglycan in the bacterial wall (Nilles, Weiss & Theile, 2022).



**Figure 1.** Chemical structure of Crystal violet.

In Cuba, the diagnosis of *H. pylori* in Pathological Anatomy laboratories is only performed on stomach biopsy samples by the Giemsa histochemical method, so it is necessary to have alternative procedures for its diagnosis. Preliminary results with Crystal violet have shown its efficacy in the histochemical diagnosis of various pathologies, so in this research we set out to evaluate the use of the Crystal violet histochemical technique in the determination of *H. pylori* in stomach biopsies, taking into account that the laboratory procedure is very similar, being even simpler and less expensive than Giemsa staining, since it uses fewer steps in the analytical procedure and less amount of chemical reagents.

## Theoretical framework

*Helicobacter pylori* is a short spiral bacillus in the form of an "S", multiflagellate (4-6 flagella) which makes it highly mobile. It measures 2.5-5.0 µm long by 0.5-1.0 µm wide. It is a slow growing microorganism, it takes 5 to 7 days to see the colonies. This bacterium has the ability to appear in both coccoid and spiral forms, the latter being the most common morphology. *H. pylori* literally "pierces" and colonizes the nonacid-secreting mucosa of the stomach and upper intestinal tract, including the duodenum. It is the only known organism that can survive in an extremely acidic environment by weakening the mucosal lining, which allows the acid to affect the sensitive surface beneath the lining, irritating it and causing ulcers (Denic, Touati & De Reuse, 2020). The bacterium is also implicated in the pathogenesis of non-atrophic gastritis, in which the mucosa is thinned and the characteristic glands may be replaced by



pyloric glands (pyloric metaplasia); atrophic multifocal gastritis, which affects several regions of the gastric body in the form of numerous scattered foci and in extensive cases causes achlorhydria and the risk of developing gastric cancer and gastric lymphoma (Öztekin, Yilmaz, Ağagündüz & Capasso, 2021).

**Histochemistry** is the application of chemical and biochemical reactions in histological technique, in order to locate and scientifically determine certain substances or their activity. Histochemical techniques comprise the set of methods used to demonstrate the chemical nature of tissue and cellular components. Histochemical methods are based on chemically reacting (incubating) certain reagents with the cellular or tissue components of interest to obtain a final product that is colored and can be seen through light or electron microscopy. These techniques are of great importance in the diagnosis of normal and pathological tissues and cells (Kitazawa, Ohno, Haraguchi & Kitazawa, 2022).

**Crystal violet** is a basic compound that binds to negatively charged cellular components, so when it crosses the cell envelope of the bacteria, it accumulates in the cytoplasm of the cells, leaving it stained violet. This occurs in both Gram positive and negative bacteria, with the difference that the latter have a thin layer of murein which is what gives their membrane rigidity. When treated with ethanol, alcohol extracts the Crystal violet and these bacteria they lose coloration more easily than Gram positive ones (Nilles, Weiss & Theile, 2022).

### Methodology

A retrospective, technological development study was carried out to evaluate the histochemical technique of the Crystal violet in the determination of *H. pylori* in stomach biopsies, in the Pathological Anatomy departments of the General Hospital “Dr. Juan Bruno Zayas Alfonso” and in the Center of Toxicology and Biomedicine (TOXIMED), using samples obtained in the period from January to December 2018.

The utility of diagnostic tests is generally described and / or quantified in terms of their sensitivity, specificity, positive predictive value, negative predictive value, and positive and negative likelihood ratios. In diagnostic accuracy studies, the results obtained with the diagnostic test under evaluation are compared with those of a reference standard in the same group of patients. The term accuracy refers precisely to the agreement between the results of the diagnostic test with the reference standard.

The reference standard, also called the gold standard, corresponds to the best available and widely accepted way to establish the presence or absence of a certain condition. In the present study, the reference standard is the histochemical Giemsa staining technique.

Definitions in the description of a diagnostic test.

- A. True positive: the patient has the disease and the diagnostic test is positive.
- B. False positive: the patient does not have the disease, but the result of the diagnostic test is positive.
- C. False negative: the patient has the disease, but the result of the diagnostic test is negative.
- D. True negative: the patient does not have the disease and the diagnostic test is negative.

**Table 1.**

*Variables evaluated*

Parameter	Definition	Formula	Values that can be assumed
<b>Sensitivity</b>	Proportion of patients with the disease who will have a positive diagnostic test.	$Sensitivity = A/(A+C)$	0 - 1
<b>Specificity</b>	Proportion of patients without the disease who will have a negative diagnostic test.	$Specificity = D/(B+D)$	0 - 1
<b>Positive predictive value</b>	Probability that the patient has the disease since the diagnostic test is positive.	$Positive\ predictive\ value = A/(A+B)$	0 - 1





<b>Negative predictive value</b>	Probability that the patient does not have the disease since the diagnostic test is negative.	Negative predictive value = $D/(C+D)$	0 - 1
<b>Likelihood ratios</b>	Describe how many times a person with the disease is more likely to receive a certain result than a person without the disease.	Positive Likelihood Ratio = $\text{Sensitivity}/(1-\text{Specificity})$	0 - $\infty$ (infinite value)
		Negative Likelihood Ratio = $(1-\text{Sensitivity})/\text{Specificity}$	0 - 1
<b>Accuracy</b>	The probability that the result of the diagnostic test correctly predicts the presence or absence of the disease.	Accuracy = $(A+D)/(A+B+C+D)$	0 - 1

For decision-making about the diagnostic test evaluated, with respect to the reference standard used, the following decision rule was established:

1. Reliable: Accuracy values between 0.95 and 1
2. Doubtful: Accuracy Values between 0.80 and 0.94
3. Rejected: Accuracy Values less than 0.80

## Results

During the period between January - December 2018, a total of 1710 stomach biopsies were recorded, entered in the Pathological Anatomy department of the General Hospital "Dr. Juan Bruno Zayas Alfonso" (Table 2). As can be seen from the total samples processed by Giemsa staining, which is the reference standard used in our study, 1,380 samples were positively diagnosed in the presence of *H. pylori*, which corresponds to 80.7% of the total evaluated. Only 19.3% (330 patients) were not infected with the bacteria.

**Table 2.**

*Results of the diagnosis of H. pylori in stomach biopsies processed between January-December 2016 in the Department of Pathological Anatomy of the General Hospital "Dr. Juan Bruno Zayas Alfonso"*

Total Biopsies	Giemsa staining		Crystal violet staining	
	<i>H. pylori</i> (+)	<i>H. pylori</i> (-)	<i>H. pylori</i> (+)	<i>H. pylori</i> (-)
1710	1380	330	1380	330
100 %	80.7 %	19.3 %	80.7 %	19.3 %

The statistic values calculated in the diagnostic accuracy study of the Histochemical Crystal violet staining method for the diagnosis of *H. pylori* in stomach biopsies are expressed in Table 3.

**Table 3.**

*Evaluation of diagnostic accuracy parameters of the Crystal violet technique using the Giemsa technique as the reference standard*

Parameter	Crystal Violet Staining
Sensitivity	1
Specificity	1
Positive predictive value	1
Negative predictive value	1
Positive Likelihood ratio	$\infty$ (infinite value)
Negative Likelihood ratio	0
Accuracy	1

The value of Sensitivity of the Crystal violet technique corresponded to 1, this is because of the total of samples evaluated (1710), *H. pylori* were diagnosed positive with this technique, the amount of 1380 samples, this being the same number of samples that had been previously diagnosed with the Giemsa



technique, which is the test used as the Reference Standard, therefore, there are no sample values with false negatives.

The value of Specificity of the Crystal violet technique corresponded to 1, this is because of the total of samples evaluated (1710), *H. pylori* were diagnosed negative with this technique, the number of (330) samples, being this is the same number of samples that had been previously diagnosed with the Giemsa technique, which is the test used as the Reference Standard, therefore, there are no sample values with false positives.

The Positive Predictive Value of the Crystal violet technique corresponded to 1, since there is a total correspondence between the values of samples diagnosed positive both by the technique evaluated and by the Reference Standard, with no values for samples with false positives. While, the Negative Predictive Value of the Crystal violet technique corresponded to 1, since there is a total correspondence between the values of samples diagnosed as negative by both the technique evaluated and the Reference Standard, with no values of samples with false negatives.

When evaluating the Likelihood ratio parameter for the Crystal violet technique, an infinite positive likelihood value was obtained, and the negative likelihood value was zero.

The evaluation of the Accuracy of the Crystal violet technique when compared to the Reference Standard used (Giemsa technique), yielded a value corresponding to 1, since as we have explained, the values diagnosed as positive and negative were the same for both techniques, therefore, there are no false positive or negative values.

## Discussion

A diagnostic test refers to any method of obtaining additional information about the patient's state of health. The type of information acquired through the use of a diagnostic test not only includes the presence or absence of a certain disease, but also the staging of a known disease or establishing the existence of a certain condition, not necessarily pathological. Diagnostic accuracy studies are very important in terms of the characterization and evaluation of diagnostic tests. Understanding its meaning and form of evaluation is essential, not only for the critical assessment of diagnostic accuracy studies, but also in its application in daily clinical work and in the development of original research (Bravo & Cruz, 2015).

The sensitivity of a diagnostic test corresponds to the proportion of individuals correctly diagnosed with the condition or disease by said test. In other words, the proportion of true positives correctly identified by the diagnostic test of the total number of sick individuals according to the reference standard. While, the specificity of a diagnostic test corresponds to the proportion of individuals correctly diagnosed with absence of the condition or disease by the diagnostic test under study. That is, it is the proportion of true negatives that were correctly identified by the diagnostic test, of the total of healthy individuals according to the reference standard (Altman & Bland, 1994). The results obtained in the study suggest that the Crystal violet technique has the same sensitivity and specificity as the Giemsa technique in the experimental conditions used in this study.

The Positive Predictive Value of a diagnostic test corresponds to the conditional probability that the patient has the disease, given that the diagnostic test was positive. In other words, it is the proportion of patients with a positive diagnostic test who actually have the condition. The Negative Predictive Value of a diagnostic test corresponds to the conditional probability that the patient does not have the disease, since the diagnostic test was negative. In other words, it is the probability that the individual does not have the condition under study after that the test is negative. It is equivalent to the inverse of the post-test probability of having the disease since it was negative (Bravo & Cruz, 2015).

Likelihood ratios are defined as how many times a patient with the disease is more likely to have a certain diagnostic test result than patients without the disease. In other words, it is the probability ratio of a specific result in patients with the disease, versus those who do not have it. In the case of dichotomous results, the





positive likelihood ratio takes values between 1 and infinity, while the negative one takes values between 1 and 0. The positive likelihood ratio is calculated as sensitivity divided into (1 - specificity), or the ratio of true positives divided into false positives. Negative likelihood ratio is calculated as specificity divided by (1 - sensitivity), or the ratio of false negatives divided by true negatives. If the likelihood ratio is equal to 1, the probability of diagnosis is the same before and after applying the test. In this case the test is useless, it has no discriminating capacity. The farther the value of the likelihood ratio is from 1, the stronger the test will take us out of the diagnostic “uncertainty zone” (Bravo & Cruz, 2015). When evaluating this parameter for the Crystal violet technique, an infinite positive likelihood value tells us that this diagnostic test has a high probability of being positive in samples from patients truly infected with *H. pylori*. For its part, the negative likelihood value suggests the low probability that there are false negative values with this diagnostic test, that is, there is a high probability that the Crystal violet technique will obtain negative results in samples of patients who they are not infected with *H. pylori*.

The Accuracy of a diagnostic test is based on the probability that the result of this test correctly predicts the presence or absence of the disease. The results suggest that the Crystal violet technique has the same Accuracy as the Giemsa technique in the experimental conditions used in this study, being classified within the criteria that we established based on its Accuracy as a reliable test, so it could be used in daily clinical practice ensuring the diagnostic value that until then the Giemsa technique has had (Dore & Pes, 2021).

In Cuba, the Giemsa stain appears to be the preferred stain for the histologic diagnosis of *H. pylori* because of its good sensitivity, excellent specificity, lack of technical difficulty in preparation, and relatively low cost (Nagi & Jahanzeb, 2020). These results obtained suggest that the Crystal violet technique has the same Accuracy as the Giemsa technique in the experimental conditions used in this study, classifying itself within the criteria that we established based on its Accuracy as a reliable test, so it could be used in daily clinical practice, ensuring the diagnostic value that the Giemsa technique has had until then.

### Conclusions

The results obtained from the evaluation study of the diagnostic staining test with Crystal violet allow us to conclude that this technique is effective for the diagnosis of *H. pylori* in stomach biopsy samples, when compared with the Giemsa staining technique, which is currently employs.

### Bibliographic references

- Altman, D. G., & Bland, J. M. (1994). Diagnostic tests. 1: Sensitivity and specificity. *BMJ: British Medical Journal*, 308(6943), 1552.
- Amuri, H. T., & Al-Nuaimy, W. M. (2022). The Role of Histochemical and Immunohistochemical Methods for The Detection of Helicobacter Pylori in Chronic Gastritis. *Iraqi Postgraduate Medical Journal*, 21(1).
- Bravo, S., & Cruz, J. P. (2015). Diagnostic accuracy studies: Tools for its Interpretation. *Revista Chilena de Radiología*, 21(4), 158-164.
- Denic, M., Touati, E., & De Reuse, H. (2020). Pathogenesis of Helicobacter pylori infection. *Helicobacter*, 25, e12736.
- Dore, M. P., & Pes, G. M. (2021). What is new in Helicobacter pylori diagnosis. An overview. *Journal of Clinical Medicine*, 10(10), 2091.
- Kitazawa, S., Ohno, T., Haraguchi, R., & Kitazawa, R. (2022). Histochemistry, cytochemistry and epigenetics. *Acta Histochemica et Cytochemica*, 55(1), 1-7.
- Lee, Y. C., Dore, M. P., & Graham, D. Y. (2022). Diagnosis and treatment of Helicobacter pylori infection. *Annual review of medicine*, 73, 183-195.
- Nagi, A. H., & Jahanzeb, A. (2020). Detection of Helicobacter pylori Through Histochemistry & Immunofluorescent Staining in Biopsies of Patients with Chronic Gastritis. In *Proceedings*, 34(4), pp. 4-9.
- Nilles, J., Weiss, J., & Theile, D. (2022). Crystal violet staining is a reliable alternative to bicinchoninic acid assay-based normalization. *BioTechniques*, 73(3), 131-135.



**ORANGE JOURNAL**

- Öztekin, M., Yilmaz, B., Ağagündüz, D., & Capasso, R. (2021). Overview of Helicobacter pylori Infection: clinical features, treatment, and nutritional aspects. *Diseases*, 9(4), 66.
- Rotimi, O., Cairns, A., Gray, S., Moayyedi, P., & Dixon, M. F. (2000). Histological identification of Helicobacter pylori: comparison of staining methods. *Journal of clinical pathology*, 53(10), 756-759.
- Valdés, M. V., Rodríguez, J. A. B., Reyes, L. S., & Pérez, Y. P. (2020). Infección por Helicobacter pylori en pacientes con enfermedades digestivas. *Medimay*, 27(4), 541-551.

