

This is an Open Access document downloaded from ORCA, Cardiff University's institutional repository: <https://orca.cardiff.ac.uk/id/eprint/161716/>

This is the author's version of a work that was submitted to / accepted for publication.

Citation for final published version:

Liu, Li Qi, Shi, Wen Qing, Chen, Jun, Li, Qing Jian, Qian Lin, Qian Ling, Wei, Hong, Xu, San Hua, Kang, Min, Huang, Hui, Chen, Xu, Wang, Yixin and Shao, Yi 2023. Retinal alterations in evaluation of rheumatoid arthritis with chloroquine treatment: A new approach. *Journal of Biophotonics* , e202300133. 10.1002/jbio.202300133

Publishers page: <https://doi.org/10.1002/jbio.202300133>

Please note:

Changes made as a result of publishing processes such as copy-editing, formatting and page numbers may not be reflected in this version. For the definitive version of this publication, please refer to the published source. You are advised to consult the publisher's version if you wish to cite this paper.

This version is being made available in accordance with publisher policies. See <http://orca.cf.ac.uk/policies.html> for usage policies. Copyright and moral rights for publications made available in ORCA are retained by the copyright holders.



RESEARCH ARTICLE

Retinal alterations in evaluation of rheumatoid arthritis with chloroquine treatment: A new approach

Li-Qi Liu¹ | Wen-Qing Shi²  | Jun Chen¹ | Qing-Jian Li³ | Qian-Ling¹ | Hong Wei¹ | San Hua Xu¹ | Min Kang¹ | Hui Huang¹ | Xu Chen⁴ | Yi-Xin Wang⁵ | Yi Shao¹

¹Department of Ophthalmology, The First Affiliated Hospital of Nanchang University, Jiangxi Center of National Ocular Disease Clinical Research Center, Nanchang, People's Republic of China

²Department of Ophthalmology, Jinshan Hospital, Fudan University, Shanghai, People's Republic of China

³Department of Ophthalmology, Xiang'an Hospital of Xiamen University, Fujian Provincial Key Laboratory of Ophthalmology and Visual Science, Eye Institute of Xiamen University, Xiamen University School of Medicine, Xiamen, People's Republic of China

⁴Department of Ophthalmology and Visual Sciences, Maastricht University, Maastricht, Netherlands

⁵School of Optometry and Vision Sciences, Cardiff University, Cardiff, UK

Correspondence

Yi Shao, Department of Ophthalmology, The First Affiliated Hospital of Nanchang University, 17 Yongwaizheng Street, Donghu, Nanchang, Jiangxi 330006, People's Republic of China.
Email: freebee99@163.com

Funding information

National Natural Science Foundation of China, Grant/Award Number: 82160195

Abstract

Objective: To evaluate the effect of hydroxychloroquine on conjunctival and retinal microvascular density in rheumatoid arthritis (RA) patients.

Methods: Ten healthy controls, 10 RA patients who had not been treated with

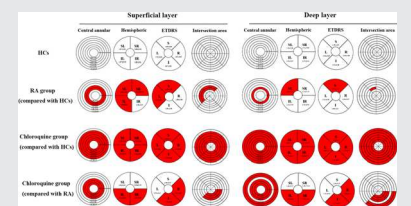
hydroxychloroquine, and 10 RA patients who had been treated with chloroquine for more than 5 years were recruited. Optical coherence tomography (OCTA) was used to examine the conjunctival and superficial and deep retinal microvascular density and compared the differences in microvascular density between the three groups.

Results: The vascular density in RA group in superficial microvascular was significantly lower than that in control group ($p < 0.001$). Compared with RA group, the chloroquine group showed statistically significantly lower microvascular ($p < 0.001$) and deep microvascular ($p = 0.018$). Superficial microvascular was positively correlated with conjunctival vessel density in RA patients ($r = 0.868$, $p = 0.0048$).

Conclusions: The use of chloroquine could further reduce the vascular density in the absence of statistical difference in the course of the disease.

KEYWORDS

chloroquine, microvascular density, optical coherence tomography angiography, retina, rheumatoid arthritis



Li-Qi Liu, Wen-Qing Shi and Jun Chen contributed equally to this study.

This is an open access article under the terms of the [Creative Commons Attribution-NonCommercial-NoDerivs](https://creativecommons.org/licenses/by-nc-nd/4.0/) License, which permits use and distribution in any medium, provided the original work is properly cited, the use is non-commercial and no modifications or adaptations are made.

© 2023 The Authors. *Journal of Biophotonics* published by Wiley-VCH GmbH.

1 | INTRODUCTION

Rheumatoid arthritis (RA) is an autoimmune disease with synovitis as the basic pathological change, patients may present with a variety of extra-articular manifestations,

such as vasculitis, interstitial pneumonia, and serositis [1]. Rheumatoid vasculitis (RV) is one of its most devastating complications. Although the pathogenesis of RA is complex and associated with various factors such as genetic susceptibility, environmental factors, and immune disorders, the appearance of autoantibodies and the deposition of immune complexes are recognized as instrumental in the pathogenesis of the disease [2]. RV may involve blood vessels throughout the body; that is, mainly small and medium-sized vessels. 15% of patients with RV have ocular symptoms due to the involvement of blood vessels in the eyes, which can cause iritis, conjunctivitis, retinitis, and other conditions [3]. Foreign body sensation in the eyes, photophobia, and tearing, as well as loss of vision are common complaints. Delays in systematic intervention and treatment can be expected to have serious consequences [4].

Chloroquine is a traditional anti-malarial drug, which is part of the standard treatment regimen for RA, and it is currently used for the treatment of mild to moderate cases. While the mechanism of chloroquine in the treatment of RA is not yet fully understood, Rainsford et al. [5] suggested that it inhibits the proliferation, activation, and secretions of immune cells including inflammatory factors, thereby suppressing the immune-inflammatory process. In addition, chloroquine as a lysosomal high-affinity inhibitor that affects the proliferation, invasion, and apoptotic resistance of fibroblast-like synoviocytes by inhibiting lysosomal autophagy [6, 7]. However, the effect of chloroquine on retinal vascular endothelial cells and how it affects blood vessels has been poorly studied, some clinical work has revealed that chloroquine treatment for RA may lead to chloroquine retinopathy, the incidence of which is increasing yearly [8]. This condition may cause damage to photoreceptors and the retinal pigment epithelium and may even lead to permanent vision loss [9]. Therefore, the consensus view is that patients need to undergo retinal monitoring during treatment.

Optical coherence tomography angiography (OCTA) is a nonpenetrating, noninvasive, rapid angiographic technique based on OCT. It maps the blood vessels in different areas of the fundus using laser reflection from the surface of moving red blood cells [10]. With its self-contained software, OCTA can perform segmentation comparisons and quantitative calculations with imaging. Due to its clear advantages, OCTA has been used for fundus imaging in a variety of systemic diseases including Alzheimer's disease (AD) [11] and multiple sclerosis (MS) [12]. It has good sensitivity and accuracy in ophthalmic diseases with typical neovascularization such as primary open-angle glaucoma with high myopia and age-related macular degeneration [13–15]. These findings suggest that OCTA could achieve accurate monitoring and early detection of ocular complications including

retinopathy after chloroquine use in patients with RA, and may improve patient prognoses, maximizing their quality of life, and avoiding serious adverse outcomes such as blindness.

Several studies have found that the use of chloroquine causes a decrease in deep retinal vascular density, an alteration that is more pronounced after more than 5 years of drug use [16–18]. This reduction in vascular density is thought to be a precursor of chloroquine toxicity by some but longitudinal studies are lacking. The innovation of our study is the use of different partitioning methods to divide the OCTA images of the fundus into different areas to locate the specific location of the altered microvascular density in the patient's eye. In addition, three groups were set up to compare patients who had and had not used chloroquine, as well as RA patients and healthy control subjects, to investigate whether disease progression in RA is involved in the process of chloroquine-induced decrease in fundus microvascular density.

2 | METHODS

2.1 | Research subjects

Ten patients with RA (RA group), 10 patients with RA who had been taking chloroquine treatment for more than 5 years (RAC group), and 10 matched healthy controls (HC group) were recruited. All participants were patients or visitors attending the Department of Ophthalmology of the First Affiliated Hospital of Nanchang University between June 2020 and June 2021. Ophthalmologists selected the subjects strictly according to the inclusion and exclusion criteria described below and performed relevant examinations, including visual acuity measurements, intraocular pressure (IOP) measurements, corneal assessment using a slit lamp, dilated fundus examinations, and antinuclear antibody and anti-platelet antibody testing. The erythrocyte sedimentation rate (ESR) and C-reactive protein (CRP) levels were measured to assess the degree of inflammation.

The study was approved by the Human Ethics Committee of the First Affiliated Hospital of Nanchang University and complied with the Declaration of Helsinki. All subjects signed an informed consent form before participating.

2.2 | Recruitment criteria

Inclusion criteria for HCs were: (1) age ≥ 18 years; (2) no diagnosis of rheumatoid arthritis, systemic lupus erythematosus, desiccation syndrome, or other similar connective tissue diseases or immune system disorders; and

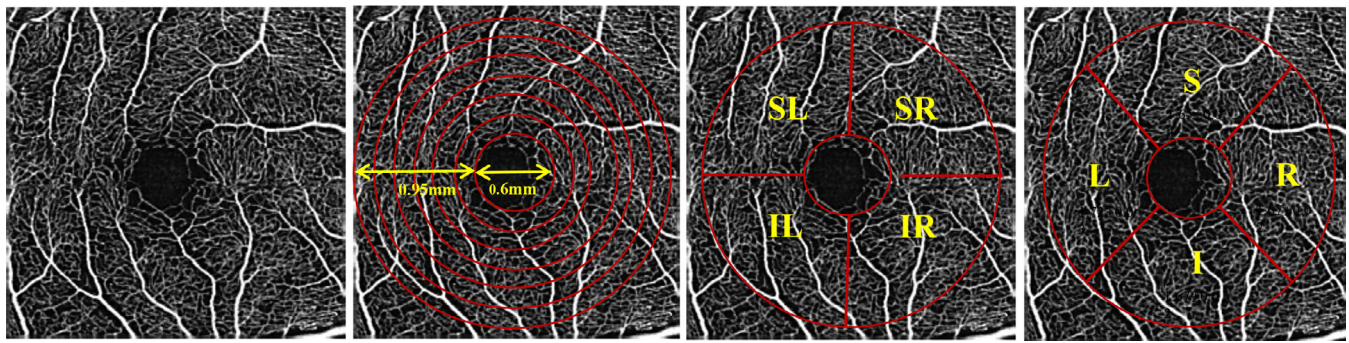


FIGURE 1 Macular retinal segmentation. From left to right: 3 mm × 3 mm retinal microvascular density image of OCTA examination of HCs; ring partition method (C1–C6); hemispheric partition method; ETDRS method. ETDRS, Early Treatment Diabetic Retinopathy Study; I, inferior; IL, inferior left; IR, inferior right; L, left; R, right; S, superior; SL, superior left; SR, superior right.

TABLE 1 Basic information of participants in all groups.

	HCs	RA	Chloroquine group	p value
Age (years)	40.60 ± 6.42	39.80 ± 12.05	43.90 ± 4.23	0.466
Gender (male/female)	0/10	0/10	0/10	N/A
Visual acuity (R) ^{***}	0.96 ± 0.08	0.73 ± 0.17	0.53 ± 0.21	<0.001
Visual acuity (L) [*]	0.86 ± 0.16	0.74 ± 0.23	0.59 ± 0.23	0.029
IOP (R)	14.84 ± 1.10	15.80 ± 1.33	15.50 ± 2.59	0.461
IOP (L)	14.78 ± 1.59	15.40 ± 1.41	15.56 ± 0.88	0.474
ESR ^{***}	3.90 ± 1.20	15.20 ± 8.01	11.00 ± 3.94	<0.001
CRP ^{**}	1.27 ± 0.78	3.90 ± 2.38	1.46 ± 0.53	0.002
ANA ^{+***}	1/10	10/10	10/10	<0.001
APA ⁺	1/10	0/10	0/10	0.322
HADS ^{**}	2.60 ± 1.07	9.20 ± 3.04	9.00 ± 2.79	0.006
Blood pressure				
SP (mmHg)	128.10 ± 18.71	125.80 ± 5.43	122.50 ± 5.34	0.363
DP (mmHg)	83.30 ± 5.98	79.10 ± 8.71	75.50 ± 7.81	0.101
Disease duration (years)	N/A	8.20 ± 2.97	9.40 ± 1.84	0.295
Medication time (years)	N/A	N/A	8.40 ± 1.90	N/A

Abbreviations: ANA, antinuclear antibody; APA, antiphospholipid antibody; DP, diastolic blood pressure; HADS, Hospital Anxiety and Depression Scale; N/A, not available; SP, systolic blood pressure.

* $p < 0.05$; ** $p < 0.01$; *** $p < 0.001$.

(3) no history of taking immunosuppressive drugs such as chloroquine and its derivatives or steroids.

Inclusion criteria for the RA group included: (1) age ≥18 years; (2) diagnosis with RA for the first time; (3) no previous treatment regimen with chloroquine or its derivatives; (4) no other immune system diseases such as Sjogren's syndrome or other corneal and ocular diseases; and (5) habitually right-handed.

Inclusion criteria for the chloroquine group included: (1) age ≥18 years; (2) previous diagnosis of RA; (3) duration of chloroquine treatment ≥5 years; (4) exclusion of other immune system diseases such as dry eye syndrome (or other corneal and ocular diseases); and (5) habitually right-handed.

2.3 | Exclusion criteria

Individuals positive for any of the following were excluded: (1) smokers; (2) diagnosis with other eye disorders (e.g., glaucoma, diabetic retinopathy, retinal arteriovenous obstruction, macular degeneration, ocular trauma, or ocular tumor); (3) bleeding or inflammation in the cornea and conjunctiva of either eye; (4) metabolic diseases such as diabetes, hypertension, or inability to cooperate due to Alzheimer's or Parkinson's disease; (5) vasculitis patient; (6) pregnant or lactating; (7) inability to tolerate the study protocol for any reason; (8) history of ophthalmic surgery; and (9) refractive error ≥6.00 D.

TABLE 2 *p* value of further intergroup comparison based on the results in Table 1.

	HCs vs. RA group	RA group vs. chloroquine group	HCs vs. chloroquine group
Visual acuity (R)	0.030*	0.308	<0.001***
Visual acuity (L)	0.750	0.399	0.024*
ESR	<0.001***	1.000	0.003**
CRP	0.007**	0.009**	1.000
HADS	<0.001***	0.999	<0.001***

p* < 0.05; *p* < 0.01; ****p* < 0.001.

TABLE 3 Examination results of vascular density in macular area.

	HCs		RA		Chloroquine group	
	Superficial layer	Deep layer	Superficial layer	Deep layer	Superficial layer	Deep layer
TMI	1.78 ± 0.02	1.80 ± 0.06	1.72 ± 0.05	1.73 ± 0.06	1.62 ± 0.04	1.55 ± 0.15
MIR	1.86 ± 0.02	1.65 ± 0.06	1.74 ± 0.05	1.57 ± 0.04	1.64 ± 0.05	1.39 ± 0.11
MAR	1.10 ± 0.03	1.01 ± 0.06	1.10 ± 0.03	1.00 ± 0.09	1.05 ± 0.04	0.97 ± 0.05
SR	1.69 ± 0.02	1.61 ± 0.06	1.53 ± 0.14	1.55 ± 0.10	1.42 ± 0.15	1.46 ± 0.14
SL	1.67 ± 0.03	1.58 ± 0.06	1.61 ± 0.03	1.47 ± 0.17	1.53 ± 0.15	1.40 ± 0.17
IL	1.67 ± 0.03	1.62 ± 0.07	1.59 ± 0.05	1.55 ± 0.04	1.51 ± 0.07	1.35 ± 0.12
IR	1.69 ± 0.01	1.57 ± 0.11	1.59 ± 0.10	1.56 ± 0.05	1.43 ± 0.06	1.32 ± 0.10
S	1.65 ± 0.04	1.59 ± 0.07	1.51 ± 0.15	1.42 ± 0.16	1.44 ± 0.15	1.44 ± 0.15
I	1.67 ± 0.02	1.59 ± 0.08	1.65 ± 0.04	1.60 ± 0.05	1.45 ± 0.09	1.32 ± 0.13
R	1.67 ± 0.02	1.66 ± 0.06	1.68 ± 0.09	1.64 ± 0.07	1.45 ± 0.06	1.38 ± 0.14
L	1.72 ± 0.03	1.58 ± 0.09	1.58 ± 0.05	1.51 ± 0.09	1.55 ± 0.13	1.41 ± 0.15
C1	1.66 ± 0.04	1.24 ± 0.13	1.44 ± 0.02	1.20 ± 0.07	1.17 ± 0.16	1.06 ± 0.08
C2	1.51 ± 0.05	1.44 ± 0.08	1.49 ± 0.04	1.33 ± 0.10	1.29 ± 0.12	1.11 ± 0.12
C3	1.56 ± 0.02	1.41 ± 0.11	1.47 ± 0.03	1.40 ± 0.08	1.29 ± 0.10	1.26 ± 0.12
C4	1.53 ± 0.02	1.45 ± 0.04	1.47 ± 0.05	1.41 ± 0.07	1.33 ± 0.10	1.32 ± 0.16
C5	1.51 ± 0.02	1.46 ± 0.04	1.49 ± 0.02	1.46 ± 0.06	1.43 ± 0.09	1.32 ± 0.12
C6	1.52 ± 0.03	1.46 ± 0.06	1.51 ± 0.02	1.47 ± 0.05	1.47 ± 0.15	1.36 ± 0.10

Abbreviations: I, inferior; L, left; MAR, macrovascular; MIR, microvascular; R, right; S, superior; TMI, total microvascular.

2.4 | OCTA examinations

2.4.1 | Macular retinal segmentation

To accurately locate the retinal microvascular changes, we used three methods to partition the images obtained by OCTA, including the central annular segmentation method, the hemispheric segmentation method, and the Early Treatment Diabetic Retinopathy Study (ETDRS) segmentation method. The ring partition method included the following: after removing the avascular region with a central concave diameter of 0.6 mm, the circular region with a diameter of 0.6–2.5 mm was defined as a ring region with a bandwidth of 0.95 mm. The ring area was divided into six fine rings with a bandwidth of 0.16 mm and the rings were named C1–C6. The hemispheric partition method included

the following: the images were divided into four quadrants according to the horizontal diagonal and vertical diagonal, which were the superior right (SR), superior left (SL), inferior left (IL), and inferior right (IR) quadrants. The Early Treatment Diabetic Retinopathy Study (ETDRS) segmentation method included the following: the images were divided into four quadrants according to the diagonal of the two quadrants, which were superior (S), inferior (I), left (L), and right (R) (Figure 1).

2.5 | Statistical analyses

All statistical analyses were completed with SPSS 21.0 (IBM Corp.). Qualitative and quantitative data were expressed as the mean ± standard deviation and frequency

TABLE 4 p value for comparison of retinal microvascular examination results among three groups.

	Superficial layer	Deep layer
TMI	<0.001	<0.001
MIR	<0.001	<0.001
MAR	<0.001	0.039
SR	<0.001	0.002
SL	<0.001	0.001
IL	<0.001	<0.001
IR	<0.001	<0.001
S	<0.001	0.001
I	<0.001	<0.001
R	<0.001	<0.001
L	<0.001	0.001
C1	<0.001	<0.001
C2	<0.001	<0.001
C3	<0.001	0.002
C4	<0.001	0.004
C5	0.011	<0.001
C6	0.341	0.006

Note: Normality test was performed in all data and single factor analysis of variance (ANOVA) was performed for those that met the normal distribution, while groups that did not meet the normal distribution were analyzed by rank sum test.

(percentage), respectively. Continuous quantifiable data were tested for normality with the Kolmogorov–Smirnov test. Data conforming to a normal distribution were controlled assessed with a one-way analysis of variance, and those not conforming were tested with a rank sum test. Further post hoc comparisons were performed if the differences among the three groups were statistically significant. For qualitative data, a chi-squared test and Fisher's exact test were utilized to make comparisons. The relationship between retinal vascular density and conjunctival microvascular density was explored with Pearson's correlation analysis. For all statistical analyses, the significance level was set at $\alpha = 0.05$.

3 | RESULTS

3.1 | Baseline characteristics of participants

Baseline characteristics were compared between groups using an independent sample rank sum test (Table 1). No significant differences were found between the three groups in age, monocular IOP, systolic blood pressure (SP), or diastolic blood pressure (DP; $p > 0.05$). Significant differences were found in monocular visual acuity (right

eye $p < 0.001$; left eye $p = 0.029$), ESR ($p < 0.001$), and CRP ($p = 0.002$). Further comparisons of these indices between the RA and HC groups revealed statistically significant differences in right eye visual acuity ($p = 0.030$), ESR ($p < 0.001$), CRP ($p = 0.007$), and HADS ($p < 0.001$). The chloroquine and RA groups differed significantly in CRP ($p = 0.009$), while CRP ($p = 1.000$) were similar in the chloroquine and HCs groups (Table 2).

3.2 | Vascular density in the superficial retinal macula

The results of OCTA examination are presented in Table 3. The differences among the three groups were statistically significant for all indicators except C6 (Table 4). In the superficial macular vessels, we observed a significant decrease in both superficial total microvascular (STMI, $p < 0.001$) and superficial microvascular (SMIR, $p < 0.001$) in RA patients compared with HCs, whereas the superficial macrovessels (SMAR, $p = 0.707$) were similar in the two groups. Specifically, the decrease in STMI in RA patients was mainly observed in the SR ($p = 0.001$), SL ($p = 0.004$), and IL ($p < 0.001$) quadrants of the hemispheric partition method and the S ($p = 0.002$) and L ($p = 0.002$) quadrants of the ETDRS method, as well as in the C2 ($p = 0.033$) quadrant of the ring segmentation method, and C3 ($p = 0.035$) in the ETDRS method (Figure 2).

The chloroquine group showed significantly lower STMI ($p < 0.001$), SMIR ($p < 0.001$), and SMAR ($p = 0.001$) than the RA group. Among these, the STMI was significantly reduced in the IL ($p = 0.002$) and IR ($p < 0.001$) quadrants in the hemispheric partition method, I ($p = 0.007$) and R ($p < 0.001$) quadrants in the ETDRS method, and C1 ($p = 0.022$), C2 ($p = 0.033$), and C3 ($p = 0.031$) quadrants in the ring partition method. The differences between the superficial macular vascular density and that of patients who had not received chloroquine were not statistically significant, but all showed an overall trend of decreasing (Table 5 and Figure 2B).

3.3 | Vascular density in the deep retinal macula

Deep total microvascular (DTMI; $p < 0.001$), deep microvascular (DMIR; $p < 0.001$), and deep macrovascular (DMAR; $p = 0.039$) densities were statistically significantly different among the three groups of subjects (Table 4). Among these, DTMI ($p = 0.183$), DMIR ($p = 0.05$), and DMAR ($p = 0.167$) were statistically similar in RA patients and HCs (Table 5). Further comparisons of DTMI

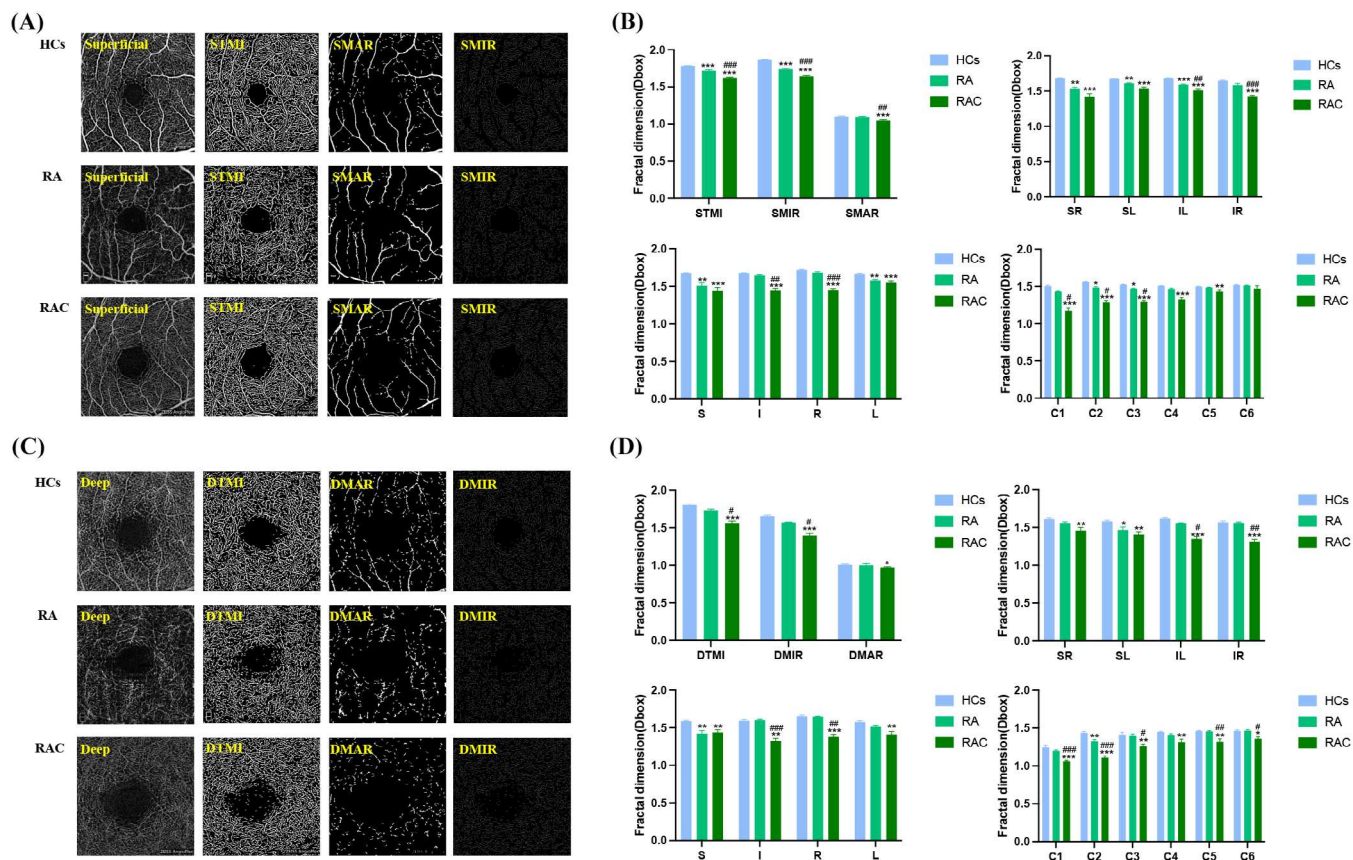


FIGURE 2 The result of OCTA examination in superficial and deep retinal layer. (A) The classic 3 mm × 3 mm OCTA image of the macular region of the retina in superficial retinal layer; (B) results of superficial retinal vessel density in HCs, RA group and chloroquine group. (C) The classic 3 mm × 3 mm OCTA image of the macular region of the retina in deep retinal layer; (D) results of deep retinal vessel density in HCs, RA group and chloroquine group. DMAR, deep macrovascular; DMIR, deep microvascular; DTMI, deep total microvascular; SMAR, superficial macrovascular; SMIR, superficial microvascular; STMI, superficial total microvascular.

using the hemispheric partition, ETDRS, and ring partition methods showed statistically significant changes in SL ($p = 0.047$), S ($p = 0.002$), and C2 ($p = 0.001$) in RA patients when compared with HCs (Figure 3).

Statistically significant reductions in DTMI and DMIR were found in the chloroquine group compared with the RA group, but no such difference was found in DMAR between the two groups ($p = 1.00$). Further investigation using a hemispheric partition, ETDRS, and ring partition methods revealed significantly lower DMAR in the chloroquine group than the RA group in the IL ($p = 0.023$), IR ($p = 0.001$), I ($p < 0.001$), and R ($p = 0.001$) quadrants, and C1 ($p < 0.001$), C2 ($p < 0.001$), C3 ($p = 0.015$), C5 ($p = 0.002$), and C6 ($p = 0.015$) regions, while densities in other regions decreased insignificantly (Table 5, Figures 2D and 3).

3.4 | Conjunctival microvasculature

Conjunctival vascular density measured using OCTA was statistically significantly different among the three groups

(see Figure 4A for details) in both superficial ($p = 0.024$) and deep (0.014) layers (Table 6).

3.5 | Correlation analyses

We investigated the relationship between the TMI and conjunctival microvasculature and observed a significant positive correlation between the two in the RA group ($r = 0.868$, $p = 0.0048$), but not in the other groups (Figure 4B,C).

4 | DISCUSSION

In our study, patients with RA generally showed lower superficial retinal vascular density than HCs, mainly in SMIR, while DTMI showed an insignificant decrease. In order to more accurately measure the areas where the blood vessel density changes, we used three different methods to divide the fundus retina. Specifically, the decrease in superficial retinal vascular density was concentrated in the superior and left side of the retina (SR,

TABLE 5 *p* value of further intergroup comparison based on the results in Table 2.

	HCs vs. RA group		RA group vs. chloroquine group		HCs vs. chloroquine group	
	Superficial layer	Deep layer	Superficial layer	Deep layer	Superficial layer	Deep layer
TMI	<0.001	0.183	<0.001	0.018	<0.001	<0.001
MIR	<0.001	0.050	<0.001	0.029	<0.001	<0.001
MAR	0.707	0.167	0.001	1.000	<0.001	0.048
SR	0.001	0.195	0.119	0.294	<0.001	0.001
SL	0.004	0.047	0.818	0.696	<0.001	0.001
IL	<0.001	0.061	0.002	0.023	<0.001	<0.001
IR	0.073	1.000	<0.001	0.001	<0.001	<0.001
S	0.002	0.002	1.000	1.000	<0.001	0.004
I	0.339	1.000	0.007	<0.001	<0.001	0.001
R	0.069	1.000	<0.001	0.001	<0.001	<0.001
L	0.002	0.159	1.000	0.225	0.001	0.001
C1	0.066	0.473	0.022	<0.001	<0.001	<0.001
C2	0.033	0.001	0.033	<0.001	<0.001	<0.001
C3	0.035	1.000	0.031	0.015	<0.001	0.003
C4	0.072	0.334	0.059	0.264	<0.001	0.003
C5	0.506	1.000	0.323	0.002	0.008	0.002
C6	N/A	1.000	N/A	0.015	N/A	0.017

Note: The post hoc test for all data conforming to the normal distribution was first performed as a chi-square test. If the variances are chi-square, the least significant difference (LSD) test was selected. If the variances are not homogeneous, the Tamhane's T2 test was selected. Abbreviation: N/A, not available.

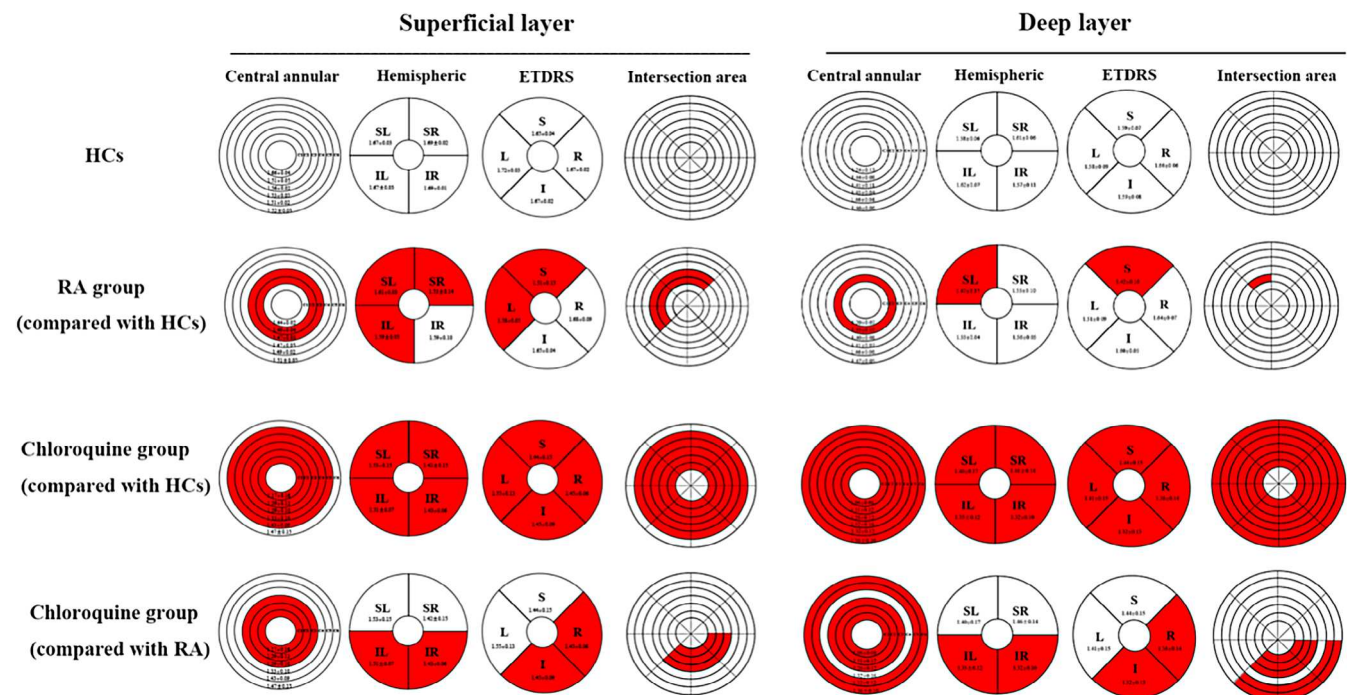


FIGURE 3 Results of superficial and deep retinal vascular density in different regions of three groups ($M \pm SD$).

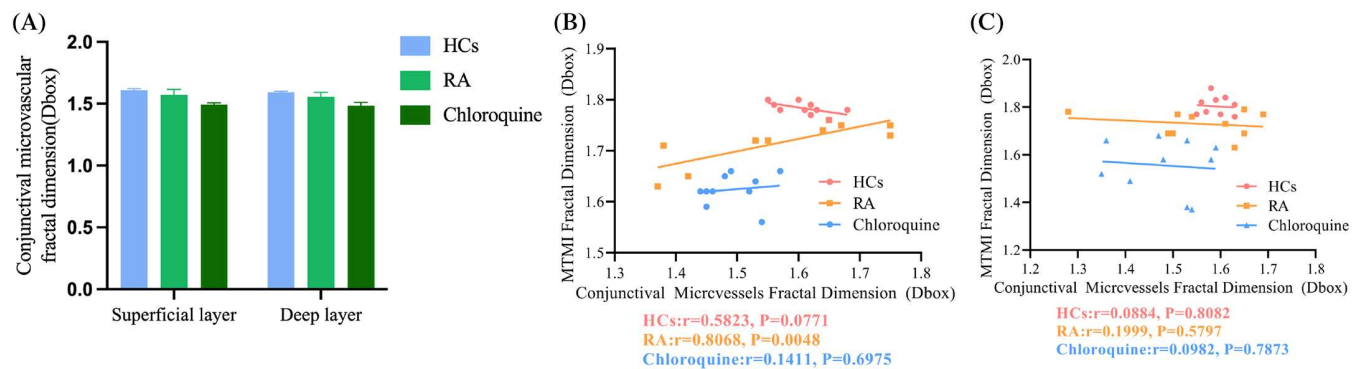


FIGURE 4 The OCTA examination result of conjunctival microvasculature density. (A) Comparisons of macular retinal vessel density (D box) between groups in both superficial (B) and deep (C) layers. HC, healthy control; RA, rheumatoid arthritis.

	HCs	RA group	Chloroquine group	p value
Superficial layer	1.61 ± 0.05	1.57 ± 0.17	1.49 ± 0.07	0.024*
Deep layer	1.59 ± 0.06	1.55 ± 0.15	1.48 ± 0.13	0.014*

TABLE 6 The result of OCTA examination in conjunctival microvasculature.

* $p < 0.05$; ** $p < 0.01$; *** $p < 0.001$.

SL, and IL) and around the macula (C2 and C3), while the decrease in deep vascular density was concentrated in the upper part of the retina (SL and S) and around the macula (C2). A significant decrease in visual acuity was also found, while none of the changes in IOP were statistically significant (Table 1). This result suggested that the progression of RA disease may result in retinal involvement, and a decrease in retinal vascular density in the early clinical stage may be one of the foremost early pathological manifestations. The decrease in retinal vascular density may result from RV caused by endothelial cell damage due to deposition of circulating immune complexes and involvement of the fundal vessels [19], in which case patients may exhibit high levels of macrophage migration inhibitory factor [20]. Koray et al. [21] conducted a similar study using OCTA to assess changes in retinal vascular density in RA patients and found that retinal capillary plexus density in the maculae of RA patients was reduced, but foveal avascular zone size was not changed appreciably, suggesting that this difference was due to small rather than large vessel changes in RA. In broad agreement with this finding, the present study found that superficial retinal vascular density changes in RA patients were mainly in the SMAR, while the decrease in SMIR was not statistically meaningful. Retinal heat shock proteins may be a key cause of RA [22] and may contribute to reduced STMI. For example, cross-reactive antigens between bacterial heat shock proteins and the surface of retinal ganglion cells are used for retinal injury models in rats, in which injection of heat shock peptides can lead to the progression of ischemic retinal injury [23].

As a classical anti-malarial drug, chloroquine is also used in the treatment of various connective tissue diseases such as systemic lupus erythematosus and RA. However, long-term use of chloroquine can lead to binding of melanin granules in the retinal pigment epithelium and eventually result in its atrophy and “bull’s eye” maculopathy, and possibly permanent loss of vision [24]. Retinal toxicity caused by chloroquine administration has attracted widespread attention, and research has been dedicated to the adverse effects of chloroquine and its derivatives in the treatment of patients with RA. Ozek [25] found a decrease in vessel density in the deep capillary plexus blood supply area after more than 5 years of chloroquine use in RA patients without a significant change in the foveal avascular zone size, although some studies have found an increase in zone size [26]. Reduced vascular plexus density has also been found in the parafoveal deep temporal and deep hemi-inferior areas using OCTA [27]. In the present study, we assessed deep and superficial vessel densities using OCTA in RA patients treated with chloroquine for more than 5 years and compared these to RA patients without chloroquine treatment. We found that the former group exhibited a reduction in STMI, SMIT, SMAR, DTMI, and DMIR, with an insignificant reduction in DMAR. We further partitioned the OCTA images using different methods to provide more precise information and found that in the superficial retinal layers, the decrease in vessel density was mainly concentrated in the lower regions (IL, IR, I, and R) and near the foveal avascular zone (C1, C2, and C3), while in the deeper layers, the decrease in vessel density was more diffusely distributed (C1, C2, C3, C5,

and C6). Most studies of chloroquine retinal toxicity have suggested that patients experience macular thinning, and Marija [28] found that this change was concentrated in the inferior, nasal, and temporal sectors. Lee [29] showed that the use of chloroquine led to a decrease in the thickness of the macular ganglion cell-inner plexiform layer.

Our study also found a significant positive correlation between STMI and conjunctival vascularity in the RA group. Chronic inflammatory stimulation is thought to lead to compensatory vasodilation and an increase in blood flow density [30]; conversely, our findings suggested that RA-induced vascular endothelial cell injury and decreases in vascular density may be more predominant than the reactive local increase in blood flow. However, there are some limitations in this study. The number of subjects in this study is small, and the mechanism of fundus vascular changes should be further analyzed, which will be further improved in future studies.

5 | CONCLUSION

We utilized OCTA imaging to assess the retinal microvasculature in the superficial and deep layers in RA patients with and without chloroquine treatment and found reduced macular microvascular density in the superficial and deep layers of the retina in both groups. Reduced density was more pronounced in patients with RA who had received long term chloroquine treatment. Fundus vessel changes are detectable using OCTA before other changes occur, such as decreased visual acuity or increased IOP. A future study with a larger sample is needed to determine whether OCTA can be used as a routine monitoring method in RA patients with chloroquine treatment to guide early intervention and avoid or delay adverse clinical outcomes.

FUNDING INFORMATION

National Natural Science Foundation (No. 82160195).

CONFLICT OF INTEREST STATEMENT

This study did not receive any industrial support. The authors have no competing interests to declare regarding this study.

DATA AVAILABILITY STATEMENT

The datasets used and/or analyzed during the present study are available from the corresponding author on reasonable request.

ORCID

Wen-Qing Shi  <https://orcid.org/0009-0007-4330-7132>

REFERENCES

- [1] J. S. Smolen, D. Aletaha, I. B. McInnes, *Lancet* **2016**, 388, 2023.
- [2] B. A. Binstadt, P. R. Patel, H. Alencar, P. A. Nigrovic, D. M. Lee, U. Mahmood, R. Weissleder, D. Mathis, C. Benoist, *Nat. Immunol.* **2006**, 7, 284.
- [3] P. J. Morgan-Warren, S. Dulku, J. Ravindran, G. Smith, *Int. Ophthalmol.* **2014**, 34, 933.
- [4] C. S. Foster, M. Yee, *Int. Ophthalmol. Clin.* **1983**, 23, 131.
- [5] K. D. Rainsford, A. L. Parke, M. Clifford-Rashotte, W. F. Kean, *Inflammopharmacology* **2015**, 23, 231.
- [6] J. Karami, M. Masoumi, H. Khorramdelazad, H. Bashiri, P. Darvishi, H. A. Sereshki, M. Shekarabi, A. Sahebkar, *Life Sci.* **2020**, 254, 117734.
- [7] L. Liu, C. Han, H. Yu, W. Zhu, H. Cui, L. Zheng, C. Zhang, L. Yue, *Oncol. Rep.* **2018**, 39, 2807.
- [8] I. H. Yusuf, S. Sharma, R. Luqmani, S. M. Downes, *Eye (Lond.)* **2017**, 31, 828.
- [9] Z. Jajic, I. Jajic, S. Grazio, *Reumatizam* **1995**, 42, 7.
- [10] J. P. Campbell, M. Zhang, T. S. Hwang, S. T. Bailey, D. J. Wilson, Y. Jia, D. Huang, *Sci. Rep.* **2017**, 7, 42201.
- [11] L. Manuelidis, *Virulence* **2013**, 4, 373.
- [12] N. Feucht, M. Maier, G. Lepennetier, M. Pettenkofer, C. Wetzlmair, T. Daltrozzo, P. Scherm, C. Zimmer, M. M. Hoshi, B. Hemmer, T. Korn, B. Knier, *Mult. Scler.* **2019**, 25, 224.
- [13] L. Querques, C. Giuffrè, F. Corvi, I. Zucchiatti, A. Carnevali, L. A. de Vitis, G. Querques, F. Bandello, *Br. J. Ophthalmol.* **2017**, 101, 609.
- [14] F. Lin, F. Li, K. Gao, W. He, J. Zeng, Y. Chen, M. Chen, W. Cheng, Y. Song, Y. Peng, L. Jin, T. P. H. Lin, Y. Wang, C. C. Tham, C. Y. Cheung, X. Zhang, *Invest. Ophthalmol. Vis. Sci.* **2021**, 62, 30.
- [15] Z. Lin, X. Pan, K. Mao, Q. Jiao, Y. Chen, Y. Zhong, Y. Cheng, *Lasers Med. Sci.* **2021**, 37, 269.
- [16] K. Ayar, M. E. Can, N. Koca, D. S. Celik, *Mod. Rheumatol.* **2021**, 31, 817.
- [17] R. Forte, H. Haulani, A. Dyrda, I. Jurgens, *Br. J. Ophthalmol.* **2021**, 105, 1297.
- [18] D. Ozek, M. Onen, E. E. Karaca, A. Omma, O. E. Kemer, C. Coskun, *Eur. J. Ophthalmol.* **2019**, 29, 532.
- [19] D. G. Scott, P. A. Bacon, C. Allen, C. J. Elson, T. Wallington, *Clin. Exp. Immunol.* **1981**, 43, 54.
- [20] K. Wakabayashi, K. Otsuka, M. Sato, R. Takahashi, T. Odai, T. Isozaki, N. Yajima, Y. Miwa, T. Kasama, *Mod. Rheumatol.* **2012**, 22, 59.
- [21] K. Ayar, M. E. Can, N. Koca, D. S. Celik, *Mod. Rheumatol.* **2021**, 31, 817.
- [22] W. van Eden, M. Jansen, I. S. Ludwig, P. Leufkens, M. C. van der Goes, J. M. van Laar, F. Broere, *Front. Immunol.* **2019**, 10, 279.
- [23] A. Fleischman, Y. Oron, O. Geyer, *J. Ocul. Pharmacol. Ther.* **2014**, 30, 634.
- [24] S. Bernatsky, C. Pineau, L. Joseph, A. Clarke, *J. Rheumatol.* **2003**, 30, 1756.
- [25] D. Ozek, M. Onen, E. E. Karaca, A. Omma, O. E. Kemer, C. Coskun, *Eur. J. Ophthalmol.* **2019**, 29, 532.
- [26] G. Liu, K. Keyal, F. Wang, *Sci. Rep.* **2017**, 7, 16297.
- [27] D. Ozek, M. Onen, E. E. Karaca, A. Omma, O. E. Kemer, C. Coskun, *Eur. J. Ophthalmol.* **2019**, 29, 532.

- [28] M. S. Trenkic Bozinovic, G. S. Babic, M. Petrovic, J. Karadzic, T. Š. Vulovic, M. Trenkic, *J. Res. Med. Sci.* **2019**, *24*, 55.
- [29] M. G. Lee, S. J. Kim, D. I. Ham, S. W. Kang, C. Kee, J. Lee, H. S. Cha, E. M. Koh, *Invest. Ophthalmol. Vis. Sci.* **2014**, *56*, 396.
- [30] C. C. McCormick, A. R. Caballero, C. L. Balzli, A. Tang, A. Weeks, R. J. O'Callaghan, *Curr. Eye Res.* **2011**, *36*, 14.

How to cite this article: L.-Q. Liu, W.-Q. Shi, J. Chen, Q.-J. Li, Qian-Ling, H. Wei, S. H. Xu, M. Kang, H. Huang, X. Chen, Y.-X. Wang, Y. Shao, *J. Biophotonics* **2023**, e202300133. <https://doi.org/10.1002/jbio.202300133>