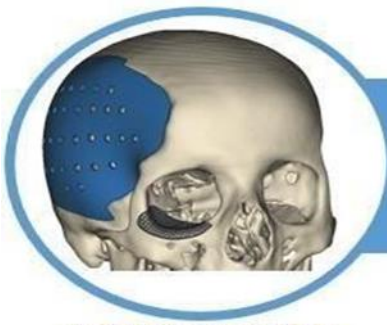



BONE ANATOMY OF THE PECTORAL GIRDER GIRDLES, THORACIC LIMB, PELVINA WAIST AND PELVINO LIMB OF *Chellus fimbriatus* (SCHNEIDER, 1783) (Reptilia: Chelidae).

Mariluce Ferreira Romão¹, André Luiz Quagliatto Santos², Thaís Aparecida Silva³

ORIGINAL ARTICLE

ABSTRACT

Testudines or queloniums generally have similar morphological characteristics. Chelonians belong to the group of reptiles, to the subclass Anapsidia, as well as to the order Chelonia or Testudinata. *Chellus fimbriatus* (Schneider 1783) is a typical South American turtle, and popularly known as mata-mata. It is a species considered exotic, in view of its external appearance, with projections in fibrillated or nailed. Differentiated skin helps, very much, in camouflage in the middle of its native environment. The osteology of the pectoral and pelvina waist, as well as the zeugopodium, stylepodium and autopodium of the thoracic and pelvino limb of *Chellus fimbriatus*, present similar patterns in relation to testudines in general. The most prominent morphological difference refers to the skin with nailed or fibrillated projections. Above all, it is important to highlight that the knowledge of the anatomy of wild animals favors the interventions of veterinarians, since it makes possible more assertive actions, which result in better prognoses, in addition to greater longevity of these animals.

Keywords: Appendicular members. Mata-mata. Osteology.

Instituição afiliada – 1- Docente do Centro Universitário de Patos de Minas, Patos de Minas (MG); Pós-doutora pela Universidade Federal de Uberlândia, Uberlândia (MG). 2- Docente da Universidade Federal de Uberlândia, Uberlândia (MG). 3- Universidade Federal de Uberlândia (UFU)

Dados da publicação: Artigo recebido em 02 de Julho e publicado em 12 de Agosto de 2023.

DOI: <https://doi.org/10.36557/2674-8169.2023v5n4p471-481>

Autor correspondente: Mariluce Ferreira Romão - marilucef@unipam.edu.br

This work is licensed under a [Creative Commons Attribution 4.0 International License](https://creativecommons.org/licenses/by/4.0/).





INTRODUCTION

Testudines or quelonians generally have similar morphological characteristics. Chelonians belong to the group of reptiles, to the subclass Anapsidia, as well as to the order Chelonia or Testudinata. In these animals, some anatomical specificities can be highlighted, such as the way of retracting the head into the carapace, in Cryptodira, happens with the verticalized recoil of the neck by the limbs, taking them into the hull, while, in Pleurodira, the neck is collected into the carapace, with lateral flexion (Boyer and Boyer 2006; Cubas et al. 2014; Carvalho et al. 2021).

The skeletal system of testudines is divided into: endoskeleton, consisting of intrinsic bones, as well as the exoskeleton formed by the carapace and plastron. The endoskeleton (skull, vertebrae and ribs; forelimbs, posterior and pelvic girdle), as it is also observed in fish, it's subdivided into axial part and appendicular part. Turtles have around 40 to 50 vertebrae, as well as their ribs are developed along with the costal plates of the carapace (Lopes et. al. 2021).

The Chellus fimbriatus (Schneider 1783) is a typical South American turtle, and popularly known as mata-mata. It is a species considered exotic, in view of its external appearance, with projections in fibrillated or nailed. The differentiated skin of *Chellus fimbriatus* helps, in camouflage in the midst of its native environment, protecting it against capture, especially for consumption or feeding purposes (Borges et. al. 2017; Silva et. al. 2018; Oliveira et. al. 2020).

Despite the peculiar appearance of the forest, as well as its wide distribution in northern South America, it is a little explored species, in relation to its natural history, biogeography, state of conservation and general morphology (Vargas-Ramírez et. al. 2020).

The present study aimed to describe the anatomy of the pectoral waist, thoracic limb, pelvina waist and pelvino limb of *Chellus fimbriatus* (Schneider 1783) (Reptilia: Chelidae). The benefits of the research are related to the contribution, both with conservation projects, as well as to preventive, therapeutic medicine, and management of the described species.

MATERIAL AND METHODS



Two specimens of *Chellus fimbriatus*, adults and females, which belong to the collection of the Laboratory of Teaching and Research in Wild Animals, fixed in 10% formaldehyde were used.

The development of the study did not present risks to *Chellus fimbriatus* specimens that were used in the research, since there were no actions contrary to the welfare of these animals, in any stage of capture, maintenance, release and euthanasia, especially absent in the development of this research, because the animals were already part of the Laboratory of Teaching and Research in Wild Animals collection.

The two copies of *C. fimbriatus* underwent previous descarte, as well as submitted to the process of boiling macerated, and submersion in hydrogen peroxide solution, at 20 volumes. Once satisfactory clarification was reached, bone accidents were identified and described as the main scope of this study (Brandão et. al., 2002; Silveira et al., 2008).

RESULTS

The pectoral and pelvina waist, as well as the zeugopodium, podium style and autopodium of both the thoracic limb and *chellus fimbriatus pelvino* are presented in Tables 1, 2, 3 and 4, as well as in Figure 1 and 2, with emphasis on its main characteristics.

Table 1 – Chest Waist Bones, Zeugopodium and Chellus *fimbriatus* Thoracic Limb Style podium.

BONE	FEATURES/JOINTS
Scapula	Dorsal and lateral toward the carapace. It designs an acromial process, which articulates with the coracoid and humerus.
Coracoid	Caudal and medial in relation to the glenoid cavity. It articulates with coracoid and humerus.
Acromial process	Dorsal and ventral towards the plastron. It articulates with the scapula forming 90°.
Humerus (Zeugopodium)	It articulates with proximal glenoid cavity, and with the radius and distal ulna.
Radius (cranial stylopodium)	It articulates with the proximal humerus, with the carpal bones (carpal intermediate, carpal central II, and distal carpal I), distal, and ulna in the dorsal region.



Ulna (caudal stylopodium)	It articulates with the proximal humerus, and with the bones of the distal carpal (carpal intermediate, carpal ulnar and carpal pisiform).
------------------------------	--

Table 2 – Bones of the Autopodium of the Thoracic Limb of *Chellus fimbriatus*.

BONES	FEATURES/JOINTS
Carpus: Proximal row	It consists of the middle bone of the carpal, which articulates proximally between the distal extremities of the radius and ulna. Distally, they articulate with the central bone of the carpal II, III, and with the ulnar of the carpal, in a restricted region, respectively.
Carpus: Middle row	It consists of the central bone of the carpal II, III, ulnar of the carpal and pisiform of the carpal. Proximally, they articulate with the radius, middle of the carpal, ulnar and psiform of the carpal. Distally, they articulate with the distal bones of the carpal: I, II, III, IV and IV.
Carpus: Distal row	It consists of the carpal's distalus bones: I, II, III, IV and V. Proximally, articulate with the radius bone, central carpal 2, 3, and ulnar of the carpal. Distally, they articulate with metacarpals I, II, III, IV and V.
Metacarpos: I, II, III, IV e V	They articulate with the carpal bones in the proximal extremities, and with the proximal phalanges, in their distal extremities.
Phalanges: Proximal, middle and distal	The fifth finger has two phalanges, and the others have three phalanges. Proximal phalanges are shorter than averages, except on finger I. Follow the following formula: 2:3:3:3:3. Most of them are similar, as to the shape and dimensions, the smaller ones being and smothered by cornified tissue, differentiated in claw.

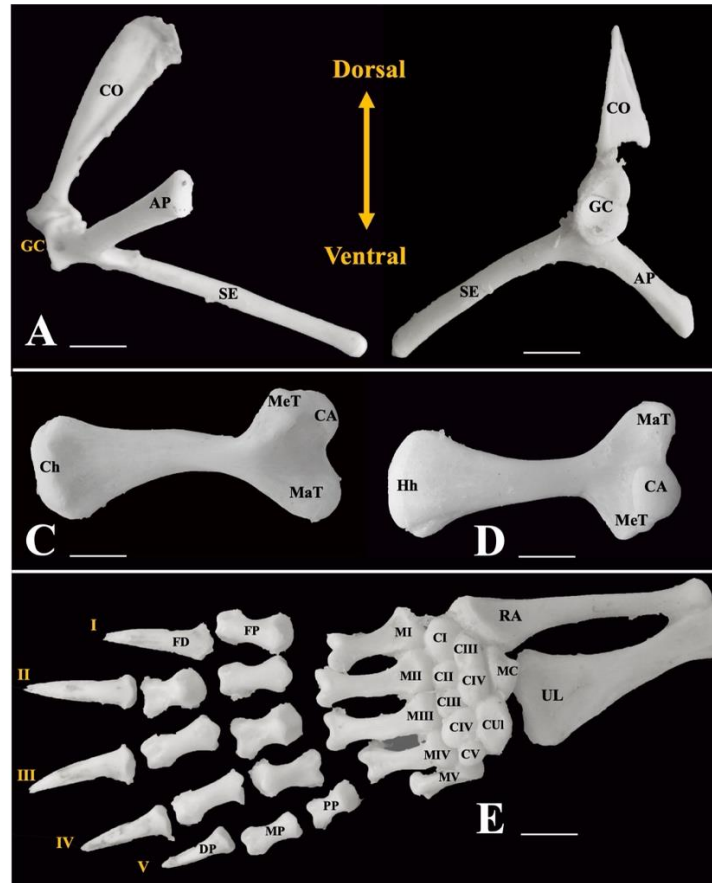


Figure 1 - Chest Waist Bones, Zeugopodium, Stylepodium and Autopodium of the Thoracic Limb of *Chellus fimbriatus*. A: Pectoral waist in Medial view. B: Pectoral waist in Medial view. CO, coracoide; AP, acromial process; SE, scapula; GC, glenoid cavity. C: Humerus in dorsal view. D: Humerus in ventral view. Hh, humerus head; MaT, major tuber; St, smaller tuber; Ch, condyl of the humerus. E: Stylepodium and autopodium in dorsal view. RA, radius; UL: ulna; MC, middle carpal; CUI, carpal ulnar; CI - V, carpal I-V tass; MI - V, metacarpals I - V; PP, proximal phalanx; MP, middle phalanx; DP, distal phalanx, FI - V, finger I - V. b*ScaleBar = 2cm.

Table 3 – Pelvina, Zeugopodium and *Chellus fimbriatus* Limb Style.

BONE	FEATURES/JOINTS
Ilium	It forms the dorsal and caudal part of the acetabulum.
Ischium	It forms the ventral and caudal part of the acetabulum.
Pubis	It forms the ventral and cranial part of the acetabulum.
Femur	It articulates with tibia (ventral) and fibula (dorsal).
Tibia	It articulates with the fibula, with the ventral condyle of the femur, and distally with the tarsus (intermediate).
Fibula	The proximal articular surface articulates with the dorsal condyle of the femur and tibia, and distally with the tarsal bones (intermediate and fibular)

Table 4 – Bones of the Autopodium of the Pelvino Member of *Chellus fimbriatus*.

BONES	FEATURES/JOINTS
Tarsus	It consists of seven bones: mid-tarsal, tarsal fibular, and tarsal distal I, II, III, IV and v. Proximally, it articulates with the tibia and fibula, and distally with the metatarsal bones. The tarsal intermediate articulates proximally with the tibia and fibula, as well as distally with the fibular, distal to tarsal II, III, and IV, and central to the tarsal.
Metatarsos: I, II, III, IV e V	They articulate with the tarsus bones in their proximal extremities, and with the proximal phalanges, in their distal extremities.
Phalanges: Proximal, middle and distal	The fifth finger has two and the other three. Proximal phalanges are slightly shorter than averages, except on finger I. Follow the following formula: 2:3:3:3:3. Most of them are similar, as to the shape and dimensions, the smaller ones being, and smothered by cornified tissue, differentiated in claw.

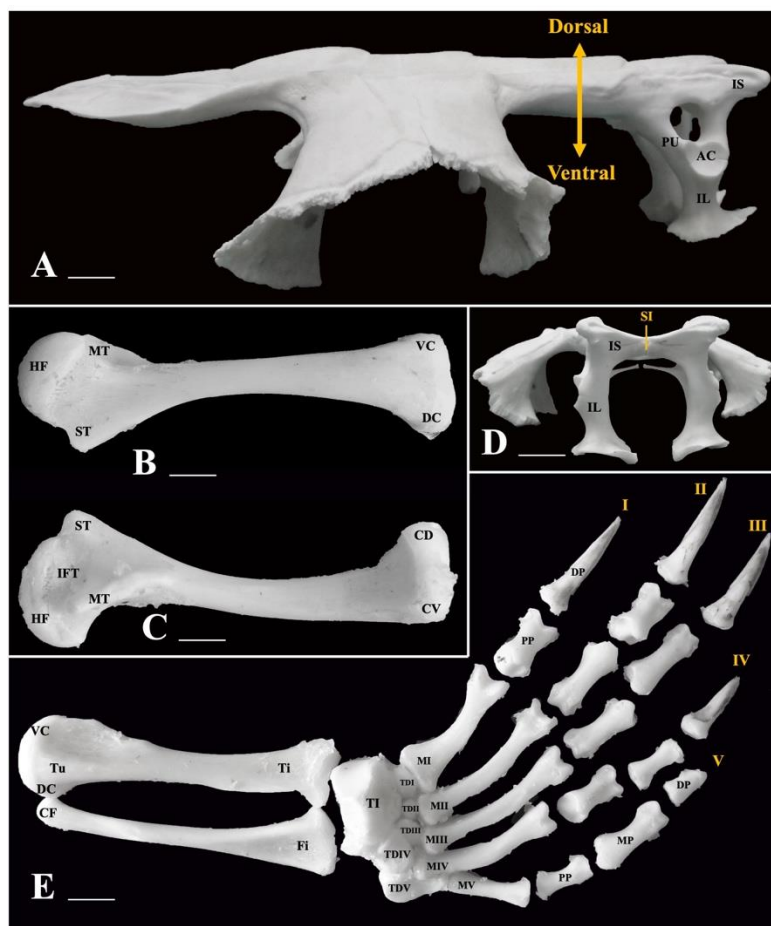


Figure 2 - Bones of the Pelvina Waist, Zeugopodium, Stylepodium and autopodium of the Pelvino Member of *chellus fimbriatus*. A: Pelvina waist in Side view. IS, ischium; IL, ilium; PU, pubis; AC, acetabula. B: Femur in dorsal view. HF, head of the femur; MT, major trochanter; ST, smaller trochanter; VC, Ventral condyle; VD; Dorsal condyl; IFT,



intertrocanteric fossa; Tu, tibial tuberosity. **C: Femur in ventral view. D: Pelvina waist in Cranial view.** PS, pubic symphysis. **E: Stylepodium and autopodium in dorsal view.** Ti, tibia; Fi, Fibula; TI, tarsus Intermediate; CT, tarsus central; TDI - V, tarsus distal I-V; MI - V, metatarsos I - V; PP, proximal phalanx; MP, middle phalanx; DP, distal phalanx. I - V, finger I - V. *ScaleBar = 2cm.

DISCUSSION

The anatomical characteristics considered more common of testudines or queloniums refer to the most developed appendicular skeleton, presenting five fingers, and the highest hull, with a concavity coated with yellow corneal plates, in the central region. In addition, the neck of these animals is collected in the caudal direction, as well as the paws and head have red scales. The pectoral and pelvina waist are found within the bony hoof, as a particularity observed in these animals (Birchard and Sherding 1998; Faria and Mariana 2001; Carvalho et al. 2021).

In the present study, scapula and coracoid present similar forms, however, different extensions, that is, although the scapula is perpendicular to the coracoid, as in most chelonians, *Chellus fimbriatus* presents the most extensive scapula, although with the same dimension in relation to the coracoid. In *Trachemys dorbignyi* (Souza et. al. 2000), as in *Podocnemes expansa* (Vieira 2008), the scapula is described with the same angular dimension of 90°, in relation to the coracoid (Walker 1973), and, on the other hand, the absence of the expansion of the costal end of the coracoid, as identified in *Chelonia mydas* (Lopes et. al. 2021), indicating good aquatic skills (Szalai 1932, 1933). In these, the greater trochanter of the femur is notably more developed, in relation to the smaller trochanter. In *Araripemys barretoii* (Carvalho et al. 2021) the scapula was observed forming an angle of approximately 60° in relation to the achromy. In *Trachemys dorbignyi* (Souza et. al. 2000), both the major trochanter and the smaller trochanter have similar characteristics, as well as in *Pseudemys scripta elegans* (Souza et. al. 2000), and in *Chellus fimbriatus*, in this study (Walker 1973).

The humerus of *Chelonia mydas* (Lopes et. al. 2021) presents a more prominent deltoide crest, in relation to what was observed in *Chellus fimbriatus*, in this study, corroborating a bone accident most prominent in most chelonians. This is a characteristic related to the improved aquatic skills (Goshe et. al. 2020).



In the young and adult *specimens of Trachemys dorbignyi* (Walker 1973), no fusions were identified between the proximal bones of the carpal and tarsus, different from the characteristics observed in *Pseudemys scripta elegans* (Souza et. al. 2000) and *Chrysemys* (Romer 1956). According to Walker (1973), the individualization of the proximal bones of the tarsus allows the distal rotation of the limb, observed in species with good aquatic abilities, such as *Grimace grimace* (1814) (Souza et. al. 2000), and *Eretmochelys imbricata* (1843) (Souza et. al. 2000).

As for the shape and arrangement of the metacarpals and metatarsis of the autopodium of the thoracic limb and pelvino limb of *Chellus fimbriatus*, they are identical to the description of *Trachemys dorbignyi* (Walker 1973), as well as in *Podocnemes expansa* (Vieira 2008) following the pattern identified in most chelonians (ROMER 1956; Walker, 1973). The phalanx formula identified in *Chellus fimbriatus* in this study was 2:3:3:3:3, as described in *Podocnemes expansa* (Vieira 2008), however, in *Trachemys dorbignyi* (Walker 1973) the formula was identified: 2:3:3:3:2. There is a great similarity between these characteristics observed in *Pseudemys scripta elegans* (Souza et. al. 2000), however, the absence of fusion of the carpals and tarsans is observed, added to the presence of claws associated with all the distal phalanges of the *trachemys dorbignyi* autopodium (Walker 1973).

The osteology of the pectoral and pelvina waist, as well as the zeugopodium, stylepodium and autopodium of the thoracic and pelvino limb of *Chellus fimbriatus*, present patterns identified in the skeletons of *Podocnemis unifilis* (Marques et. al. 2020), *Testudo europaea* (= *Emys orbicularis* Linnaeus, 1758), (Bojanus 1819-1821), *Testudo graeca* Linnaeus (1758) and *Testudo ibera Pallas* (1814) (Thomson 1932), as well as to the genera *Chelydra Schweigger* (1814), *Chrysemys* and *Pseudemys* (Ashley 1955), and *Clemmys marmorata Baird* and Girard (1852) (Noble and Noble 1940).

CONCLUSION

It is concluded that the theology of the pectoral and pelvina waist, as well as the zeugopodium, stylepodium and autopodium of the thoracic limb and pelvino of *Chellus fimbriatus*, present similar patterns in relation to testudines in general. The most prominent



morphological difference refers to the skin with nailed or fibrillated projections. Above all, it is important to highlight that the knowledge of the anatomy of wild animals favors the interventions of veterinarians, since it makes possible more assertive actions, which result in better prognoses, in addition to greater longevity of these animals.

With the contemporary advent of turtles, having become pets, for example, in addition to the entire context related to the conservation of these species, it is clear the need for greater morphological knowledge, starting with the descriptions and anatomical correlations. Such studies are still very restricted to the older descriptions, which end up becoming timeless, in view of the scarcity of specific research, such as the osteology of the pectoral and pelvino waist, as well as the zeugopodium, stylepodium and autopodium of the thoracic and pelvino limb of *chellus fimbriatus*, presented in this research.

REFERENCES

- AHRANJANI, B. A. et. al. Anatomical, radiographical and computed tomographic study of the limbs skeleton of the Euphrates soft shell turtle (*Rafetus euphraticus*). **Veterinary Research Forum**. 2016, 7, (2):117 – 124.
- ASHLEY, L. M. **Laboratory Anatomy of the Turtle**. IOWA, WM.C. BROWM CO., 1955.
- BRANDÃO, C. V. S. et. al. Substituição do ligamento da cabeça do fêmur com auto-enxerto de fásia lata na luxação coxofemoral em cães. *Cienc. Rural*, Santa Maria, 2002, 2:275-280.
- BIRCHARD, S. J. and SHERDING, R. J. **Manual Saunders - Clínica de pequenos animais**. São Paulo: Roca, 1998.
- BOJANUS, L. H. **Anatome Testudinis Europaeae. Vilnae (reeditada pela Society for The Study of Amphibians and Reptiles (1970))**, 1819 – 1821.
- BORGES, L. M. et. al. *Herpetofauna da Universidade Federal de Santa Maria Campus Sede*. Pelotas (RS): USEB, 2017.
- BOYER, T.H. and BOYER, D.M. Turtles, tortoises and terrapins. In: MADER, D.R. **Reptile Medicine and Surgery**. 2. ed. Missouri: Saunders Elsevier, 2006.
- CARVALHO, S. R. T. C. et al. Quelônios. **Biol. Geral Exper**, 2021, 20/21(1): 49-55.
- CUBAS, Z. S. et. al. *Tratado de Animais Selvagens - Medicina Veterinária*. São Paulo: Editora Roca, 2014, v.2.
- FARIA, T. N. and MARIANA, A. B. Origens e ramificações das artérias aorta esquerda e dorsal do jabuti (*Geochelone carbonaria*, Spix, 1824). **Braz. J. Vet. Res. Anim. Sci.**, 2001, 38:155-159.



GOSHE, L. R. et. al. Protocol for processing sea turtle bones for age estimation. **NOAA, Technical Memorandum NMFS-SEFSC**, 2020, 746, p.1-49.

LOPES, E. Q. et. al. Descrição Anatômica Esquelética da tartaruga verde (*Chelonia Mydas*) proveniente de encalhe nas unidades de Conservação do Mosaico Jureia-Itatins, Estação Ecológica Tupiniquins e APACIP – Área de Proteção Ambiental Cananeia-Iguape-Peruíbe-SP. **Brazilian Journal of Animal and Environmental Research**, 2021, 4(4) 5441-5456, 2021.

MARQUES, D. A. et. al. **Atlas simplificado de osteologia da família podocnemididae.** - Manaus, 2020.

NOBLE, G. A. and E. R. NOBLE. **A Brief Anatomy of the Turtle.** Califomia, Stanford University Press, 1940.

OLIVEIRA, M. N. et. al. Exposições Científicas como Ferramenta de Obtenção de Dados para Desenvolvimento de Estratégias de Conservação de Quelônios Amazônicos. **Ensaio**, 2020, 24(3)289-292.

ROMER, A.S. **Osteology of the reptiles.** Chicago, Univ. Chicago Press, 1956.

SILVA, T. L. et al. Perspectivas de estudantes sobre a conservação de quelônios em uma escola da zona periférica de Cruzeiro do Sul - Acre. **Rev. Communitas**, 2018, 2(3) 304–313.

SILVEIRA, M. J. et al. Análise de processos alternativos na preparação de esqueletos para uso didático. **Acta Sci. Biol. Sci.**, Maringá, 2008, 4:465-472.

SOUZA, A. M. et. al. Estudo do esqueleto em *Trachemys dorbignyi* (Duméril; Bibron) (Reptilia, Testudines, Emydidae). *Revta bras. Zoor*, 2000, 17 (4): 1041-1063.

SZALAI, T. Biomechanische Untersuchungen am Schultergürtel der Testudinaten. **Ann. Naturhisl. Mus. Wie**, 1932-1933, 46:157-163.

THOMSON, L. S. The Anatomy of the Tortoise. **Sei. Proc. Royal Dublin Soc**, 1932, 20(28)359-461.

VARGAS-RAMÍREZ, M. et. al. As análises genômicas revelam duas espécies de matamata (Testudines: Chelidae: *Chellus* spp.) E esclarecem sua filogeografia. **Molecular Phylogenetics and Evolution**, v. 148, 2020.

VIEIRA, L. G. **Ontogenia dos ossos do esqueleto da tartaruga da Amazônia *Podocnemis expansa* (Shweigger, 1812) (Testudines, Podocnemididae).** 152f. Dissertação apresentada à faculdade de Medicina Veterinária – UFU, como parte das exigências para obtenção do título de Mestre em Ciências Veterinárias. 2008.

WALKER, L.R. and F. WARILLIN. **The Locomotor Apparatus of Testudines.** In: C. GANS (Ed.). *Biology of Reptilia*. London, Academic Press. 1973.