

Case Report

Remitting Seronegative Symmetrical Synovitis with Pitting Edema: A Case Report of an Immune-Related Adverse Event following Surgery

Helena J. Janse van Rensburg^a Pavlina Spiliopoulou^b Anas Makhzoum^c
Brian D. Healy^d

^aDepartment of Internal Medicine, University of Toronto, Toronto, ON, Canada; ^bDepartment of Medical Oncology and Haematology, Princess Margaret Cancer Centre, University Health Network, Toronto, ON, Canada; ^cDepartment of Rheumatology, Trillium Health Partners, Mississauga, ON, Canada; ^dDepartment of Oncology, Juravinski Hospital and Cancer Centre, Hamilton Health Sciences, Hamilton, ON, Canada

Keywords

Cancer · Immunotherapy · Immune checkpoint inhibitor · Immune-related adverse event · Rheumatology · Remitting seronegative symmetrical synovitis with pitting edema · Surgery · Hip replacement · Case report

Abstract

Immune checkpoint inhibitors (ICIs) have emerged as a novel class of anti-neoplastic agent in oncology. Their integration into practice has been accompanied by “immune-related adverse events” (irAEs) wherein off-target immune responses damage healthy tissues. Severe irAEs can cause irreversible organ dysfunction and death. Despite this, little is known about factors which predispose certain patients to develop irAEs or which precipitate their onset. Here, we report a case of a patient with melanoma who completed adjuvant immunotherapy, underwent elective hip replacement, and developed a rare rheumatologic irAE (remitting seronegative symmetrical synovitis with pitting edema) post-operatively. Mechanistically, we hypothesize that surgery contributed to irAE pathogenesis as a sensitizing event in which self-antigens were presented to an immune system with diminished peripheral tolerance in the context of recent ICI administration. This case highlights a need for future correlative analyses, investigating whether iatrogenic interventions such as surgery might be associated with irAE development.

© 2023 The Author(s).
Published by S. Karger AG, Basel

Correspondence to:
Helena J. Janse van Rensburg, ellen.jansevanrensburg@mail.utoronto.ca

Introduction

Immune checkpoint inhibitors (ICIs) have become commonly applied therapies in a variety of cancers. The integration of antibodies targeting CTLA-4 and PD-1/PD-L1 into management algorithms has represented a paradigm shift in oncology, not only due to the durable clinical responses observed with these agents but also because of their distinctive adverse effects [1]. Unlike cytotoxic and targeted therapies, for which adverse effects are predictable and temporally related to dose administration, immune-related adverse events (irAEs) associated with immunotherapies can affect any organ system and can even occur several months after treatment cessation.

Severe irAEs can lead to high levels of morbidity and even fatal events. Given this, there has been interest in understanding factors which determine ICI response and irAE development, to inform risk/benefit discussions and support clinical decision-making. Several patient-intrinsic factors affecting efficacy and toxicity have been identified [2–6]. Less is known about patient-extrinsic factors contributing to irAE development. Although concurrent systemic treatments and radiotherapy have been associated with increased risk in certain contexts, whether other interventions such as surgery might precipitate an irAE is unknown [2, 7].

Remitting seronegative symmetrical synovitis with pitting edema (RS3PE) is a rare rheumatologic syndrome [8]. Although there are no absolute diagnostic criteria, RS3PE often presents as pitting edema in the limbs and acute symmetrical polyarthritis in adults over 50 years old. Male predominance, elevated acute phase reactants, rheumatoid factor negativity, and rapid response to steroids (and/or disease-modifying anti-rheumatic agents, e.g., methotrexate) are also characteristic of the diagnosis, and distinguish RS3PE from other rheumatologic diseases, although notable exceptions have been described [9, 10]. The exact mechanisms underlying the pathogenesis of RS3PE have not yet been elucidated; however, it is generally characterized as an inflammatory phenomenon. RS3PE has been reported as a paraneoplastic syndrome and has also been recognized as an irAE after ICI in two prior case reports [11, 12].

Here, we present a case of a man with melanoma who received adjuvant ICI therapy and developed RS3PE post-operatively after a hip replacement. This case raises the possibility that surgery may act as an inciting event in irAE development and underscores the need for future work interrogating this hypothesis.

Case Presentation

A male patient in his 70s with a medical history of hypertension, obstructive sleep apnea, and osteoarthritis was diagnosed with stage 3a cutaneous melanoma (*BRAF* wildtype, *NRAS* mutated). He had a remote surgical history of tibia/fibula fracture and inguinal hernia repairs. He had no personal or family history of autoimmune disease. He underwent wide local excision of the primary melanoma and sentinel lymph node biopsy followed by 1 year of adjuvant PD-1 inhibition with nivolumab. After four cycles, he developed grade 1 rash which was treated with topical hydrocortisone. He further experienced ICI-related hypothyroidism after his ninth cycle and was started on thyroid hormone replacement. He completed 13 total cycles and has remained on surveillance since, with no clinical or radiographic evidence of recurrence to the present day.

Three weeks after receiving his last dose of nivolumab, the patient underwent an elective uncemented right total hip replacement with bone graft to the acetabulum under spinal anesthetic for osteoarthritis. The surgery was uncomplicated, and the patient remained as an

inpatient post-operatively for mobilization. Upon waking from general anesthesia, he noted new bilateral ankle swelling as well as severe left leg pain. On post-operative day one, he further experienced symptomatic orthostatic hypotension. Despite this, he was deemed medically fit for discharge and returned home after one night in hospital.

After discharge, the patient's condition substantially deteriorated. His peripheral edema progressed to involve all four extremities and became functionally impairing (Fig. 1a). He developed bilateral ankle, knee, wrist, and hand pain with intense hyperalgesia and morning stiffness. Associated fatigue and generalized weakness rendered him largely bedbound. When attempting ambulation, he described symptomatic orthostatic hypotension concordant with 20–30 mm Hg systolic blood pressure drops on home measurements. There was no history of fever, rash, focal infectious symptoms, syncope, palpitations, dyspnea, or hemoptysis.

After 2 weeks of progressive symptoms, baseline blood investigations were ordered by the patient's primary care provider. Post-operative infection was suspected due to neutrophilia of $9.9 \times 10^9/L$; thus, a course of quinolone antibiotic was prescribed. Concurrent polyarticular gout was also considered for which non-steroidal anti-inflammatory medication was suggested. Both medications were taken as directed without interval improvement.

Three weeks after surgery, the patient presented to the emergency department due to persistent symptoms. Physical exam revealed an afebrile, normotensive male with orthostatic systolic blood pressure drop of 40 mm Hg, pitting edema to all limbs, as well as swollen and tender bilateral ankles and right wrist joints. An admission to the internal medicine ward was deemed necessary for further assessment and management.

Upon admission, a wide differential diagnosis was considered including infection, renal or liver dysfunction, endocrinopathy, cardiac decompensation, venous thromboembolism, and rheumatologic disease. Key investigations are summarized in Table 1. In brief, the patient had a normocytic anemia with hemoglobin 104 g/L (pre-operative: 143 g/L). There was a mild neutrophilia and thrombocytosis. Renal and liver profiles were within normal limits. Hypoalbuminemia of 28 g/L was noted (pre-operative: 43–48 g/L). Two sets of blood cultures did not show any growth. Arthrocentesis for synovial fluid analysis was not performed. Troponin and B-type natriuretic peptide were both negative. Vitamin B12, glycosylated hemoglobin, triglycerides, thyroid-stimulating hormone, morning cortisol, adrenocorticotrophic hormone, uric acid, and creatine kinase were all within normal limits. 0,25-vitamin D was low. Serum protein electrophoresis revealed a small unquantifiable M protein.

Transthoracic echocardiogram showed normal biventricular size and function. Diastolic function was mildly impaired, but with normal filling pressures. There was no significant valvular disease. Doppler ultrasounds and CT pulmonary angiography were negative for deep vein thrombosis and pulmonary embolus, respectively. Ankle-brachial indices were normal.

Finally, ferritin, erythrocyte sedimentation rate (ESR), and C-reactive protein (CRP) were all markedly elevated. Rheumatoid factor returned weakly positive at 16 IU/mL (normal ≤ 14 IU/mL); however, cyclic citrullinated peptide was negative. Anti-nuclear antibody, anti-neutrophil cytoplasmic antibodies, and human leukocyte antigen-B27 were negative. X-rays of the affected joints were not performed.

With no etiology for orthostatic hypotension identified, a supportive approach to management was taken. The patient's postural symptoms resolved with initiation of midodrine and fludrocortisone, and he was discharged home without improvement in his peripheral edema. The possibility of an inflammatory arthritis was raised given the constellation of joint pain and elevated inflammatory markers; therefore, a referral to outpatient rheumatology was arranged. In the interim, the patient's primary care provider initiated a trial of oral diuretic with no response.

Two months after symptom onset, the patient was seen by a rheumatologist who established the diagnosis of RS3PE. The patient was started on prednisone (20 mg daily) which

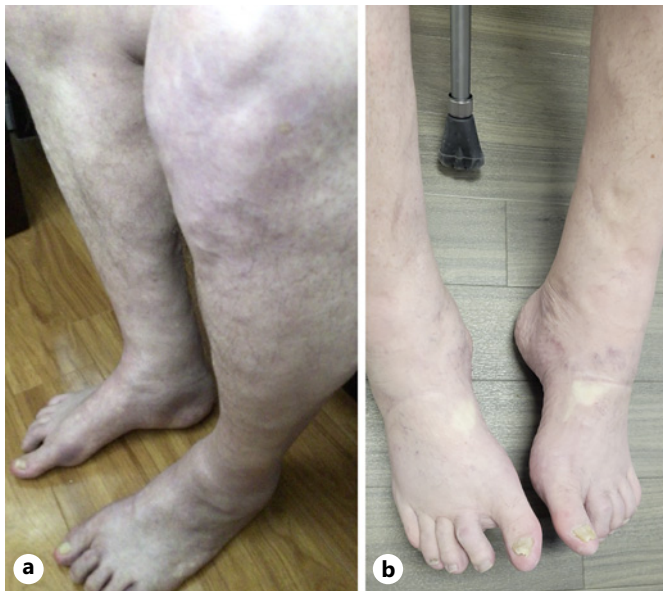

Fig. 1. a Lower extremity peripheral edema as a symptom of RS3PE after immune checkpoint inhibitor therapy and elective hip replacement surgery. **b** Interval improvement in lower extremity peripheral edema after 2 months of prednisone therapy.

resulted in rapid improvement in his weakness, joint pain, and peripheral edema. Blood collection was repeated after 2 weeks of steroids which revealed improving inflammatory markers (CRP 44.9 mg/L from 183 mg/L, ESR 65 mm/h from 113 mm/h) and hypoalbuminemia (36 g/L from 28 g/L). He was able to discontinue midodrine, fludrocortisone, and furosemide without recurrent symptoms. After 4 months of follow-up, the patient was reported to be continuing a steroid taper with a transition to methotrexate underway. He endorsed mild residual ankle swelling and joint discomfort but was otherwise working to return to his functional baseline (Fig. 1b, 2).

Discussion

Here, we describe a case of a patient who developed RS3PE after adjuvant ICI for melanoma and elective orthopedic surgery. The diagnosis of RS3PE occurred 2 months after symptom onset, after three prior episodes of health care contact, and required outpatient specialist assessment. RS3PE is indeed an exceedingly rare diagnosis with many rheumatologists only seeing a handful of such cases in their careers. However, a constellation of signs and symptoms may raise the possibility of this syndrome, allowing for more prompt recognition and treatment. Notably, our patient's abrupt onset of peripheral edema in combination with synovitis was characteristic of RS3PE. His significantly elevated inflammatory markers including ferritin, ESR, and CRP pointed to an underlying inflammatory state driving his presentation. Furthermore, the lack of improvement in peripheral edema with oral diuretics despite normal renal function and no history of previous diuretic resistance was suggestive of a secondary underlying cause. Finally, the gradual improvement in his symptoms with initiation of prednisone was again supportive of an inflammatory cause for his presentation and argued against a more frequently observed differential diagnosis of polymyalgia rheumatica, which should rapidly resolve after several days of steroids. Collectively,

Table 1. Results of bloodwork sent at presentation to emergency department

Complete blood count	
Hemoglobin	104 g/L (MCV 87.4 fL)
Leukocytes	11.1 × 10⁹/L
Neutrophils	7.8 × 10⁹/L
Platelets	520 × 10⁹/L
Creatinine	57 µmol/L
Urea	4.3 mmol/L
Electrolytes	
Sodium	137 mmol/L
Potassium	4.2 mmol/L
Chloride	100 mmol/L
Bicarbonate	29 mmol/L
Blood glucose	7.2 mmol/L
Liver profile	
AST	24 U/L
ALT	35 U/L
Total bilirubin	7.6 µmol/L
INR	1.3
Albumin	28 g/L
Troponins	3 ng/L
BNP	25 ng/L
Vitamin B12	400 pmol/L
0,25-vitamin D	40.2 nmol/L
A1C	6.30%
Triglycerides	1.21 mmol/L
TSH	1.72 mIU/L
AM cortisol	253 nmol/L
ACTH	4.5 pmol/L
SPEP	Unquantifiable M protein
Uric acid	176 µmol/L
CK	35 U/L
Ferritin	1,330 µg/L
ESR	113 mm/h
CRP	183 mg/L
RF	16 IU/mL
CCP	<0.5 U/mL
ANA	Negative
ANCA	Negative
HLA-B27	Negative

Abnormal values are denoted in bold font.

AST, aspartate aminotransferase; ALT, alanine transaminase; INR, international normalized ratio; BNP, B-type natriuretic peptide; A1C, glycosylated hemoglobin A1C; TSH, thyroid-stimulating hormone; AM cortisol, morning cortisol; ACTH, adrenocorticotropic hormone; SPEP, serum protein electrophoresis; CK, creatine kinase; ESR, erythrocyte sedimentation rate; CRP, C-reactive protein; RF, rheumatoid factor; CCP, cyclic citrullinated peptide; ANA, anti-nuclear antibody; ANCA, anti-neutrophil cytoplasmic antibodies; HLA-B27, human leukocyte antigen-B27.

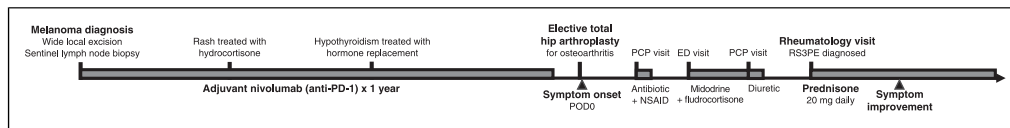


Fig. 2. Timeline of key events in patient's presentation, diagnosis, and treatment. ED, emergency department; NSAID, non-steroidal anti-inflammatory drug; PCP, primary care provider.

these observations secured the diagnosis of RS3PE and allowed our patient to receive appropriate treatment.

Orthostatic hypotension was a predominant and interesting aspect of our patient's presentation. Importantly, this has not been reported as a common feature of RS3PE and should not be relied upon to rule in or rule out this diagnosis. In fact, there are only rare descriptions of orthostasis in the context of autoimmune disease, where inflammation may be linked to autonomic dysfunction [13, 14]. Nonetheless, as no other cause for orthostasis was identified during our patient's comprehensive work-up, and given that this symptom resolved with steroids, we do suspect that this was attributable to RS3PE.

RS3PE has been reported as a paraneoplastic phenomenon. A recent review of 38 publications pertaining to RS3PE has described cancer as a relatively frequent occurrence among patients with this syndrome [15]. Other reports have suggested that a diagnosis of RS3PE should prompt investigation for possible underlying malignancy, particularly when symptoms are refractory to moderate doses of steroids [9]. When occurring in a paraneoplastic manner, cancer-directed treatments (i.e., surgery, radiation, systemic therapies) form a key part of management of the rheumatologic presentation. Interestingly, ICI therapy has been successfully employed in this manner, with one prior case report describing a patient with non-small cell lung cancer experiencing partial improvement in RS3PE symptoms after starting pembrolizumab [16].

Given the timeline of our patient's symptom onset, we hypothesize that recent ICI administration was a factor in his development of RS3PE. Two similar descriptions in patients receiving nivolumab for metastatic melanoma have been published. In one, a male patient in his 80s developed RS3PE after two cycles of nivolumab and rapidly improved once prescribed prednisone [11]. Although the patient required 9 months of tapering steroids, he was able to resume nivolumab 4 weeks after starting prednisone without symptomatic relapse. In another case report, a male patient in his 70s developed RS3PE after approximately eight cycles of nivolumab [12]. This patient's melanoma demonstrated a complete response to immunotherapy, thus the authors of this report argued that paraneoplastic RS3PE was an unlikely etiology for his presentation. We similarly reason that an alternative explanation of paraneoplastic RS3PE for our patient would be unlikely as he had no evidence of active malignancy at his symptom onset.

Moreover, our patient developed RS3PE after elective orthopedic surgery. Post-operative RS3PE after urologic surgery has been described in one prior case report [17]. Little is known about the safety of surgery around ICI administration. From a mechanistic perspective, it is conceivable that local trauma during surgery might allow for the release of self-antigens and co-stimulatory inflammatory molecules, leading to immune sensitization when peripheral tolerance mechanisms have been diminished by ICI. Concordant with this hypothesis, Zhao et al. [18] have published a report of a patient with locally advanced non-small cell lung cancer receiving nivolumab who developed pneumonitis requiring ICU admission 1 week after lobectomy. Two other similar, albeit milder, cases of ICI-related interstitial lung disease after thoracic surgery for non-small cell lung cancer have been reported [19, 20]. Likewise, Sasaki et al. [21] have reported a case of ICI-related hypopituitarism and hypothyroidism 4 days after partial hepatectomy for liver metastases in a patient with gastric cancer treated with

pembrolizumab. In contrast to each of these cases, where surgery was undertaken for cancer management, our patient developed an irAE after an elective surgery, which might have been postponed if an increased risk of irAE was anticipated. At present, there are no guidelines or literature that can be used to inform such a recommendation.

Future observational studies will be necessary to test any potential causative relationship between medical interventions such as surgery and irAEs. Presumably, this hypothesis would be amenable to interrogation within a retrospective case-control study format. Further research will also be needed to identify other potential precipitants for irAE development. Given the significant burden of irAEs for patients both in terms of morbidity and mortality, ongoing work in this area is certainly justified.

Conclusions

To the best of our knowledge, this is the first case report of a patient who developed RS3PE after immunotherapy and surgery. Although the relative contributions of each of these factors toward the patient's presentation are unknown, we offer this description in a hypothesis-generating manner which may provide a rationale for future correlative analyses. Future work exploring patient-extrinsic and modifiable factors prompting irAE pathogenesis is needed.

The CARE checklist has been completed by the authors for this case report and is attached as online supplementary Material (for all online suppl. material, see <https://doi.org/10.1159/000532004>).

Statement of Ethics

This retrospective review of patient data did not require ethical approval in accordance with local/national guidelines. Written informed consent was obtained from the patient for publication of this case report and accompanying images.

Conflict of Interest Statement

The authors have no conflicts of interest to declare.

Funding Sources

This article received no external funding.

Author Contributions

H.J.J.V.R.: manuscript writing. P.S., A.M., and B.D.H.: manuscript revision.

Data Availability Statement

All data generated or analyzed during this study are included in this article and its online supplementary material. Further inquiries can be directed to the corresponding author.

References

- 1 Ramos-Casals M, Brahmer JR, Callahan MK, Flores-Chávez A, Keegan N, Khamashta MA, et al. Immune-related adverse events of checkpoint inhibitors. *Nat Rev Dis Primers*. 2020 May;6(1):38.
- 2 Liu X, Shi Y, Zhang D, Zhou Q, Liu J, Chen M, et al. Risk factors for immune-related adverse events: what have we learned and what lies ahead? *Biomark Res*. 2021 Nov;9(1):79.
- 3 Rizzo A, Cusmai A, Gadaleta-Caldarola G, Palmiotti G. Which role for predictors of response to immune checkpoint inhibitors in hepatocellular carcinoma? *Expert Rev Gastroenterol Hepatol*. 2022 Apr;16(4):333–9.
- 4 Di Federico A, Rizzo A, Carloni R, De Giglio A, Bruno R, Ricci D, et al. Atezolizumab-bevacizumab plus Y-90 TARE for the treatment of hepatocellular carcinoma: preclinical rationale and ongoing clinical trials. *Expert Opin Investig Drugs*. 2022 Apr;31(4):361–9.
- 5 Santoni M, Rizzo A, Kucharz J, Mollica V, Rosellini M, Marchetti A, et al. Complete remissions following immunotherapy or immuno-oncology combinations in cancer patients: the MOUSEION-03 meta-analysis. *Cancer Immunol Immunother*. 2023 Jun;72(6):1365–79.
- 6 Rizzo A, Cusmai A, Giovannelli F, Acquafredda S, Rinaldi L, Misino A, et al. Impact of proton pump inhibitors and histamine-2-receptor antagonists on non-small cell lung cancer immunotherapy: a systematic review and meta-analysis. *Cancers*. 2022 Mar;14(6):1404.
- 7 Bang A, Wilhite TJ, Pike LRG, Cagney DN, Aizer AA, Taylor A, et al. Multicenter evaluation of the tolerability of combined treatment with PD-1 and CTLA-4 immune checkpoint inhibitors and palliative radiation therapy. *Int J Radiat Oncol Biol Phys*. 2017 Jun;98(2):344–51.
- 8 McCarty DJ, O'Duffy JD, Pearson L, Hunter JB. Remitting seronegative symmetrical synovitis with pitting edema. RS3PE syndrome. *JAMA*. 1985 Nov;254(19):2763–7.
- 9 Varshney A, Singh N. Syndrome of remitting seronegative symmetrical synovitis with pitting edema: a case series. *J Postgrad Med*. 2015;61(1):38–41.
- 10 Finnell JA, Cuesta IA. Remitting seronegative symmetrical synovitis with pitting edema (RS3PE) syndrome: a review of the literature and a report of three cases. *J Foot Ankle Surg*. 2000 May;39(3):189–93.
- 11 Gauci M-L, Baroudjian B, Laly P, Madelaine I, Da Meda L, Vercellino L, et al. Remitting seronegative symmetrical synovitis with pitting edema (RS3PE) syndrome induced by nivolumab. *Semin Arthritis Rheum*. 2017 Oct;47(2):281–7.
- 12 Ngo L, Miller E, Valen P, Gertner E. Nivolumab induced remitting seronegative symmetrical synovitis with pitting edema in a patient with melanoma: a case report. *J Med Case Rep*. 2018 Feb;12(1):48.
- 13 Tang S, Calkins H, Petri M. Neurally mediated hypotension in systemic lupus erythematosus patients with fibromyalgia. *Rheumatology*. 2004 May;43(5):609–14.
- 14 Johansson M, Ricci F, Aung N, Sutton R, Melander O, Fedorowski A. Inflammatory biomarker profiling in classical orthostatic hypotension: insights from the SYSTEMA cohort. *Int J Cardiol*. 2018 May;259:192–7.
- 15 Lakhmalla M, Dahiya DS, Kichloo A, Fatima T, Edigin E, Wani F. Remitting seronegative symmetrical synovitis with pitting edema: a review. *J Investig Med*. 2021 Jan;69(1):86–90.
- 16 Aoshima Y, Karayama M, Sagisaka S, Yasui H, Hozumi H, Suzuki Y, et al. Synchronous occurrence of bazex syndrome and remitting seronegative symmetrical synovitis with pitting edema syndrome in a patient with lung cancer. *Intern Med*. 2019 Nov;58(22):3267–71.
- 17 Tunc SE, Arslan C, Ayvacioglu NB, Sahin M, Akkus S, Yorgancigil H. Paraneoplastic remitting seronegative symmetrical synovitis with pitting edema (RS3PE syndrome): a report of two cases and review of the literature. *Rheumatol Int*. 2004 Jul;24(4):234–7.
- 18 Zhao H, Ning J, Gu Y, Zhang X, Yu W, Chen T, et al. Consecutive severe immune-related adverse events after PD-1 inhibitor induction and surgery in locally advanced non-small cell lung cancer: a case report. *Transl Lung Cancer Res*. 2021 Aug;10(8):3682–8.
- 19 Xu Y, Lyu X, Qin Y, Ma D, Wang M, Shi J, et al. Multi-organs perioperative immune-related adverse events and postoperative bronchial anastomotic fistula in a patient receiving neoadjuvant immunotherapy with NSCLC. *Thorac Cancer*. 2022 Aug;13(16):2340–5.
- 20 Fujita T, Hayama N, Kuroki T, Shiraishi Y, Amano H, Nakamura M, et al. Pembrolizumab-induced interstitial lung disease following thoracic surgery in a patient with non-small cell lung cancer. *Thorac Cancer*. 2019 Nov;10(11):2179–82.
- 21 Sasaki K, Kobayashi S, Kudo M, Sugimoto M, Takahashi S, Nakamura Y, et al. Hypothyroidism and hypopituitarism as immune-related adverse events due to lenvatinib plus pembrolizumab therapy in the immediate postoperative period after laparoscopic hepatectomy for liver metastases from gastric cancer: a case report. *Surg Case Rep*. 2021 Dec;7(1):267.