

This is a provisional PDF only. Copyedited and fully formatted version will be made available soon.

# REPORTS OF PRACTICAL ONCOLOGY AND RADIOTHERAPY

**ISSN:** 1507-1367

**e-ISSN:** 2083-4640

## **Esophageal cancer — the utility of PET/CT in staging prior to chemoradiation**

**Authors:** Adam Deja, Marcin Włodarczyk

**DOI:** 10.5603/rpor.96869

**Article type:** Research paper

**Published online:** 2023-08-10

This article has been peer reviewed and published immediately upon acceptance. It is an open access article, which means that it can be downloaded, printed, and distributed freely, provided the work is properly cited.

## Esophageal cancer — the utility of PET/CT in staging prior to chemoradiation

[10.5603/rpor.96869](https://doi.org/10.5603/rpor.96869)

Adam Deja<sup>1</sup>, Marcin Włodarczyk<sup>2</sup>

<sup>1</sup>*Radiotherapy Department, Greater Poland Cancer Center, Poznań, Poland*

<sup>2</sup>*Breast Surgical Oncology Department, Greater Poland Cancer Centre, Poznań, Poland*

**Corresponding author:** Adam Deja, M.D., Greater Poland Cancer Center, Radiotherapy Department, ul. Garbary 15, Poznań 61–866, Poland: e-mail: [adam.deja@wco.pl](mailto:adam.deja@wco.pl)

### Abstract

**Background and purpose:** Thorough staging plays a significant role in determining therapy modality in esophageal cancer patients. The aim of this study was to assess whether positron emission tomography/computed tomography (PET/CT) may be safely omitted in selected groups of patients.

**Materials and methods:** This retrospective analysis included 37 esophageal cancer patients recruited to chemoradiation by the Multidisciplinary Tumor Board (MTB) at the Greater Poland Cancer Center in 2021. Prior to radiotherapy planning every patient was referred to PET/CT to have the extent of their disease assessed.

**Results:** Among 37 patients PET/CT changed the staging status to metastatic (M1) in six cases (3 planoepithelial and 3 adenocarcinomas). In all those cases but one (1 patient with supraclavicular node metastasis finally received chemoradiation) confirmation of distant metastases excluded patients from radical treatment. Interestingly, in the PET/CT distant positive group 3 patients were initially staged as locally advanced (without nodal involvement). The other 3 were initially identified as at least N2 in tomography.

**Conclusion:** Results of this report allowed the conclusion that PET/CT plays a key role in esophageal cancer patients considered for radical chemoradiation; therefore, it remains a necessary tool to exclude metastatic disease in both main pathology types. Since the delayed time for PET/CT scan in esophageal cancer patients planned to chemoradiation may negatively influence treatment results, the data should be alarming for national health provider.

**Key words:** esophageal cancer; radiotherapy; chemoradiation; PET/CT

## **Introduction**

Definitive or preoperative chemoradiation remains the state of art treatment modality in most patients with locally or locoregionally advanced esophageal cancer [1–5]. Prior to radical treatment patients should undergo proper pre-treatment staging. This includes endoscopy with biopsy, blood tests, contrasted CT of abdomen and chest. When radical treatment is considered then 18-FDG-positron emission tomography (PET/CT) is recommended to confirm the presence or absence of distant metastases [6]. Due to restricted availability of PET/CT facilities, referral to PET/CT examination may lead to treatment delay [7].

The aim of this retrospective study was to evaluate the utility of PET/CT (18-FDG-positron emission tomography/computed tomography) in patients with locally or locoregionally advanced esophageal cancer who are being considered for radical chemoradiation.

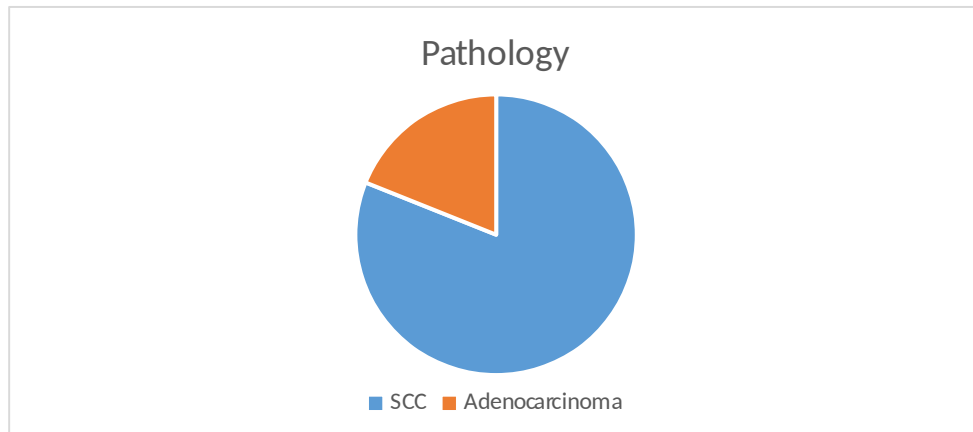
The findings of the study aim to provide evidence supporting the necessity of PET/CT in the staging and treatment planning process for esophageal cancer patients undergoing definitive chemoradiation.

## **Material and methods**

The study included 37 consecutive esophageal cancer patients who were recruited for chemoradiation by the Multidisciplinary Tumor Board (MTB) at the Greater Poland Cancer Center (Wielkopolskie Centrum Onkologii, WCO) in 2021.

The inclusion criteria were as follows: patients with esophageal cancer who did not have distant metastases detected at the time of MTB and Eastern Cooperative Oncology Group (ECOG) Performance Status was at least ECOG-2. Very early lesions that were able to be managed through endoscopic procedures or definitive surgery were excluded from the analysis. Out of the 37 patients, 24 were male and 13 were female, with an average age of 65. The performance status of the patients was classified as ECOG 0–2, indicating a range from fully active to being ambulatory but limited in physical activity. In terms of histology, squamous cell carcinoma was the dominant type, observed in 30 patients, while adenocarcinoma was present in 7 patients (Fig. 1).

The study period encompassed the year 2021, during which the patients were discussed by the MTB and referred to chemoradiation. Their data was analyzed retrospectively to assess the role of PET/CT in the staging and management of esophageal cancer patients undergoing chemoradiation.



**Figure 1.** Tumor pathology proportion in the study. SCC — squamos cell carcinoma

Prior to radiotherapy planning every patient was referred to PET/CT to have the extent of their disease assessed. Staging was based on the American Joint Committee on Cancer (AJCC) Tumour–Node–Metastasis (TNM) Staging Classification for Carcinoma of the Esophagus and Esophagogastric Junction (8<sup>th</sup> ed., 2017). Cervical nodes metastases were considered distant in case of non-cervical primary tumor.

Radiotherapy was based on CT scan with PET/CT fusion to ensure proper tumor delineation. In certain cases the 4-D gating technique was implemented. The total dose in chemoradiation schedule ranged from 41.4 Gy to 66.4 Gy delivered in 5 fractions a week with weekly carboplatin/paclitaxel.

## Results

Among 37 patients PET/CT changed the staging status to metastatic (M1) in six cases (3 planoepithelial and 3 adenocarcinomas). In all those cases but one (1 patient with supraclavicular node metastasis finally received chemoradiation) confirmation of distant metastases excluded patients from radical treatment. Interestingly, in the PET/CT distant positive group 3 patients were initially staged as locally advanced (without nodal involvement). The other 3 were initially identified as at least N2 in tomography. In the whole

cohort, based on conventional imaging, 20 out of 30 squamous cell carcinomas and 5 out of 7 adenocarcinomas showed nodal involvement.

**Table 1.** Pattern of disease dissemination in positron emission tomography/computed tomography (PET/CT) in patients with metastases (M+) included in the study

Patient no	Pathology	CT-based TNM	PET/CT result	Final treatment
1.	Planoepithelial	T2N2M0	Lung metastasis/second primary	Supportive care
2.	Planoepithelial	T2N0M0	Non-regional nodal metastasis	RTCT
3.	Planoepithelial	T2N0M0	Liver and bone mets	Radiotherapy
4.	Adenocarcinoma	T3N3M0	Liver and non-regional nodal mets	Systemic therapy, radiotherapy
5.	Adenocarcinoma	T2N0M0	Liver and bone mets	Radiotherapy
6.	Adenocarcinoma	T3N3M0	Non-regional nodal metastasis	Radiotherapy

RTCT — radiotherapy plus chemotherapy

## Discussion

This study investigates the utility of PET in staging potentially curative esophageal carcinoma. Given the challenges associated with accessing PET/CT facilities in certain regions [7], it is worth discussing whether this diagnostic tool is necessary for all cases of esophageal cancer. Current guidelines recommend the use of PET/CT in the staging workup [8].

A systematic review conducted by van Westreenen et al. assessed the staging performance of FDG-PET in esophageal cancer [9]. Their study demonstrated the high sensitivity and specificity of FDG-PET in identifying both local and distant metastases. The findings

emphasized the superior performance of FDG-PET in detecting distant metastases, particularly in non-regional lymph nodes, liver, and bone. These results confirm the essential role of FDG-PET in accurately staging and excluding metastatic disease in esophageal cancer.

Flamen et al. investigated the utility of FDG-PET in staging patients with potentially operable esophageal carcinoma [10]. Their study evaluated the impact of FDG-PET on treatment decision-making, particularly in identifying patients suitable for surgery. The findings demonstrated that FDG-PET provided additional crucial information, leading to modifications in the management plans of a significant number of patients. FDG-PET contributed to the detection of distant metastases, resulting in the exclusion of patients from surgery and the initiation of alternative treatment strategies.

Our study reaffirms that PET/CT remains an indispensable diagnostic tool for excluding distant metastases. Its utility was evident across both squamous cell carcinoma and adenocarcinoma, with 10% of squamous cell carcinoma patients and 43% of adenocarcinoma patients identified as having metastases based on PET/CT findings. Although the pattern of distant metastases varied, commonly affected sites included the liver, bone, and non-regional lymph nodes. In one case, the presence of a lung tumor was suspected; however, due to complications related to a fistula, the patient did not receive radiotherapy, and pulmonary diagnostics were incomplete.

Notably, the locoregional advancement observed on contrast-enhanced CT did not consistently correlate with PET/CT results. The time interval between these diagnostic modalities may play a role in this disparity. In our study, the average delay from the baseline CT scan to PET/CT was 45 days, a significant duration that could potentially impact disease progression and worsen treatment prognosis.

Furthermore, disease confined solely to the esophagus, as identified by baseline CT without nodal involvement, did not guarantee the absence of distant metastases on PET/CT. This finding suggests that PET/CT should not be omitted even in cases of relatively less advanced tumors. While the utility of PET/CT in the diagnostic workup is unquestioned in both clinical practice and guidelines, its integration into radiotherapy planning remains uncertain. As the authors of the "systematic review on the role of FDG-PET/CT in tumor delineation and radiotherapy planning in patients with esophageal cancer" conclude [11], "it is not established as a standard and requires further investigation."

## **Conclusion**

The study concludes that PET/CT is a crucial diagnostic tool in esophageal cancer patients undergoing radical chemoradiation. It plays a key role in excluding metastatic disease, allowing for appropriate treatment planning. The findings show that PET/CT changed the staging status to metastatic in six cases, leading to the exclusion of these patients from radical treatment.

The study suggests that PET/CT should not be omitted even in relatively less advanced tumors confined to the esophagus only. The study highlights the importance of timely access to PET/CT facilities, as the delay in obtaining scans may impact disease progression and treatment prognosis.

## ***Ethical permission***

Ethical approval was not necessary for the preparation of this article.

## ***Conflicts of interest***

Authors have no conflict of interest to declare.

## ***Funding***

This publication was prepared without any external source of funding.

## **References**

1. Noordman Boj, Verdam MGE, Lagarde SM, et al. CROSS Study Group. Impact of neoadjuvant chemoradiotherapy on health-related quality of life in long-term survivors of esophageal or junctional cancer: results from the randomized CROSS trial. *Ann Oncol.* 2018; 29(2): 445–451, doi: [10.1093/annonc/mdx726](https://doi.org/10.1093/annonc/mdx726), indexed in Pubmed: [29126244](https://pubmed.ncbi.nlm.nih.gov/29126244/).
2. Fiorica F, Di Bona D, Schepis F, et al. Preoperative chemoradiotherapy for oesophageal cancer: a systematic review and meta-analysis. *Gut.* 2004; 53(7): 925–930, doi: [10.1136/gut.2003.025080](https://doi.org/10.1136/gut.2003.025080), indexed in Pubmed: [15194636](https://pubmed.ncbi.nlm.nih.gov/15194636/).
3. Urschel JD, Vasan H. A meta-analysis of randomized controlled trials that compared neoadjuvant chemoradiation and surgery to surgery alone for resectable esophageal cancer. *Am J Surg.* 2003; 185(6): 538–543, doi: [10.1016/s0002-9610\(03\)00066-7](https://doi.org/10.1016/s0002-9610(03)00066-7), indexed in Pubmed: [12781882](https://pubmed.ncbi.nlm.nih.gov/12781882/).
4. Swisher SG, Hofstetter W, Komaki R, et al. Improved long-term outcome with chemoradiotherapy strategies in esophageal cancer. *Ann Thorac Surg.* 2010; 90(3): 892–8; discussion 898, doi: [10.1016/j.athoracsur.2010.04.061](https://doi.org/10.1016/j.athoracsur.2010.04.061), indexed in Pubmed: [20732514](https://pubmed.ncbi.nlm.nih.gov/20732514/).
5. Sjoquist KM, Burmeister BH, Smithers BM, et al. Australasian Gastro-Intestinal Trials Group. Survival after neoadjuvant chemotherapy or chemoradiotherapy for resectable oesophageal

carcinoma: an updated meta-analysis. *Lancet Oncol.* 2011; 12(7): 681-692, doi: [10.1016/S1470-2045\(11\)70142-5](https://doi.org/10.1016/S1470-2045(11)70142-5), indexed in Pubmed: [21684205](https://pubmed.ncbi.nlm.nih.gov/21684205/).

6. Pennathur A, Gibson M, Jobe B, et al. Oesophageal carcinoma. *Lancet.* 2013; 381(9864): 400-412, doi: [10.1016/s0140-6736\(12\)60643-6](https://doi.org/10.1016/s0140-6736(12)60643-6), indexed in Pubmed: [23374478](https://pubmed.ncbi.nlm.nih.gov/23374478/).
7. Gallach M, Mikhail Lette M, Abdel-Wahab M, et al. Addressing Global Inequities in Positron Emission Tomography-Computed Tomography (PET-CT) for Cancer Management: A Statistical Model to Guide Strategic Planning. *Med Sci Monit.* 2020; 26: e926544, doi: [10.12659/MSM.926544](https://doi.org/10.12659/MSM.926544), indexed in Pubmed: [32848125](https://pubmed.ncbi.nlm.nih.gov/32848125/).
8. NCCN Clinical Practice Guidelines in Oncology (NCCN Guidelines®) Esophageal and Esophagogastric Junction Cancers Version 5.2022 — December 5, 2022.
9. van Westreenen HL, Westerterp M, Bossuyt PMM, et al. Systematic review of the staging performance of 18F-fluorodeoxyglucose positron emission tomography in esophageal cancer. *J Clin Oncol.* 2004; 22(18): 3805-3812, doi: [10.1200/JCO.2004.01.083](https://doi.org/10.1200/JCO.2004.01.083), indexed in Pubmed: [15365078](https://pubmed.ncbi.nlm.nih.gov/15365078/).
10. Flamen P, Lerut A, Van Cutsem E, et al. Utility of positron emission tomography for the staging of patients with potentially operable esophageal carcinoma. *J Clin Oncol.* 2000; 18(18): 3202-3210, doi: [10.1200/JCO.2000.18.18.3202](https://doi.org/10.1200/JCO.2000.18.18.3202), indexed in Pubmed: [10986052](https://pubmed.ncbi.nlm.nih.gov/10986052/).
11. Muijs CT, Beukema JC, Pruijm J. A systematic review on the role of FDG-PET/CT in tumour delineation and radiotherapy planning in patients with esophageal cancer. *Radiother Oncol.* 2010; 97(2): 165-171, doi: [10.1016/j.radonc.2010.04.024](https://doi.org/10.1016/j.radonc.2010.04.024), indexed in Pubmed: [20541273](https://pubmed.ncbi.nlm.nih.gov/20541273/).