












# Glomangioma in the hand: diagnosis, treatment, and challenges

Bartosz Szmyd<sup>1</sup> , Mikołaj Malicki<sup>1</sup>, Maciej Błaszczyk<sup>1</sup> , Filip Franciszek Karuga<sup>2</sup> , Marcin Braun<sup>3</sup> ,  
Julia Sołek<sup>3</sup> , Redwan Jabbar<sup>1</sup> , Jakub Jankowski<sup>1</sup> , Grzegorz Wyśiadecki<sup>4</sup> , Maciej Radek<sup>1</sup> 

<sup>1</sup>Department of Neurosurgery, Spine and Peripheral Nerve Surgery, Medical University of Lodz, Lodz, Poland

<sup>2</sup>Department of Sleep Medicine and Metabolic Disorders, Medical University of Lodz, Lodz, Poland

<sup>3</sup>Department of Pathology, Chair of Oncology, Medical University of Lodz, Lodz, Poland

<sup>4</sup>Department of Normal and Clinical Anatomy, Medical University of Lodz, Lodz, Poland

## ABSTRACT

**Introduction.** In this paper, we have analysed all hand glomangioma cases referred to our clinic in the context of symptoms, time to diagnosis, and the role of surgical resection of the lesion.

**Material and methods.** We have collected the following data: the presence of risk factors, manifestation, time to diagnosis, the treatment applied, and follow-up of patients.

**Results.** We have collected medical records from six patients, three males and three females. The median age was 45 (IQR: 29.5–65.75). The main symptom in all patients was severe pain and tenderness. The first-choice physician(s) were: general practitioners, general surgeons, and neurologists. The median time to diagnosis was 7 (IQR: 5–10) years. The main complaint of our patients was severe pain — 9 (IQR: 9–10) on the VAS scale, which was significantly alleviated after surgical treatment — 0 (IQR: 0–0;  $p = 0.043$ ).

**Conclusions.** Extremely long times to final diagnosis, and excellent outcomes of surgical treatment, highlight the necessity of raising awareness of glomangiomas among clinicians.

**Key words:** subungual glomangioma, glomangioma, glomuvenous malformation, glomangiosarcoma, risk factors, treatment

## Introduction

Glomangioma is a rare, typically benign, lesion accounting for up to 2% of soft tissue tumours. According to the World Health Organisation guidelines, it is defined as “a mesenchymal neoplasm composed of cells resembling the perivascular modified smooth muscle cells of the normal glomus body” [1]. The small (< 1 cm) visible and/or palpable mass (Fig. 1A, Supp. Fig. 1), with a pinkish-red or bluish macule and/or spot, is usually located in the distal extremities - especially in the subungual region, but also in the hand, wrist, and foot [1, 2]. Other localisations have been observed especially in males e.g. nerves, bones, muscles, mediastinum, lung,

gastrointestinal tract (preferably stomach), genitourinary system, and others [3–9].

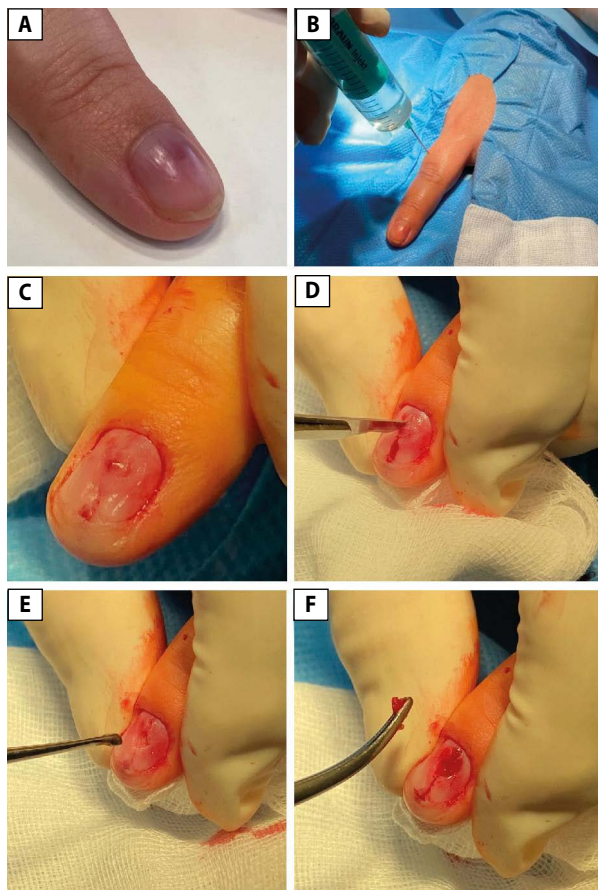
Our patients reported the typical triad of symptoms: paroxysmal pain, cold sensitivity, and exquisite point tenderness in the region of the tumour. Not all of these symptoms were present consistently, and pain was the most common [1, 2]. The diagnosis was based on clinical presentation and clinical signs/tests, especially the Hildreth sign, cold-sensitivity test, and transillumination test [2]. The final verification was made by a pathologist.

In this paper, we analyse all hand glomangioma cases referred to the Department of Neurosurgery, Spine and Peripheral Nerves Surgery of the Medical University of Lodz,

**Address for correspondence:** Prof. Maciej Radek, M.D., Ph.D., Department of Neurosurgery, Spine and Peripheral Nerve Surgery, Medical University of Lodz, 113 Stefana Żeromskiego St., 90–549 Lodz, Poland; e-mail: maciej.radek@umed.lodz.pl

Received: 22.12.2022 Accepted: 11.05.2023 Early publication date: 21.06.2023

This article is available in open access under Creative Commons Attribution-Non-Commercial-No Derivatives 4.0 International (CC BY-NC-ND 4.0) license, allowing to download articles and share them with others as long as they credit the authors and the publisher, but without permission to change them in any way or use them commercially.



**Figure 1.** Intraoperative images show dissection of glomangioma: (A) presurgical photography of lesion, (B) usage of infiltration anaesthesia with lignocaine just after standard preparation of operating field, (C) visualisation of subungual glomangioma, (D) incision of aforementioned lesion, (E) removal of lesion, (F) state after subungual glomangioma removal

Poland in the context of symptoms, time to diagnosis, and the role of surgical resection of the lesion.

## Material and methods

### Patient selection and collected data

We analysed the medical records of six patients treated for glomangioma in the Department of Neurosurgery, Spine and Peripheral Nerves Surgery of the Medical University of Lodz between 1 January, 2017 and 31 October, 2022. From all of these patients, we attempted to collect the following data: preoperative [age, sex, occupation, lesion location, initial symptoms, photographic documentation, duration of symptoms, first-choice physician, time to diagnosis, presurgical pain severity according to the Visual Analogue Scale (VAS)], intraoperative (photographic documentation, surgery description), and postoperative [histopathological verification result, appearance of new similar lesions in patient or patient's family,

pain severity in VAS (Supp. Tab. 1)]. Moreover, the data was juxtaposed with the presence/absence of selected risk factors including positive familial history, multiple lesions, mutations in the glomulin gene (GLMN), and neurofibromatosis type 1.

### Surgical technique

The patients underwent Oberst anaesthesia just after the standard preparation of the operating field. Then the nail was removed if needed. In the case of nonvisible, nonpalpable lesions, they were further visualised using transillumination. The lesions were further totally dissected (Fig. 1B–F) and sent for histopathological verification (Supp. Fig. 2). The control of haemostasis was performed. A sterile dressing was used. These steps are shown in Supp. Video 1.

## Results

We collected medical records from six patients, three males and three females. The median age was 45 (IQR: 29.5–65.75). One patient (16.67%) (Tab. 2) missed the follow-up. A lesion was found in the following localisations: (1) subungual in the first finger of the right hand, (2) fingertip of the third finger of the right hand, (3) subungual in the fifth finger of the left hand, (4) subungual in the first finger of the left hand, (5) subungual in the second finger of the left hand, and (6) fingertip of the first finger of the left hand. The lesion was visible in just one case (Fig. 1A). The lesion was palpable in three patients (50%).

The main symptoms in all patients were severe pain with the presence of point tenderness in the region of the tumour. Patients were diagnosed by general practitioners ( $n = 3$ ), general surgeons ( $n = 2$ ), and neurologists ( $n = 2$ ). Two of them were diagnosed by more than one physician. The median time to diagnosis was 7 (IQR: 5–10) years.

### Preoperative pain and its relief

The main complaint of our patients was initially severe pain - 9 (IQR: 9–10) on the VAS scale. The specificity differed between patients (Tab. 1). Three months after surgery, median pain severity was 0 (IQR: 0–0;  $p = 0.043$ ).

### Risk factor presence

There was no case of positive familial history of glomangioma, multiple lesions, detected mutations in the glomulin gene (GLMN), or neurofibromatosis type 1 symptoms (diagnosed NF1, six or more café-au-lait spots over 5 mm in greatest diameter in pre-pubertal individuals and over 15 mm in greatest diameter in post-pubertal individuals, two or more neurofibromas of any type or one plexiform neurofibroma, optic nerve glioma, two or more Lisch nodules (pigmented iris hamartomas), a distinctive osseous lesion such as sphenoid dysplasia, or thinning of the long bone cortex with or without pseudarthrosis, or a first-degree relative (i.e. parent, sibling, or offspring) with NF1 by the above criteria).

**Table 1.** Results of pre-, intra-, and postoperative examinations juxtaposed with presence of selected risk factors

No.	Sex	Age	Symptoms	Lesion	First-choice physician(s)	Time to diagnosis [years]	Pain severity in VAS scale pre- and postoperative	Risk factors
1.	M	74	Pain radiating to elbow, especially at night, tenderness	Nonvisible, palpable	Neurologist	5	7 > 1	No
2.	M	34	Dull pain, tenderness	Nonvisible, nonpalpable	General surgeon	10	9 > 0	No
3.	M	28	Pulsating pain, tenderness	Nonvisible, nonpalpable	GP, general surgeon	4	9 > 0	No
4.	F	69	Pain, tenderness	Nonvisible, nonpalpable	N.D.	N.D.	N.D.	No
5.	F	24	Paroxysmal pain, and tenderness, aggravated by temperature changes	Visible (Fig. 1), palpable	GP, neurologist	7	10 > 0	No
6.	F	56	Tenderness	Nonvisible, palpable	GP	10	10 > 0	No

GP — general practitioner; N.D. — no data; VAS — visual analogue scale

## Discussion

Glomangioma remains a rare entity that significantly affects patients' quality of life. These six patients reported the typical triad of symptoms: paroxysmal pain, cold sensitivity, and point tenderness in the region of the tumour. Not all of the symptoms were present consistently, and pain was the most common [2]. This statement is supported by our data. All patients reported severe pain and the presence of point tenderness in the region of the tumour. Interestingly, sensitivity to temperature changes was observed in just 1/6 cases. Glomangioma may be visible as a small pinkish-red or bluish macule and/or spot, as was seen in the case presented in Figure 1 [1].

Glomangioma is mostly localised on distal extremities — especially in the subungual region but also in the hand, wrist, and foot. In the current study, we have focused on glomangioma localised in the hand: 5/6 (83.33%) presented with a subungual lesion, and only 1/6 (16.67%) presented glomangioma in the fingertip of the third finger of the right hand. Other localizations are rarely observed but can include: nerves, bones, muscles, the mediastinum, lungs, the gastrointestinal tract, and the genitourinary system [4–9].

### Diagnostic problems

Falcone has stated that hand glomangiomas are characterised by a high rate of misdiagnosis, due to “the very ignorance of their existence by the medical corpus” [10]. The extremely long time to diagnosis among our patients — 7 (IQR: 5–10) years — reveals a good deal of justification for this thesis. As patients were first diagnosed by general practitioners, general surgeons, and neurologists, there is a need to raise awareness of glomangiomas among clinicians.

In the case of uncertain diagnosis, the following entities should be taken into consideration in differential diagnosis,

especially during histopathological verification: exostosis, enchondroma, leiomyoma, ganglion spiradenoma, and heman-gioma [2]. Fortunately, in all of our cases, the initial diagnosis was confirmed.

### Surgical treatment

Complete surgical resection remains the best treatment for subungual/finger glomangioma [10]. There are two main surgical approaches: trans-ungual with the removal of the nail, and lateral. The first of these is recommended for lesions localised in the central subungual region, while the second approach should be used in the case of glomangioma observed in the lateral subungual region and/or on the finger pad [2].

2-4 weeks after surgery, most of the patients reported significant relief, although pain can last longer in some cases [2]. In 4/6 (66.67%) cases we observed relief within the first month. One patient (16.67%) had pain lasting for two months, with complete recovery subsequently.

### Histopathological diagnosis

Glomus tumours are composed of cells that resemble the modified smooth muscle cells of the normal glomus body. These glomus cells are round, monomorphic, and have indistinct borders, but no atypia. In most cases, they form dense nests that surround small vessels in hyalinised stroma. Oncocytic or epithelioid changes are occasionally present in glomus tumours [11, 12]. Features indicating malignant transformation include marked cellular (nuclear) atypia and atypical mitotic figures adjacent to the normal (benign) component.

According to the WHO 2020 Classification of Soft Tissue Tumours, an accurate diagnosis of glomus tumours should include the following immunohistochemical stainings: Smooth Muscle Actin (SMA) and CD34, to confirm the glomus body's origin; desmin, to exclude other tumours of myogenic

differentiation; chromogranin, to exclude neuroendocrine differentiation; pan-cytokeratin (CKAE1/AE3), to exclude epithelial differentiation; melan-A, to exclude melanocytic differentiation; and Ki-67, to confirm a low proliferation index [1].

### Risk factors

The established risk factors are a positive familial history of glomangioma, multiple lesions, detected mutations in the glomulin gene (*GLMN*), or neurofibromatosis type 1 [1]. Small studies have shown that pathogenic variants in *BRAF*, *NOTCH*, *PDGFRB*, *KRAS*, and *SMARCB1* can predispose to glomangiomas. In our group of patients, there were no clinical indications for further genetic counselling, and therefore it was waived.

### Prognosis and recurrence risk

The largest series of glomangioma patients in the last 15 years have been presented by Lin et al. (n = 75) and Chou et al. (n = 50) [13, 14]. Although all of these patients underwent surgical removal of the lesion with good therapeutic effect, the outcome was not event-free in all cases. Chou et al. observed recurrence in three (6%) and nail deformity in three (6%) patients, while Lin et al. noted 13 (17%) recurrences [13, 14]. Recurrences can be divided into early (caused by incomplete excision or undiagnosed secondary tumours) or delayed (caused by the development of a new tumour) [15]. Recurrence risk factors encompass being skin-coloured (OR = 31.67; 95% CI = 2.68–373.74), being located within the nail matrix (OR = 5.79, 95% CI = 1.03–32.49), and a genetic condition predisposing to glomangiomas [13].

### Conclusions

Glomangioma remains a rarely observed lesion that strongly affects the patient's quality of life, mainly due to severe pain. Unfortunately, knowledge regarding this entity seems to be relatively scarce among physicians, which results in an extremely long time until the final diagnosis. The excellent outcomes of surgical treatment highlight the necessity to raise awareness of glomangiomas among clinicians.

### Clinical implications/future directions

We observed a high necessity to raise awareness of glomangiomas among clinicians, especially general practitioners, neurologists, and general surgeons. This may result in a reduction of the time to diagnosis and prompt treatment.

### Strengths and limitations

The main advantage of this study was the relatively large group of patients with subungual glomangioma from the Department of Neurosurgery, Spine and Peripheral Nerves

Surgery. All the questions were consulted with an experienced dermatologist, a neurologist, a general practitioner, and a neurosurgeon. All data was collected by medical doctors experienced in scientific work.

Nevertheless, the study also has visible limitations, especially its retrospective character and the fact that the research was performed in a single centre.

**Conflicts of interests:** None

**Funding:** The APC was funded by the Department of Neurosurgery, Spine and Peripheral Nerves Surgery of the Medical University of Lodz, 90–549 Lodz, Poland.

**Acknowledgments:** We would like to thank Prof. Andrzej Radek for raising awareness of glomangioma in our Department. Moreover, we would like to thank all of our patients for their trust and motivation to let us become better and more experienced clinicians.

### References

- Specht K, Antonescu C. Glomus tumour. *Soft Tissue Bone Tumours WHO Classif. Tumours*, vol. 3. 5th ed. International Agency for Research on Cancer, Lyon 2020: 179–181.
- Samaniego E, Crespo A, Sanz A. [Key diagnostic features and treatment of subungual glomus tumor]. *Actas Dermosifiliogr*. 2009; 100(10): 875–882, indexed in Pubmed: [20038364](#).
- Gombos Z, Zhang PJ. Glomus tumor. *Arch Pathol Lab Med*. 2008; 132(9): 1448–1452, doi: [10.5858/2008-132-1448-GT](#), indexed in Pubmed: [18788860](#).
- Miettinen M, Paal E, Lasota J, et al. Gastrointestinal glomus tumors: a clinicopathologic, immunohistochemical, and molecular genetic study of 32 cases. *Am J Surg Pathol*. 2002; 26(3): 301–311, doi: [10.1097/0000478-200203000-00003](#), indexed in Pubmed: [11859201](#).
- Rössle M, Bayerle W, Löhns U. Glomangioma of the lungs: a rare differential diagnosis of a pulmonary tumour. *J Clin Pathol*. 2006; 59(9): 1000, doi: [10.1136/jcp.2005.031237](#), indexed in Pubmed: [16935981](#).
- Scheithauer BW, Rodriguez FJ, Spinner RJ, et al. Glomus tumor and glomangioma of the nerve. Report of two cases. *J Neurosurg*. 2008; 108(2): 348–356, doi: [10.3171/JNS/2008/108/2/0348](#), indexed in Pubmed: [18240933](#).
- Wang Y, Xiang Y, Bian Y, et al. Glomus tumors associated with the bone and joints: a review of 91 cases. *Ann Transl Med*. 2020; 8(21): 1460, doi: [10.21037/atm-20-6998](#), indexed in Pubmed: [33313205](#).
- Bistazzoni S, Polosa M, Bellocchi SD. Unusual location of glomus tumors. *Case Reports and Images in Surgery*. 2020; 3(2), doi: [10.15761/cris.1000144](#).
- Lee TJ, Reddy GP, Leung JWT, et al. Mediastinal glomangioma: CT and octreotide scintigraphy appearance, and review of the literature. *J Thorac Imaging*. 2008; 23(4): 289–291, doi: [10.1097/RTI.0b013e31817eee70](#), indexed in Pubmed: [19204477](#).
- Falcone MO. Glomus tumors of the fingers. *Rev Prat*. 2022; 72(3): 313–316, indexed in Pubmed: [35638965](#).
- Slater DN, Cotton DW, Azzopardi JG. Oncocytic glomus tumour: a new variant. *Histopathology*. 1987; 11(5): 523–531, doi: [10.1111/j.1365-2559.1987.tb02660.x](#), indexed in Pubmed: [3038728](#).

12. Pulitzer D, Martin P, Reed R. Epithelioid glomus tumor. *Human Pathology*. 1995; 26(9): 1022–1027, doi: [10.1016/0046-8177\(95\)90093-4](https://doi.org/10.1016/0046-8177(95)90093-4).
13. Lin YC, Hsiao PF, Wu YH, et al. Recurrent digital glomus tumor: analysis of 75 cases. *Dermatol Surg*. 2010; 36(9): 1396–1400, doi: [10.1111/j.1524-4725.2010.01647.x](https://doi.org/10.1111/j.1524-4725.2010.01647.x), indexed in Pubmed: 20629689.
14. Chou T, Pan SC, Shieh SJ, et al. Glomus tumor: twenty-year experience and literature review. *Ann Plast Surg*. 2016; 76 Suppl 1: S35–S40, doi: [10.1097/SAP.0000000000000684](https://doi.org/10.1097/SAP.0000000000000684), indexed in Pubmed: 26808758.
15. Lee JJ, Park DH, Park MC, et al. Subungual glomus tumours of the hand: diagnosis and outcome of the transungual approach. *J Hand Surg Eur Vol*. 2009; 34(5): 685–688, doi: [10.1177/1753193408104799](https://doi.org/10.1177/1753193408104799), indexed in Pubmed: 19959449.