

This is a provisional PDF only. Copyedited and fully formatted version will be made available soon.



ISSN: 0015-5659

e-ISSN: 1644-3284

A retrospective evaluation of condylar morphology using panoramic radiography in a sample of Turkish population

Authors: Hilal Peker Öztürk, Hakan Avsever İsmail, Buğra Şenel, Hatice Seda Özgedik, Mehmet Hakan Kurt

DOI: 10.5603/FM.a2023.0045

Article type: Original article

Submitted: 2022-12-17

Accepted: 2023-06-11

Published online: 2023-06-19

This article has been peer reviewed and published immediately upon acceptance. It is an open access article, which means that it can be downloaded, printed, and distributed freely, provided the work is properly cited.

Articles in "Folia Morphologica" are listed in PubMed.

A retrospective evaluation of condylar morphology using panoramic radiography in a sample of turkish population

Peker Öztürk Hilal et al., Evaluation of condylar morphology

Peker Öztürk Hilal¹, Avsever İsmail Hakan^{1,2}, Şenel Buğra^{1,2}, Özgedik Hatice Seda¹, Kurt Mehmet Hakan³

¹Department of Dentomaxillofacial Radiology, Gulhane Dentistry Faculty, University of Health Sciences, Ankara, Turkey

²Department of Dentomaxillofacial Radiology, Faculty of Dentistry, University of East Mediterranean, Gazi Mağusa, Cyprus

³Department of Dentomaxillofacial Radiology, Faculty of Dentistry, Ankara University, Ankara, Turkey

Address for correspondence: Assistant Professor Hilal Peker Öztürk, Health Sciences University, Gulhane Dentistry Faculty, Department of Dentomaxillofacial Radiology, Ankara, Turkey, tel-1: +90 3123046063, tel-2: +90 5054463628, e-mail: hpozurk0@gmail.com

ABSTRACT

Background: The temporomandibular joint is one of the most complex anatomic structures. It takes a great role in masticatory system and helps to make possible some functions such as speaking, chewing and swallowing. Clinicians should have sufficient anatomical knowledge to assess relationships of the hard and soft tissues, including the mandibular condyle, glenoid fossa, articular eminence of the temporal bone, the articular disc and its attachments. The aim of this study was to evaluate the frequency of different types of mandibular condyles and its distribution according to the age and gender. It was also evaluated whether the condyle types were bilaterally symmetrical or not.

Materials and methods: A total of 1315 digital panoramic images which obtained from the patients suffering from the dental problems were assessed. Demographic data, condylar morphology were noted. All obtained data were analyzed by using descriptive statistics. Morphology of mandibular condyles were classified into four shapes as identified in other studies, namely: Type I - Oval shape, Type II - Diamond shape, Type III - Bird beak shape, Type IV - Crooked finger shape. Two independent examiners, who have 19 and 7 years of experience in oral and dentomaxillofacial radiology, made a consensus and evaluated all images.

Results: A total of 1315 digital panoramic images were assessed. 767[58.3%] of the patients were female and 548[41.6%] were male. The age range of patients was from 18 to 84 years. Right-left condyle types were found to be symmetrical in the range of 67% of the subpopulation examined in the study. For the consensus, ‘oval’ condyle was common on both the right and left, while ‘crooked finger’ condyle was the rarest.

Conclusions: The TMJ is the most important structure for all jaw functions such as speech, swallowing. In order for all these functions to continue in a healthy way, the anatomical structure should be known very well down to the finest detail. Identification of anatomical structures and their variations can play an important role in implant dentistry. Clinicians commonly prefer conventional radiologic methods to evaluate dentomaxillofacial region. Although the most of the variations are asymptomatic and require no treatment, correct identification of these findings will reduce unnecessary further diagnostic assessments and will provide more appropriate treatment plans.

Key words: mandibular condyle, anatomy, radiographic interpretation

INTRODUCTION

The temporomandibular joint (TMJ) is one of the most complex anatomic structures. It takes a great role in masticatory system and helps to make possible some functions such as speaking, chewing and swallowing [29]. Although TMJ has some common features with other joints, it has some differences such as anatomic complexity and close anatomical relationships make it specific among others in the body. TMJ has bony articular surfaces, articular capsule, synovial membrane, ligaments and also an articular disc [25]. Clinicians should have sufficient anatomical knowledge to assess relationships of the hard and soft tissues, including the mandibular condyle, glenoid fossa, articular eminence of the temporal bone, the articular disc and its attachments [11,18,20].

Improving the knowledge of dentomaxillofacial anatomy and the features of imaging modalities will lead practitioners to avoid misinterpretations and misdiagnosis. In this context, radiographic examination is necessary to evaluate TMJ structures, abnormalities, growth and bony changes. Choosing the most appropriate imaging technique is precious. Over the years, radiologists have used different oblique projections to overcome the limitations of standard conventional radiographic techniques. Recently, there are several imaging modalities available including conventional radiographic techniques, computerized tomography(CT) scanning, cone-beam CT(CBCT), arthrography, magnetic resonance imaging(MRI), computerized axiography, and ultrasonography [20].

Considering the advantages of the panoramic imaging technique, it is often used for dental reasons in the evaluation of the dentomaxillofacial area. Although panoramic imaging is one of the most common imaging techniques in dental practice, there are some limitations. These limitations including; magnifications, distortions and superimpositions make difficult to interpret the anatomical structures such as TMJ [21]. Despite these limitations some anatomical structures can be evaluated. One of these is condyle shape. A number of studies which were made in different populations by using panoramic imaging technique are available in literature about the shape of the mandibular condyle. Some differences between several populations were found in prevalence [2,5,10,26,27,31].

Condyle is a special part of TMJ, because it stimulates the growth of mandible. Shape of mandibular condyle can differ among some individuals. Simple developmental variability, remodelling to accommodate developmental variations, malocclusion, trauma and other developmental abnormalities can cause morphological changes on the mandibular condyle (8, 3). Besides these the form and function can be considered closely linked. Due to this situation morphology of TMJ may be related to functional forces (12). Full understanding of the anatomy and the morphology of the TMJ is crucial to detect the normal and the abnormal condition (8). Normal condylar head is assumed to have convex structure and to be of the same shape bilaterally in the same person (23). Morphological changes of mandibular condyle are most commonly observed in elderly people due to the degeneration of TMJ (17). Based on all these, the detection of changes in the condyle is important for the diagnosis of TMJ diseases and reduces misinterpretation (3).

The aim of this study was to examine the morphologies of the mandibular condyle and evaluate the frequency of different types of mandibular condyles and their distribution according to age and gender in a Turkish subpopulation. It is also revealed the frequency of the difference of bilateral occurrence if available.

Therefore the current study's hypothesis was that the right and left mandibular condyles in a person mostly would be in different types and age and gender does not effect condyle types.

MATERIAL AND METHODS

Study design

This study was authorized by the Local Research Ethics Committee (Protocol: 2021/278). The retrospective cross-sectional study was performed on digital panoramic images of 10287 patients who were referred to the Department of Dentomaxillofacial Radiology at Gulhane Dentistry Faculty, University of Health Sciences, Ankara, Turkey, between 2021 and 2022. The panoramic images were performed using a Planmeca Promax digital panoramic system at 66 kVp, 8 mA and 15.8 s exposure settings (Planmeca, Helsinki, Finland).

All images were made with the same radiographic equipment (Planmeca, Helsinki, Finland) with the maximum KVP of 66, mA=8. All radiography were carried out by the same technician. All of the images were evaluated on the same monitor (HP Compaq LE1711 LCD Monitor, Palo Alto, CA, USA).

The panoramic images which were obtained for dentomaxillofacial problems such as impacted teeth, pathological lesions, orthognathic problems, dental implant procedures, endodontic lesions, etc were evaluated in this study. Inclusion criterion consisted of individuals over 18 years of age undergoing a panoramic radiographic examination with adequate diagnostic quality. The images of patients who were under the age of 18 or had a history of surgery, trauma, or developmental deficiencies in the dentomaxillofacial region and that were with low quality were excluded from the study. The images were evaluated to have adequate diagnostic quality, with all examined anatomical structures being visualized correctly, without any artifacts such as blurring, streaking, or ghosting, and with suitable contrast and density. A total of 1315 images were evaluated, 767[58.3%] of the patients were female and 548[41.6%] were male.

Image evaluation

The images were evaluated by consensus by 2 radiologists who have experience over 10 years, with ClearCanvas DICOM Viewer, version 1.0.0.0v4 (ClearCanvas Inc., Toronto, Ontario, Canada) on a standard computer with calibrated monitor (HP Compaq LE1711 LCD Monitor, Palo Alto, CA, USA). The contrast and brightness level of the images and zooming were left to the examiner's choices.

Morphology of mandibular condyles were classified into four shapes as identified in other studies [2,26]: Type I- Oval shape, Type II- Diamond shape, Type III- Bird beak shape, Type IV- Crooked finger shape shown in Figure 1.

Statistical analysis

Obtained data were analysed by descriptive statistics. The frequency of the condylar morphology types were calculated. All categorical variables were shown as n (%). The Pearson's Chi-Square Test was used to compare categorical variables. All statistical analyses were carried out using IBM SPSS Statistics 21.0 (IBM Corp., Armonk, NY, USA) and MS Excel 2007.

RESULTS

Total of 2630 condyles from 1315 panoramic radiographs were evaluated. 767 of panoramic radiographs were female's and 548 of them were male's. In the study, there were 784 patients over the age of 40 and 531 patients under the age of 40. The average age of the included individuals was 43.93 years, with an age range between 15-89 years.

According to the consensus, the condyles were highly symmetrical(table-1). Oval condyles were detected at a rate of 66% of the patients whose condyle type was symmetrical in the panoramic images (figure-2). However, crooked finger condyles were in symmetry with the lowest level at a rate of approximately ten percent. Most of the patients who exhibited asymmetry had a right condyle type-3(diamond)-left condyle type-1(oval) form (figure-3). The rarest combination of asymmetry was found to be either a right condyle type-3(diamond)- left condyle type-4(crooked finger), or a right condylar type-4(crooked finger)- left condylar type-3 (diamond) (figure 4).

At first, symmetrical or asymmetrical status of condyles were evaluated. In the study conducted on panoramic images, the probabilistic value is 0.789 (table-1). Therefore Pearson Chi-Square Test results concluded that symmetry/asymmetry appearance is independent of gender for the consensus in 5% confidence interval. Similar to gender results, age group indicator has no impact on symmetry/asymmetry appearance with p-value of consensus 0.677 (table-2). Although there was no significant relationship, the study distinguished data into two groups as age of under and over 40 in study groups symmetry was observed in consensus 68% of individuals over the age of 40, and 69% of individuals under the age of 40.

Type of condyles were studied with age groups and gender. The distribution of condyles with respect to age groups was interpreted. For the consensus, oval type of condyle was seen as the most common type and the crooked finger as the rarest one in both right and left condyles.

According to the results, a strongly significant relationship was found between the type of condyles and the age group (p-value: 0.05) (table-3). Moreover, a strongly significant relationship was found between gender and condyle types. (p-value: 0.00) (table-4). For the consensus at right condyles; 54% of women had oval condyle, while the lowest proportion (13%) of women had crooked finger condyles, in male patients 62% of the patients had oval condyle and 7% had crooked finger condyle. In both genders, oval condyle was observed with a significant intensity on the right and crooked finger condyle was the rarest. Left condyles were similar to the right side; oval condyles were seen in 57% of women and 61% of men and crooked finger condyles were observed most rarely in both genders.

According to consensus, oval condyle was observed at the highest rate among all types when both sides were evaluated separately within themselves; 57% oval on right side, 59% oval on left side and when both sides were evaluated together; oval type was found at a rate of 58%. Type of crooked finger was found at a rate of ten percentage on both sides as the rarest.

DISCUSSION

The study was performed on percentages and quantitative data of mandibular condyle shapes according to gender or age like the similar ones. This is useful because it provides to compare different populations or subgroups within a population.

The morphological view of the mandibular condyle may vary significantly between different age groups and different individuals [9,26,30]. Condyle findings in panoramic radiographs need to be interpreted with extreme caution. It is necessary to know the limitations of panoramic radiography when describing condyle morphology [19].

Researchs on condyle shape goes back to the 1960's. Yale et al performed the first research on this subject within the scope of 4 basic shapes of condyle head[31,32,33]. In the present study the condyle classification is based on the studies of Anussizuman et al and Shaikh et al [2,26].

This research aimed to reveal the rate of condyle types in a Turkish subpopulation. Condyle types and their rate were assessed in relation to age and gender. The study findings about the most common condyle type were oval type (in the range of; 57%) on both the right and the left side. Besides, condyle types differed significantly according to gender. Proportionally, the oval type was detected as more intense in males(61%). The most common combination of symmetry was seen as oval-oval.

The null hypothesis that the right and left mandibular condyles in a person mostly would be asymmetrical was rejected. The rate of asymmetry was found as 32%. This outcome may be due to the group of patients studied or the number of patients who didn't use the right and left sides of the jaw equally was less than expected.

Honda et al performed a study and reported that the panoramic radiography technique is beneficial on assesment of TMJ pathologies [9]. It's an evidence that about 20 years ago the panoramic radiograph's competence about TMJ pathologies was proved. In a similar study it was conducted in a different population, type of oval was the most common condyle type, while crooked finger was the least common like the current study. This prevalence was seen in all age groups and in both genders. In the same study it was found 74.2% of condyles as symmetrical with oval-oval type and it was the most commonly occuring among the other combinations. All the results of our study were consistent with the results of the study of Al-Saedi et al [1].

Similar to present study, another one was carried out by Sonal et al; the highest proportion in a population at 60% was the oval type condyle and crooked finger type was the least common at 2% [28]. In a study conducted in Bangladesh population the 'oval' was the most common type with 68%, and the 'crooked finger' was the rarest type. The most common combination both in male and female was 'oval-oval', the less common one was 'crooked finger-crooked finger' [2]. Consistent with literature, Shaikh et al found that oval type condyle was the most common [26]. In the current study, the oval condyle type was the most common and the crooked finger type was the rarest. It was seen that despite different populations and countries, it turns out that usually the common condyle type is the oval type. Shaikh et al, Choudhary et al and Ribeiro et al, in their studies in different country populations, each

showed that round-round combination was the most common in both genders [6,22,26]. They used a different classification as 'flat', 'pointed', 'angled' and 'round' condyle types. 'Round' type express the same type as the oval type in the classification used in the present study.

In Ashwinirani's study, the most common condyle type was 'round' in female, but 'angled' in male, different results were observed in male and female [4]. Ashwinirani used a different classification. In another study round type of condyle was again found to be the most common [24]. Similarly Maqbool et al, Al Saedi et al and Gindha et al revealed highly significant difference in condylar type between right and left sides in females and males [1,7,13].

Similar to this one, a significant relation was found between gender and condyle types in the current study. Thus the second hypothesis that there would be no correlation between condyle types and age and gender was also rejected. According to the consensus, for both sides (right and left) condyle type of oval was the most common in both genders. The rarest type was the crooked finger in both genders and sides.

Al Saedi et al, Nagaraj et al, Ashwinirani et al found no significant difference between age groups and condyle types [1,4,15]. Contrary to these studies, in the present study it was observed that there was a significant relationship between age groups and condyle types. The study was performed by Nalla et al revealed that toughness of bones decreases by approximately 40% from 40 to 100 years (16). Another study reported that morphological change of condyle is commonly seen in patients over the age of 40(90%) compared to under the age of 40(64%), (14). Based on these, in this study the patients classified into two groups in terms of age; over the age of 40 and under the age of 40. According to the consensus; the most common, oval condyle and the rarest crooked finger condyle were found both on the right and the left in individuals. Similarly, Shaikh et al found a significant relation between condyle morphology and age; they revealed that diamond shape was higher in the 56 and older age group.

Al Saedi et al reported 64.8% of radiographs had bilateral occurrence of same type and most common combination was oval-oval (46%) [1]. Similar to Al-Saedi, in another study approximately two-thirds of the panoramic radiographs had the same type of condyles bilaterally [19]. In the current study, in line with the results of previous studies, most of the patients had a symmetrical condylar shape with most common oval-oval combination.

However in Oliveiro's study, a more equal distribution between types is observed in older individuals, while a clear predominance of the 'round' type is observed among younger individuals. In the present study, condyle type of oval was seen distinctly more intense in both age groups and the other types were seen approximately at the same rates in both age groups.

During the study, no evaluation was made according to the dentition and edentulous status. The fact that the edentulous state was not included in the the study evaluation can be seen as a limitation of the study.

CONCLUSIONS

This study has demonstrated that evaluation of mandibular condyle shapes can be achieved through panoramic radiography.

According to the findings of this research, it has been concluded that there was no significant difference between bilateral occurrence of same condyle shape with gender and age. However, it has also been found that age and gender do affect the types of condyles.

The oval shape of condyles were most common for both genders and both age groups. The most common combination of symmetry was seen as Oval-Oval.

In future studies regarding this topic, clinical and radiological findings should be combined. By increasing the study sample and including clinical parameters such as dentition or edentulism status of patients, how long this condition has been going on in the study, more reliable information about populations will be provided.

Acknowledgement

We thank to Electrical Electronics Engineer M. Çağrı PEKER for the support he gave us at the statistical point of the study.

This study was performed at Department of Dentomaxillofacial Radiology in Gülhane Dentistry Faculty, University of Health Sciences, Ankara, Turkey.

Conflict of interest: None declared

REFERENCES

1. Al-Saedi IL, Taei RA, Jasim NHA et al. A Panoramic Study of the Morphology of Mandibular Condyle in a Sample of Population from Basrah City. *Int. J. Morphol.* 2020; 38(6):1707-12.
2. Anisuzzaman MM, Khan SR, Khan MTI, Abdullah MK, Afrin A. Evaluation of Mandibular Condylar Morphology by Orthopantomogram In Bangladeshi Population. *Update Dental College Journal.* 2019 April; 9(1): 29-31.
3. Arayapisit T, Ngamsom S, Duangthip P, Wongdit S, Wattanachaisiri S, Joonthongvirat Y, Somsak Y Mitirattanakul (2020) Understanding the mandibular condyle morphology on panoramic images: A conebeam computed tomography comparison study, CRANIO®
4. Ashwinirani SR, Patil ST, Nair B, Rajmane Y, Kamala KA. Morphological Variations Of Condylar Process And Sigmoid Notch Using Orthopantomograms In Western Part Of Maharashtra Population. *Int J Appl Dent Sci.* 2018; 4(1):160-3.
5. Chaudhary S, Srivastava D, Jaetli V, Tirth A. Evaluation of condylar morphology using panoramic radiography in normal adult population. *Int J Sci Stud.* 2015; 2 (11): 164-8.
6. Choudhary A, Ahuja US, Rathore A, et al. Association of Temporomandibular Joint Morphology in Patients with and without Temporomandibular Joint Dysfunction: A Cone-Beam Computed Tomography Based Study. *Dent Res J (Isfahan).* 2020 Sep 7;17(5):338-346. PMID: 33343841; PMCID: PMC7737818.
7. Gindha GS, Singh TP, Sood KS, Maharana SS. Amorphometric Study of Condylod Process of Dry Human Mandible for Sexing From Its Shape. *MOJ Anat Physiol.* 2017;3(2):58- 62.
8. Hegde S, Praveen BN, Shetty SR (2013) Morphological and Radiological Variations of Mandibular Condyles in Health and Diseases: A Systematic Review. *Dentistry* 3: 154. doi:[10.4172/2161-1122.1000154](https://doi.org/10.4172/2161-1122.1000154)
9. Honda E, Yoshino N, Sasaki T. Condylar Appearance In Panoramic Radiograms Of Asymptomatic Subjects And Patients With Temporomandibular Disorders. *Oral Radiol.* 1994;10:43-53.
10. Kanjani V, Kalyani P, Patwa N, Sharma V. Morphometric Variations in Sigmoid Notch and Condyle of the Mandible: A Retrospective Forensic Digital Analysis in North Indian Population. *Arch Med Health Sci.* 2020;8: 31-4.
11. Kaplan AS. Plain, tomographic, and panoramic radiography and radionuclide imaging. In: Kaplan AS, Assael LA (ed.). *Temporomandibular disorders, diagnosis and treatment.* W.B. Saunders, Philadelphia 1991: 312–36.
12. Katsavrias EG, Halazonetis DJ. Condyle and fossa shape in Class II and Class III skeletal patterns: a morphometric tomographic study. *Am J Orthod Dentofacial Orthop.* 2005 Sep;128(3):337-46.
13. Maqbool S, Wani BA, Chalkoo AH, Sharma P. Morphological Assessment of Variations of Condylar Head And Sigmoid Notch on Orthopantomograms of Kashmiri Population. *Int J Recent Sci Res.* 2018; 9(10):29162-5.
14. Mathew AL, Sholapurkar AA, Pai KM. Condylar Changes and Its Association with Age, TMD, and Dentition Status: A Cross-Sectional Study. *International Journal of Dentistry.* 2011; 2011, Article ID 413639, 7 pages, 2011. <https://doi.org/10.1155/2011/413639>
15. Nagaraj T, Nigam H, Santosh HN, Gogula S, et al. Morphological Variations of the Coronoid Process, Condyle And Sigmoid Notch As an Adjunct in Personal Identification. *J Med Radiol Pathol Surg.* 2017; 4(2):1-5.

16. Nalla RK, Kruzic JJ, Kinney JH, Ritchie RO. Effect of Aging on the Toughness of Human Cortical Bone: Evaluation by R-curves. *Bone*. 2004; 35(6): 1240-1246.
17. Neto JV, Estrela C, Bueno MR, Guedes OA, Porto OCL, et al. (2010) Mandibular condyle dimensional changes in subjects from 3 to 20 years of age using Cone- Beam Computed Tomography: A preliminary study. *Dental Press J Orthod* 15: 172-181.
18. Okeson JP. History and examination for temporomandibular disorders. In: Okeson JP (ed.). *Management of temporomandibular disorders and occlusion*. 4th ed. Mosby, St. Louis 1998: 234–309.
19. Oliveira-Santos C, Bernardo RT, Capelozza ALA. Mandibular Condyle Morphology on Panoramic Radiographs of Asymptomatic Temporomandibular Joints. *IJD Int J Dent (Recife)*. 2009; 8(3):114-8.
20. Orhan K. Introduction to TMJ imaging. In: Rozylo-Kalinowzka I, Orhan K (ed). *Imaging of the temporomandibular joint*. Springer, Switzerland 2019: 1-9.
21. Ozgedik S, Karacayli U, Ozarslanturk S, Avsever H, Orhan K. Trifid Mandibular Canal and Lingual Accessory Mental Foramen: A Case of Two Rare Anatomical Variations. *Dentistry Adv Res*. 2017; 2:136. doi: 10.29011/2574-7347.100036
22. Ribeiro E, Sanches M, Alonso L, et al. Shape and Symmetry of Human Condyle and Mandibular Fossa. *Int J Odontostomatol*. 2015; 9(1): 65–72.
23. Ross BR, Johnston MC (1994) Developmental anomalies and dysfunction. In: Zarb GA, Carlsson GE, Sessle BJ, Mohl ND (eds). *Temporomandibular joint and masticatory muscle disorders*. Mosby 221-222.
24. Sahithi D, Reddy S, Teja Divya DV, Koneru J, Praveen KNS, Sruthi R. Reveal the concealed – Morphological variations of the coronoid process, condyle and sigmoid notch in personal identification. *Egyptian Journal of Forensic Sciences*. 2015; 6(2):108-13.
25. Sakul BU, Bilecenoglu B, Ocak M. Anatomy of the temporomandibular joint. In: Rozylo-Kalinowzka I, Orhan K. (ed). *Imaging of the temporomandibular joint*. Springer, Switzerland 2019: 9-12.
26. Shaikh AH, Ahmed S, Ahmed AR, Das G, Taqi M, Nisar S, Khan O. Assessment of radiographic morphology of mandibular condyles: a radiographic study. *Folia Morphol (Warsz)*. 2022;81(2):481-6. doi: 10.5603/FM.a2021.0049. Epub 2021 May 21. PMID: 34018177.
27. Singh B, Kumar NR, Balan A, et al. Evaluation of Normal Morphology of Mandibular Condyle: A Radiographic Survey. *J Clin Imaging Sci*. 2020;17;10:51, doi:10.25259/JCIS_84_2020. PMID: 32874756; PMCID: PMC7451156.
28. Sonal V, Sandeep P, Kapil G, Christine R. Evaluation Of Condylar Morphology Using Panoramic Radiography. *J Adv Clin Res Insights*. 2016; 3:5-8.
29. Ulhuq A. *Management of Temporomandibular Disorders and Occlusion* (6th edition). *Br Dent J*. 2008; 204:535, doi:10.1038.
30. Yalcin ED, Ararat E. Cone-Beam computed tomography study of mandibular condylar morphology. *J Craniofac Surg*. 2019; 30(8): 2621–2624, doi: 10.1097/SCS.0000000000005699, indexed in Pubmed: 31261335.
31. Yale SH, Allison BD, Hauptfuehrer JD. An Epidemiological Assessment Of Mandibular Condyle Morphology. *Oral Surgery, Oral Medicine, Oral Pathology and Oral Radiology*. 1966;21(2):169-77.
32. Yale SH et al. [Some Observations on the Classification of Mandibular Condyle Types. Oral Surg Oral Med Oral Pathol. 1963 May; 16:572-7, doi:10.1016/0030-4220\(63\)90146-4.](#)
33. Yale SH et al. [Laminagraphic Cephalometry in the Analysis of Mandibular Condyle Morphology. A Preliminary Report. Oral Surg Oral Med Oral Pathol. 1961 Jul;14:793-805, doi: 10.1016/s0030-4220\(61\)80008-x.](#)

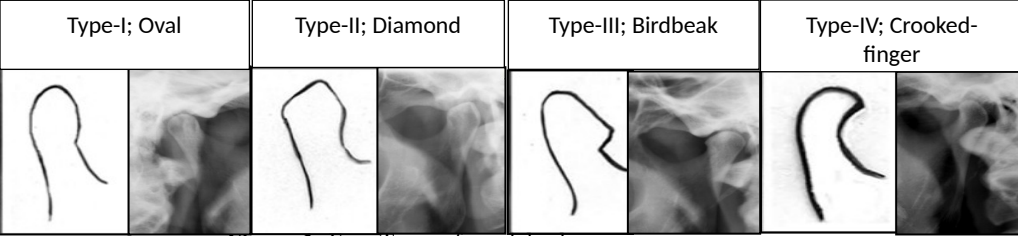


Figure-1: Four Types of condyle shapes.

Figure 2. A panoramic radiograph which shows symmetry on right and left condyles as oval (type-1)- oval (type-1)

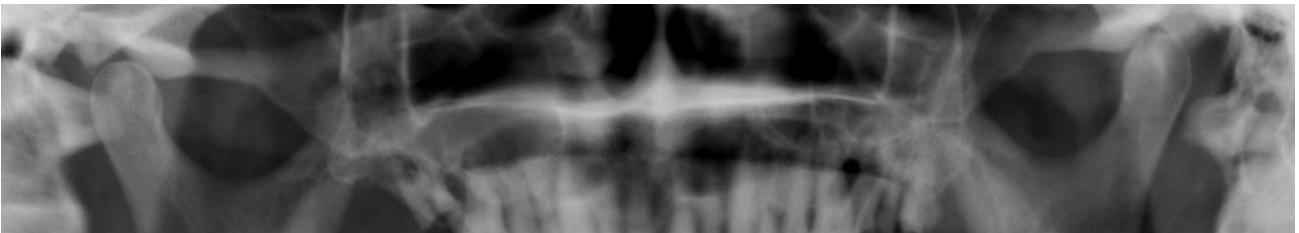


Figure 3. The most common asymmetrical combination seen in the study was bird-beak(type-3)- oval (type-1) for the right and left condyle

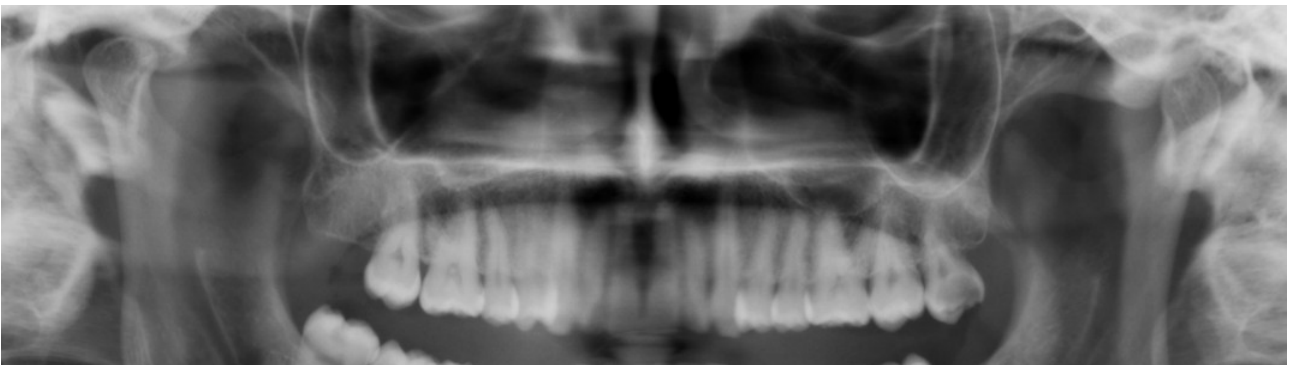

Figure 4. The rarest asymmetrical combination seen in the study was bird-beak(type-3)-crooked finger(type-4) for the right and left condyle

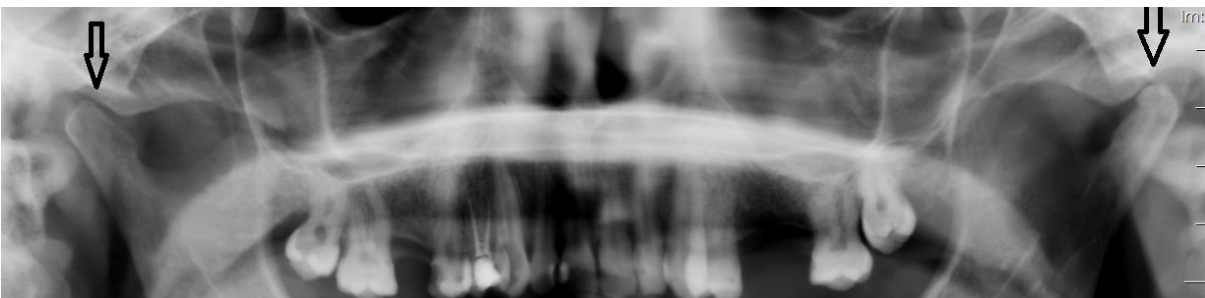


Table 1. Comparing the symmetry status of right and left condyles between both genders

	Symmetrical condyle types		Asymmetrical condyle types		Total		Does symmetry differ subject to gender? (no) p=0.789
	n	%	n	%	n	%	
Female	526	40%	241	18%	767	58%	
Male	372	28%	176	14%	548	42%	

Table 2. Comparing the symmetry status of right and left condyles between age groups

	Symmetrical condyle types		Asymmetrical condyle types		Total		Does symmetry differ subject to age? (no) p=0.677
	n	%	n	%	n	%	
Under the age of 40	361	28%	170	13%	531	41%	
Over the age of 40	537	40%	247	19%	784	59%	

Table 3. Distribution of condyle types according to age

		Condyle type 1	Condyle type 2	Condyle type 3	Condyle type 4	Total	Does condyle type differ subject to age group? (yes) p=0.05
		n	n	n	n	n	
Under age of 40	n	609	164	155	134	1062	
	%	23,2%	6.2%	5.9%	5.1%	40.4%	
Over age of 40	n	915	260	256	137	1568	
	%	34.7%	9.9%	9.8%	5.2%	59.6%	
Total	n	1524	424	411	271	2630	
	%	57.9%	16.1%	15.6%	10.3%	100.0%	

Table 4. Distribution of condyle types according to gender

		Condyle type 1	Condyle type 2	Condyle type 3	Condyle type 4	Total	Does condyle type differ subject to gender? (yes) p=0.00
		n	n	n	n	n	
Female	n	848	288	202	196	1534	
	%	32.2%	10.9%	7.7%	7.5%	58.3%	
Male	n	676	136	209	75	1096	
	%	25.7%	5.2%	8%	2.8%	41.7%	
Total	n	1524	424	411	271	2630	
	%	57.9%	16.1%	15.6%	10.3%	100.0%	