



June 2023

## Unusual Mode of Endovascular Femoral Sheath Failure and Disruption Requiring Open Operative Retrieval

Ali H. Hakim et. al.

*University of Nebraska Medical Center*

Tell us how you used this information in this [short survey](#).

Follow this and additional works at: <https://digitalcommons.unmc.edu/gmerj>



Part of the [Higher Education Commons](#), and the [Medicine and Health Sciences Commons](#)

### Recommended Citation

Hakim, A. H. Unusual Mode of Endovascular Femoral Sheath Failure and Disruption Requiring Open Operative Retrieval. *Graduate Medical Education Research Journal*. 2023 Jun 30; 5(1).  
<https://digitalcommons.unmc.edu/gmerj/vol5/iss1/87>

This Conference Proceeding is brought to you for free and open access by DigitalCommons@UNMC. It has been accepted for inclusion in *Graduate Medical Education Research Journal* by an authorized editor of DigitalCommons@UNMC. For more information, please contact [digitalcommons@unmc.edu](mailto:digitalcommons@unmc.edu).

---

## Unusual Mode of Endovascular Femoral Sheath Failure and Disruption Requiring Open Operative Retrieval

Creative Commons License



This work is licensed under a [Creative Commons Attribution-Noncommercial-No Derivative Works 4.0 License](https://creativecommons.org/licenses/by-nc-nd/4.0/).

## Not Just Testicles and Ovaries: A Case Report of Gallbladder Torsion

Jason Lizalek<sup>1</sup>, Antonia Gurney<sup>2</sup>, Olabisi Sheppard<sup>1</sup>

<sup>1</sup>Department of Surgery, College of Medicine, University of Nebraska Medical Center

<sup>2</sup>Department of Radiology, College of Medicine, University of Nebraska Medical Center

**Mentor:** Olabisi Sheppard

**Program:** General Surgery

**Type:** Case Report

**Background:** Gallbladder torsion is a rare cause of acalculous cholecystitis. More common in elderly women, it is an important diagnosis to include in the differential for right upper quadrant pain. We describe intra-operative diagnosis of gallbladder torsion as the etiology of gangrenous cholecystitis and bilious peritonitis.

**Case:** A 91-year-old woman presented with two days of right-sided abdominal pain. Examination revealed Murphy's sign and tenderness in the right lower quadrant. Labs revealed a leukocytosis, 22,000, bandemia, 19%, lactic acid, 2.1, total bilirubin, 1.1, and normal transaminase levels. Computed tomography demonstrated a distended and thick-walled gallbladder with biliary ductal dilatation suggestive of

acute cholecystitis. Ultrasound revealed a gallbladder wall thickness, 0.80 cm, common bile duct diameter, 1.2 cm, and no cholelithiasis. Magnetic retrograde cholangiopancreatography did not reveal ductal obstruction. Intravenous antibiotics and crystalloid resuscitation were initiated. The patient was taken to the operating room for laparoscopic cholecystectomy. Intra-operatively, there was purulent bilious ascites, adhesions from the gallbladder to the omentum and hepatic flexure of the colon, and patchy necrosis of the gallbladder. The gallbladder appeared rotated 180° counterclockwise with the infundibulum positioned anterosuperior and the fundus posteriorly. The gallbladder was rotated clockwise. There were minimal attachments from the gallbladder to the cystic plate and a pendulous cystic mesentery. The cholecystectomy was performed. The pathology report revealed transmural necrosis and no malignancy. The patient was discharged postoperative day 7.

**Conclusion:** We demonstrate a rare case of perforated gangrenous acalculous cholecystitis from gallbladder torsion. Despite improvement in imaging technology, it is often a diagnosis made intra-operatively.

<https://doi.org/10.32873/unmc.dc.gmerj.5.1.085>

## Unusual Mode of Endovascular Femoral Sheath Failure and Disruption Requiring Open Operative Retrieval

Ali H. Hakim<sup>1</sup>, William E. Poulson<sup>2</sup>, Andrew M. Goldsweig<sup>3</sup>, Iraklis I. Pipinos<sup>1</sup>

<sup>1</sup>Department of Surgery, College of Medicine, University of Nebraska Medical Center

<sup>2</sup>Department of Surgery, University of Kansas Medical Center

<sup>3</sup>Department of Cardiology, Baystate Medical Center

**Mentor:** Iraklis Pipinos

**Program:** General Surgery

**Type:** Case Report

**Background:** Lost intravascular foreign body, commonly lost guidewires and sheath fragments, remains an important cause of retained foreign bodies. We describe an unusual mode of introducer sheath disruption.

**Case:** Patient was a 31-year-old female with left main coronary dissection treated with coronary artery bypass. Patient was placed on right femoral extracorporeal membrane oxygenation with plans for additional Impella support via left femoral access.

To achieve antegrade perfusion of the left lower limb with Impella, a retrograde (7Fr x 10cm) and antegrade (7Fr x 11cm) sheath were placed in the small left femoral artery. The antegrade sheath was found to have inadvertently run through the retrograde sheath and both were removed. Unfortunately, the distal 7 cm portion of the retrograde

sheath sheared off. Retrieval attempts using balloons and snares were unsuccessful. Open retroperitoneal access was performed. The edge of the sheath and wire tip were tenting the common iliac artery. A 2 cm arteriotomy was made. The sheath and wire were removed, and a focal dissection was repaired. Angiogram confirmed patent repair. Patient survived the initial operation but her cardiac function never recovered. She remained on ECMO and was not a transplant candidate. Once extubated, she chose comfort care measures only and passed on postoperative day 19.

**Conclusion:** This unique mode of failure of an introducer sheath has not previously been reported. In the context of modern circulatory support, this case highlights the importance of dual open surgical and endovascular expertise with interdisciplinary collaboration for the management of these unusual complications.

<https://doi.org/10.32873/unmc.dc.gmerj.5.1.086>

## Eruptive Lichenoid Actinic Keratosis: A Potential Side Effect of IVIG

Allison M. Lloyd-McLennan<sup>1</sup>, Corey J. Georgesen<sup>1</sup>, Elizabeth Mata<sup>1</sup>, Melodi Javid Whitley<sup>1,2</sup>

<sup>1</sup>Department of Dermatology, College of Medicine, University of Nebraska Medical Center

<sup>2</sup>Department of Dermatology, Duke University Medical Center

<sup>3</sup>Department of Dermatology, College of Medicine-Tucson, University of Arizona

**Mentor:** Melodi Javid Whitley

**Program:** Dermatology

**Type:** Case Report

**Background:** Intravenous Immune Globulin (IVIG) is used to treat multiple disorders, including immunodeficiencies, autoimmune conditions, and inflammatory disorders. Inflammatory cutaneous side effects occur in 6% of patients receiving IVIG, including urticaria, atopic disease, and lichenoid dermatitis.

Actinic Keratoses (AKs) are pre-cancerous lesions that present as scaly and erythematous papules and plaques on chronically sun-exposed skin. Many drugs cause inflammation

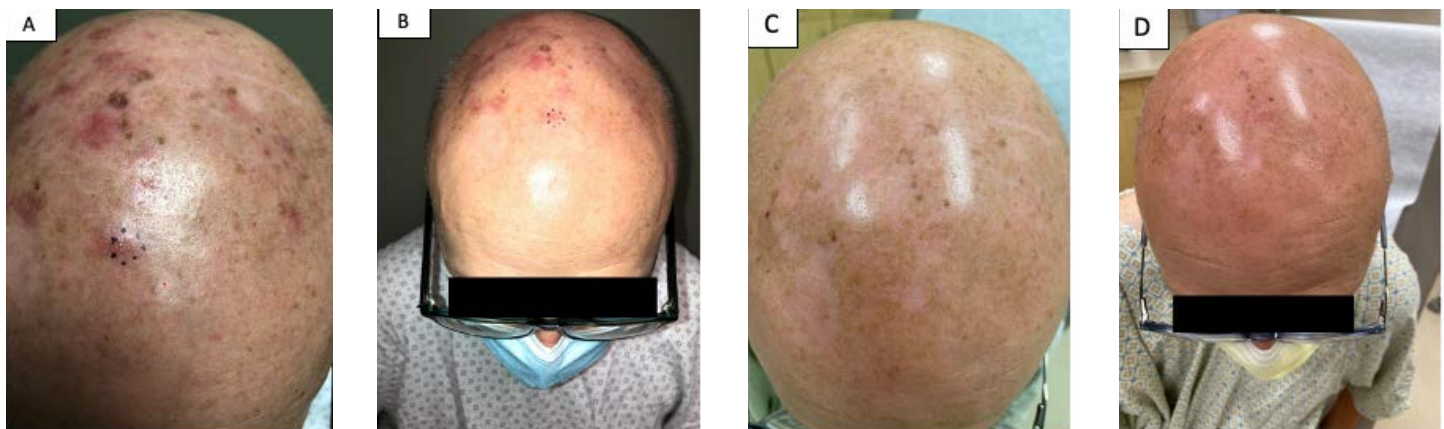
of preexisting and subclinical AKs, however, this case represents the first report of IVIG-induced lichenoid AK.

**Case:** A 67-year-old male with no skin cancer history presents with abrupt onset of red papules on the scalp. At the time of evaluation, the lesions had been present for two months. He had a history of spinal cord lesions of unknown etiology and recently initiated weekly IVIG (0.4mg/kg). On exam, he had scattered red scaly thin papules on the frontal and mid scalp, bilateral ears, and lateral face (Figure 1A & 1B). Shave biopsy of a central scalp papule showed partial thickness squamous atypia with areas of lichenoid interface dermatitis consistent with a lichenoid AK. The patient was treated with

hydrocortisone 2.5% ointment and canceled his two-month follow-up appointment due to significant improvement (Figure 1C & 1D). When the patient returned to clinic eight months later, his scalp was clear, with resolution of all AKs. No additional treatment was necessary.

**Conclusion:** Lichenoid inflammation of pre-existing actinic disease may be an underrecognized side effect of IVIG therapy. Rashes in immunocompromised patients can cause significant concern; therefore, it may be beneficial to screen for AKs prior to starting IVIG and counsel patients on possible flares.

<https://doi.org/10.32873/unmc.dc.gmerj.5.1.087>



**Figure 1:** A, B. Scattered red scaly thin papules on the frontal and mid scalp. C, D. Frontal and mid scalp clear of lesions after a short course of topical steroid treatment.

## Allergic Contact Dermatitis to Parabens in Topical Corticosteroids (including “hypoallergenic” triamcinolone ointment!!): Definite Relevance to a “Non-Allergen”

Joohee Han<sup>1,2</sup>, Alexander Idrogo-Lam<sup>3</sup>, Erin M. Warshaw<sup>2,4,5</sup>

<sup>1</sup>Clarkson Family Medicine, Nebraska Medicine

<sup>2</sup>Park Nicollet Contact Dermatitis Clinic

<sup>3</sup>Integra Dermatology

<sup>4</sup>Department of Dermatology, University of Minnesota

<sup>5</sup>Department of Dermatology, Minneapolis Veterans Affairs Medical Center

**Mentor:** Erin M. Warshaw

**Program:** Clarkson Family Medicine

**Type:** Case Report

**Background:** We present a case of a clinically relevant contact allergy to parabens.

**Case:** A 35-year-old male welder presented with a 5-year history of pruritic dermatitis

which initially began on his hands shortly after starting his first welding job. The rash worsened and spread to involve his face (especially eyelids, preauricular ears, and infra-oral chin) as well as his neck, arms, axillae, back, legs, feet and groin. A biopsy of his left upper arm demonstrated spongiotic dermatitis with eosinophils. Patch testing was performed to the 2020-2021 North American Contact Dermatitis Group

screening series (80 allergens) as well as several supplemental series (preservatives, emulsifiers, personal care products, fragrances, sunscreen, corticosteroids, medicaments) and 17 of his own products. Important patch test results included + reactions to paraben mix 12% pet. and 4 individual parabens (butyl, ethyl, methyl, propyl, all 3% pet.) as well as to his Cortizone-10 cream (contained methyl and propyl parabens). Other relevant

positive reactions included multiple rubber accelerators, his rubber work gloves, nickel 2.5% and 5% pet., and methylisothiazolinone 0.2% aq., methylisothiazolinone/methylchloroisothiazolinone 0.02% aq. Pertinent negatives included other potential allergens in Cortizone-10 cream (mineral oil, glycerin, cetearyl alcohol, white/yellow beeswax, tocopherol, propylene glycol, cetyl alcohol, aloe vera liquid). Comprehensive

investigation discovered parabens in multiple products including methyl and propyl parabens in his Taro triamcinolone 0.1% ointment, generally considered to be a very safe “hypoallergenic” topical corticosteroid.

**Conclusion:** Physicians should be aware of the presence of parabens, a rare allergen, in low-allergen corticosteroid formulations.

<https://doi.org/10.32873/unmc.dc.gmerj.5.1.088>

## Coil and Gel Foam Embolization of a Replaced Common Hepatic Artery Pseudoaneurysm: A Rare Anatomic Variant

**Kevin Cokingtin**<sup>1</sup>, Benjamin Haverkamp<sup>1</sup>

<sup>1</sup>Department of Radiology, College of Medicine, University of Nebraska Medical Center

**Mentor:** Benjamin Haverkamp

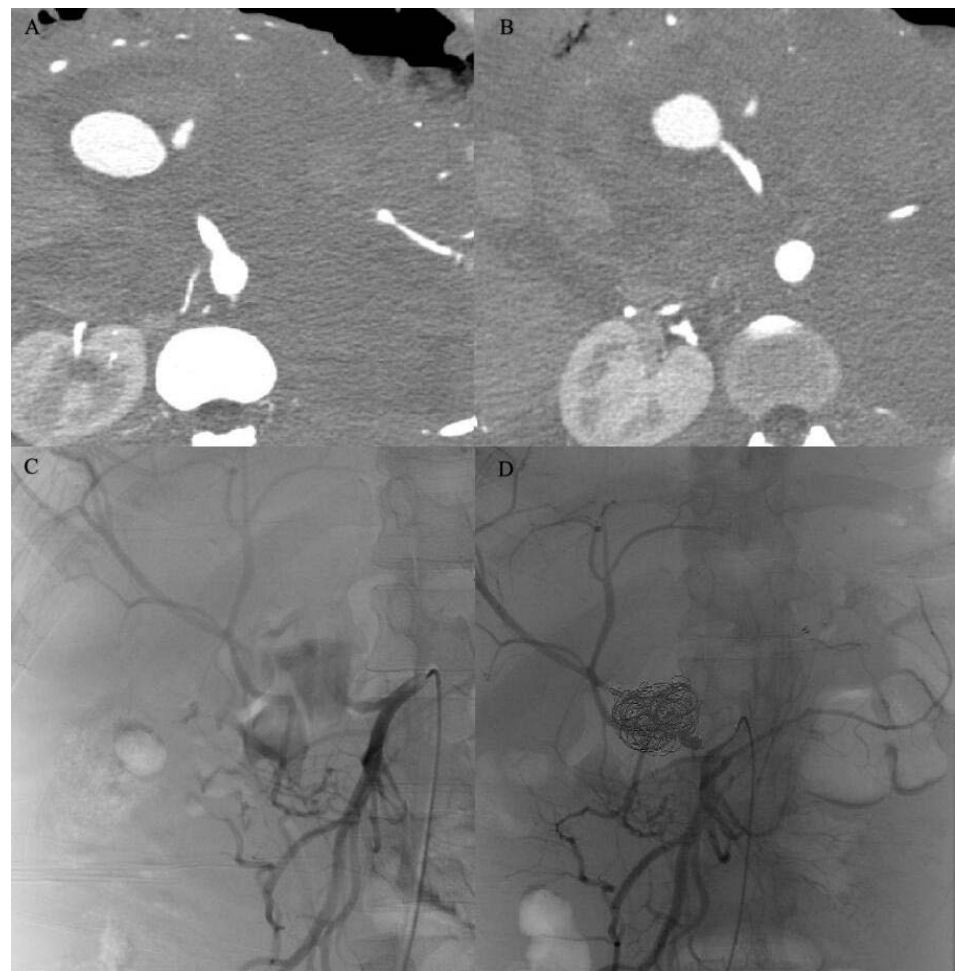
**Program:** Radiology

**Type:** Case Report

**Background:** A replaced common hepatic artery (CHA) is a rare anatomic variant in which the CHA arises from the superior mesenteric artery (SMA), when it would normally arise from the celiac trunk. We present a case of a replaced CHA pseudoaneurysm treated with coil and gel foam embolization.

**Case:** A 39-year-old male with a history of malignant gastrointestinal stromal tumor presented for routine staging MRI of the abdomen, which demonstrated a bleeding pseudoaneurysm arising from a replaced CHA. These findings were confirmed on subsequent triple-phase CT angiogram of the abdomen and pelvis (Figure 1A & 1B) and acute blood loss anemia confirmed on laboratory testing.

The patient was then referred to interventional radiology for emergent embolization arteriogram. Selective SMA arteriogram revealed the CHA arising from the SMA (Figure 1C) with a bleeding pseudoaneurysm arising from the replaced CHA. The pseudoaneurysm distal common hepatic outflow artery, pseudoaneurysm sac, and proximal common hepatic inflow artery were then embolized with coils. Persistent bleeding on post-coil angiogram was then treated with gel foam and additional coils. SMA and replaced CHA angiograms demonstrated no residual bleeding, with preserved flow to the right and left hepatic arteries via the gastroduodenal artery from the SMA pancreaticoduodenal cascade (Figure 1D). No immediate post-procedure complications were experienced.



**Figure 1:** A&B. CT angiogram images demonstrated a pseudoaneurysm arising from a replaced common hepatic artery (CHA). C. Selective superior mesenteric artery (SMA) angiogram confirmed a replaced CHA pseudoaneurysm with evidence of active bleeding. D. Selective SMA post-coil and gel foam embolization angiogram demonstrated no angiographic evidence of active bleeding.

**Conclusion:** A replaced CHA is rarely encountered incidentally, and a bleeding pseudoaneurysm arising from a replaced CHA is even more rare. Successful treatment of this condition requires essential knowledge of

variant abdominal vascular anatomy to ensure preserved flow to vital end organs following treatment.

<https://doi.org/10.32873/unmc.dc.gmerj.5.1.089>