



June 2023

Pediatric Pedal Plantar Papules

Dillon Clarey et. al.

University of Nebraska Medical Center

Tell us how you used this information in this [short survey](#).

Follow this and additional works at: <https://digitalcommons.unmc.edu/gmerj>



Part of the [Higher Education Commons](#), and the [Medicine and Health Sciences Commons](#)

Recommended Citation

Clarey, D. Pediatric Pedal Plantar Papules. Graduate Medical Education Research Journal. 2023 Jun 30; 5(1).

<https://digitalcommons.unmc.edu/gmerj/vol5/iss1/80>

This Conference Proceeding is brought to you for free and open access by DigitalCommons@UNMC. It has been accepted for inclusion in Graduate Medical Education Research Journal by an authorized editor of DigitalCommons@UNMC. For more information, please contact digitalcommons@unmc.edu.

Pediatric Pedal Plantar Papules

Creative Commons License



This work is licensed under a [Creative Commons Attribution-Noncommercial-No Derivative Works 4.0 License](https://creativecommons.org/licenses/by-nc-nd/4.0/).

Primary CNS T-Cell Lymphoma Presenting as a Brainstem Lesion in a Young Female

Dmitry Balian¹, Jennifer Shaw¹, Hannah Maldonado¹, Shannon Lynch²

¹Department of Neurological Sciences, College of Medicine, University of Nebraska Medical Center

²Department of Ophthalmology and Visual Sciences, College of Medicine, University of Nebraska Medical Center

Mentor: Shannon Lynch

Program: Neurology

Type: Case Report

Background: Primary central nervous system (CNS) T-cell lymphomas are rare and comprise less than 5% of all CNS lymphomas. A significant majority present as hemispheric mass lesions in the sixth or seventh decades of life. Here we present a unique case of primary CNS T-cell lymphoma presenting as a brainstem lesion in a young female.

Case: A 24-year-old healthy female presented to our emergency room for recurrent headache, vertigo, diplopia, bilateral upper extremity weakness, and left hemifacial paresthesias. She was seen at an outside hospital five days prior for similar symptoms. She was treated for suspected ophthalmoplegic migraine and discharged home. Magnetic resonance imaging (MRI) performed at our facility showed a 1.2cm lesion in the left dorsal cervicomedullary junction concerning for demyelination or glioma (Figure 1). MRI of cervical and thoracic spine did not show any additional demyelinating lesions. Cerebrospinal fluid (CSF) studies did not show any signs of infection or malignancy. A presumptive diagnosis of demyelinating disease was made. She was treated with 5 days of intravenous methylprednisolone and 5 sessions of plasma exchange with continued decline. Repeat CSF studies were unrevealing. Whole body positron emission tomography (PET) was negative for malignancy. MRI spectroscopy findings were not consistent with high grade glioma. Brainstem biopsy was ultimately pursued. Pathology was consistent with primary CNS T-cell lymphoma.

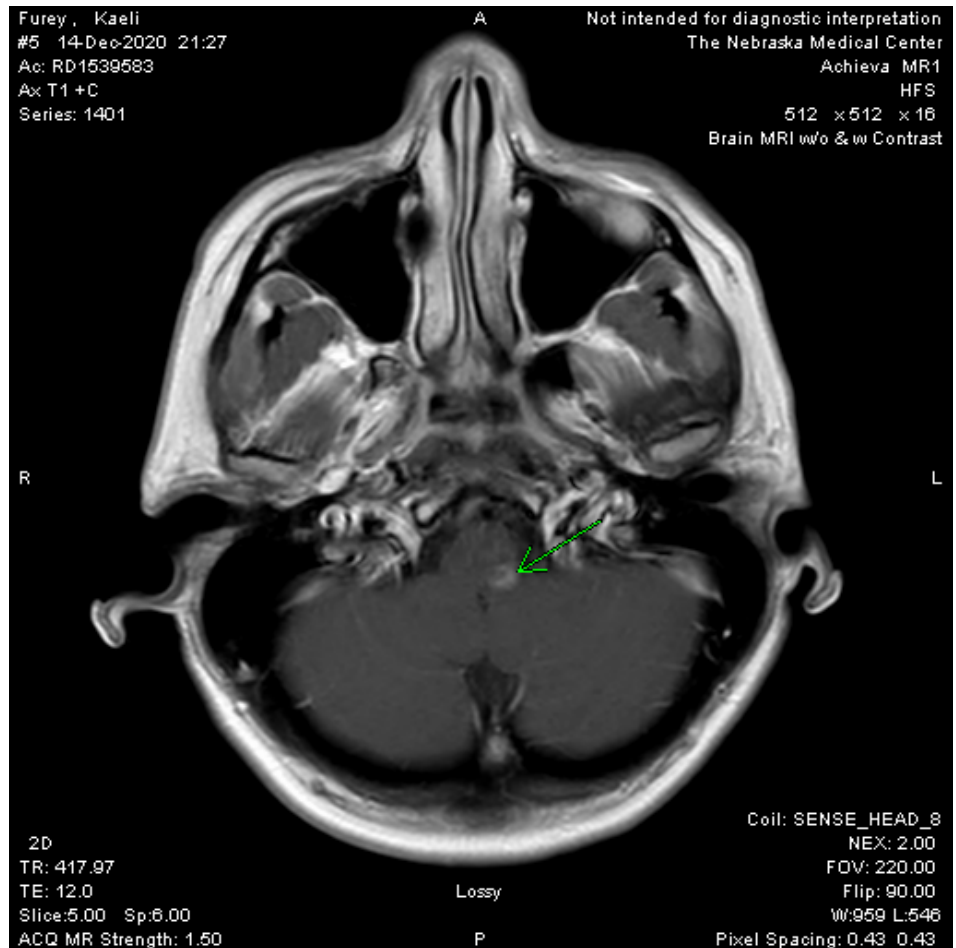


Figure 1: Axial T1 with contrast MRI showing left dorsal cervicomedullary junction lesion with patchy enhancement.

Conclusion: Primary CNS T-cell lymphomas are exceedingly rare malignancies and rarer still in young patients. Brainstem lesions are atypical and may initially suggest alternative diagnoses. Brain biopsy should be considered when the diagnosis remains unclear.

<https://doi.org/10.32873/unmc.dc.gmerj.5.1.076>

Treatment of IT Band Tendinopathy and Gerdy’s Tubercle Hypertrophy with Dextrose Prolotherapy

Ryan Wendt¹, Jason Meredith¹

¹Department of Family Medicine, College of Medicine, University of Nebraska Medical Center

Mentor: Jason Meredith

Program: Family Medicine

Type: Case Report

Background: Distal Iliotibial (IT) band tendinopathy is an overuse injury often caused by weakness of the hip abductors. Patients often make improvement with

physical therapy; however, when patients fail to improve, other less well studied nonsurgical options may be deployed. This includes needle tenotomy, biologic injection, prolotherapy, and shockwave therapy.

Case: A 49-year-old female presented for evaluation of left knee pain. She runs 40 miles per week. Her pain occurs immediately when running, persists after, and she awakens with

pain. She notes a “lump” on her lateral knee that grows as her pain worsens. On exam, she had a ping pong ball sized prominence over the location of Gerdy’s tubercle. Tenderness to palpation over Gerdy’s tubercle and Hoffa’s fat pad with a thickened IT band were noted. Single leg squat demonstrated significant dysfunction in core and pelvic strength. Plain films and MRI demonstrated hypertrophied Gerdy’s tubercle, edema within Hoffa’s fat

pad near the IT band attachment and partial tear of distal IT band.

She did 8 weeks of physiotherapy with minimal improvement. The decision was made to undergo ultrasound guided tenotomies with dextrose prolotherapy monthly for three treatments. She made

steady improvement in pain and swelling over the course of therapy with 95% improvement after the 3rd session. One month after final treatment she completed a local 5K without pain.

Conclusion: This case presents an example of both needle tenotomy and dextrose

prolotherapy being used to successfully treat distal IT band tendinopathy. Dextrose prolotherapy can provide a cost-conscious, nonsurgical treatment modality for chronic tendinopathy.

<https://doi.org/10.32873/unmc.dc.gmerj.5.1.077>

Cutaneous Myxofibrosarcoma of the Nasal Tip

Tyler D. Evans¹, Jacob Schneider², Alfredo Siller Jr.¹, Adam V. Sutton¹, Corey Georgesen¹

¹Department of Dermatology, College of Medicine, University of Nebraska Medical Center

²College of Medicine, University of Nebraska Medical Center

Mentor: Adam V. Sutton

Program: Dermatology

Type: Case Report

Background: Myxofibrosarcoma (MFS) is a connective tissue neoplasm seen in the elderly that typically presents in the subcutaneous tissue of the lower extremities. MFS presenting with epidermal changes is rare, especially in the head and neck region, with only six known cases reported. Workup for MFS includes a full body PET/CT to evaluate for metastasis, along with more targeted imaging, to aid surgical planning. Standard treatment includes wide local excision (WLE) with up to 2 cm margins and consideration of chemotherapy or radiation. Recurrence rates are upwards of 60% and overall metastatic risk of approximately 30%. The 5-year survival for MFS is directly correlated to the tumor's grading, which is stratified into low, intermediate, or high grade based on pathologic features.

Case: An 83-year-old male presented for a Mohs micrographic surgery (MMS) consult with outside biopsy results read as atypical fibroxanthoma of the nasal tip. The lesion was treated with MMS and was cleared. Surgical debulking was sent for paraffin sections and revealed a spindle cell and myxoid dermal neoplasm with hyper and hypo cellular areas and curvilinear vessels consistent with a cutaneous MFS, intermediate grade (Figure 1). Immunohistochemistry supported this diagnosis with D2-40 highlighting vessel architecture and Ki-67 positivity in > 30% of lesions cells.

Conclusion: MFS of the head or neck represents a rare clinical finding with only six known prior cases reported. Due to such high recurrence rates after WLE, and risk of metastasis, total and comprehensive margin assessment with MMS is becoming an important treatment modality for these neoplasms.

<https://doi.org/10.32873/unmc.dc.gmerj.5.1.078>

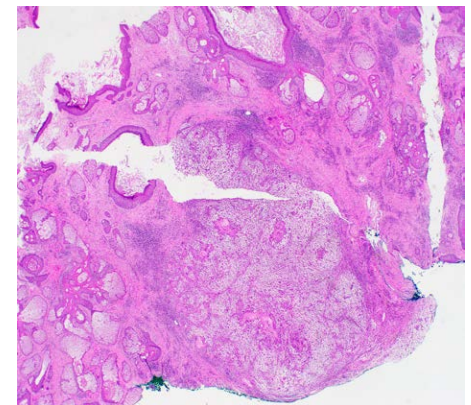


Figure 1. H&E highlights the myxoid, spindle cell, nature of the neoplasm with hyper and hypocellular areas. The tumor is composed of spindled, epithelioid cells, with prominent pleomorphism, multiple nucleoli, and several mitoses

Pediatric Pedal Plantar Papules

Dillon Clarey¹, Sarah Mullen², Ritu Swali¹, Nicole Harter^{1,3}

¹Department of Dermatology, College of Medicine, University of Nebraska Medical Center

²College of Medicine, University of Nebraska Medical Center

³Division of Pediatric Dermatology, Children's Hospital & Medical Center

Mentor: Nicole Harter

Program: Dermatology

Type: Case Report

Background: Precalcaneal congenital fibrolipomatous hamartomas are skin-colored, benign nodules of mature adipose enveloped in fibrous sheaths that are present at birth or shortly after. They are usually bilateral on the precalcaneal medial aspect of the plantar foot but have been reported to be unilateral, retrocalcaneal, or on palms. Etiology is possibly related to failure of fetal tissues to involute, fat herniation through plantar fascia, or a genetic mechanism.

Case: We present a 2-year-old female with bilateral, symmetric, skin-colored nodules of the precalcaneal medial feet that were noticed at 2 months of age and had not changed in size or shape that were consistent with precalcaneal congenital fibrolipomatous hamartomas. Given distribution of lesions and benign physical exam, reassurance was provided and follow up in 6 months was scheduled.

Conclusion: Pediatric pedal plantar papules are asymptomatic but often grow with the patient until age 2 or 3, when most begin to regress spontaneously. No further workup is required, and reassurance is the management of choice.

<https://doi.org/10.32873/unmc.dc.gmerj.5.1.079>

Post-Thoracotomy Pain Syndrome Treated with Intercostal Nerve Pulsed Radiofrequency Ablation

Eric Jonswoold¹, Graeme Boyter¹, Gabrielle Aldabbagh¹, Justin Choi¹

¹Department of Physical Medicine and Rehabilitation, College of Medicine, University of Nebraska Medical Center

Mentor: Justin Choi

Program: Physical Medicine and Rehabilitation

Type: Case Report

Background: Post-thoracotomy pain syndrome (PTPS) is defined as persistent or recurrent pain for at least 2 months following thoracotomy, most commonly attributed to direct trauma to intercostal nerves (ICNs). For some, pain can be severe and truly disabling. Pain management for PTPS is difficult and has historically included oral nonsteroidal anti-inflammatory drugs, oral neuromodulating agents, topical analgesics, physical therapy, transcutaneous electrical

nerve stimulation, ICN blocks, and trigger point and epidural steroid injections. Another consideration for treatment of PTPS has been radiofrequency ablation (RFA) of ICNs, however, research is limited.

Case: Our patient is a 59-year-old man with history of histoplasmosis pulmonary nodule who underwent open left thoracotomy with partial posterolateral resection of the left sixth rib. Three weeks post-thoracotomy, he developed severe neuropathic pain along the left T6 dermatome which remained constant for 11 months. His pain was refractory to medications and physical therapy. He presented to our clinic 12 months post-thoracotomy and elected for ICN blocks to

determine candidacy for RFA. We performed diagnostic ICN blocks of the left ribs 6 and 7 under fluoroscopy without complications. Given his positive response to the blocks, we proceeded with pulsed RFA to the left ribs 6 and 7 under fluoroscopy, which resulted in complete pain relief for 2 weeks with eventual return to baseline.

Conclusion: Pulsed RFA of ICNs can safely treat PTPS. This has substantial implications for physiatrists, pain specialists, and thoracic surgeons given the prevalence of respiratory complications following thoracic surgery and disability related to intercostal neuralgia.

<https://doi.org/10.32873/unmc.dc.gmerj.5.1.080>

Recurrent Polymicrobial Bloodstream Infections as Harbingers of a Duodenal-Inferior Vena Cava Fistula

Gregory Koval¹, Richard Hankins², Jasmine R. Marcelin²

¹Department of Surgery, College of Medicine, University of Nebraska Medical Center

²Department of Internal Medicine, College of Medicine, University of Nebraska Medical Center

Mentor: Jasmine R Marcelin

Program: General Surgery

Type: Case Report

Background: Duodenal-caval fistula (DCF) is rare and associated with high mortality. This discussion highlights DCF as an uncommon complication of inferior vena cava (IVC) stenting.

Case: We report a case of an 82-year-old female patient who previously underwent distal IVC to common iliac vein stenting for post thrombotic syndrome. She presented with recurrent polymicrobial bloodstream infections and no obvious source of infection. CT scans demonstrated a small amount of gas within the lumen of the IVC stent that was initially thought to be from IV access. DCF was suspected given recurrent bloodstream infections in the context of suspicious intraluminal air. The patient was taken to the OR where the duodenum was found to be adherent to the IVC with a communication between them (Figure 1). The duodenum was repaired primarily. IVC reconstruction was avoided due to the patient's clinical status. With no saphenous veins available, a fascia lata patch was used to repair the IVC. She did well post-op and was discharged on post-operative day 10.

Conclusion: Our case has certain unique elements. We thought that the reason for

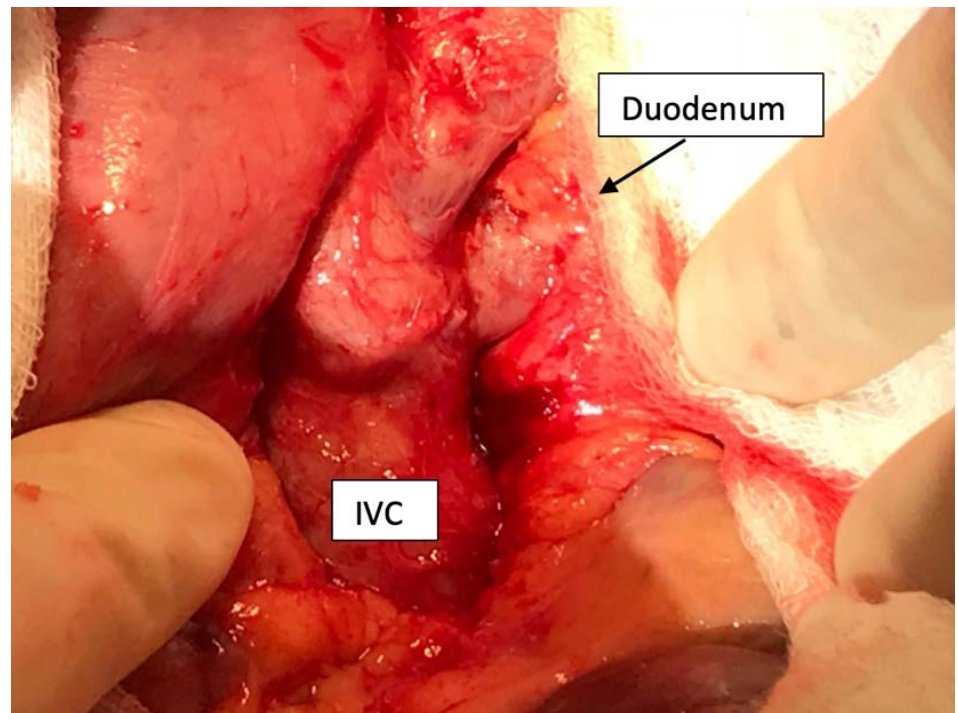


Figure 1. This photo illustrates the intra-operative findings of the duodenum adherent to the IVC.

infection was the enteric communication and not primary stent infection and with source control and antibiotics, bare metal stents would allow infection control. A fascia lata patch was utilized to repair the fistula with successful outcome. The relative ease of harvest and assumed resistance to infection

made this an ideal choice for this case. This is a unique case that highlights a previously unreported complication of IVC stenting and the challenges in diagnosis.

<https://doi.org/10.32873/unmc.dc.gmerj.5.1.081>

Up to the Chest in Bowels: A Case of Strangulated Right Diaphragmatic Hernia with Paraesophageal Hernia in a Non-trauma Patient

Elizabeth Maginot¹, Jason Lizalek¹, Mike Matos²

¹Department of Surgery, College of Medicine, University of Nebraska Medical Center

²Division of Acute Care Surgery, Department of Surgery, College of Medicine, University of Nebraska Medical Center

Mentor: Mike Matos

Program: General Surgery

Type: Case Report

Background: A Bochdalek hernia is a type of congenital diaphragmatic hernia and is in the posterolateral lumbocostal triangle. The incidence of adult Bochdalek hernias is estimated to be about 0.17%. They are most often diagnosed in infancy and classically occur on the left side.

Case: A 78-year-old female presented with abdominal pain, vomiting, and dyspnea. She was in atrial fibrillation with rapid ventricular response. Laboratory work-

up revealed a leukocytosis of 15,300/ μ L. Computerized tomography of the chest and abdomen showed a right-sided posterolateral diaphragmatic hernia containing multiple loops of bowel with evidence of ischemia as well as a type 4 paraesophageal hernia (Figure 1). The stomach was rotated on the organoaxial plane, and the duodenum was within the mediastinum. The patient was taken emergently for an exploratory laparotomy. A posterolateral hernia defect containing 50 cm of strangulated small bowel was identified. The ischemic small bowel was resected, a primary stapled enteroenterostomy was performed and the hernia defect was repaired primarily. The stomach was reduced, a primary crura repair was performed,

and gastropexy was performed with a gastrojejunostomy tube. The patient was transferred to the intensive care unit, and subsequently extubated, enteral feeds were initiated, and had anticipated discharge to a skilled nursing facility.

Conclusion: This case highlights an uncommon atraumatic presentation of an adult with diaphragmatic hernia. Its rarity is further denoted due to its right-sided laterality and strangulated small bowel as the usual herniated abdominal organs are the liver or colon.

<https://doi.org/10.32873/unmc.dc.gmerj.5.1.082>

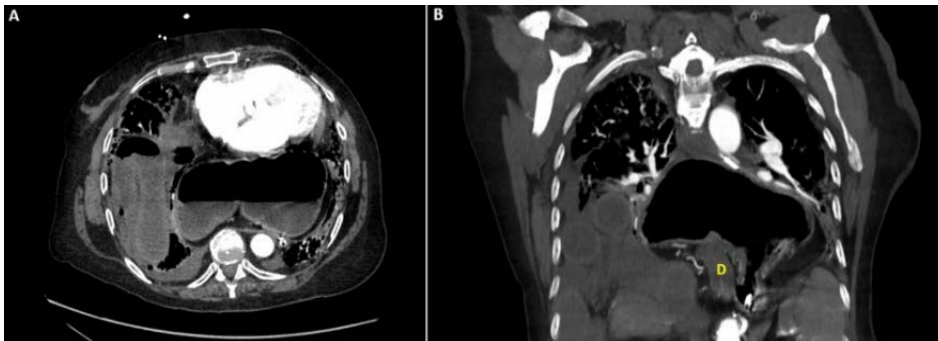


Figure 1. Computed Tomography of the Chest and Abdomen: A, Axial section demonstrating incarcerated small bowel within the right hemithorax as well as stomach within the posterior mediastinum. B, Coronal section demonstrating incarcerated small bowel within the right hemithorax above the liver as well as hiatal hernia containing stomach in an organoaxial rotation as well as the duodenum (D).

Extensive Tophaceous Pseudogout of the Temporomandibular Joint, Reconstructed with Custom Alloplastic Temporomandibular Joint and Mandibular Sagittal Split Osteotomy

Chad S. Sloan¹, **Blake H. Neece**¹, Jason Untrauer¹, David Wagner²

¹Department of Surgery, College of Medicine, University of Nebraska Medical Center

²Department of Pathology and Microbiology, College of Medicine, University of Nebraska Medical Center

Mentor: Jason Untrauer

Program: Oral and Maxillofacial Surgery

Type: Case Report

Background: Tophaceous Pseudogout is a form of calcium pyrophosphate dihydrate deposition (CPPD) disease that affects peri-articular surfaces. Lesions have been reported in the knee, wrist, shoulder, and rarely, in the temporomandibular joint (TMJ). CPPD induces a histiocyte giant cell reaction and causes localized destruction along with neoplastic-like expansion of the joint space, secondary to deposition and inflammation. We report a case affecting the right TMJ with expansive calcifications and osteolysis, successfully resected and reconstructed.

Case: A 49-year-old healthy male was referred with complaint of right-sided preauricular fullness, audible joint crepitus, and deviation of his mandible for the past several months. Significant erosive changes and calcifications were noted on computed tomography (CT) imaging (Figure 1A). The referring team had performed CT-guided biopsy with results inconclusive, but suggestive of synovial chondromatosis versus chondrosarcoma. Utilizing 3D-medical modeling, a custom-fitted TMJ Concepts (Ventura, CA) joint was constructed along with plan for a left mandibular sagittal split osteotomy. Intraoperative resection of calcifications was extensive (Figure 1B). Successful reconstruction was completed with re-establishment of TMJ function and mandibular skeleton (Figure 1C). Tissue

pathology revealed multinucleated giant cells, crystal deposition, and inflammatory tissue consistent with tophaceous pseudogout (Figure 1D). Consent was obtained to use this case for educational purposes.

Conclusion: This case demonstrates the difficulty of diagnosis and treatment of temporomandibular joint pathology. Tophaceous CPPD disease is one of several rare entities that should be considered when evaluating TMJ pathology. Successful management with custom TMJ reconstruction has proven effective and can dramatically improve patient quality of life.

<https://doi.org/10.32873/unmc.dc.gmerj.5.1.083>

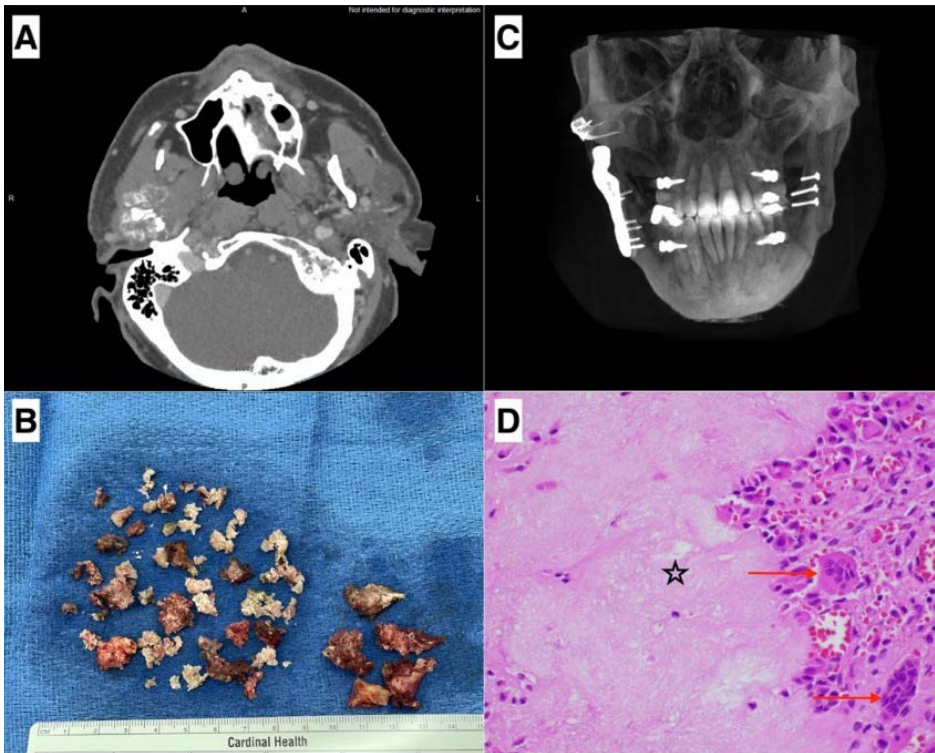


Figure 1. (A) Axial CT showing extensive calcifications and osteolytic changes, (B) intraoperative resection of fibrocartilaginous and dense crystal deposition tissue, (C) Post-operative CT with right total joint reconstructed, temporary intermaxillary fixation screws, and left sagittal split osteotomy screws, (D) Hematoxylin-eosin staining showing multi-nucleated giant cells [red arrows], and focal areas of crystal deposition [black star].

Is It Really Appendicitis? Spigelian Hernia with Incarcerated Ovary Presenting as Acute-onset Right Lower Quadrant Pain

Elizabeth Maginot¹, Joel Ketner², Jason Lizalek¹, Bennett Berning¹

¹Department of Surgery, College of Medicine, University of Nebraska Medical Center

²College of Medicine, University of Nebraska Medical Center

Mentor: Bennett Berning

Program: General Surgery

Type: Case Report

Background: Spigelian hernias are uncommon ventral hernia that protrudes through the internal oblique and transversus abdominis aponeuroses near the semilunar line. Surgical repair is required upon diagnosis due to its insidious presentation of incarcerated or strangulated abdominopelvic viscera. Pelvic reproductive organs in female patients add further complexity to differential diagnoses for right lower quadrant pain. We report a rare case of incarcerated ovary within a Spigelian hernia masquerading as appendicitis on clinical exam.

Case: A 76-year-old female presented with progressively worsening abdominal pain for 3 days. Physical examination revealed right lower quadrant tenderness to palpation and rebound tenderness, raising concern for acute appendicitis. Cross-sectional imaging did not easily visualize the appendix, but there were no signs of inflammation. A right lower quadrant ventral hernia was identified superior to the inguinal ligament containing

fluid and the right ovary and fallopian tube (Figure 1). We proceeded to urgently take the patient to the operating room for laparoscopic ventral hernia repair. Intraoperative findings revealed a hernia defect measuring 2 x 4 cm at the semilunar line. The peritoneum was within the hernia sac, and a congested right ovary was just proximal to the defect within the abdominal cavity. A preperitoneal mesh repair was performed. The patient tolerated the operation well and was discharged postoperative day 1.

Conclusion: This case highlights the additional complexity of the female patient presenting with acute lower quadrant abdominal pain and demonstrates an exceedingly rare presentation of incarcerated ovary within a Spigelian hernia.

<https://doi.org/10.32873/unmc.dc.gmerj.5.1.084>

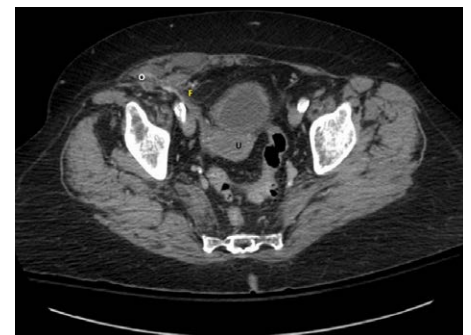


Figure 1. Axial section of the pelvis demonstrating the uterus(U) positioned toward the right pelvis with fallopian tube(F) leading into the Spigelian hernia containing the right ovary(O).