

PRELIMINARY ASSESMENT OF EFFICIENCY OF TELEMICROSCOPY SYSTEM FOR DISTANCE DIAGNOSIS OF LEISHMANIASIS IN PARAGUAY

Oddone, R.¹; Samudio, M.¹; Boggino, H.²; Cane, V.¹; Cáceres, C.²

Rolando Oddone, roloddone@googlemail.com, Margarita Samudio, margarita.samudio@gmail.com, Hugo Boggino, heboggino@yahoo.com, Virgilio Cane, vcaneleon@hotmail.com

¹Instituto de Investigaciones en Ciencias de la Salud, National University of Asunción (IICS-UNA) Paraguay

²Laboratory of Pathology PATLAB, Asunción, Paraguay

PROGRAMA PROCIENCIA – CONVOCATORIA 2013 - PROYECTO 14-INV-170

INTRODUCTION

Mucocutaneous leishmaniasis (MCL) is endemic in rural areas of Paraguay, and mainly due to *Leishmania (Viannia) braziliensis*. In order to achieve diagnosis, clinical and epidemiological data are required in combination with different laboratory methods, which are not available in rural areas. Parasitologic confirmation of MCL is obligatory before chemotherapy can be considered. Histopathological analysis (HPA) has advantages as can give either confirmation, or diagnosis of probability or differential diagnosis. Several studies in which different conventional parasitologic methods were evaluated showed heterogenous and sometimes conflicting results (1-4).

In a country where few experts and little resources are available, the means for many people to access to specialized diagnosis and verifying interpretations remain prohibitive. Telemicroscopy networks enable to overcome these limitations through remote interpretation of images and data, expert teleconsultation and proficiency testing (5-15). Taking advantage of the increase in the coverage of mobile networks, telephones equipped with digital cameras, 3D printing and web-type applications, the goal of the study was to develop a telemicroscopy system for clinical diagnosis and registration of diseases of public health significance in Paraguay such as MCL. The system also allows storage, management and analysis of the medical records (images, diagnosis, treatment, and geolocation) to monitor endemic diseases and provide quality control of remote interpretations of the images.

MATERIAL AND METHODS

Phone-microscope adapter: An adapter was designed in AutoCAD 3D in its 2014 version for various types of telephones and microscopes and printed in a 3D printer with plastic PLA.

WEB Application: A software application was developed to create a computer record as a clinical electronic record for the patient personal data and HPA images. The features of the application are as follows: a) it uses HTML5 and JavaScript as an access interface for the client; b) PHP as a server-side programming language; c) The Apache HTTP server as a server of WEB pages, and d) the data is stored in a database management system called MariaDB. To manage the support of the Centos 7 operating system, a DELL R720 server was used. The web access to the system is the URL www.iics.una.py/lh.

The WEB application transmits information using "Secure Sockets Layer" (SSL) connections, and the data is encrypted in the database for greater security.

Mobile phones equipped with iOS 6 or higher and Android 4.0 "Ice Cream Sandwich" or higher can use an input type = "file" with a capture attribute that has the value "camera". This launches the camera application and the photo taken by the user is sent when the HTML form containing the input type = "file" is sent. Images were up load to the WEB application file when filling out the data, avoiding storage of images in the mobile phone.

In addition, the application incorporates a mechanism to prevent simultaneous edition of the registry by different users. All the user actions (Entries / Exits / created registries / modified registries / deleted registries) are stored in a registry of the system.

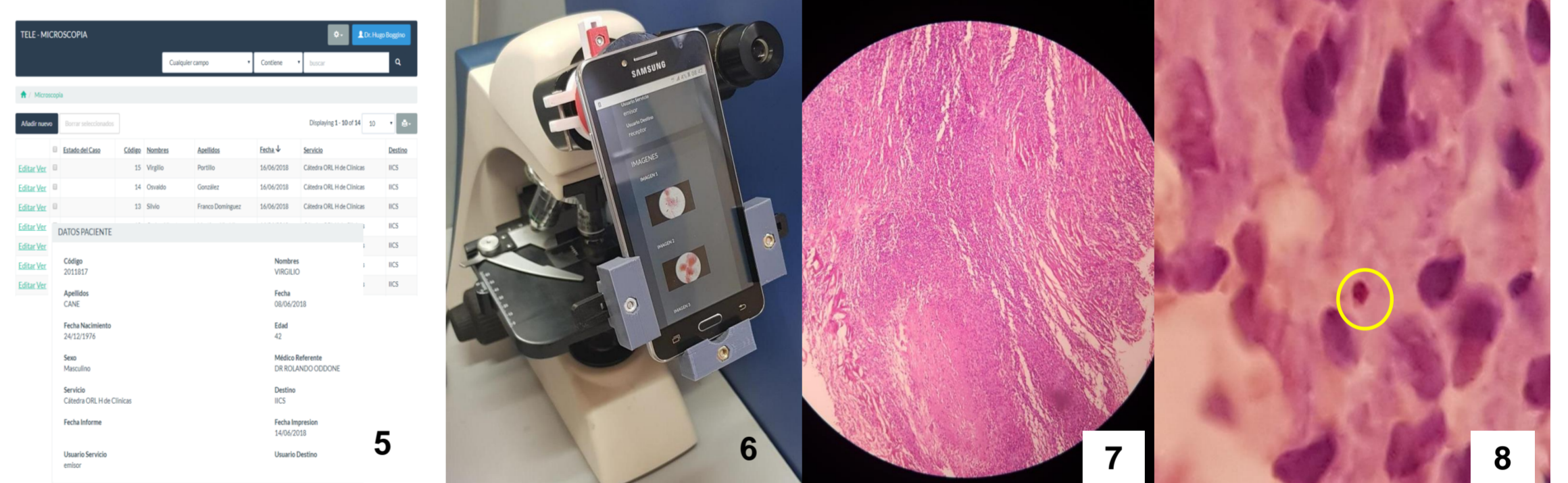
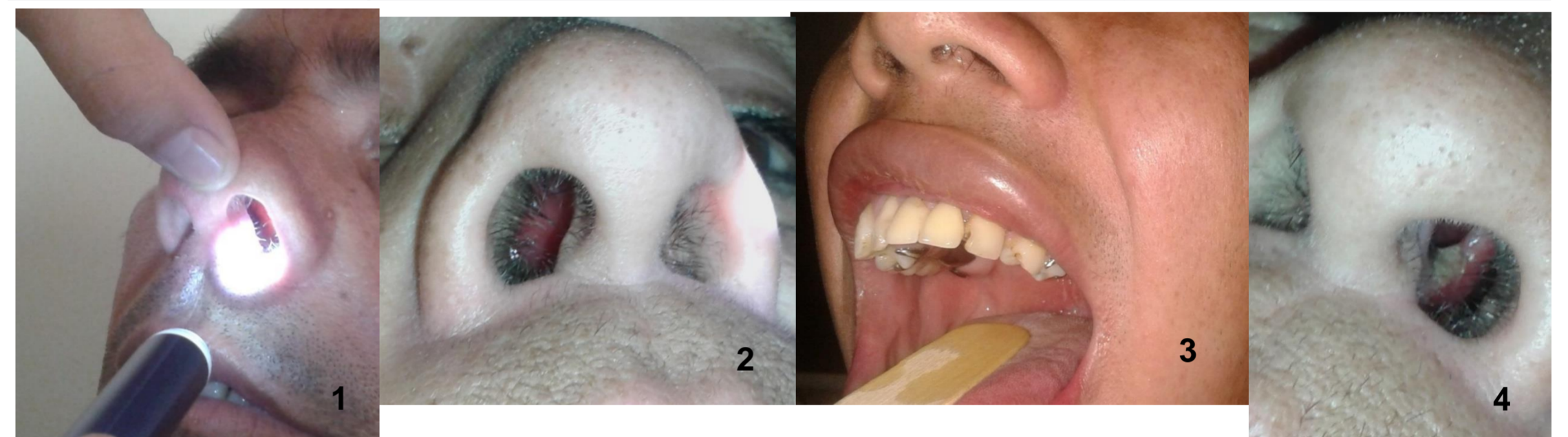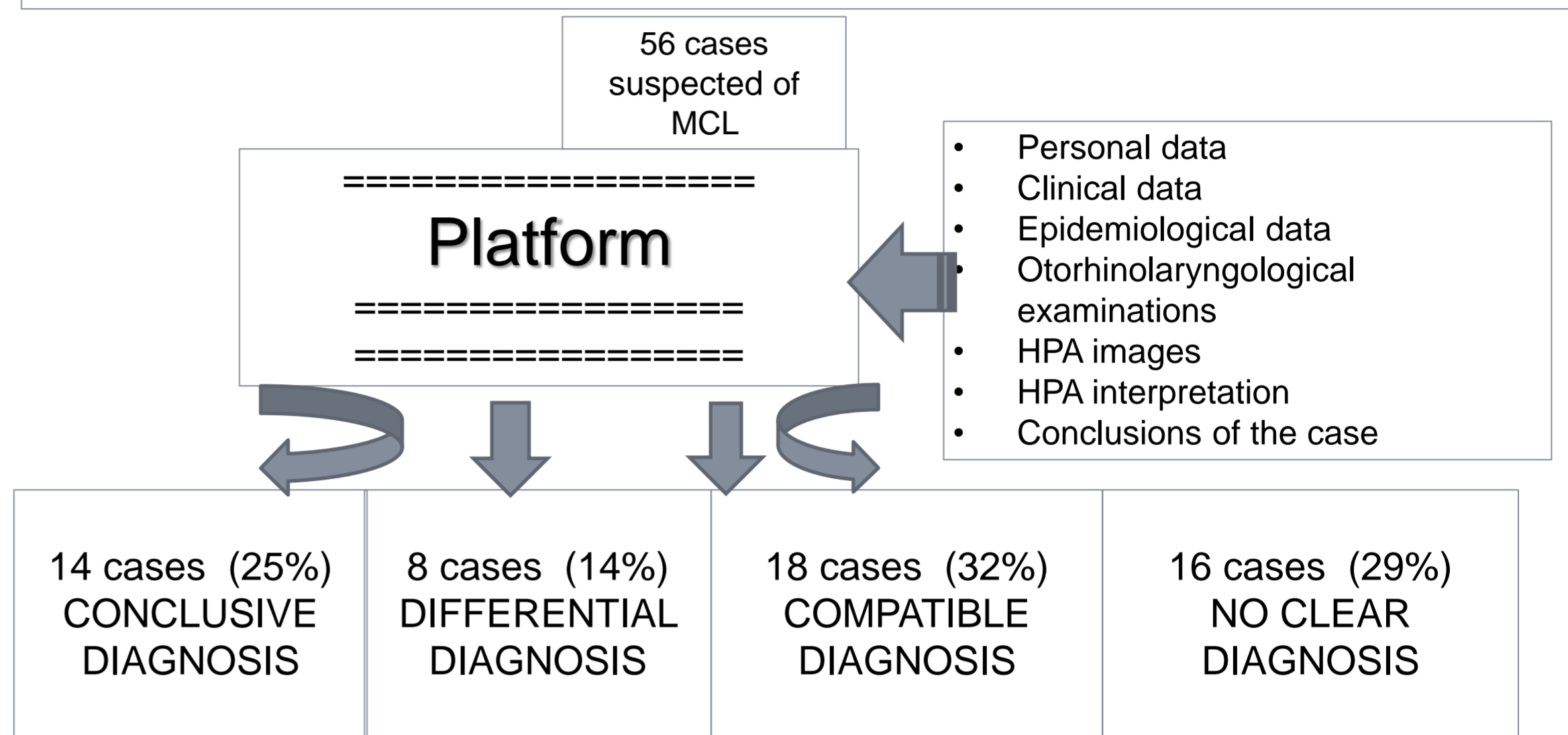
Personal, clinical and epidemiological data were collected and introduced to the telemicroscopy platform. Also, otorhinolaryngological and HPA images as well as HPA interpretation.

RESULTS

In this preliminary study, 56 cases suspected of mucosal leishmaniasis referred to IICS-UNA were included. Clinical, epidemiological and laboratory data were introduced into the platform. HPA led to conclusive MCL diagnosis in 14 cases (25%) and made differential diagnosis in 8 cases (14%). In 18 individuals (32%) in which compatible diagnosis was given by HPA, the sharing of clinical and epidemiological data and images, let to arrive to conclusive diagnosis. The remaining 16 cases (29%) had no clear diagnosis.

In general, sharing information through the platform was optimal and let to arrive to diagnosis in a quick way (7 days on average). The main difficulty was to collect the data to the platform by all those involved in a concerted manner.

FLOW CHART OF THE CASES



Figures: 1-4: Different clinical presentations of MCL. **5:** Virtual platform. **6:** Adapter coupled to phone and microscope. **7:** Mucosal sample at the microscope (20X). **8:** Amastigote of *Leishmania* in inflammatory infiltrate (100X)

CONCLUSIONS

Remote access of images and patient data based in telemicroscopy, let to quick and efficient diagnosis of MCL, and it is becoming a useful system to be implemented for public health in Paraguay. Even more useful in diseases which diagnosis requires inputs of different expertise (clinical, epidemiological and laboratory).

REFERENCES

- Chena L, Nara E, Canese A, Oddone R and Russomando G. 2013. Aplicación de la PCR para la detección de géneros y complejos de Leishmania en diferentes tipos de muestras biológicas. Memorias del IICS 11 (1), 45-51.
- Cuba-Cuba C A, Llanos-Cuentas A, Barreto A, Magalhaes A, Lago E, et al. 1984. Human mucocutaneous leishmaniasis in Tres Bracos, Bahia, Brazil. An area of *Leishmania braziliensis braziliensis* transmission. I. Laboratory diagnosis. Rev Soc Brasil Med Trop. 17:161-167.
- Cuba-Cuba C A, Masden P, Barreto A C, Rocha R, Sanpaio R R, et al. 1981. Parasitologic and immunologic diagnosis of American (mucocutaneous) leishmaniasis. Bull Pan Am Health Organ. 15:249-259.
- Navin T, Arana F, deMérida A, Arana B, Castillo L, Silvers D. 1990. Cutaneous leishmaniasis in Guatemala: comparison of diagnostic methods. Am J Trop Med Hyg. 42:36-42.
- Breslauer DN, et al. 2009. Mobile Phone Based Clinical Microscopy for Global Health Applications. EnPLoS ONE, Vol. 4, N° 7, pp. e6320.
- Park S., Pantanowitz L. y AV.Parwani, 2012. Digital imaging in pathology. EnClin Lab Med, Vol. 32, N° 4, pp. 557-84.
- Park S. et al. 2012. Handheld computing in pathology. EnJPathol Inform, Vol. 3, pp. 15.
- Bellina L, and E. Missoni, 2009. Mobile cell-phones (M-phones) in telemicroscopy: Increasing connectivity of isolated laboratories. EnDiagnPathol. Vol. 4, Jun 2009, pp. 19.
- Breslauer DN. et al. 2009. Mobile phone based clinical microscopy for global health applications. EnPLoS One. Vol. 4, N° 7, pp. e6320.
- McLean R, 2009. Application of camera phones in telehaematology. EnJTelemed Telecare. Vol. 15, N° 7, pp.339-43.
- Zhu H. et al. 2011. Cost-effective and compact wide-field fluorescent imaging on a cell-phone. EnLab Chip. Vol. 11, pp.315-22.
- Tseng D. et al. 2010. Lensfree microscopy on a cellphone. En Lab Chip. Vol. 10, N° 14, pp.1787-92.
- Wimmer J. et al. 2012. A novel smartphone-microscope camera adapter: An option for cytology consultation in low-resource environments. En J Am Soc Cytopathol. Vol. 1, N° 1, pp.S124-5.
- Lehman JS, and LE Gibson, 2013. Smart teledermatopathology: A feasibility study of novel, high-value, portable, widely accessible and intuitive telepathology methods using handheld electronic devices. En JCutanPathol. Vol. 40, N° 5, pp.513-8.
- Rhoads DD. et al. 2016. Review of Telemicrobiology. En Archives of Pathology & Laboratory Medicine [Online], Vol. 140, N° 4, pp. 362-370. Available in: <http://doi.org/10.5858/arpa.2015-0116-RA> [Accessed on April 26, 2018]