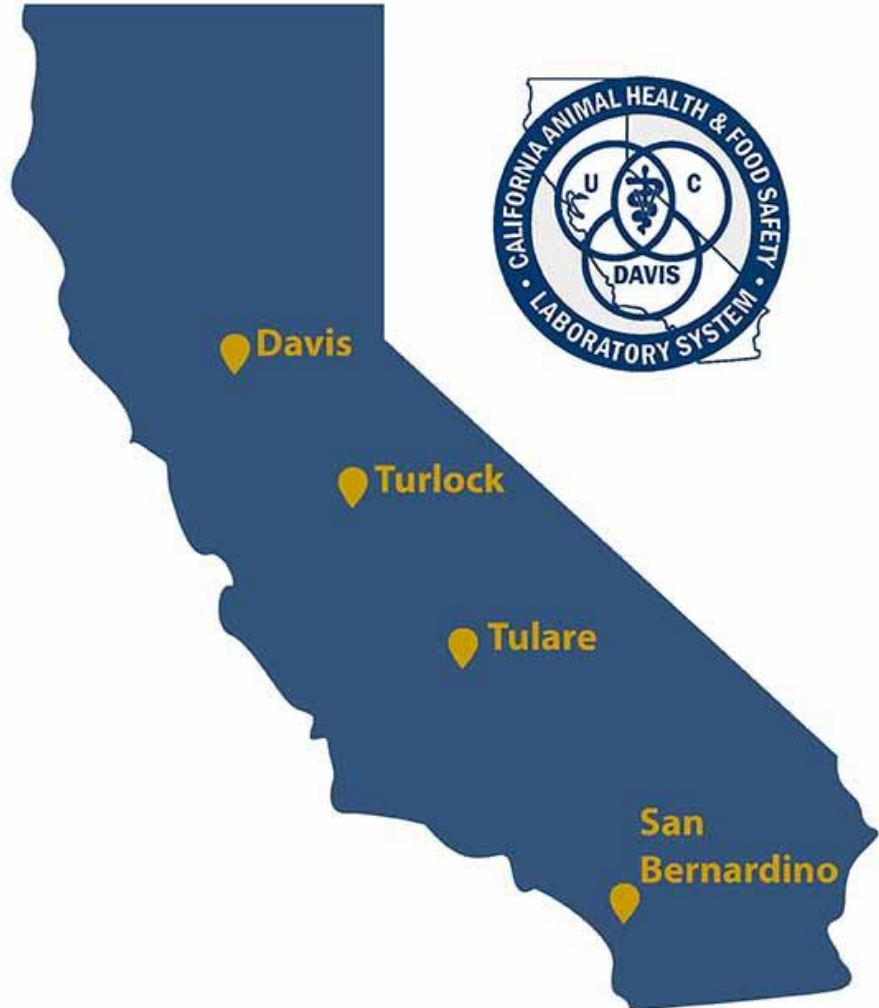

Utilización de la inmunohistoquímica como herramienta de diagnóstico en veterinaria

Alvaro Wehrle Martinez

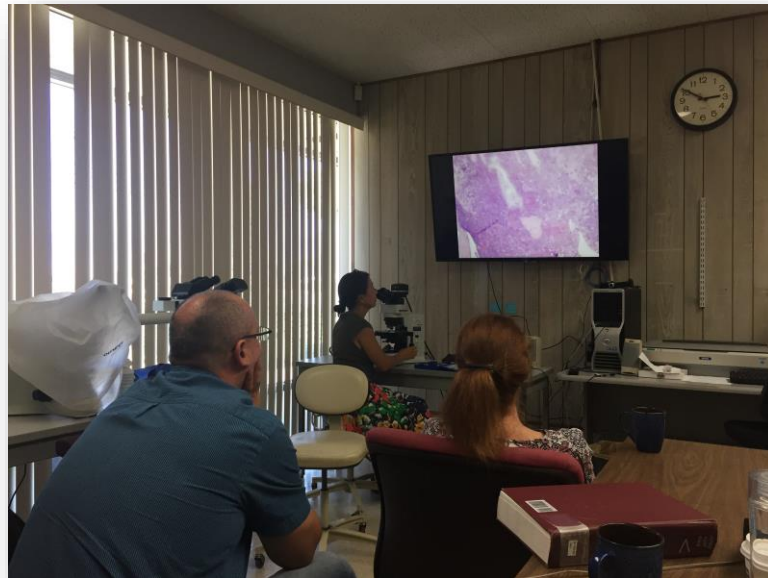Programa de vinculación de Científicos y Tecnólogos - 2017



UC DAVIS
VETERINARY MEDICINE




El laboratorio



Gross Morbid Pathology of Laboratory Rodents *The CPL edition*

Denise M. Imai-Leonard DVM, PhD, DACVP
Senior Pathologist, Comparative Pathology Laboratory
Assistant Health Sciences Clinical Professor, School of Veterinary Medicine
University of California, Davis
Tel: 530-754-4937
Email: dmimai@ucdavis.edu



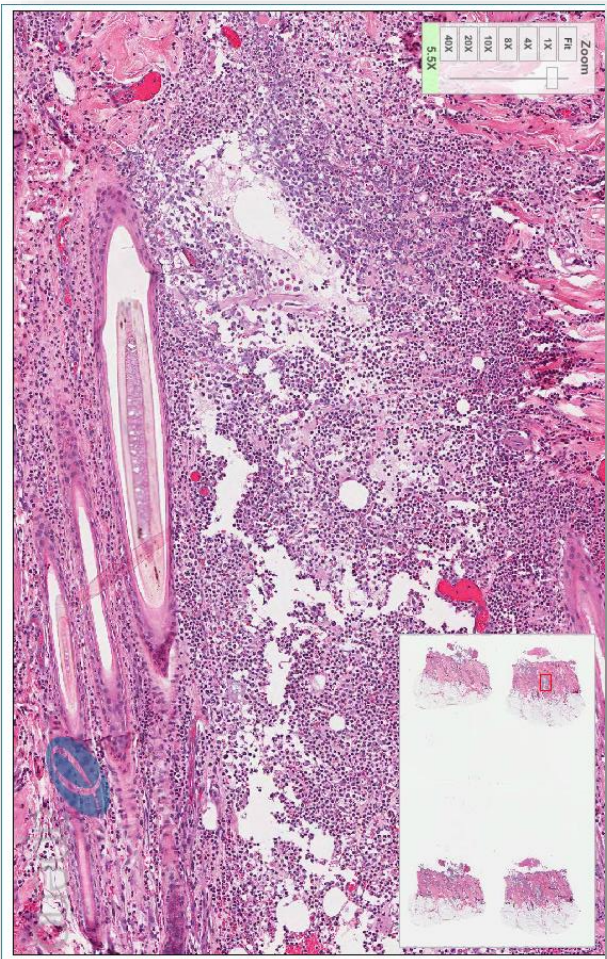
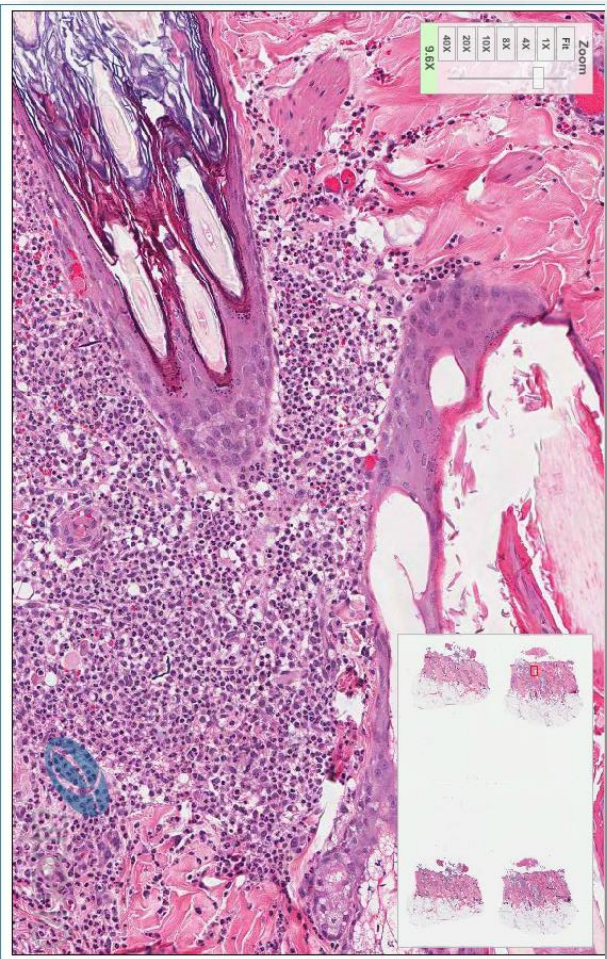
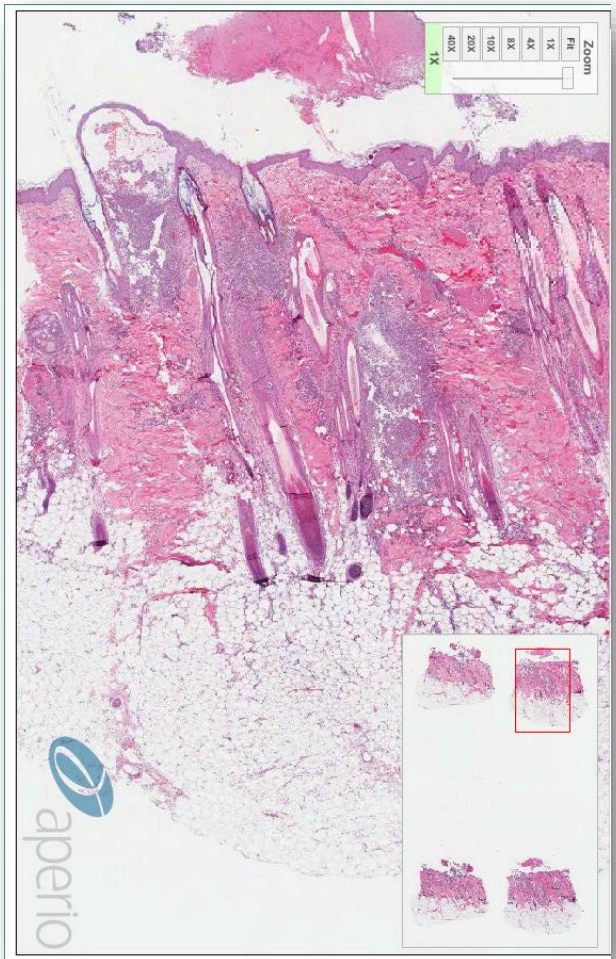
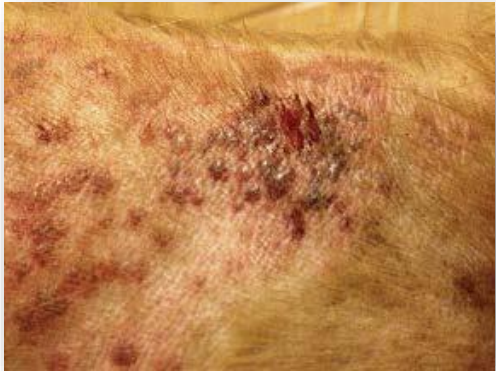Pasantía

Histopatología

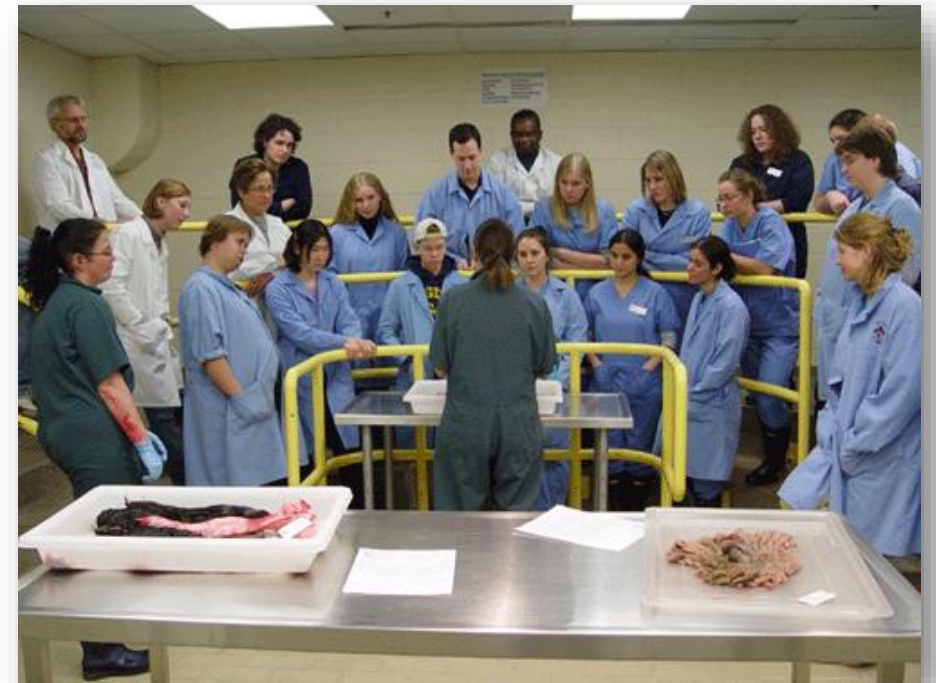

| Conference 1 | 9 September 2015 | | | | | |
|--------------|-------------------|----------------------|---------------------------|--|------------------------|------|
| Case | JPC No. | Slide ID No. | Species | Lesion / condition | Tissue | Page |
| 1 | 3167631 | 09-A-471 | NHP, Rhesus macaque | Mucinous adenocarcinoma | Colon | 1 |
| 2 | 4066309 | 15-0022 | NHP, African green monkey | Mesenteritis, abdominal abscess (<i>Klebsiella pneumoniae</i>) | Mesentery/ abdomen | 6 |
| 3 | 4065942 | 14-144 | Sheep | Venous thrombophlebitis (<i>Pseudomonas aeruginosa</i>) | Jugular vein | 10 |
| 4 | 4049056 | D12-33071 | Dog | Hydatid cysts (<i>E. multilocularis</i> larvae) | Liver | 15 |
| Conference 2 | 16 September 2015 | | | | | |
| 1 | 4050459 | B15-894 | Dog | Sertoli tumor and squamous metaplasia | Testicle/Prostate | 23 |
| 2 | 3164421 | S09-1502 | Cat | Herpesvirus pneumonia | Lung | 26 |
| 3 | 3169265 | 08-2379-7 | Cat | Tularemia | Spleen | 31 |
| 4 | 4066360 | B14-182 | Dog | Fungal mastitis; (<i>Zygomycetes</i> or <i>Pythium</i>) | Mammary | 34 |
| Conference 3 | 23 September 2015 | | | | | |
| 1 | 4066661 | 8482-15 | Ox/Calf | Brucellosis abortion | Placenta | 38 |
| 2 | 3165093 | NCAH 2010-2 | Deer | <i>Pasteurella multocida</i> pneumonia | Lung | 42 |
| 3 | 4032719 | 13-11676 | Elk | Myonecrosis | Skeletal muscle | 45 |
| 4 | 4066795 | 21-Jan-09 | Horse | Pulmonary silicosis | Lung | 49 |
| Conference 4 | 30 September 2015 | | | | | |
| 1 | 4066007 | 15H672 | Cat | Adenocarcinoma | Trachea | 54 |
| 2 | 4066222 | 13-338 | Dog | <i>Neospora caninum</i> encephalitis | Cerebellum / Brainstem | 56 |
| 3 | 4065318 | 14-May-98 | Cat | <i>Tritrichomonas foetus</i> colitis | Large intestine | 61 |
| 4 | 4066091 | D15-6096 | Dog | Canine adenovirus 2 | Pancreas / Lung | 63 |
| Conference 5 | 7 October 2015 | | | | | |
| 1 | 4065817 | 060377-1 | Horse | Squamous cell carcinoma | Prepuce | 71 |
| 2 | 4066859 | 14-42715 | Cat | Pulmonary fibrosis | Lung | 75 |
| 3 | 4032912 | 12-269-84 | Rat | <i>Capillaria hepatica</i> | Liver | 79 |
| 4 | 4066359 | N14-367 | Pig | Porcine reproductive and respiratory syndrome | Lung | 84 |
| Conference 6 | 28 October 2015 | | | | | |
| 1 | 4018127 | NCAH-2012B | Raccoon | Cystic endometrial hyperplasia | Uterus | 89 |
| 2 | 4048928 | E274/14 | Parrot | <i>Chlamydia psittaci</i> hepatitis | Liver | 93 |
| 3 | 4066233 | A | Duck | <i>Leukocytozoon</i> spp. encephalitis | Brain | 96 |
| 4 | 4066459 | N2015-0172 (Digital) | Toad | Nephroblastoma and <i>Mycobacterium</i> spp. | Kidney | 101 |

Fotografías microscópicas de cada caso



- GROSS ROUNDS
- HISTO ROUNDS
- BIOPSY CONFERENCE



www.vetmed.ucdavis.edu/vss/conferences/170623/index.cfm

Vet Med Home Hospital News Giving Contact Us Campus Directory Maps VIPER UCDAVIS

UCDAVIS VETERINARY MEDICINE

Digital Microscopy and Whole Slide Imaging

Virtual Microscopy Laboratory Services Resources Rates Biopsy Conferences About

Home > Biopsy Conferences > June 23, 2017

June 23, 2017

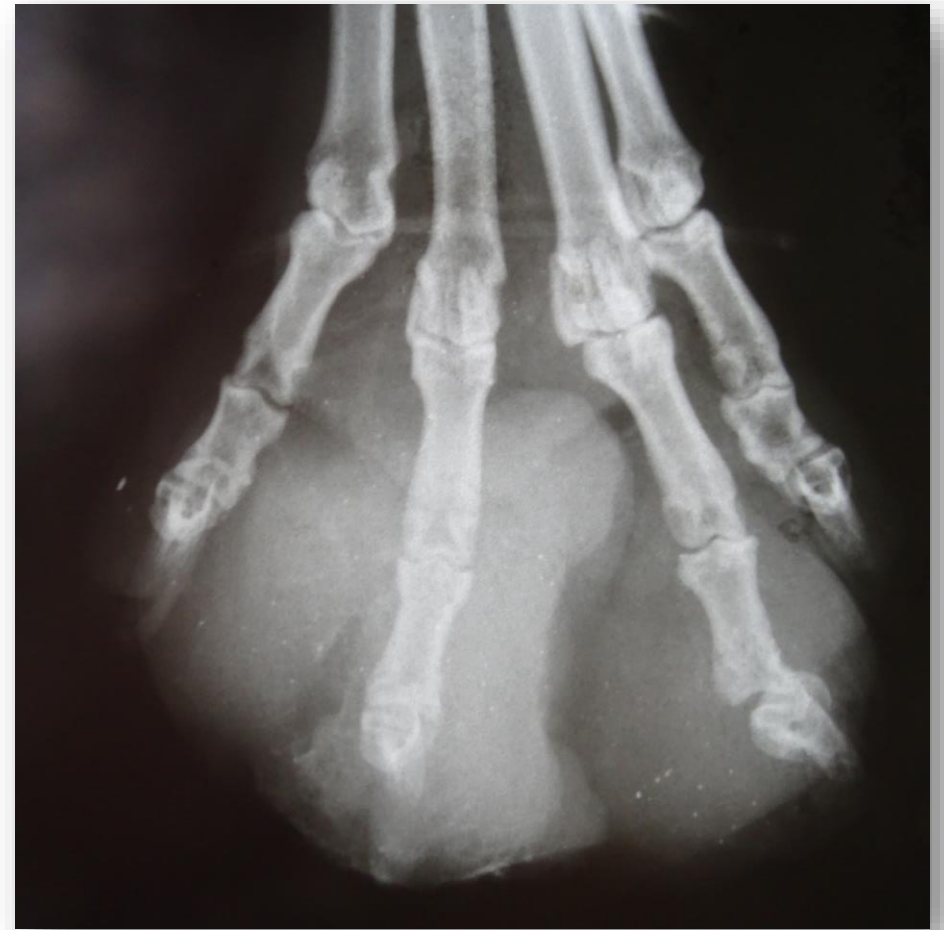- Case 1 - 170623
- Case 1 - 170623
- Case 1 - 170623
- Case 1 - 170623
- May 19, 2017

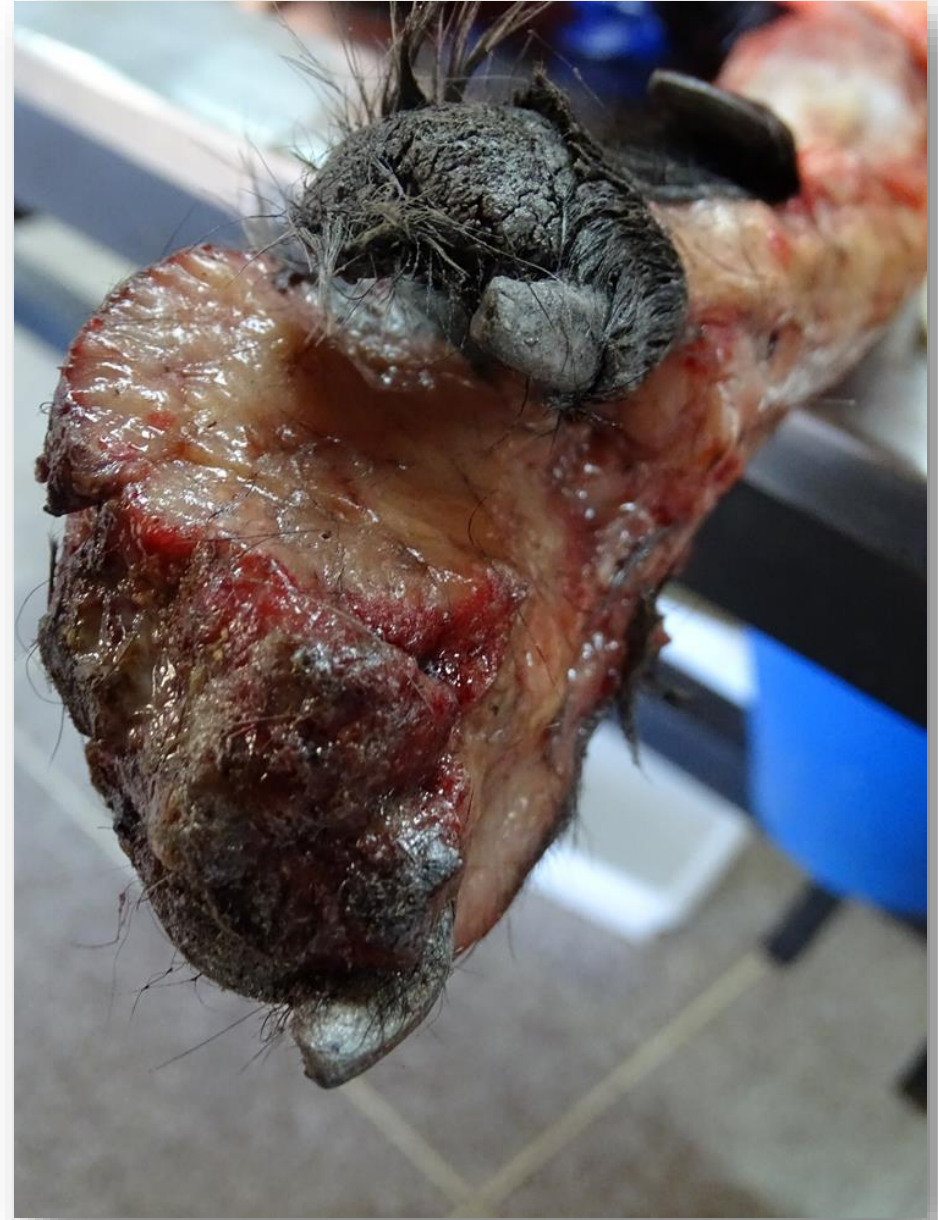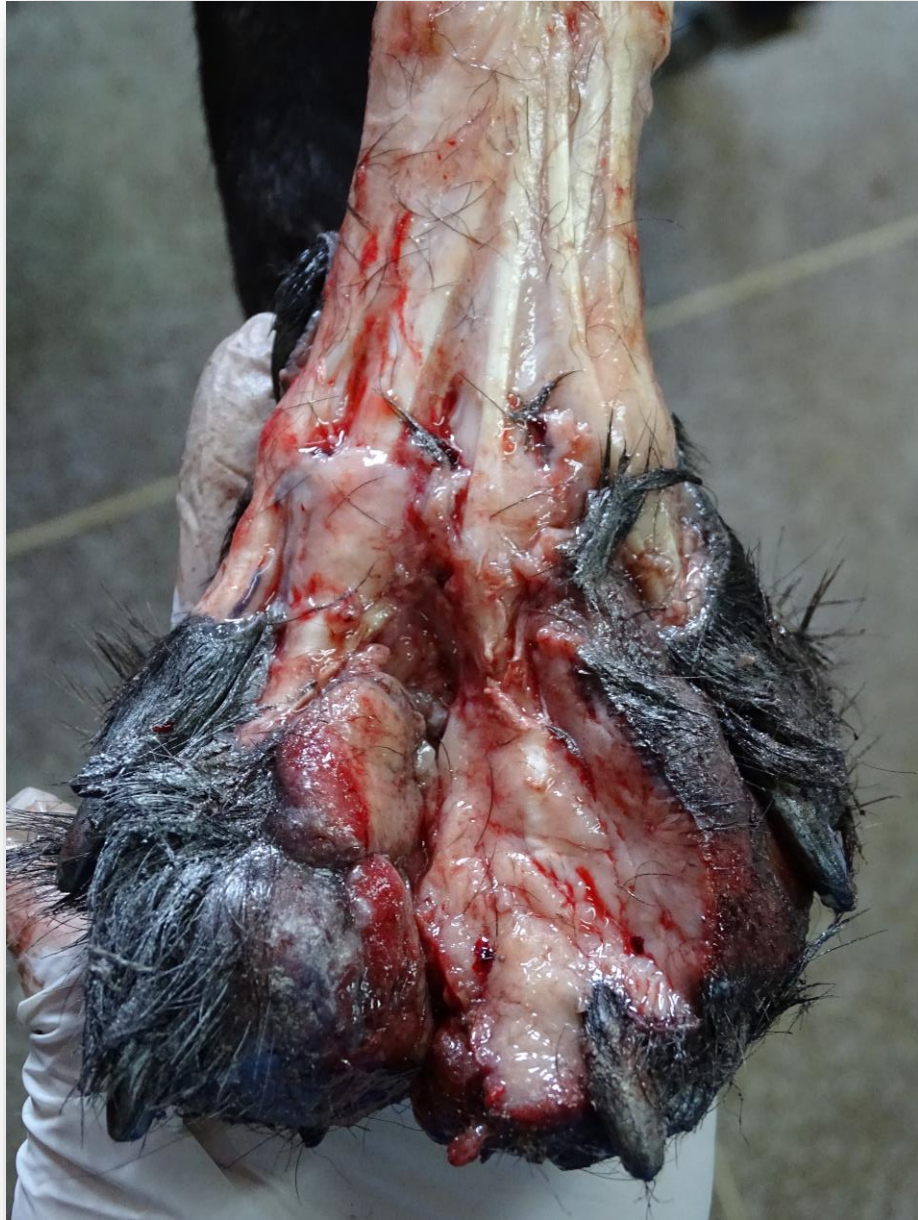UC Davis Biopsy Conference - June 23, 2017
Conference materials were organized and presented by Dr. Sarah Stevens.

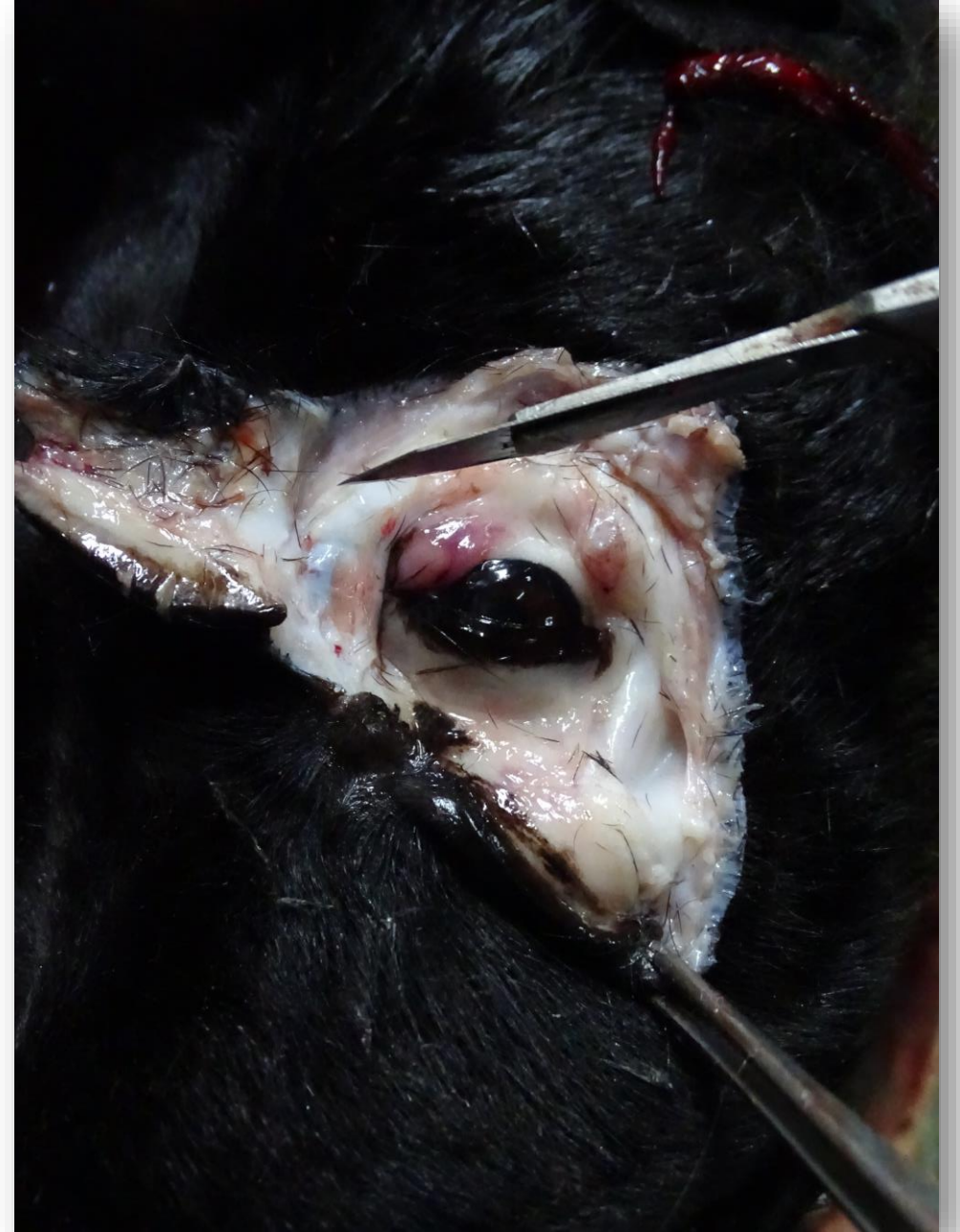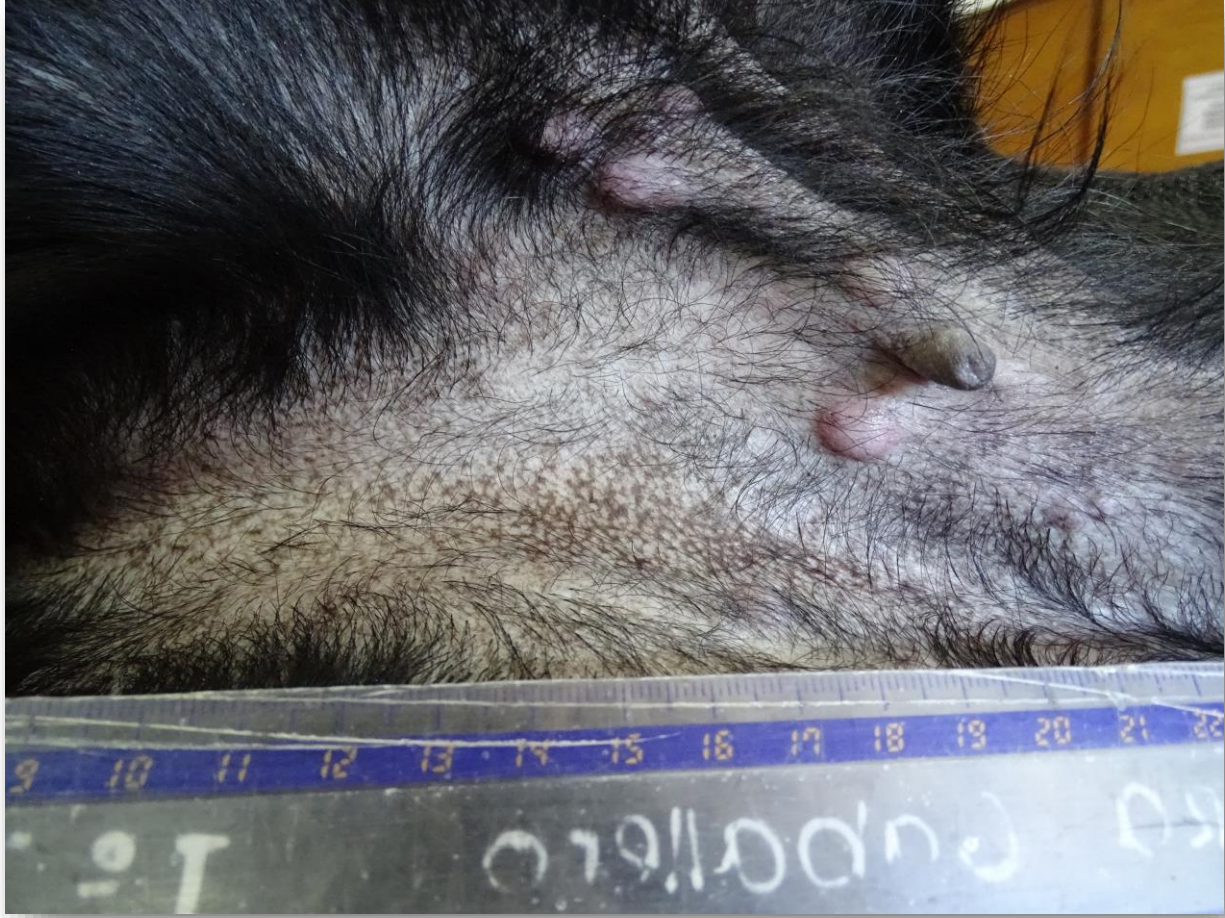| Case 170623-1 Cat | Case 170623-2 Dog | Case 170623-3 Hog | Case 170623-4 Horse |
|----------------------|----------------------|----------------------|------------------------|
| | | | |

6:35 PM 10/24/2017

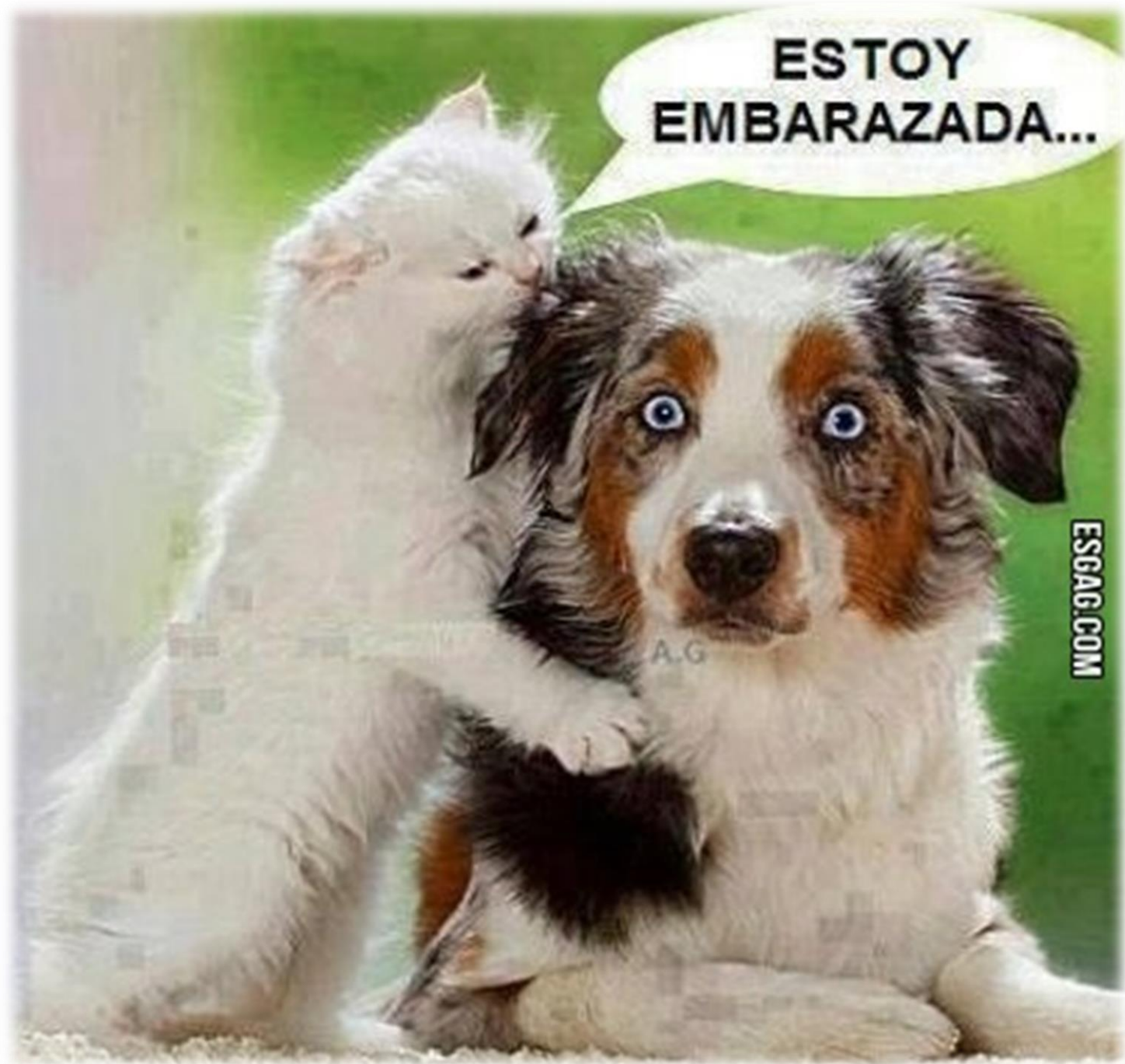Estudio de caso:



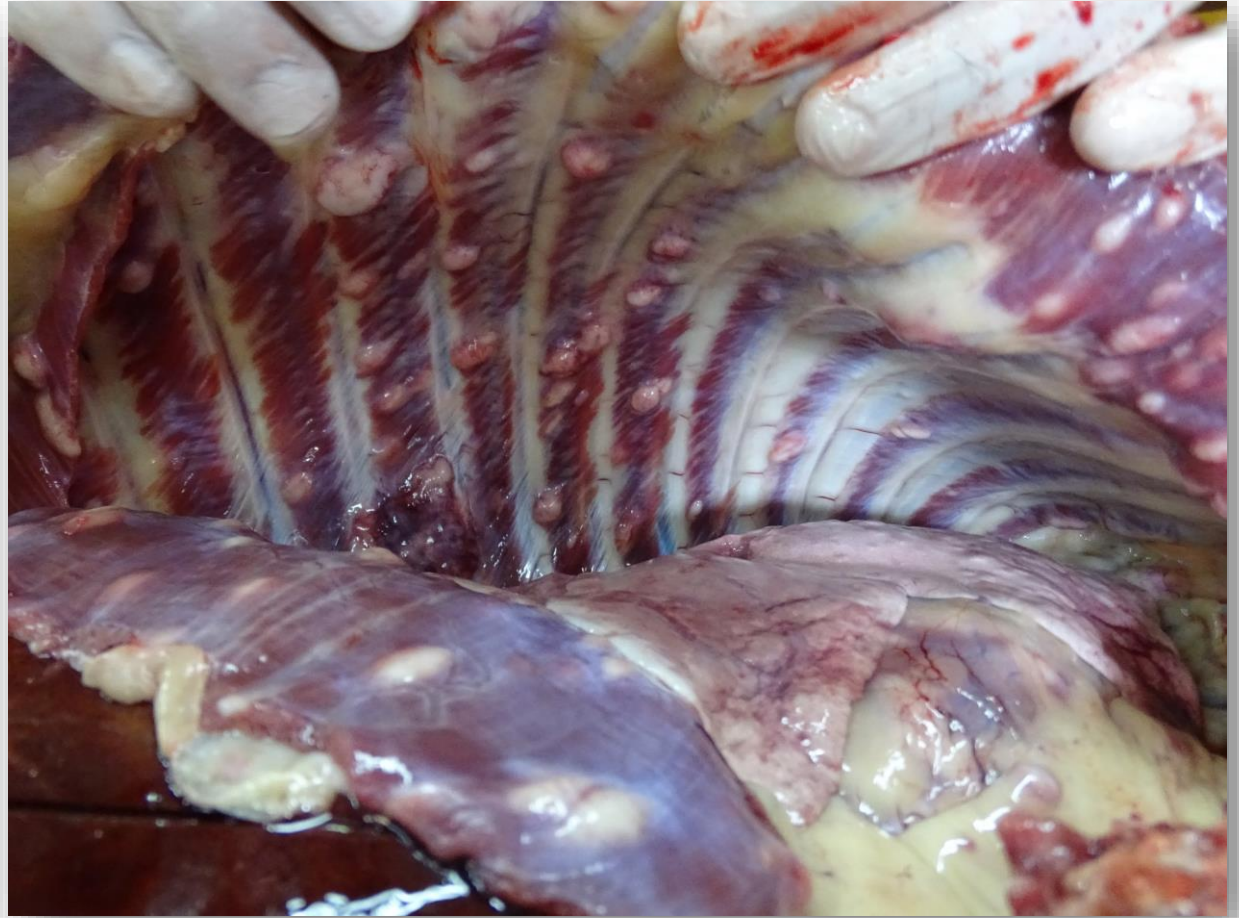
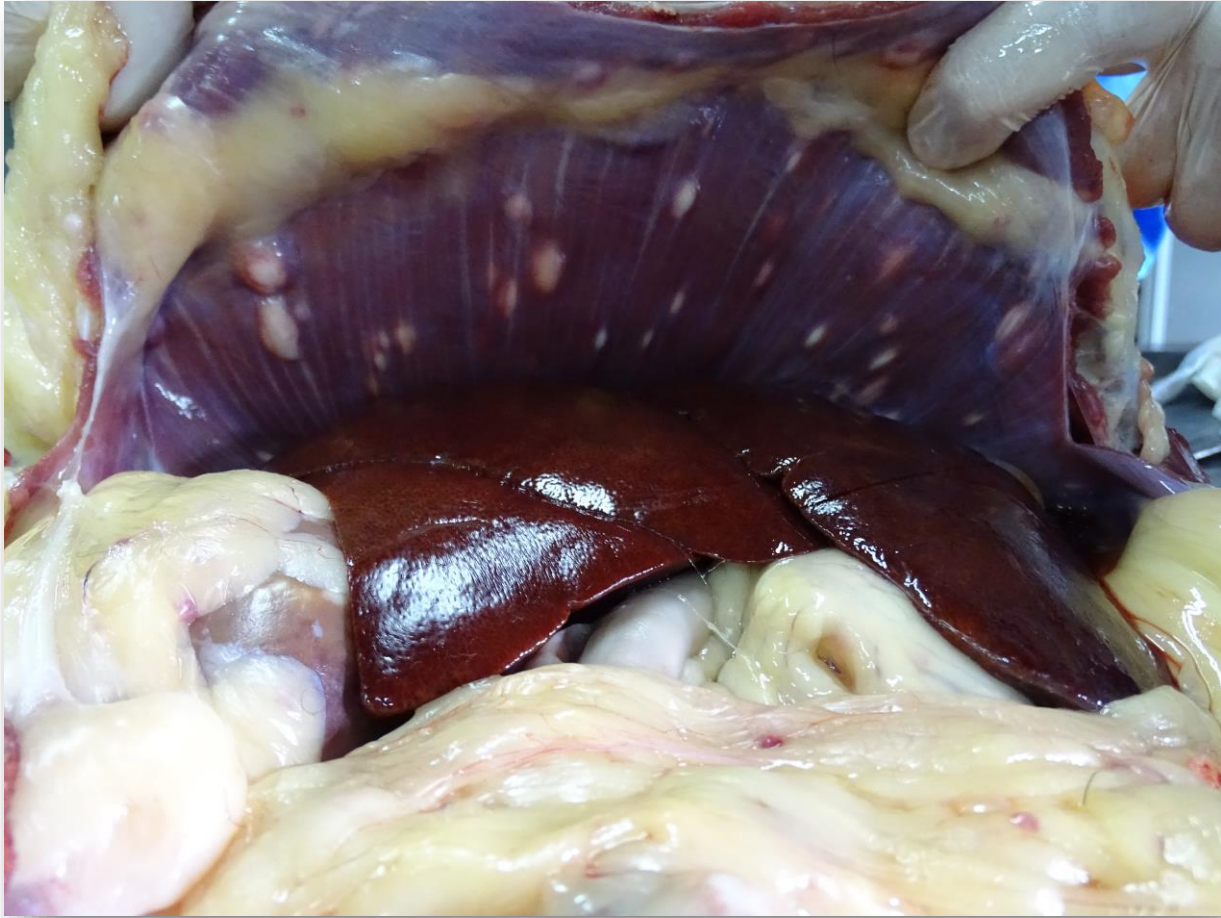


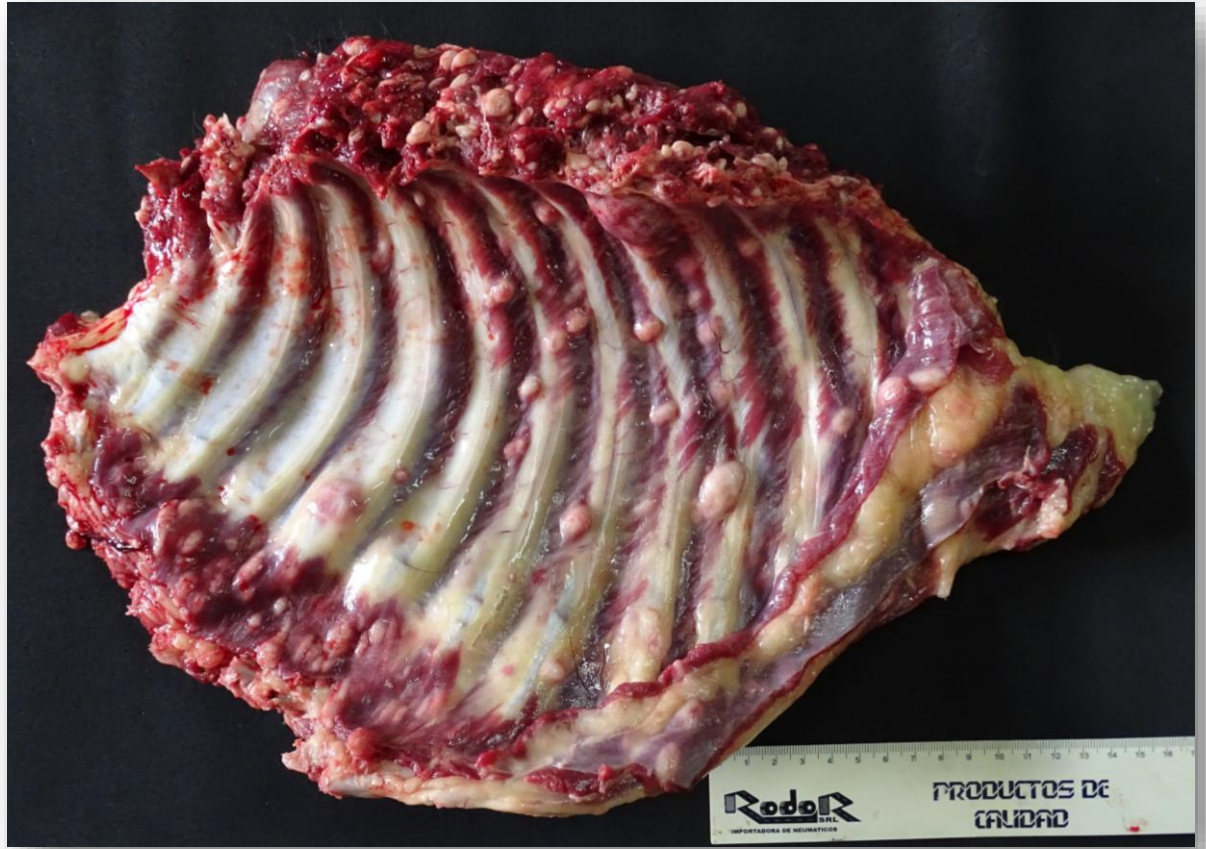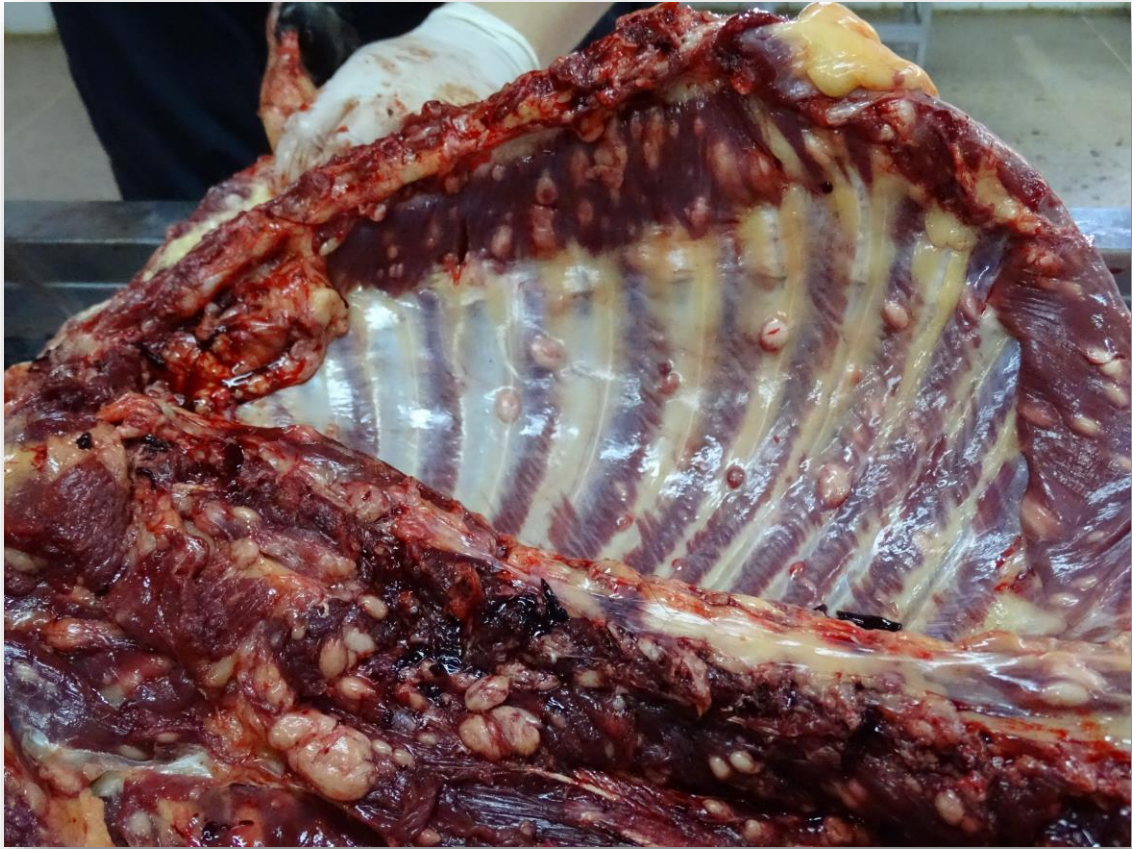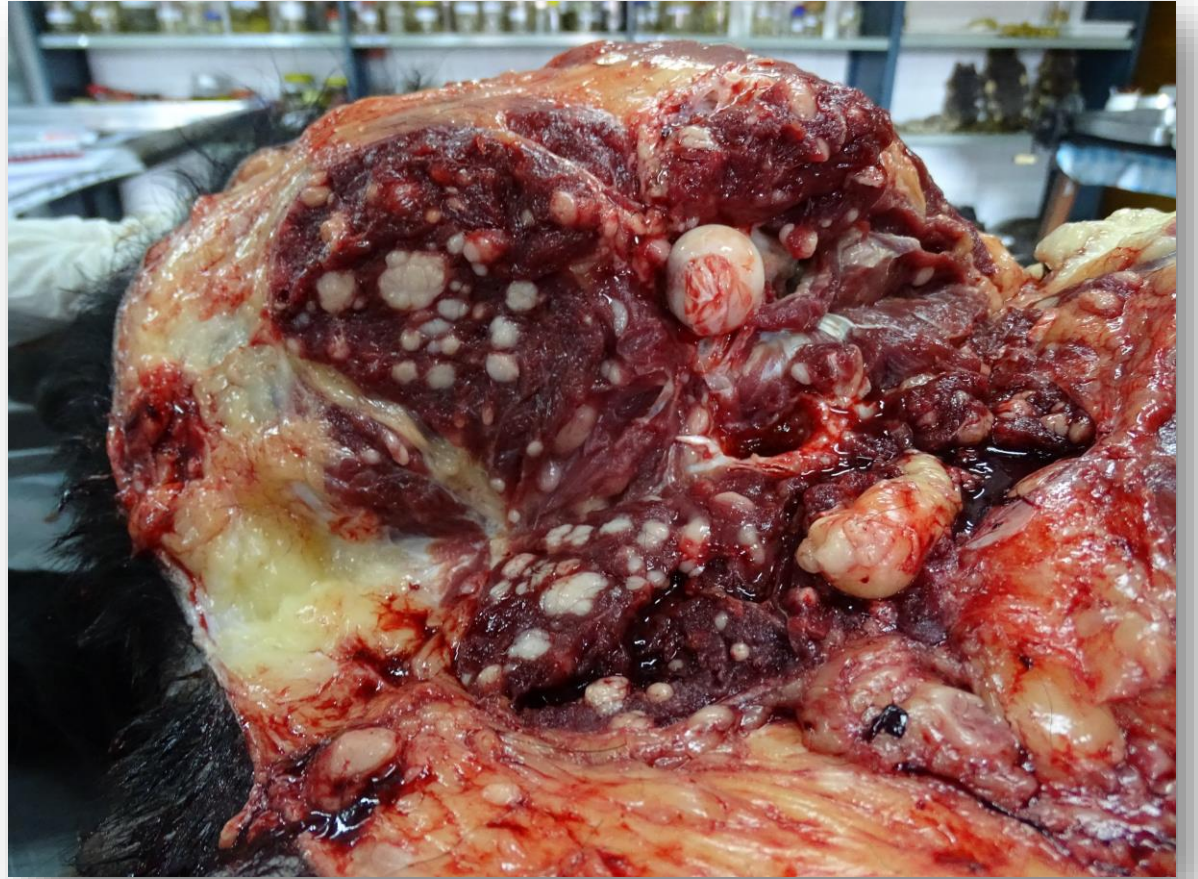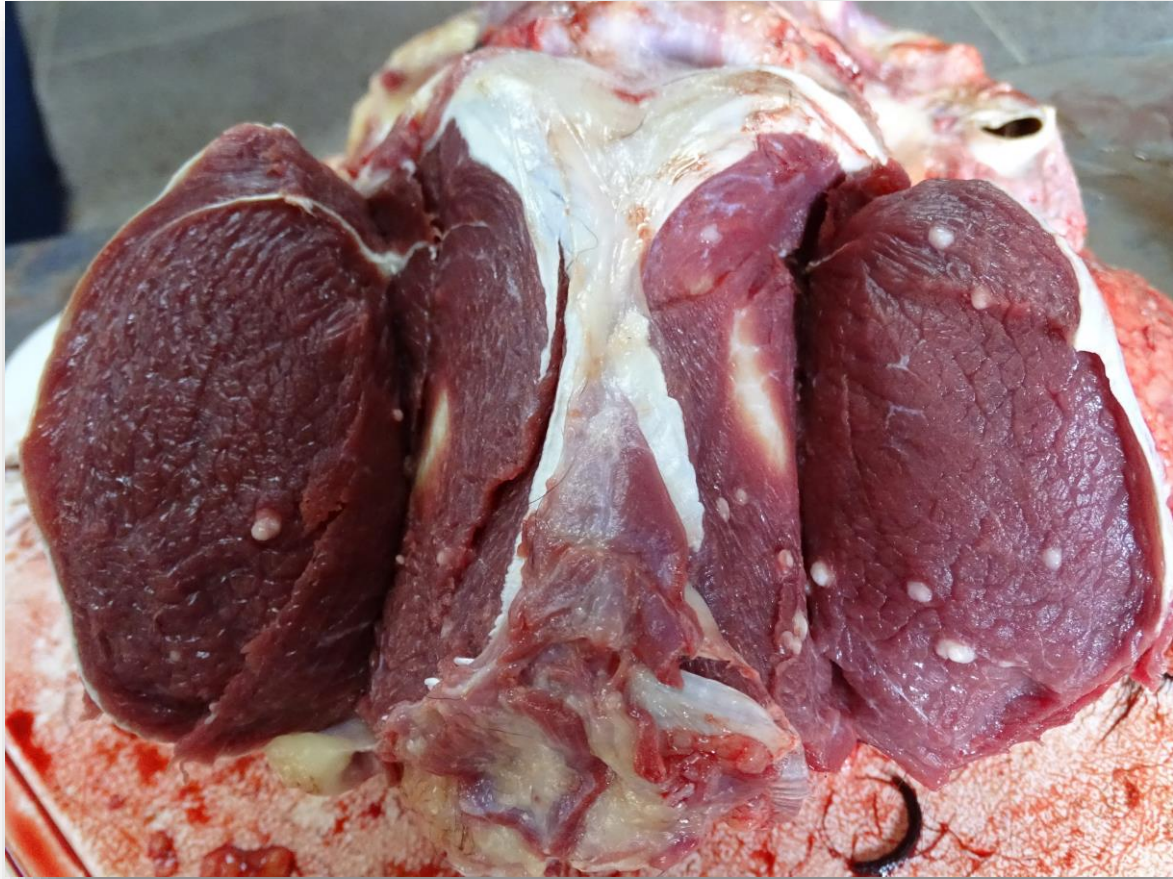
**ESTOY
EMBARAZADA...**

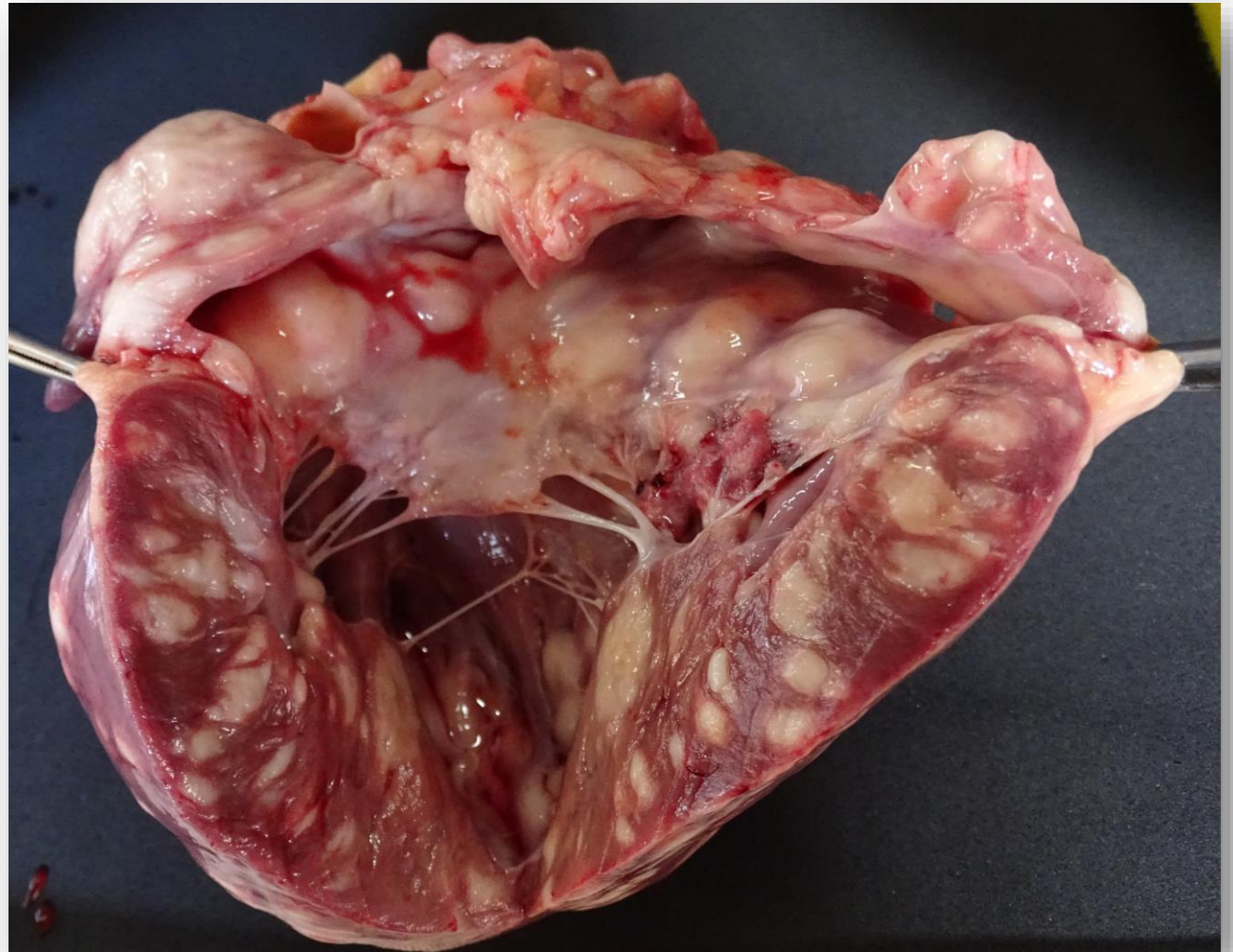
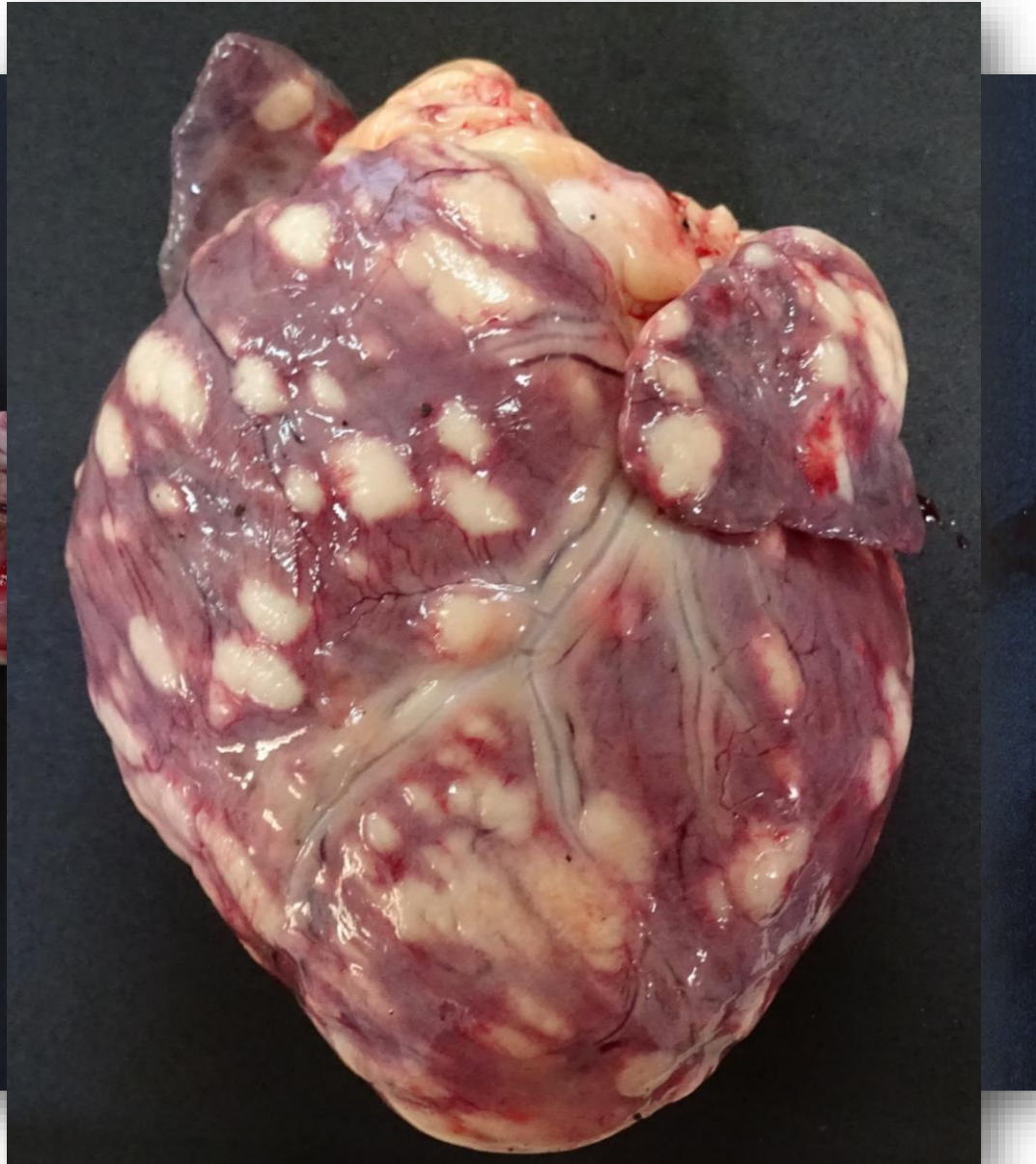

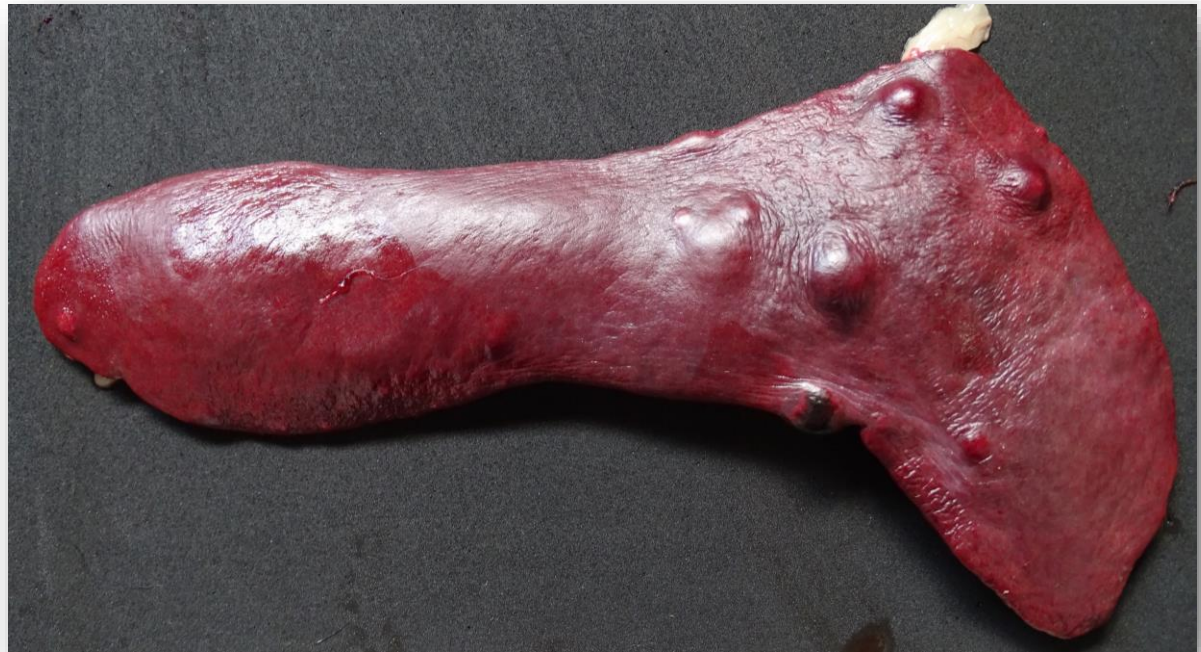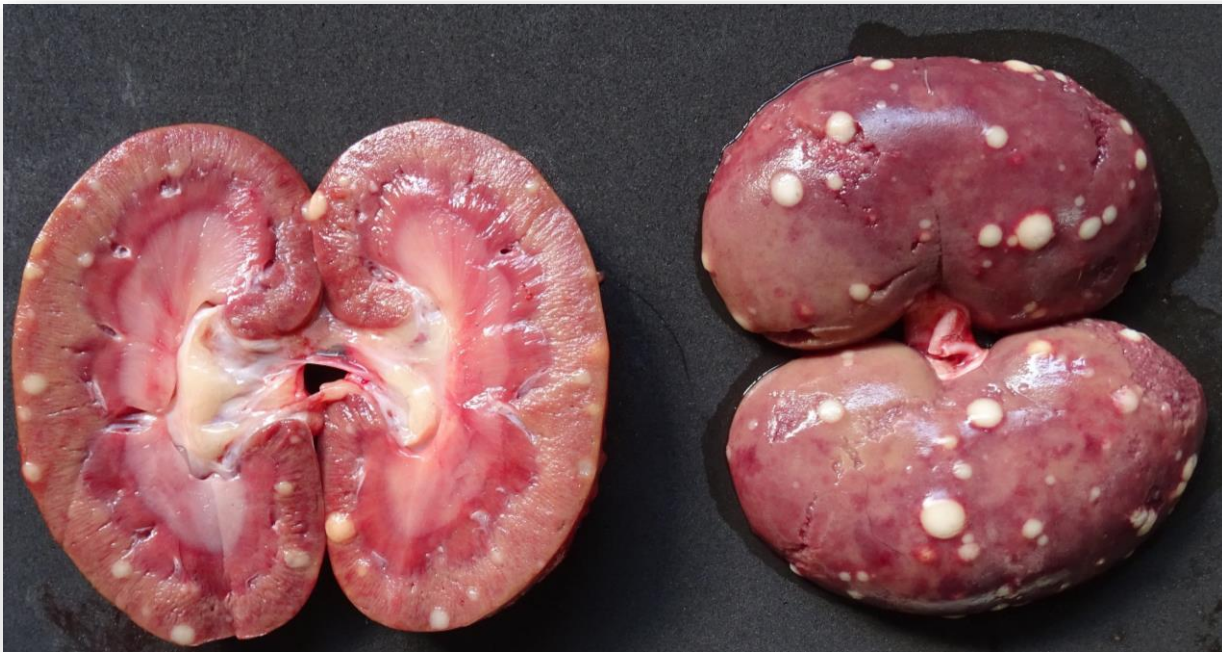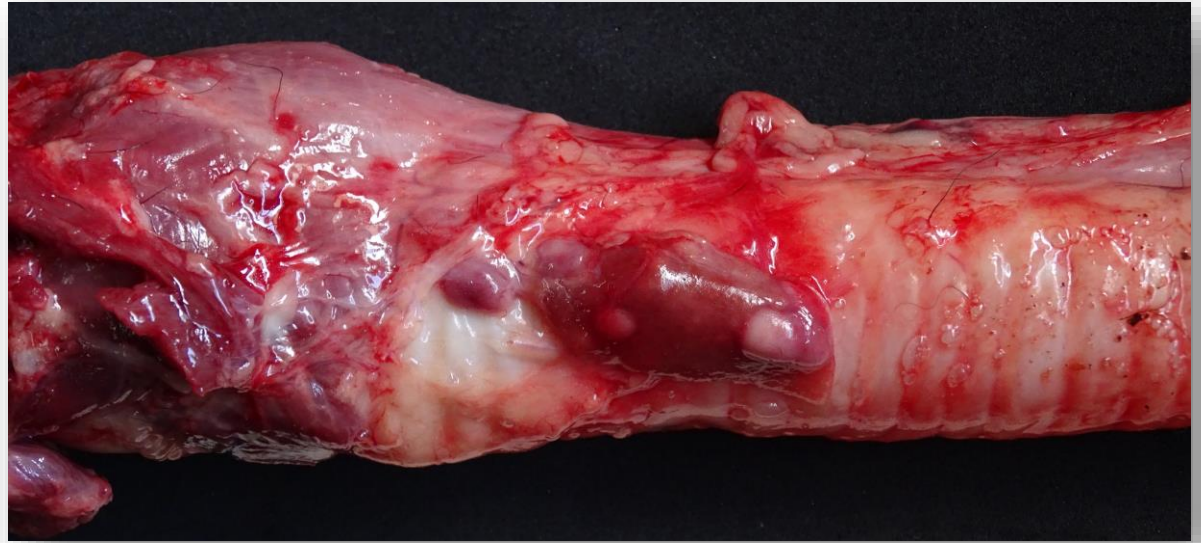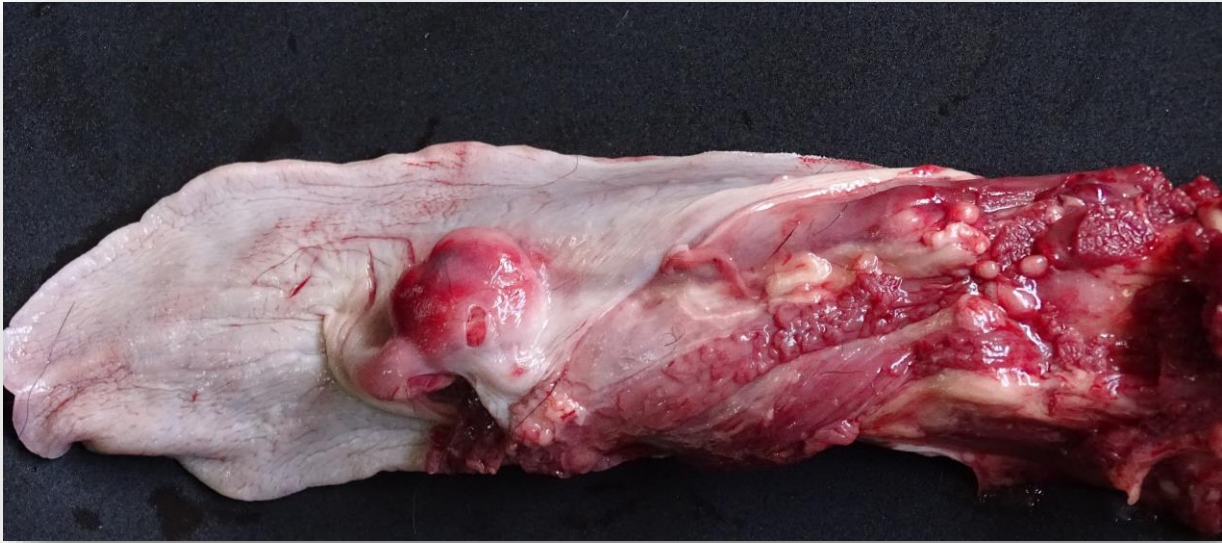ESGAG.COM



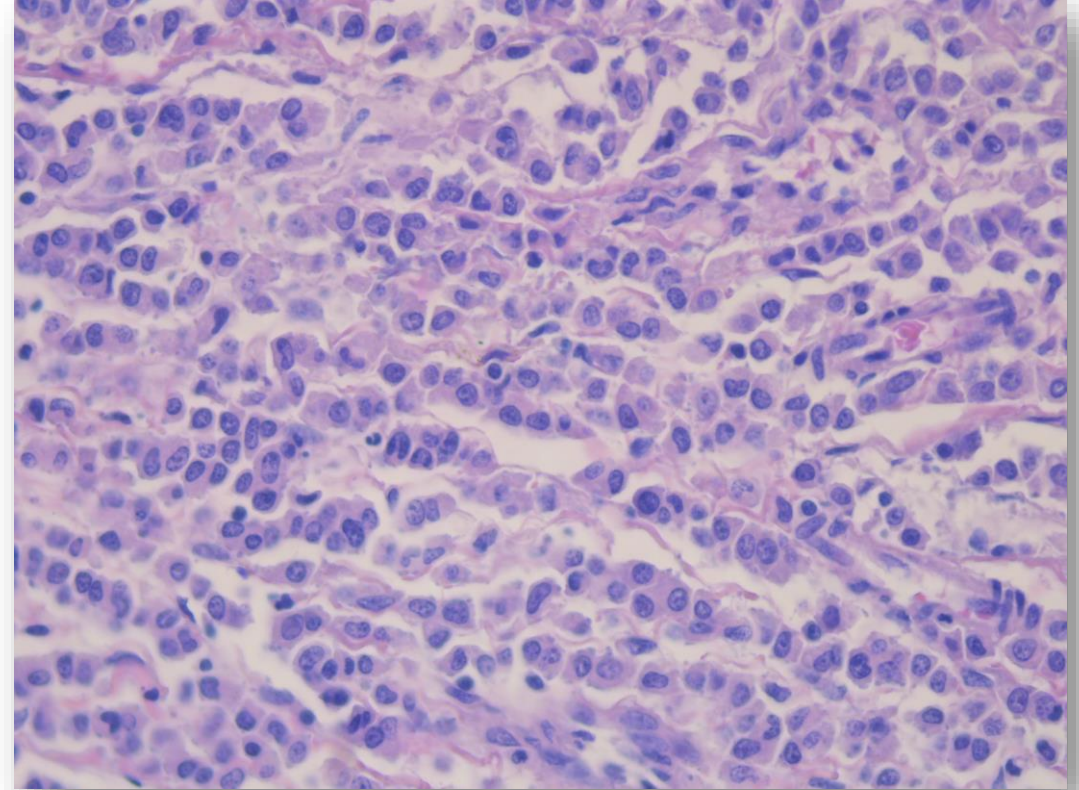
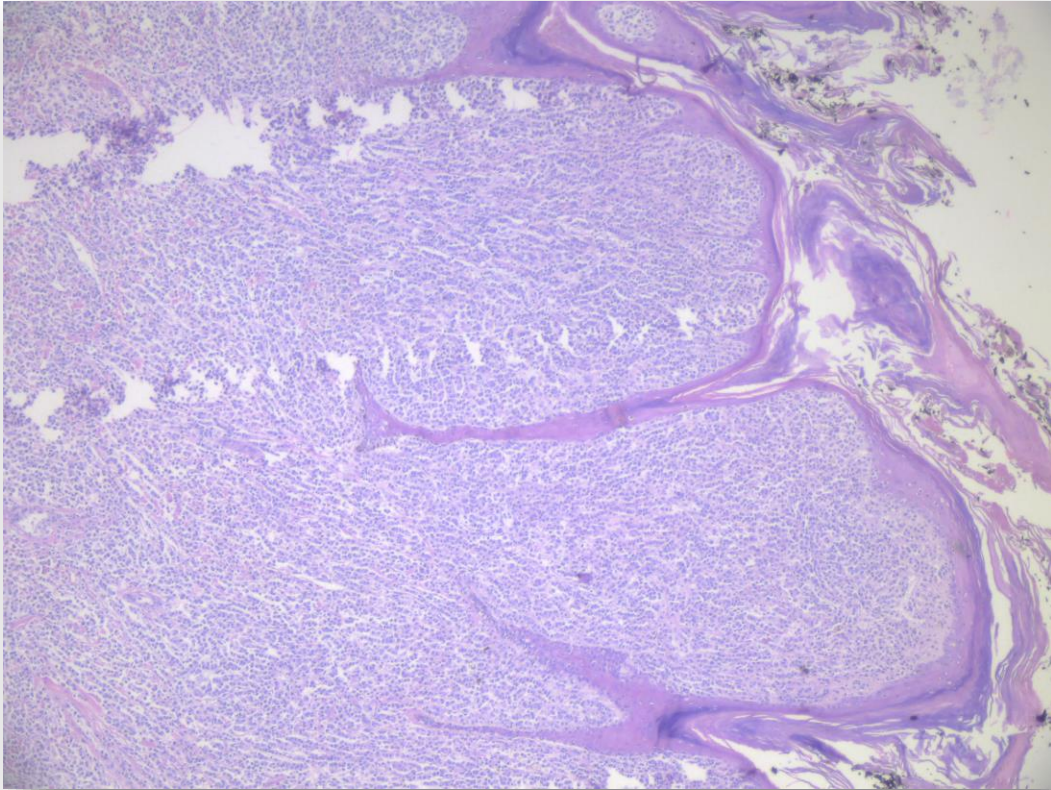






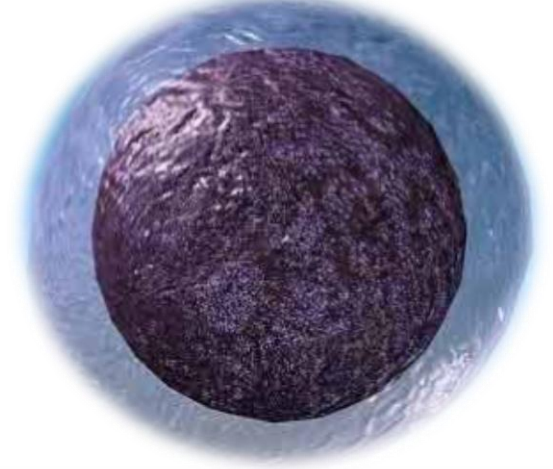


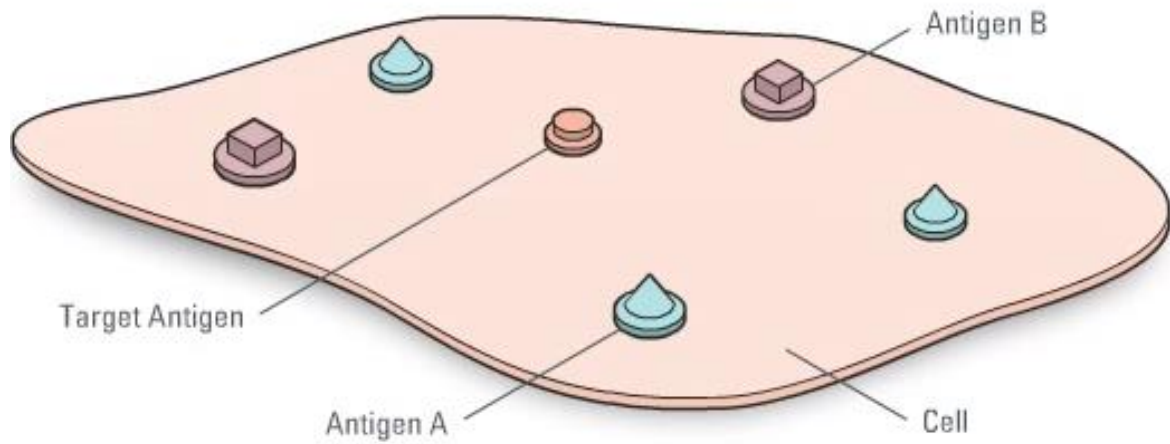
Estudio histopatológico:



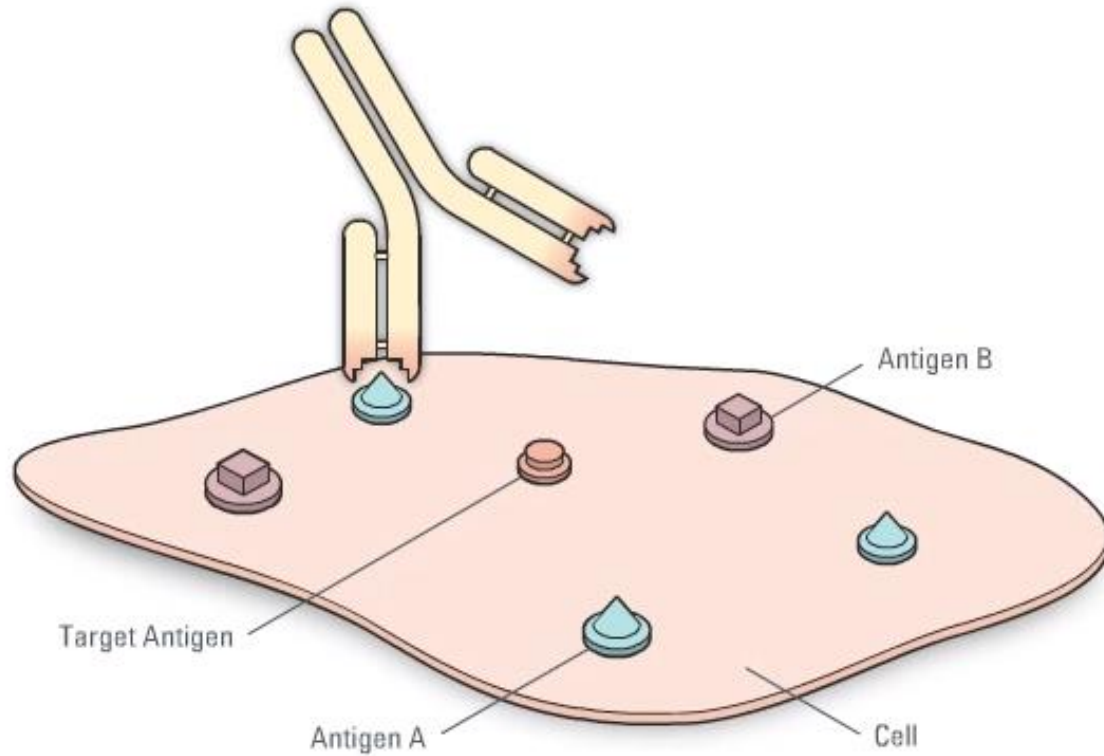
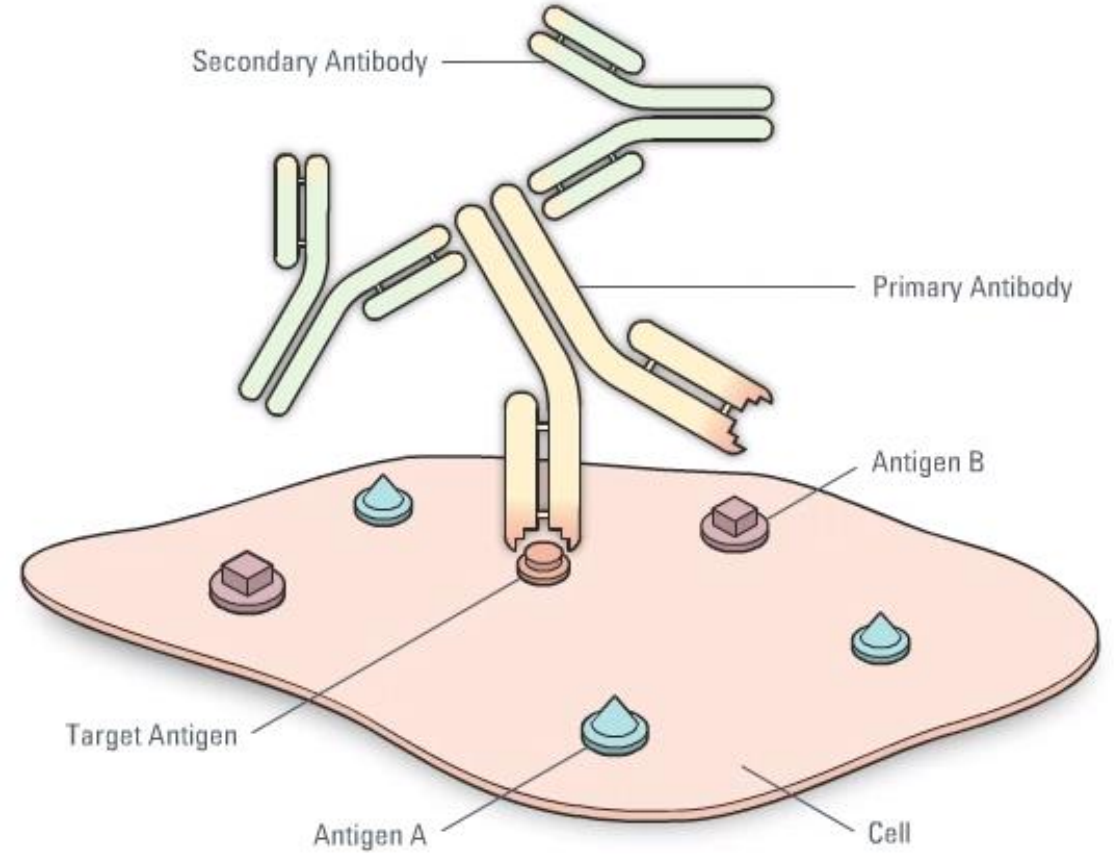
Múltiples diagnósticos diferenciales...

- Linfoma cutáneo
- Histiocitoma cutáneo
- Mastocitoma cutáneo
- Plasmocitoma cutáneo
- Tumor venéreo transmisible
- Sarcoma histiocítico
- Melanoma cutáneo

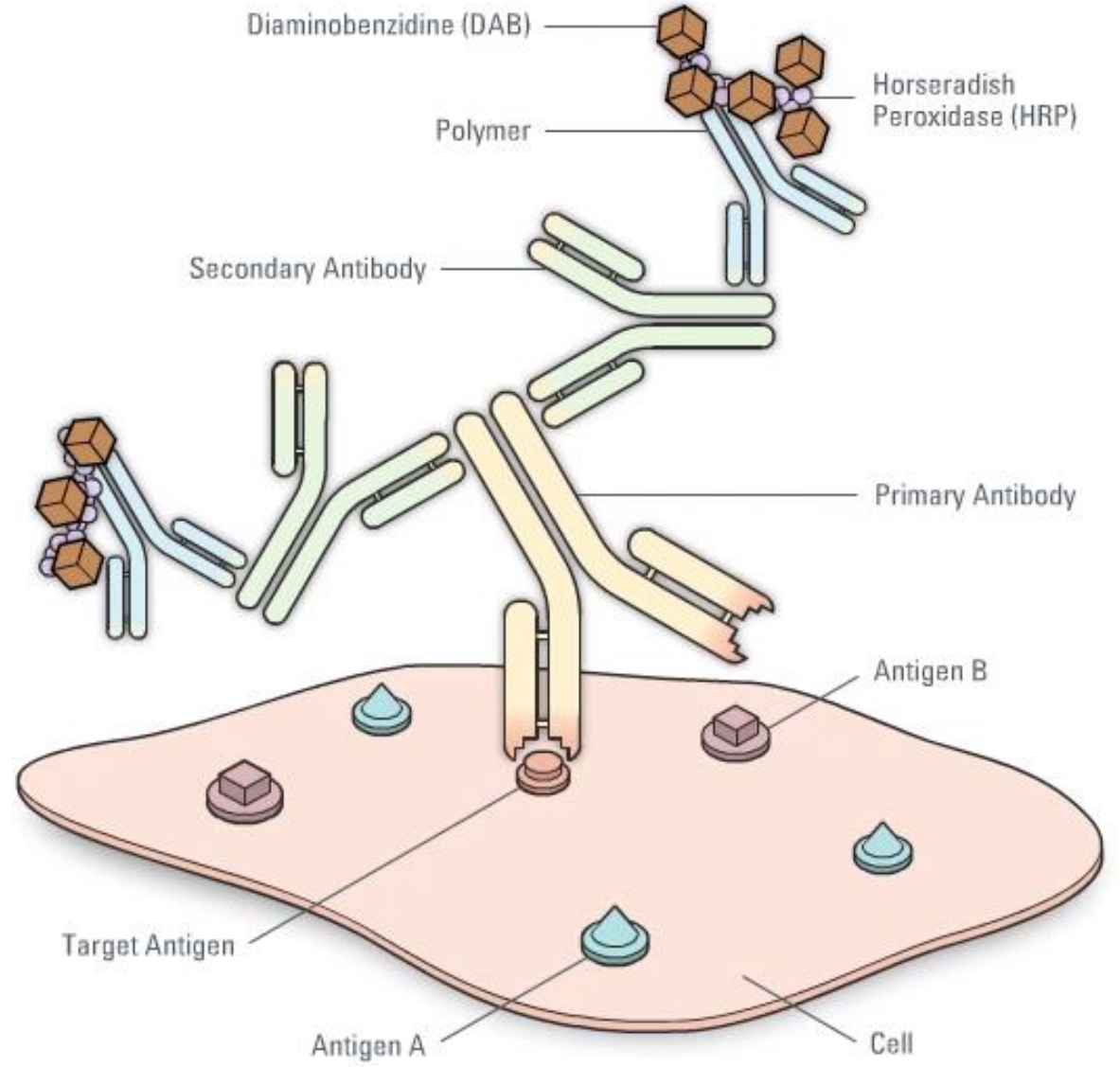
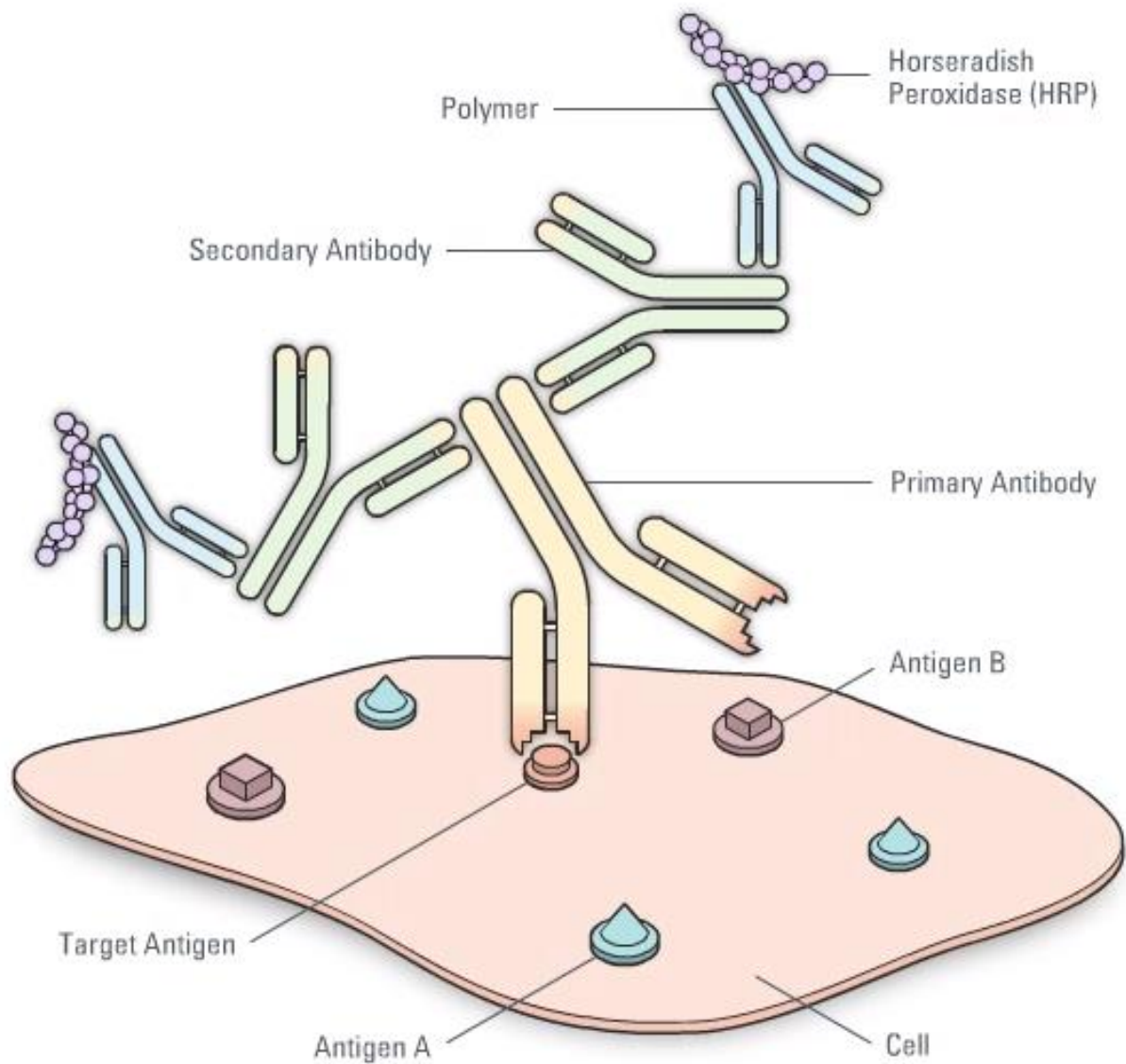




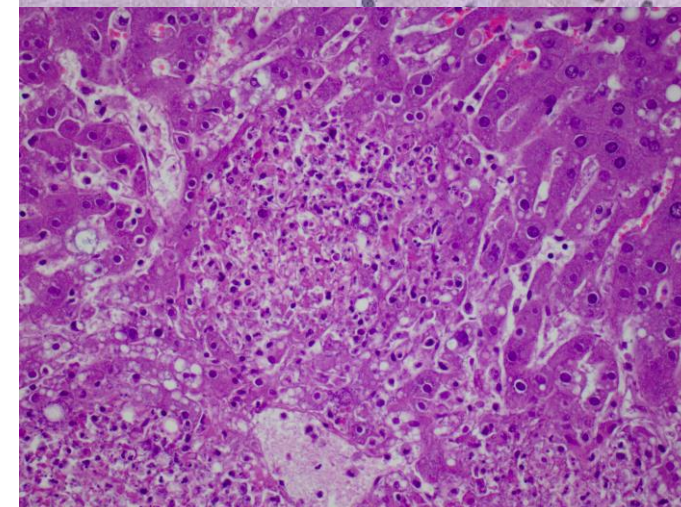
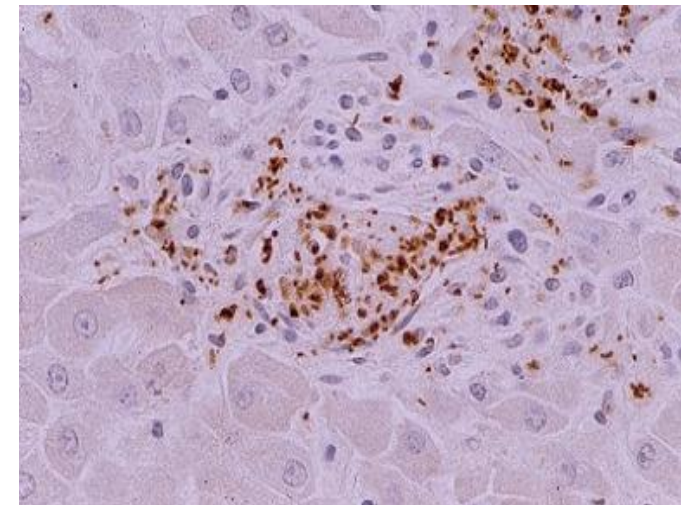
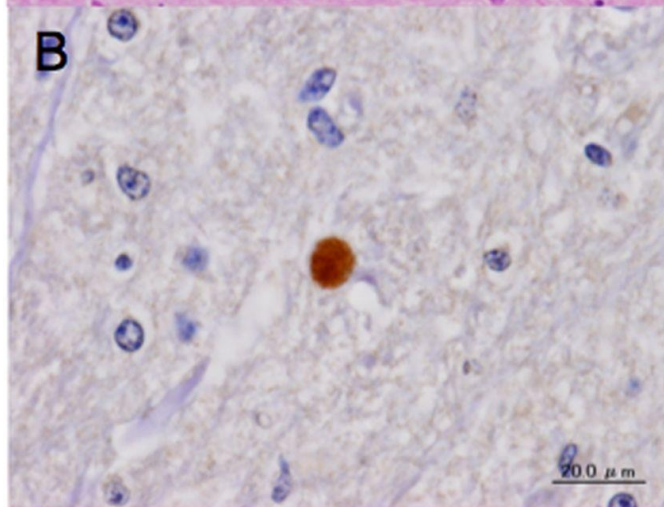
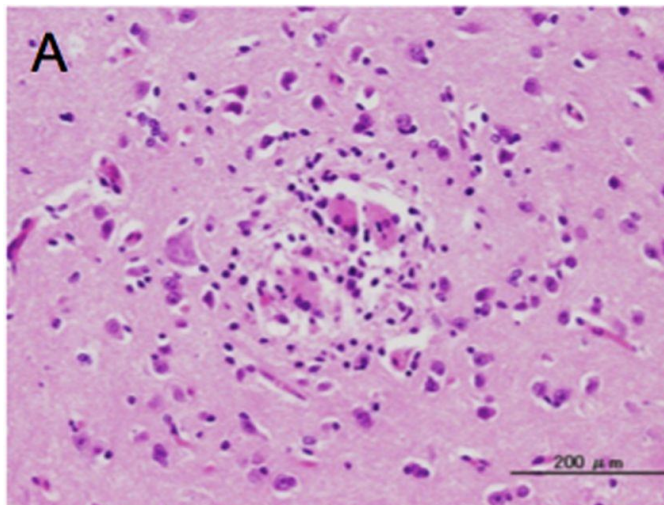
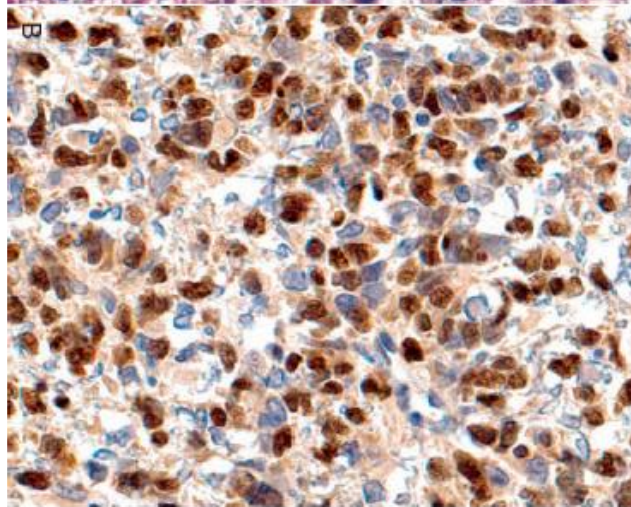
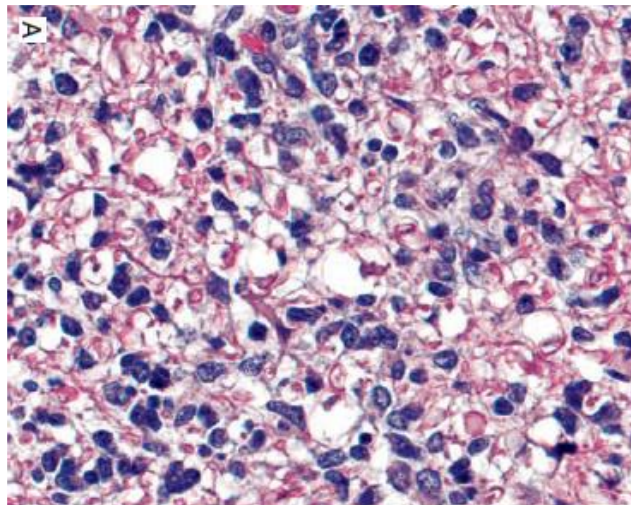
TOOLUMICA



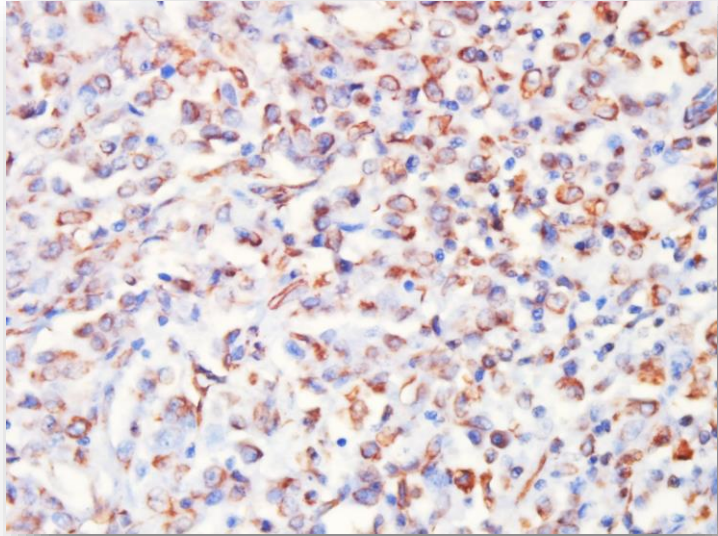
<http://www.leicabiosystems.com/pathologyleaders/animated-guide-to-immunohistochemistry/>



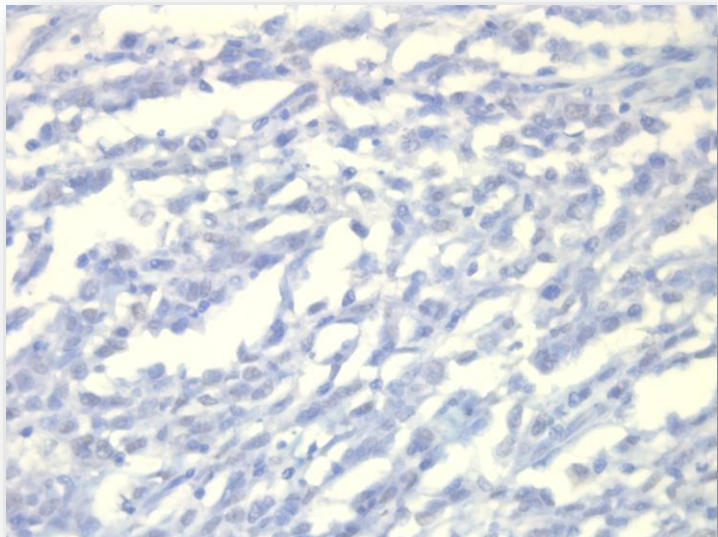
Aplicaciones de la IHQ



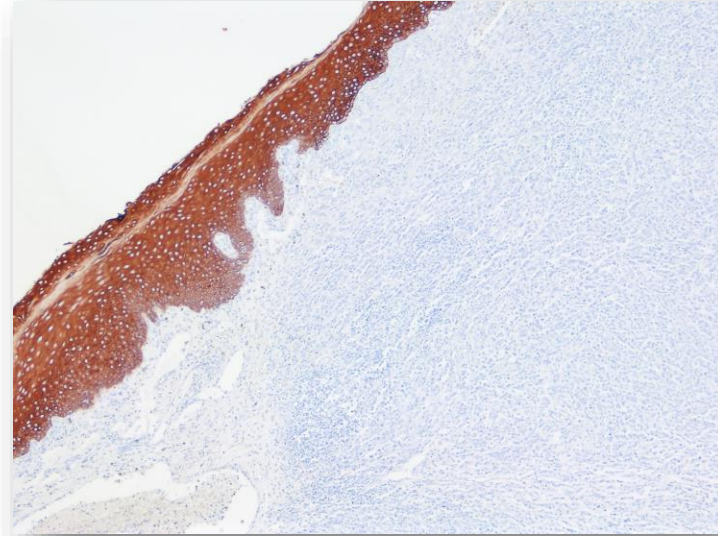
VIMENTINA



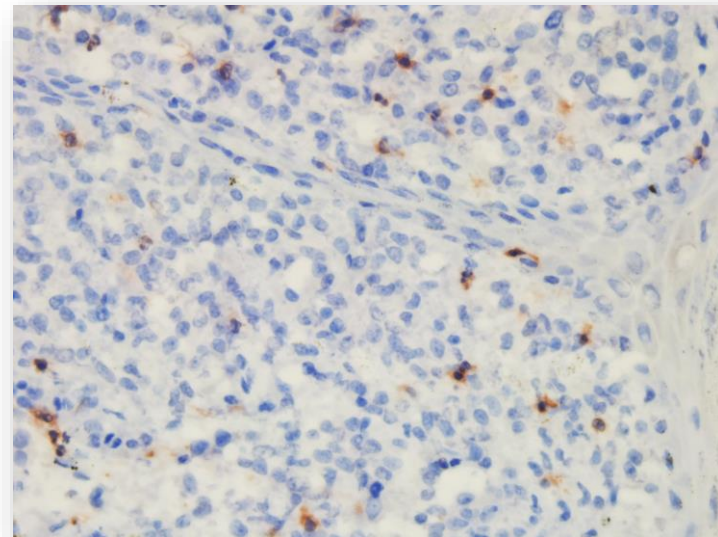
CD 79a



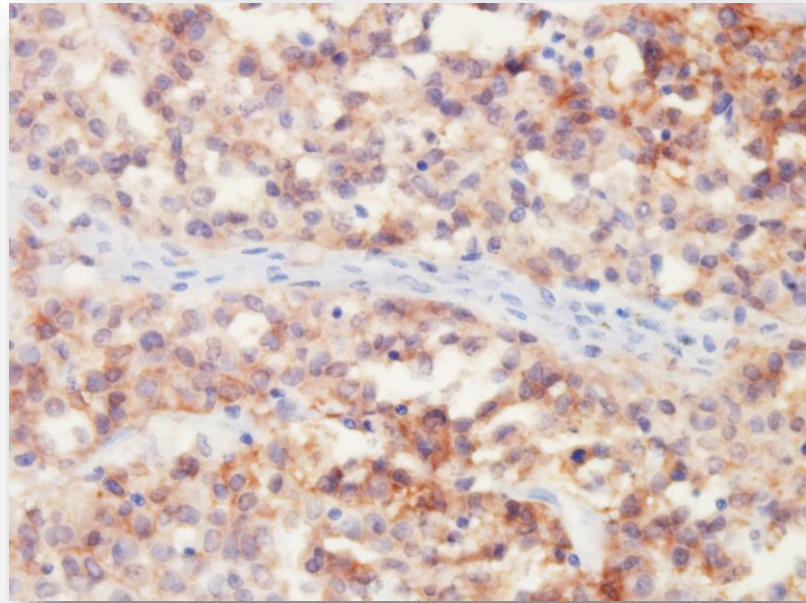
CITOQUERATINA



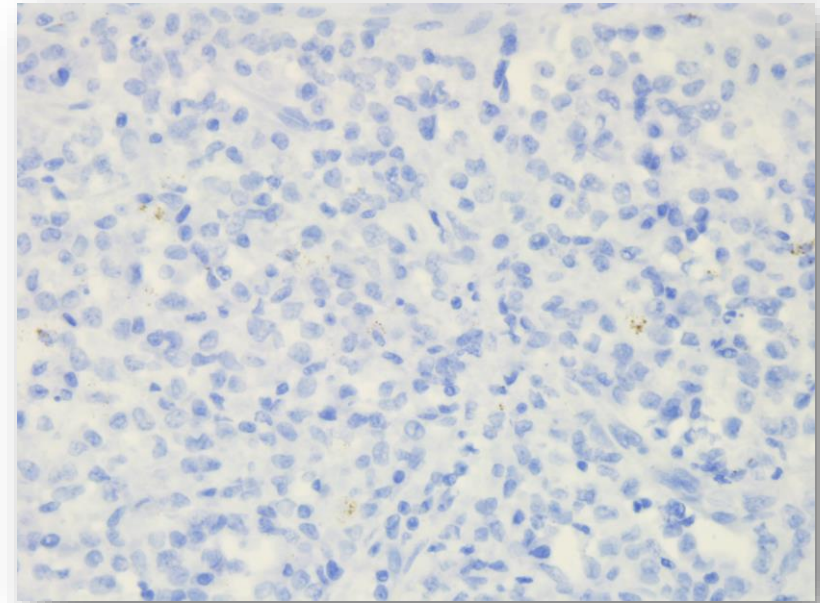
CD3



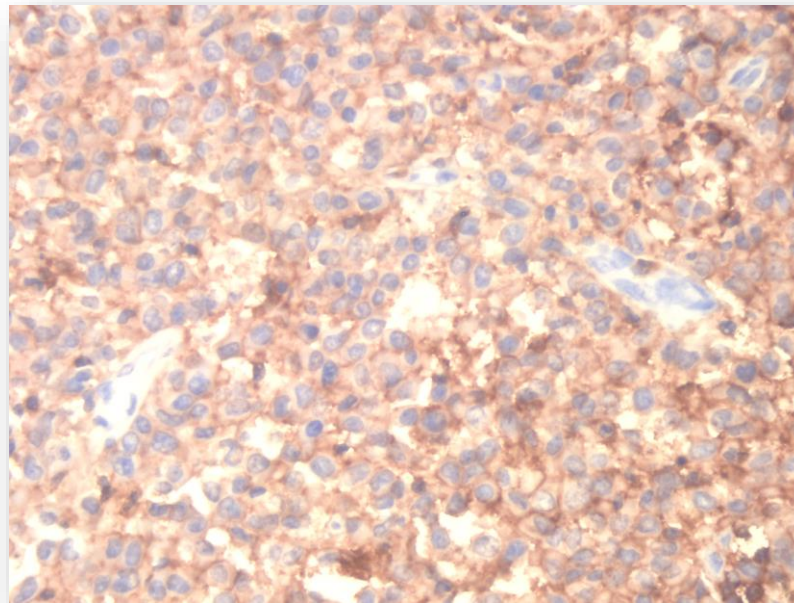
C-KIT



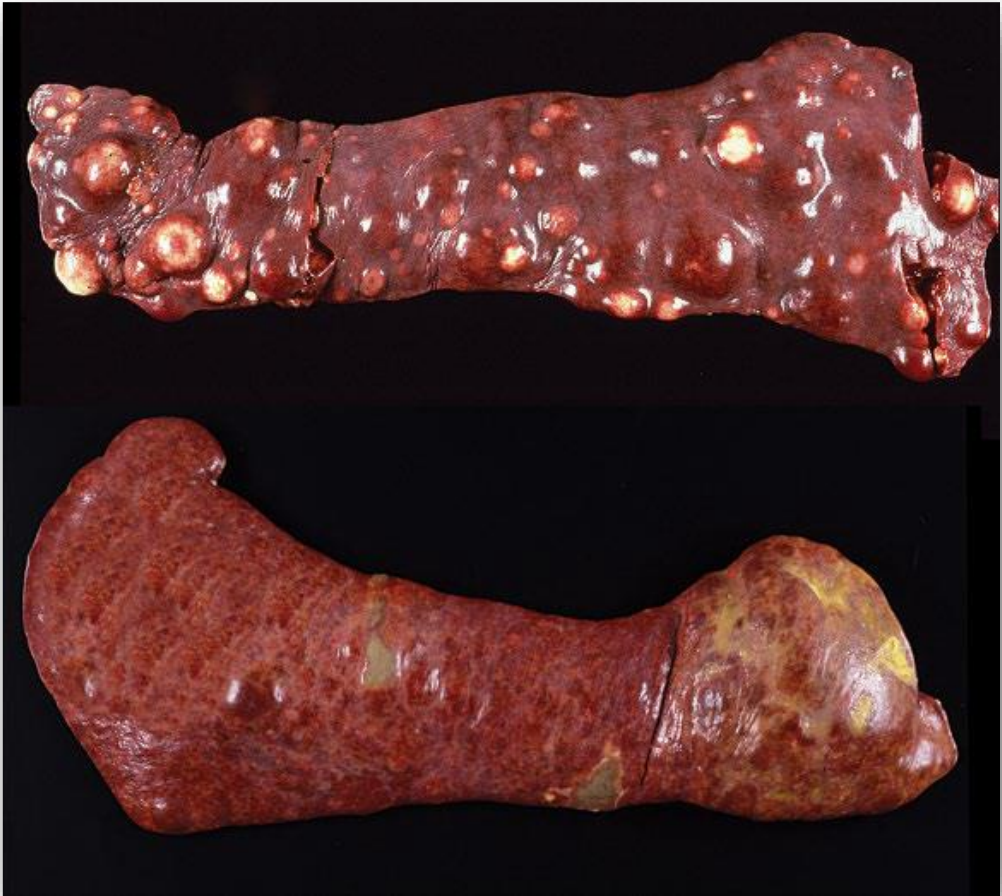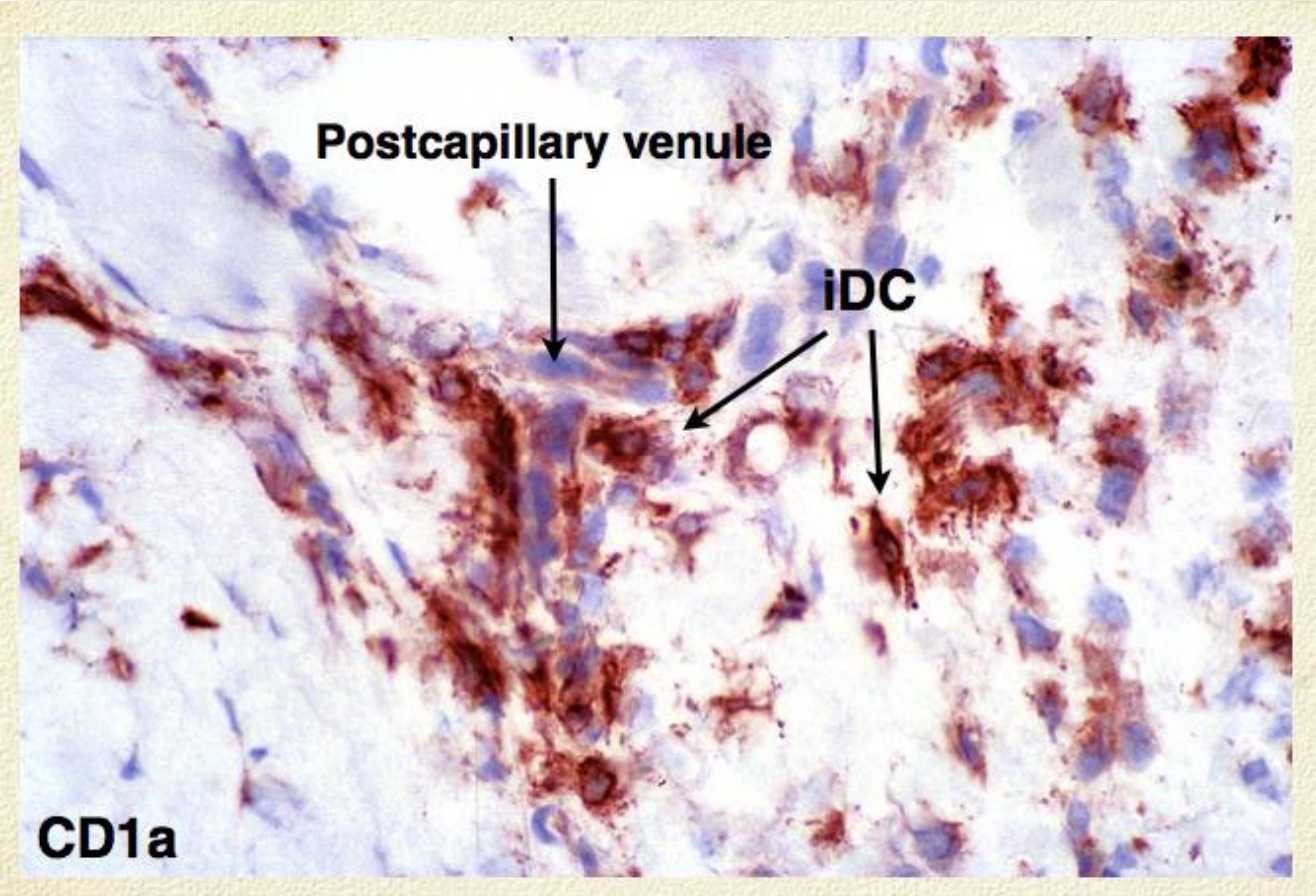
MELAN A




CD 18



Diagnóstico final: Sarcoma histiocito diseminado







MUCHAS GRACIAS!