



Effects of artificial tears on keratocyte cell density after femtosecond laser in situ keratomileusis: a prospective, comparative, interventional, contralateral eye study

Noor Shazana Md Rejab¹, Muhammad Emy Iekmal Bin Yusof², Mohd Radzi Hilmi² and Khairidzan Mohd Kamal³

¹ School of Optometry, Faculty of Medicine and Health Sciences, UCSI University, Malaysia

² Department of Optometry and Visual Science, Kulliyah of Allied Health Sciences, International Islamic University Malaysia, Kuantan, Pahang, Malaysia

³ Department of Ophthalmology, Kulliyah of Medicine, International Islamic University Malaysia, Kuantan, Pahang, Malaysia

ABSTRACT

Background: Flap creation during laser refractive surgery restructures the anterior cornea, particularly the stroma, reducing the keratocyte cell density (KCD). This reduced density makes it challenging to completely regenerate to the presurgical phase. The aim of the present study was to investigate the effects of two types of artificial tear (AT) interventions on KCD up to 3 months after femtosecond laser-assisted in situ keratomileusis (FS-LASIK) surgery.

Methods: This prospective, double-blind, comparative, interventional, contralateral eye study recruited patients with myopia scheduled for FS-LASIK. Inclusion criteria were healthy individuals aged 19 – 25 years with moderate or high myopia, a maximum cylindrical error of - 1.25 diopters, and a maximum pupil size of 6.5 mm who had undergone FS-LASIK and completed 3 months of follow-up. Complete optometric and ophthalmologic examinations were performed. Bilateral simultaneous FS-LASIK surgery was performed using the same femtosecond laser platform as in the standard procedure. The Research Randomizer was used to determine the eye to be treated with Systane® Hydration (Alcon Laboratories, Inc., Fort Worth, TX, USA) or Systane® ULTRA (Alcon Laboratories, Inc., Fort Worth, TX, USA) AT. KCD was examined using real-time images obtained from in vivo confocal microscopy (Heidelberg Retina Tomograph 3 with the Rostock Cornea Module, HRT III RCM); Heidelberg Engineering GmbH, Heidelberg, Germany) at baseline and 1- and 3-month postoperative visits.

Results: We included 60 eyes of 30 participants with a mean (standard deviation) age of 21.34 (1.85) years and a male-to-female ratio of 1:1 who completed 3-month post-FS-LASIK surgery follow-up. KCD did not differ significantly between the two groups at any visit (all $P > 0.05$); nevertheless, mean KCD was initially reduced up to 1 month postoperatively and then revealed a slight increase up to 3 months postoperatively in Systane® Hydration-treated eyes and continued to reduce in Systane® ULTRA-treated eyes. Intragroup comparisons revealed that the eyes treated with ATs experienced a significant reduction in KCD between the preoperative and 1-month postoperative visits and between the preoperative and 3-month postoperative visits (all $P < 0.05$). Treatment-related complications were not observed.

Conclusions: Overall, KCD reduced up to 3 months post-FS-LASIK surgery. Both AT types exerted a comparable effect on postoperative KCD up to 3 months. Future studies with a more frequent administration of ATs, longer follow-up periods, and a control group are required before preliminary outcomes of the present study can be generalized.

KEYWORDS

artificial tear, laser assisted stromal in situ keratomileusis, LASIK, corneal keratocyte, cell density, sodium hyaluronate

Correspondence: Mohd Radzi Hilmi, Department of Optometry and Visual Science, Kulliyah of Allied Health Sciences, International Islamic University Malaysia, Jln Sultan Ahmad Shah Bandar Indera Mahkota 25200, Kuantan, Pahang, Malaysia. Email: mohdradzihilmi@iiu.edu.my. ORCID iD: <https://orcid.org/0000-0001-6352-5152>

How to cite this article: Md Rejab NS, Bin Yusof MEI, Hilmi MR, Kamal KM. Effects of artificial tears on keratocyte cell density after femtosecond laser in situ keratomileusis: a prospective, comparative, interventional, contralateral eye study. *Med Hypothesis Discov Innov Optom*. 2023 Summer; 4(2): 50-56. DOI: <https://doi.org/10.51329/mehdiopometry173>

Received: 07 January 2023; Accepted: 01 May 2023



Copyright © Author(s). This is an open-access article distributed under the terms of the Creative Commons Attribution-NonCommercial 4.0 International License (<https://creativecommons.org/licenses/by-nc/4.0/>) which permits copy and redistribute the material just in noncommercial usages, provided the original work is properly cited.

INTRODUCTION

Femtosecond laser-assisted in situ keratomileusis (FS-LASIK) is a type of laser-refractive surgery (LRS) involving two approaches that use different types of femtosecond lasers. The first approach uses a femtosecond laser (1043-nm wavelength) to create a corneal flap, followed by an excimer laser (193-nm wavelength) to ablate the corneal area according to the corneal flap to correct the refractive error to the desired value [1]. Another type of femtosecond laser is a focusable photodisruptive laser that runs in an infrared form (1000 – 1053-nm wavelength) to ionize the corneal tissue for smaller cavitation and create small bubble sizes during incision for corneal flapping with better precision because of the shorter pulse duration [2].

Flap creation during LRS restructures the anterior cornea, particularly the stroma, reducing the keratocyte cell density (KCD). This reduced density makes it challenging to completely regenerate to the presurgical phase [3]. Thus, the structural, optical, and visual performances of the cornea are compromised [3]. In addition to flap creation, cell necrosis is a factor that reduces KCD [4]. Thus, a poor corneal surface and disorientation at the cellular level cause vision disruption from light scattering [5, 6].

Because these unintended effects of LRS on KCD and corneal epithelial healing are paramount in regaining the best vision [7], using artificial tears (ATs) has been suggested for corneal healing or as a protective approach because of their direct impact on the corneal epithelium layer [8]. The epithelial wound healing rate, re-epithelialization time, and speed were significantly improved by the topical instillation of AT drops [7]. Although the mechanism of re-epithelialization remains unclear, ATs provide lubrication to reduce friction, some resistance, and nourishment and strengthen cell junctions [9].

The aim of the present study was to evaluate the effects of two types of AT interventions in promoting keratocyte regeneration post-FS-LASIK surgery.

METHODS

This prospective, double-blind, comparative, interventional, contralateral eye study was conducted at the Optometry Clinic of the International Islamic University Malaysia (IIUM), Kuliyyah of Allied Health Sciences, IIUM Pahang, Malaysia, from January to June 2019. Patients with myopia who had been scheduled for FS-LASIK surgery were recruited. Ethical approval was obtained from the IIUM Research Ethics Committee (IREC; approval code: IIUM/504/14/11/2/IREC 2019-KAHS [U]), and the study conformed to the tenets of the Declaration of Helsinki. All participants were provided with adequate information regarding the methods and risks of the study. Participation was voluntary, and written consent was obtained from each participant before recruitment.

Inclusion criteria were: healthy individuals; age of 19 – 25 years; spherical refractive error ranging from - 3.00 diopters (D) to - 5.00 D (moderate myopia) or > - 5.00 D (high myopia); maximum cylindrical error of - 1.25 D of cylinder (DC); maximum pupil size of 6.5 mm; history of FS-LASIK with completion of 3 months of follow-up. Exclusion criteria were: abnormal tear film [10]; corneal irregularity-related conditions, such as pterygium and keratoconus [11]; ocular surface abnormalities due to dry eye [12, 13]; history of ocular trauma or ocular pathology; systemic diseases [14]; use of systemic steroids; and lactating or breastfeeding women. Participants who wore soft contact lenses within 2 weeks of the measurements or rigid gas-permeable contact lenses for 4 weeks were excluded [15-17]. Figure 1 illustrates the CONSORT flow diagram of the interventional study.

All eligible participants underwent complete optometry and ophthalmology examinations [18, 19] before commencement of the study. The included patients underwent bilateral simultaneous FS-LASIK surgery using the same femtosecond laser platform, the Zeiss MEL[®] 90 excimer laser (Carl Zeiss Meditec AG, Jena, Germany) [20], using the standard procedure described in detail elsewhere [21], which was performed by a single consultant laser refractive surgeon (K.M.K.) blinded to the group assignment. Both eyes underwent similar treatment postoperatively [22].

Two types of dual polymer ATs were used in this study: Systane[®] Hydration (Alcon Laboratories, Inc., Fort Worth, TX, USA) and Systane[®] ULTRA (Alcon Laboratories, Inc., Fort Worth, TX, USA). Research Randomizer [23] was used to determine the eye to be treated with Systane[®] Hydration or Systane[®] ULTRA AT. The patients and examiners were blinded to the group assignments.

KCD was examined using real-time images obtained from in vivo confocal microscopy (IVCM; Heidelberg Retina Tomograph 3 with the Rostock Cornea Module, HRT III RCM; Heidelberg Engineering GmbH, Heidelberg, Germany). A 63× objective lens with a numerical aperture of 0.9 and a close working distance relative to the applanating Tomocap[™] (Heidelberg Engineering GmbH, Heidelberg, Germany) was used to ensure that the images were of good quality. The IVCM field of measurement was set as 400×400 μm with a

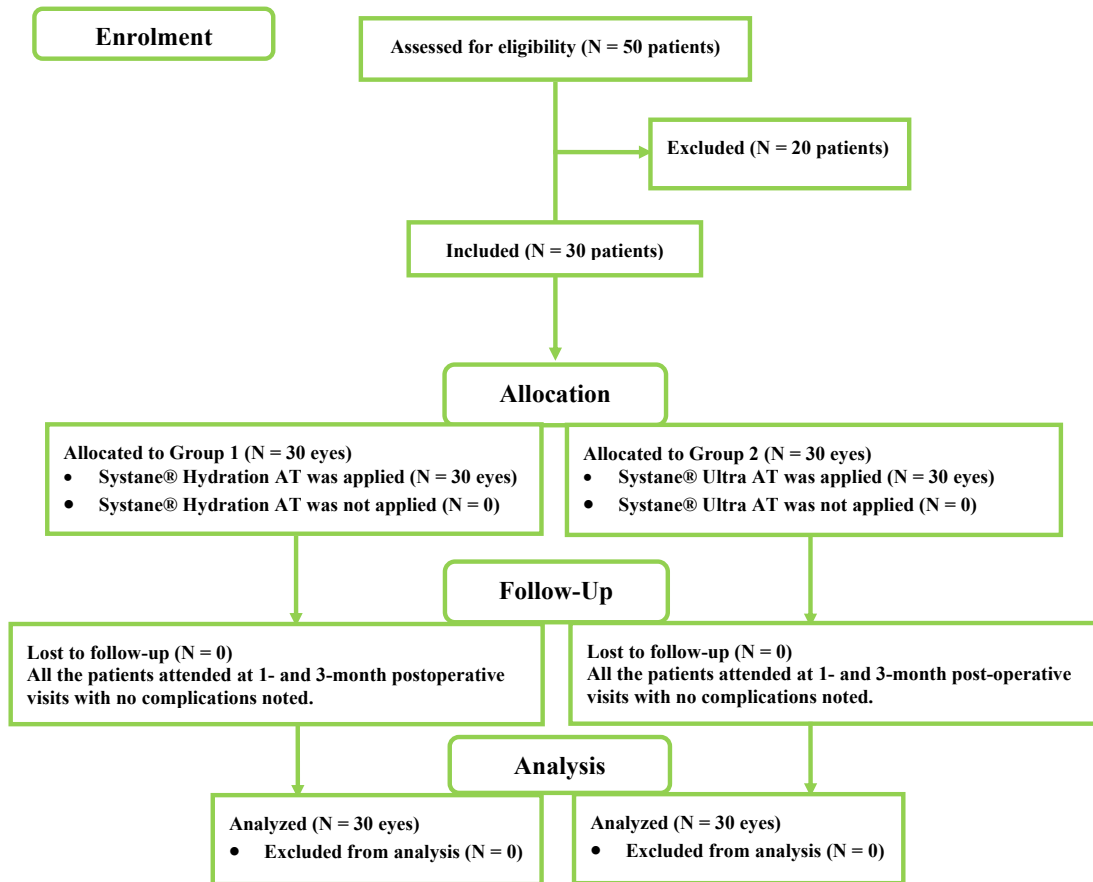


Figure 1. CONSORT flow diagram of the study process showing allocation of participants to group 1 or 2. Abbreviations: N, numbers; AT, artificial tear. Note: Eyes in group 1 received Systane® Hydration (Alcon Laboratories, Inc., Fort Worth, TX, USA) artificial tear (AT), and eyes in group 2 received Systane® Ultra (Alcon Laboratories, Inc., Fort Worth, TX, USA) AT.

1- μ m laser beam spot to ensure better coverage of measurement. The optical resolution for the two-dimensional digital image was 384×384 pixels. Live imaging of the cornea was performed using a charge-coupled device camera attached to a microscope to enable the examiner to determine the exact location for examination. KCD was measured with IVCM preoperatively and 1 and 3 months postoperatively by a single expert technician blinded to the group assignment. Only 10% of the anterior stromal layer was examined and analyzed, as described previously [14].

Before the IVCM procedure, a drop of gental gel (Gental™ Gel; Alcon Pharmaceuticals Ltd., Switzerland) was applied onto and over the objective tip, as was instilled at the tip of the microscope objective lenses, to provide cushioning and eliminate bright reflection before positioning the objective lens in front and at the center of the cornea to obtain a flat field image. A scanning process called confocal microscopy through-focusing (CMTF) was used together in this machine for image capturing. CMTF scans were performed by scanning the image from the endothelium to the epithelium using a lens moving at a constant speed, and simultaneously, the image was collected using the HRT built-in software [24].

Data were analyzed using IBM SPSS Statistics for Windows (version 25.0; IBM Corp., Armonk, NY, USA). Normality of data distribution was evaluated using the Shapiro – Wilk test. The independent *t*-test was used to compare differences between Systane® Hydration and Systane® Ultra ATs in regenerating KCD. The repeated-measures analysis of variance was used to compare the progression of KCD after AT instillation preoperatively and 1 and 3 months postoperatively. The mean values of the 1- and 3-month postoperative KCD were compared with the baseline in each group using the paired *t*-test. A *P*-value < 0.05 was considered to indicate statistical significance.

RESULTS

We included 60 eyes of 30 participants with a mean (standard deviation [SD]) age of 21.34 (1.85) years and a male-to-female ratio of 1:1 who completed 3-month post-FS-LASIK surgery follow-up. KCD did not differ significantly between the two groups at any visit (all $P > 0.05$; Table 1 and Figure 2); nevertheless, the mean KCD reduced up to 1 month postoperatively in both groups and then slightly increased to 3 months postoperatively in group 1 but continued to decrease in group 2 (Table 1 and Figure 2).

Intragroup comparisons revealed that the eyes treated with either ATs significantly reduced in KCD between preoperative and 1-month postoperative visits and between preoperative and 3-month postoperative visits (all $P < 0.05$; Table 1). No treatment-related complications were observed during the follow-up.

DISCUSSION

The impact of ATs on KCD was evaluated with the notion that the corneal flap process can generally reduce KCDs [3]. KCD was significantly reduced at 1 and 3 months postoperatively compared to the baseline mean values in both groups. The mean KCD did not differ significantly between the two groups at any postoperative visit. However, the mean KCD had slightly increased in Systane® Hydration-treated eyes at 3 months postoperatively compared to 1 month postoperatively; nevertheless, in Systane® Ultra-treated eyes, this was reverse.

The corneal healing process involves a series of complex sequential processes, such as activation of keratocytes called fibroblasts, the action of immune cells, and cell migration and proliferation in stromal framework cells [25]. HA can be divided into high-molecular-weight hyaluronic acid (HMW HA) and low-molecular-weight

Table 1. Intragroup and intergroup comparisons of keratocyte cell density

Time Point	Variable	Group 1 (n = 30)	Group 2 (n = 30)	Intergroup P-value
Baseline, Mean \pm SD	KCD (cell / mm ²)	500.3 \pm 69.8	516.3 \pm 51.5	0.589
1-month post-op, Mean \pm SD	KCD (cell / mm ²)	305.6 \pm 51.0	368.0 \pm 83.9	0.079
	Intragroup P-value	0.001	0.014	
3-month post-op, Mean \pm SD	KCD (cell / mm ²)	315.3 \pm 45.8	350.7 \pm 72.7	0.234
	Intragroup P-value	< 0.001	0.008	

Abbreviations: n, number of included eyes; KCD, keratocytes cell density; cells / mm², cells per square millimeter; SD, standard deviation; post-op, postoperative visit. Note: P-values < 0.05 are shown in bold; Intergroup P-value, P-value for comparing KCD between two groups at each visit; intragroup P-value, P-value for comparing KCD at each postoperative visit with baseline values in group 1 or 2; Eyes in group 1 received Systane® Hydration (Alcon Laboratories, Inc., Fort Worth, TX, USA) artificial tear (AT), and eyes in group 2 received Systane® Ultra (Alcon Laboratories, Inc., Fort Worth, TX, USA) AT.

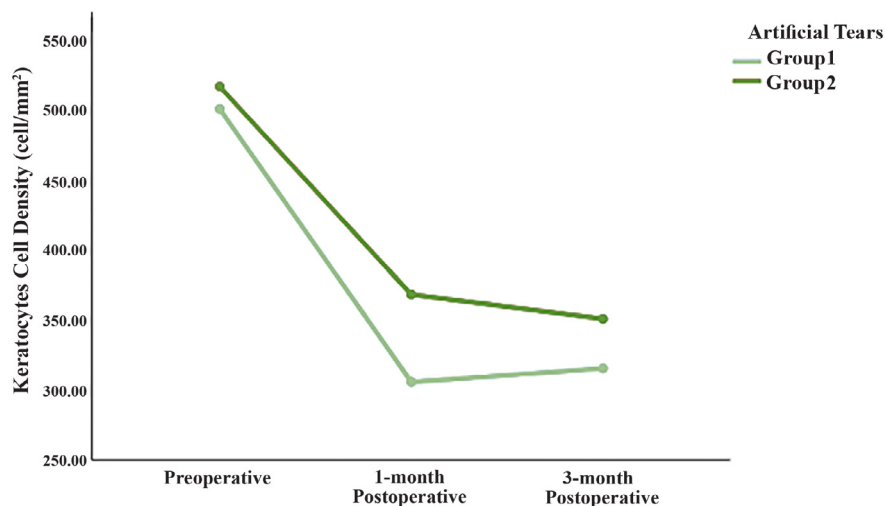


Figure 2. The line graph shows the trend of keratocyte cell density (cell / mm²) changes at all visits for groups 1 and 2. Abbreviations: cells/mm², cells per square millimeter. Note: Eyes in group 1 received Systane® Hydration (Alcon Laboratories, Inc., Fort Worth, TX, USA) artificial tear (AT), and eyes in group 2 received Systane® Ultra (Alcon Laboratories, Inc., Fort Worth, TX, USA) AT; Both AT types exerted a comparable effect on postoperative KCD up to 3 months.

hyaluronic acid (LMW HA) [26], and Systane® Hydration contains LMW HA [27]. HA-containing ATs, such as Systane® Hydration, support corneal cell migration and wound healing [28]. The presence of HA as a component in the formulation [27] could impart anti-inflammatory and antioxidant properties [29]; thus, HA may play a role in wound healing induced by surgery and ocular injuries. Although HA has been noted to rapidly increase cell migration compared to other cell culture approaches [30], its role in inflammation differs based on its molecular weight. HMW HA displays anti-inflammatory activity, whereas LW degradation products of HA can induce inflammation [27, 31, 32]. Considering the presence of LMW HA in Systane® Hydration formulation and slight improvement in KCD 3 months postoperatively in the treated eyes necessitate further investigation on this AT and other available ATs that contained LMW HA, such as Zolag (Laboratories Grin, Mexico D.F., Mexico), Hyabak (Thea Pharmaceuticals, Keele, Newcastle-under-Lyme, UK), and Thealoz Duo (Thea Pharmaceuticals) [27] to discover their exact effects and underlying mechanism on recovering of KCD after KRS.

Sodium hyaluronate (SH) containing ophthalmic solutions are the gold standard method for treating dry eye disease [33]. Both ATs used in this study contained SH [34]. The presence of SH in Systane® Hydration was better than Systane® Ultra in terms of keratocyte regeneration 3 months postoperatively; nevertheless, the difference did not reach statistical significance. This could be because of its ingredients, based on non-sulfated glycosaminoglycan, which retains and binds to water molecules [35, 36]; nevertheless, the validity of this justification should be tested further.

We measured KCD of 10% of the anterior stroma layer. Groups 1 and 2 had comparable mean (SD) values of 500.3 (69.8) and 516.3 (51.5) cell / mm² preoperatively, respectively, 305.6 (51.0) and 368.0 (83.9) cell / mm² 1 month postoperatively, respectively, and 315.3 (45.8) and 350.7 (71.7) cell / mm² 3 months postoperatively, respectively. Using the same instrument, Alvani et al. [37] reported a mean (SD) anterior KCD of 910 (38) cell / mm² in the eyes with normal virgin corneas. Li et al. used a similar instrument and selected two high-quality scans in the central cornea from the layer in the cap or flap 10 µm anterior to the interface (pre-IF) and two from the layer in the stroma 10 µm posterior to the interface (post-IF) to count the KCD [38]. The mean (SD) values for mean KCD in pre- and post-IF regions in the FS-LASIK-treated eyes at baseline were 230 (26.6) and 221.2 (28.6) cells / mm² preoperatively, respectively, 174.0 (46.1) and 138.2 (30.3) cells / mm² at 1 month postoperatively, respectively, and 150.6 (39.5) and 135.1 (30.0) cells / mm² at 3 months postoperatively, respectively. Despite using the same instruments, mean values differed among studies, which could arise from differences in the exact area of measurement due to depth-dependent changes in KCD [39, 40] or different racial backgrounds of the study population. Niederer et al. used IVCN in the eyes with keratoconus and observed a significant difference in cell density when the groups were subanalyzed for ethnicity [41]. Future studies that define the precise depth of measurement in different ethnic groups are required to verify our results.

KCD reduced significantly from the preoperative value to the 1-month postoperative value and from the preoperative value to the 3-month postoperative value in the eyes treated with ATs. Likewise, Li et al. noted an immediate decrease in pre- and post-IF KCD after FS-LASIK surgery and found no signs of recovery at the 6-month follow-up [38]. In the 15 eyes of 15 healthy individuals who had undergone myopic LASIK surgery, Moilanen et al. found a statistically significant decreasing trend in anterior KCD at 3 months, 6 months, and 2 years postoperatively [42]. Canadas et al. used a similar instrument in the 31 eyes of 31 patients who had undergone FS-LASIK surgery and found a reduction in KCD throughout the stromal flap (flap average) and in the stromal bed at 15 months compared to that at 3 months postoperatively and controls. It remained stable afterwards and did not differ significantly between the KCD measured 15 months and 3 – 5 years postoperatively [43]. These findings indicate that the KCD values and rate of regeneration differ with the follow-up duration. Therefore, a similar interventional study with a longer follow-up period may reveal the effects of ATs on KCD regeneration.

This study found comparable outcomes in postoperative KCD using two types of ATs, and the measurements were performed in real time with good accuracy. KCD was significantly reduced at 1 and 3 months postoperatively compared to the baseline mean values in both groups. However, this study has some limitations. First, the low frequency of drops may have affected the outcome, as a single drop may have been inadequate. Second, selecting the surgical approach was limited because we only included FS-LASIK-treated eyes. Third, a control group was lacking to compare the outcome of both interventions with the eyes that did not receive ATs to interpret whether or not the observed trend in KCD resulted from a natural postoperative recovery trend or instilled ATs. Finally, the effects could be extended to a longer postoperative period to evaluate the recovery. Future trials addressing these limitations are necessary before generalizing the research outcomes.

CONCLUSIONS

Overall, the eyes in both treatment groups experienced a reduction in KCD up to 3 months post-FS-LASIK surgery compared to baseline. Both ATs had a comparable effect on postoperative KCD up to 3 months postoperatively without complications. Future studies with more frequent administrations of ATs, longer follow-up periods, and the addition of a control group are required before the preliminary outcomes of the current study can be generalized.

ETHICAL DECLARATIONS

Ethical approval: Ethical approval was obtained from the IIUM Research Ethics Committee (IREC; approval code: IIUM/504/14/11/2/IREC 2019-KAHS [U]), and the study conformed to the tenets of the Declaration of Helsinki. All participants were provided with adequate information regarding the methods and risks of the study. Participation was voluntary, and written consent was obtained from each participant before recruitment.

Conflict of interest: None.

FUNDING

This study was funded by the Ministry of Higher Education under the Fundamental Research Grant Scheme 2019.

ACKNOWLEDGMENTS

This study was financially supported by the Ministry of Higher Education under the Fundamental Research Grant Scheme 2019 (FRGS 2019; FRGS/1/2019/SKK06/UIAM/02/12).

REFERENCES

1. Tabacaru B, Stanca HT. One year refractive outcomes of Femtosecond-LASIK in mild, moderate and high myopia. *Rom J Ophthalmol.* 2017;61(1):23-31. doi: 10.22336/rjo.2017.5 pmid: 29450367
2. Farjo AA, Sugar A, Schallhorn SC, Majmudar PA, Tanzer DJ, Trattler WB, et al. Femtosecond lasers for LASIK flap creation: a report by the American Academy of Ophthalmology. *Ophthalmology.* 2013;120(3):e5-e20. doi: 10.1016/j.ophtha.2012.08.013 pmid: 23174396
3. McLaren JW, Bourne WM, Maguire LJ, Patel SV. Changes in Keratocyte Density and Visual Function Five Years After Laser In Situ Keratomileusis: Femtosecond Laser Versus Mechanical Microkeratome. *Am J Ophthalmol.* 2015;160(1):163-70. doi: 10.1016/j.ajo.2015.04.006 pmid: 25868758
4. Netto MV, Mohan RR, Medeiros FW, Dupps WJ Jr, Sinha S, Krueger RR, et al. Femtosecond laser and microkeratome corneal flaps: comparison of stromal wound healing and inflammation. *J Refract Surg.* 2007;23(7):667-76. doi: 10.3928/1081-597X-20070901-05 pmid: 17912936
5. Hilmi MR, Khairidzan MK, Azemin ZC, Azami MH, Ariffin AE. Measurement of contrast sensitivity using the M&S Smart System II compared with the standard Pelli-Robson chart in patients with primary pterygium. *Makara Journal of Health Research.* 2018;22(3):9. doi: 10.7454/msk.v22i3.9978
6. Chan JW, Edwards MH, Woo GC, Woo VC. Contrast sensitivity after laser in situ keratomileusis. one-year follow-up. *J Cataract Refract Surg.* 2002;28(10):1774-9. doi: 10.1016/s0886-3350(02)01499-2 pmid: 12388027
7. Zhang Y, Lu XY, Hu RJ, Fan FL, Jin XM. Evaluation of artificial tears on cornea epithelium healing. *Int J Ophthalmol.* 2018;11(7):1096-1101. doi: 10.18240/ijo.2018.07.04 pmid: 30046523
8. Watson SL, Daniels JT, Geerling G, Dart JK. Clinical trials of therapeutic ocular surface medium for moderate to severe dry eye. *Cornea.* 2010;29(11):1241-6. doi: 10.1097/ICO.0b013e3181d82f5e pmid: 20697273
9. Lin T, Gong L. Sodium hyaluronate eye drops treatment for superficial corneal abrasion caused by mechanical damage: a randomized clinical trial in the People's Republic of China. *Drug Des Devel Ther.* 2015;9:687-94. doi: 10.2147/DDDT.S77270 pmid: 25678773
10. Mohd RH, Che AM, Ithnin MH. Clinical Features of Lid Margin, Meibomian Gland and Tear Film Changes in Patients with Primary Pterygium. *J Ophthalmic Res Ocular Care.* 2022;5(1):92-6. doi: 10.36959/936/576
11. Hilmi MR, Che Azemin MZ, Mohd Kamal K, Mohd Tamrin MI, Abdul Gaffur N, Tengku Sembok TM. Prediction of Changes in Visual Acuity and Contrast Sensitivity Function by Tissue Redness after Pterygium Surgery. *Curr Eye Res.* 2017;42(6):852-856. doi: 10.1080/02713683.2016.1250277 pmid: 28118054
12. Mohd Radzi H, Khairidzan MK, Mohd Zulfaezal CA, Azrin EA. Corneo-ptyerygium total area measurements utilising image analysis method. *J Optom.* 2019;12(4):272-277. doi: 10.1016/j.optom.2019.04.001 pmid: 31097348
13. Hilmi MR, Kamal KM, Ariffin AE, Norazmar N, Maruziki NN, Musa NH, et al. Effects of different types of primary pterygium on changes in oculovisual function. *Sains Malaysiana.* 2020;49(2):383-8. doi: 10.17576/jsm-2020-4902-16
14. Rejab NS, Hilmi MR, Kamal KM. Validation of IVCIM In Measuring Sub-Basal Nerve Plexus and Keratocyte Cell Density in Corneal Wound Healing. *J Ophthalmic Res Vis Care.* 2022;2(1). doi: 10.54289/JORVC2200105
15. Cook WH, McKelvie J, Wallace HB, Misra SL. Comparison of higher order wavefront aberrations with four aberrometers. *Indian J Ophthalmol.* 2019;67(7):1030-1035. doi: 10.4103/ijo.IJO_1464_18 pmid: 31238402

16. Moshirfar M, Motlagh MN, Murri MS, Momeni-Moghaddam H, Ronquillo YC, Hoopes PC. Galilei Corneal Tomography for Screening of Refractive Surgery Candidates: A Review of the Literature, Part II. *Med Hypothesis Discov Innov Ophthalmol*. 2019;8(3):204-218 [pmid: 31598521](#)
17. Xu Y, Deng J, Zhang B, Xu X, Cheng T, Wang J, et al. Higher-order aberrations and their association with axial elongation in highly myopic children and adolescents. *Br J Ophthalmol*. 2023;107(6):862-868. [doi: 10.1136/bjophthalmol-2021-319769](#) [pmid: 35027355](#)
18. Foulks GN, Pflugfelder SC. New testing options for diagnosing and grading dry eye disease. *Am J Ophthalmol*. 2014;157(6):1122-9. [doi: 10.1016/j.ajo.2014.03.002](#) [pmid: 24631478](#)
19. Messmer EM. The pathophysiology, diagnosis, and treatment of dry eye disease. *Dtsch Arztebl Int*. 2015;112(5):71-81; quiz 82. [doi: 10.3238/arztebl.2015.0071](#) [pmid: 25686388](#)
20. Reinstein DZ, Carp GI, Lewis TA, Archer TJ, Gobbe M. Outcomes for Myopic LASIK With the MEL 90 excimer laser. *J Refract Surg*. 2015;31(5):316-21. [doi: 10.3928/1081597X-20150423-05](#) [pmid: 25974970](#)
21. Jada V, Desai N, Taylor KR, Caldwell MC, Panday VA, Reilly CD. Visual outcomes after femtosecond laser in situ keratomileusis flap complications. *J Cataract Refract Surg*. 2015;41(11):2487-92. [doi: 10.1016/j.jcrs.2015.05.024](#) [pmid: 26703500](#)
22. Shtein RM, Michelotti MM, Kaplan A, Mian SI. Association of surgeon experience with outcomes of femtosecond LASIK. *Ophthalmic Surg Lasers Imaging*. 2012;43(6):489-94. [doi: 10.3928/15428877-20120920-02](#) [pmid: 23776949](#)
23. Urbaniak GC, Plous S (2013). 'Research Randomizer (Version 4.0) [Computer software]'. Available at: <http://www.randomizer.org/> (Accessed: June 22, 2019)
24. Petroll WM, Weaver M, Vaidya S, McCulley JP, Cavanagh HD. Quantitative 3-dimensional corneal imaging in vivo using a modified HRT-RCM confocal microscope. *Cornea*. 2013;32(4):e36-43. [doi: 10.1097/ICO.0b013e31825ec44e](#) [pmid: 23051907](#)
25. Kamil S, Mohan RR. Corneal stromal wound healing: Major regulators and therapeutic targets. *Ocul Surf*. 2021;19:290-306. [doi: 10.1016/j.jtos.2020.10.006](#) [pmid: 33127599](#)
26. Chistyakov DV, Astakhova AA, Azbukina NV, Goriainov SV, Chistyakov VV, Sergeeva MG. High and Low Molecular Weight Hyaluronic Acid Differentially Influences Oxylipins Synthesis in Course of Neuroinflammation. *Int J Mol Sci*. 2019;20(16):3894. [doi: 10.3390/ijms20163894](#) [pmid: 31405034](#)
27. Aragona P, Simmons PA, Wang H, Wang T. Physicochemical Properties of Hyaluronic Acid-Based Lubricant Eye Drops. *Transl Vis Sci Technol*. 2019;8(6):2. [doi: 10.1167/tvst.8.6.2](#) [pmid: 31695963](#)
28. Ho WT, Chiang TH, Chang SW, Chen YH, Hu FR, Wang J. Enhanced corneal wound healing with hyaluronic acid and high-potassium artificial tears. *Clin Exp Optom*. 2013;96(6):536-41. [doi: 10.1111/cxo.12073](#) [pmid: 23782164](#)
29. Dahiya P, Kamal R. Hyaluronic Acid: a boon in periodontal therapy. *N Am J Med Sci*. 2013;5(5):309-15. [doi: 10.4103/1947-2714.112473](#) [pmid: 23814761](#)
30. Gomes JA, Amankwah R, Powell-Richards A, Dua HS. Sodium hyaluronate (hyaluronic acid) promotes migration of human corneal epithelial cells in vitro. *Br J Ophthalmol*. 2004;88(6):821-5. [doi: 10.1136/bjo.2003.027573](#) [pmid: 15148219](#)
31. Litwiniuk M, Krejner A, Speyrer MS, Gauto AR, Grzela T. Hyaluronic Acid in Inflammation and Tissue Regeneration. *Wounds*. 2016;28(3):78-88. [pmid: 26978861](#)
32. Prevo R, Banerji S, Ferguson DJ, Clasper S, Jackson DG. Mouse LYVE-1 is an endocytic receptor for hyaluronan in lymphatic endothelium. *J Biol Chem*. 2001;276(22):19420-30. [doi: 10.1074/jbc.M011004200](#) [pmid: 11278811](#)
33. Baudouin C, Cochener B, Pisella PJ, Girard B, Pouliquen P, Cooper H, et al. Randomized, phase III study comparing osmoprotective carboxymethylcellulose with sodium hyaluronate in dry eye disease. *Eur J Ophthalmol*. 2012;22(5):751-61. [doi: 10.5301/ejo.S000117](#) [pmid: 22287172](#)
34. Carlson E, Kao WWY, Ogundele A. Impact of Hyaluronic Acid-Containing Artificial Tear Products on Reepithelialization in an In Vivo Corneal Wound Model. *J Ocul Pharmacol Ther*. 2018;34(4):360-364. [doi: 10.1089/jop.2017.0080](#) [pmid: 29394128](#)
35. Papakonstantinou E, Roth M, Karakiulakis G. Hyaluronic acid: A key molecule in skin aging. *Dermatoendocrinol*. 2012;4(3):253-8. [doi: 10.4161/derm.21923](#) [pmid: 23467280](#)
36. Belalcázar-Rey S, Sánchez Huerta V, Ochoa-Tabares JC, Altamirano Vallejo S, Soto-Gómez A, Suárez-Velasco R, et al. Efficacy and Safety of Sodium Hyaluronate/chondroitin Sulfate Preservative-free Ophthalmic Solution in the Treatment of Dry Eye: A Clinical Trial. *Curr Eye Res*. 2021;46(7):919-929. [doi: 10.1080/02713683.2020.1849733](#) [pmid: 33289602](#)
37. Alvani A, Hashemi H, Pakravan M, Mahbod M, Seyedian MA, Amanzadeh K, et al. Post-LASIK Ectasia Versus Keratoconus: An In Vivo Confocal Microscopy Study. *Cornea*. 2020;39(8):1006-1012. [doi: 10.1097/ICO.0000000000002318](#) [pmid: 32341315](#)
38. Li M, Niu L, Qin B, Zhou Z, Ni K, Le Q, et al. Confocal comparison of corneal reinnervation after small incision lenticule extraction (SMILE) and femtosecond laser in situ keratomileusis (FS-LASIK). *PLoS One*. 2013;8(12):e81435. [doi: 10.1371/journal.pone.0081435](#) [pmid: 24349069](#)
39. Petroll WM, Robertson DM. In Vivo Confocal Microscopy of the Cornea: New Developments in Image Acquisition, Reconstruction, and Analysis Using the HRT-Rostock Corneal Module. *Ocul Surf*. 2015;13(3):187-203. [doi: 10.1016/j.jtos.2015.05.002](#) [pmid: 25998608](#)
40. Twa MD, Giese MJ. Assessment of corneal thickness and keratocyte density in a rabbit model of laser in situ keratomileusis using scanning laser confocal microscopy. *Am J Ophthalmol*. 2011;152(6):941-953.e1. [doi: 10.1016/j.ajo.2011.05.023](#) [pmid: 21871603](#)
41. Niederer RL, Perumal D, Sherwin T, McGhee CN. Laser scanning in vivo confocal microscopy reveals reduced innervation and reduction in cell density in all layers of the keratoconic cornea. *Invest Ophthalmol Vis Sci*. 2008;49(7):2964-70. [doi: 10.1167/iovs.07-0968](#) [pmid: 18579760](#)
42. Moilanen JA, Holopainen JM, Vesaluoma MH, Tervo TM. Corneal recovery after lasik for high myopia: a 2-year prospective confocal microscopic study. *Br J Ophthalmol*. 2008;92(10):1397-402. [doi: 10.1136/bjo.2007.126821](#) [pmid: 18650214](#)
43. Cañadas P, de Benito-Llopis L, Hernández-Verdejo JL, Teus MA. Comparison of keratocyte density after femtosecond laser vs mechanical microkeratome from 3 months up to 5 years after LASIK. *Graefes Arch Clin Exp Ophthalmol*. 2013;251(9):2171-9. [doi: 10.1007/s00417-013-2357-9](#) [pmid: 23657729](#)