



# Molecular detection of novel herpesviruses and adenoviruses in two species of Australian freshwater turtles

God'spower Richard Okoh<sup>1</sup> · Ellen Ariel<sup>1</sup> · Wytamma Wirth<sup>1,2</sup> · David Whitmore<sup>1</sup> · Paul F. Horwood<sup>1,3</sup>

Received: 18 February 2023 / Revised: 3 July 2023 / Accepted: 11 July 2023  
© The Author(s) 2023

## Abstract

Cutaneous lesions were observed in a wild population of freshwater turtles during routine disease surveillance at Alligator Creek, Townsville, Australia. Previous attempts to identify the causative agent of these lesions were unsuccessful; however, existing evidence suggests viral etiology. To further investigate these events, blood samples and lesion, oral and cloacal swabs collected from 128 freshwater turtles at two locations (Alligator Creek and Ross River) were screened for herpesvirus, adenovirus, poxvirus and papillomavirus by polymerase chain reaction. We detected three novel herpesviruses (chelid herpesvirus 1–3) as well as three adenoviruses (saw-shelled turtle adenovirus 1–3). Phylogenetic analyses showed that the herpesviruses formed a distinct clade with the tumour-associated chelonid alphaherpesvirus 5 (*Scutavirus chelonidalpha5*) within the subfamily *Alphaherpesvirinae*. The adenoviruses clustered with members of the genus *Testadenovirus*. Although the novel herpesviruses and adenoviruses could not be linked to the occurrence of cutaneous lesions, further characterisation will help provide better insights into their clinical, epidemiological and conservation significance.

**Keywords** Herpesviruses · Adenoviruses · PCR · Cutaneous lesions · Freshwater turtles

## Introduction

Australia is home to many freshwater turtles of the Family Chelidae and contains at least 20 endemic species (Davies and Stewart 2013). Most Australian freshwater turtles, including the saw-shelled (*Myuchelys latisternum*) and Krefft's (*Emydura macquarii krefftii*) turtles, belong to the suborder Pleurodira, and are evolutionarily and genetically distinct from turtles in the suborder Cryptodira (Cann and Sadlier 2017; Chiari et al. 2012). Australian freshwater turtles comprise two morphological forms, the short-necked and the long-necked turtles, which are both widely distributed across the country (Seddon et al. 1997; Scheyer

2009; Petrov et al. 2018). They are highly aquatic species and mainly leave the water to lay eggs, bask, or migrate between water bodies in search of mates or food (Brown and Brooks 1993; Buhlmann et al. 2008). Freshwater turtles are long-lived and well adapted to multiple foraging strategies, including scavenging, opportunism, herbivory and omnivory (Petrov et al. 2018). Thus, they play a vital role in maintaining ecological diversity and serve as important environmental health indicators (Lovich et al. 2018).

Many extant Australian freshwater turtles are listed as vulnerable, endangered, or critically endangered by conservation agencies (Van Dyke et al. 2019). The survival of these turtles is constantly threatened by different factors, including human activities, natural disasters and disease outbreaks (Van Dyke et al. 2019). Viral infections can potentially threaten the extinction of freshwater turtle species in local catchments, as exemplified in the Bellinger River snapping turtle (*Myuchelys georgesi*) population in 2015 (Cann et al. 2015; Spencer et al. 2018; Zhang et al. 2018; Van Dyke et al. 2019). Similarly, a novel turtle fraserivirus 1 (TFV1) and the soft-shelled turtle systemic septicaemia spherical virus (STSSSV) have been reported to cause severe mortality events in freshwater turtle populations in USA and China respectively (Chen et al. 2017; Lyu et al. 2019; Waltzek et al.

✉ God'spower Richard Okoh  
godspower.okoh@my.jcu.edu.au

✉ Paul F. Horwood  
paul.horwood@jcu.edu.au

<sup>1</sup> College of Public Health, Medical and Veterinary Sciences, James Cook University, Townsville, QLD 4811, Australia

<sup>2</sup> Peter Doherty Institute for Infection and Immunity, University of Melbourne, Melbourne, Australia

<sup>3</sup> Australian Institute of Tropical Health and Medicine, James Cook University, Townsville, QLD 4811, Australia

2022). Therefore, it has become pertinent to monitor the health of threatened populations for the timely detection and possible prevention of novel or emerging viral diseases.

Herpesviruses (HVs) and adenoviruses (AdVs) are important pathogens of chelonians that have been implicated in various clinical diseases with both pathogens and non-infectious (stress or immunosuppression) factors considered as contributing in most cases (Adamovicz et al. 2018; Archer et al. 2017; Farkas and Gál 2009; Okoh et al. 2021; Sim et al. 2016; Yonkers et al. 2015). HVs have been identified in clinically healthy chelonians due to their ability to remain latent in susceptible hosts (Aplasca et al. 2019; Lindemann et al. 2018; Marschang et al. 2015; Nieto-Claudin et al. 2022; Vincent et al. 2023; Woźniakowski and Samorek-Salamonowicz 2015). However, HVs can cause severe diseases when reactivated in some hosts or when the virus cross-infects a closely related species (Okoh et al. 2021). HVs have been associated with necrotizing and necrotic stomatitis, glossitis, rhinitis in tortoises (Hunt 2006; Okoh et al. 2021); proliferative and/or ulcerative lesions of the skin and shell in freshwater turtles (Okoh et al. 2021; Široký et al. 2018); and fibropapillomatosis and grey-patch disease in sea turtles (Cárdenas et al. 2019; Jacobson et al. 1986; Robben et al. 2023; Stacy et al. 2008). AdVs that have been found to infect chelonians include members of the genera *Siadenovirus*, *Atadenovirus* and *Testadenovirus* (Rivera et al. 2009; Doszpoly et al. 2013; Garcia-Morante et al. 2016; Salzmänn et al. 2021). While siadenovirus (Sulawesi tortoise adenovirus 1) and atadenovirus (spur-thighed tortoise adenovirus 1) have been associated with anorexia, lethargy, ulcerations and erosions of the oral mucosa, stomatitis, esophagitis and mortality in tortoise (Rivera et al. 2009; Garcia-Morante et al. 2016), testadenoviruses have been frequently detected in clinically healthy chelonians (Doszpoly et al. 2013; Salzmänn et al. 2021; Nieto-Claudin et al. 2022).

During a routine health assessment and monitoring of wild freshwater turtles at Alligator Creek, North Queensland in 2016, cutaneous lesions were observed on a large proportion of the turtles examined (Wirth et al. 2020). An investigation was conducted to identify and characterise the

causative agents from lesion samples (Wirth et al. 2020). Although a specific causative agent was not identified, the pathological features of the cutaneous lesions (Fig. 1) appear to be consistent with previously described lesions in turtles and other reptilian species associated with viral agents (detected as primary or copathogens) including herpesviruses (Rebell et al. 1975; Fischer et al. 2006; Cowan et al. 2015; Shilton et al. 2016), adenovirus (Perkins et al. 2001), papillomaviruses (Jacobson et al. 1982), ranaviruses (Stöhr et al. 2013; Wirth et al. 2019), reovirus (Uğurtas et al. 2008) and poxviruses (Jacobson et al. 1979; Huchzermeyer et al. 1991; Penrith et al. 1991; Buenviaje et al. 1998). The present study further assessed the health of freshwater turtle populations at Alligator Creek to determine the occurrence and the association with some of these suspected viral pathogens (herpes-, adeno-, pox- and papillomaviruses) with the cutaneous lesions. Here, we employed strategies that could improve detection, and these included the collection and testing of different sample types and modification of existing protocols as well as the design of new protocols.

## Materials and methods

### Primary sampling location

Freshwater turtle sampling was conducted in Alligator Creek 25 km south of the city of Townsville, Queensland, Australia (latitude:  $-19^{\circ} 25' 26.00''$  S; longitude:  $146^{\circ} 56' 44.02''$  E). The creek flows from Mount Elliott in Cape Bowling Green National Park to Cleveland Bay within the region of Cape Cleveland (Queensland). The lands along Alligator Creek outside the National Park have a population of approximately 1353 people with a range of agricultural and industrial activities (Australian Bureau of Statistics 2016). The sampling pond at the border of the national park is inhabited by two species of freshwater turtle, *Emydura macquarii krefftii* and *Myuchelys latisternum* as well as other freshwater animal species including fish, crustaceans and crocodiles. Samples were also collected from the Ross River in Townsville, Queensland, Australia

**Fig. 1** Skin lesions (red arrows) on the neck and limbs of freshwater turtles (Krefft's river and Saw-shelled turtles) at Alligator Creek



(latitude:  $-19^{\circ} 24' 13.19''$  S; longitude:  $146^{\circ} 44' 1.19''$  E). The river is 49 km long and flows from the Hervey Range below Pepper Pot Mountain through Townsville City and empties in the Coral Sea (<http://www.bonzle.com/c/a?a=p&p=208535&cmd=sp>).

To assess the association between the lesions and the potential pathogens identified in this study, we carried out a case–control investigation (Thrusfield 2007) where the population of turtles in Alligator Creek was designated the case group. Ross River is located within 20 km of Alligator Creek on a different watershed. The two waterways contain the same species of turtles and have been monitored annually for over a decade by the JCU Turtle Health Team without ever noticing lesions on the skin of turtles from Ross River similar to the ones recorded in Alligator Creek. The Ross River turtles were therefore designated the control group, and this allowed us to statistically test the association between pathogens and lesions using odds ratio (Thrusfield 2007).

### Sample collection and DNA extraction

Turtles were captured by hand while snorkelling and various samples were collected from 28 Krefft's river turtles (*Emydura macquarii krefftii*) and 29 saw-shelled turtles (*Myuchelys latisternum*). Additional samples were obtained from freshwater turtles (67 Krefft's and 4 saw-shelled turtles) captured by baited traps in Ross River, Townsville. For purposes of identification and disease monitoring, the captured turtles were marked by attaching a single titanium tag (National Wing Tags, Jiffy 893) to the web of one of the hind feet.

Following the collection of morphometric data (Supplementary File 1, Table S1), turtles were physically examined, and swabs of the oral and cloacal mucosa were collected. Lesion scrapings and swabs were collected successively from cleaned skin lesions using sterile scalpel blades and dry swabs respectively. Lastly, blood samples (0.7–1 mL) were collected from the jugular vein (with 1 mL syringes and 27 G needles) into clean microfuge tubes. All of the samples were transported to the laboratory on ice and stored at  $-80^{\circ}\text{C}$  until required for testing. The blood samples were allowed to clot at room temperature in the field and then centrifuged at 1000 g for 10 min in the laboratory. The resulting sera and clots were then transferred into clean tubes and stored at  $-80^{\circ}\text{C}$ . The oral and cloacal swabs, as well as the blood (sera and clots) samples, were initially pooled according to sample type, species and location for an initial cost-effective screen (Tables 1a, 1b and 1c; Supplementary File 2, Table S2). Finally, total nucleic acids were extracted from individual and pooled samples using the DNeasy Blood and Tissue Kit (Qiagen, Germany) as recommended by the manufacturer.

## Molecular testing for viruses

### Lesion and pooled sample testing for viruses

The lesion and pooled samples were initially tested for herpesviruses (HVs) using a touchdown PCR with a set of consensus primers (AlphaFWD1 and AlphaREV2; Table 1) targeting a 265–277 base pairs (bp) segment of the DNA polymerase gene of the subfamily *Alphaherpesvirinae* (Okoh et al. 2023). A 20  $\mu\text{L}$  reaction mixture containing 2  $\mu\text{L}$  of extracted DNA, 2  $\mu\text{M}$  of each primer, 200  $\mu\text{M}$  dNTPs, 5% DMSO, 45 mM tetramethylammonium chloride (TMAC), 1  $\times$  PCR buffer and 0.5 U HotStarTaq DNA polymerase (Qiagen) was initially denatured at  $95^{\circ}\text{C}$  for 5 min and then cycled 15 times with 1 min of denaturation at  $94^{\circ}\text{C}$ , 1 min of annealing at  $63^{\circ}\text{C}$  with a decrement of  $1^{\circ}\text{C}$  per cycle ( $-1^{\circ}\text{C}/\text{cycle}$ ) and 2 min of extension at  $72^{\circ}\text{C}$ . This was then followed by 35 cycles of  $94^{\circ}\text{C}$  for 1 min,  $48^{\circ}\text{C}$  for 1 min and  $72^{\circ}\text{C}$  for 2 min. After cycling, a final strand extension at  $72^{\circ}\text{C}$  for 10 min was performed and the reaction mixture was held at  $4^{\circ}\text{C}$ . Bovine HV-1 and Gallid HV-2 were used as positive controls. The PCR products were purified using the QIAquick Gel Extraction Kit (Qiagen).

The lesion and pooled samples were also tested for HVs using a nested PCR, which targets a short segment (215–315 bp) of the DNA polymerase gene (VanDevanter et al. 1996) (Supplementary File 2, Table S3). Human HV-2 was used as the positive control in this experiment. The PCR products of selected samples were cloned into pGEM<sup>®</sup>-T Easy Vector (Promega) and transformed in JM109 High Efficiency Competent Cells (Promega). The transformed plasmids were then purified with a Monarch<sup>®</sup> Plasmid Mini-prep kit (NEB) as instructed by the manufacturer.

For the detection of adenoviruses (AdVs), the nested PCR protocol previously described by Wellehan et al. (2004) and modified by Anthony et al. (2013) was used in this study. Briefly, the first-round reaction mixture (20  $\mu\text{L}$  total reaction volume) contained 2  $\mu\text{L}$  of extracted DNA, 1  $\mu\text{M}$  of each external primer (pol/F/outer and pol/R/outer), 400  $\mu\text{M}$  dNTPs, 2.5 mM  $\text{MgCl}_2$ , 2.5 U of HotStarTaq DNA Polymerase (Qiagen), Q-solution and PCR buffer (Qiagen). Amplification of the mixture was then carried out with an initial denaturation at  $95^{\circ}\text{C}$  for 15 min, followed by 14 cycles at  $94^{\circ}\text{C}$  for 30 s,  $63^{\circ}\text{C}$  for 35 s ( $-1^{\circ}\text{C}/\text{cycle}$ ) and  $72^{\circ}\text{C}$  for 60 s. Another 35 cycles at  $94^{\circ}\text{C}$  for 30 s,  $45^{\circ}\text{C}$  for 60 s and  $72^{\circ}\text{C}$  for 60 s were performed with a final strand extension at  $72^{\circ}\text{C}$  for 5 min. For the second-round amplification, 4  $\mu\text{L}$  of the PCR product from the primary reaction was used with the internal primer pair (pol/F/inner and pol/R/inner) and amplified under the same conditions used for the first-round reaction.

Lesion samples were also tested for the presence of papillomavirus and poxvirus using previously described PCR

**Table 1** a. Pooled and individual (lesion) samples from Krefft's turtles

Location collected	Sample type	Pool identifier	Number of individual samples	Number of samples per pool	
Alligator Creek	Oral swab	1	-	28	
	Cloacal swab	2	-	25	
	Lesion swab	-	2	-	
	Lesion scrapings	-	2	-	
	Serum	3	-	9	
	Serum	4	-	8	
	Clot	5	-	9	
	Clot	6	-	8	
	Ross River	Oral swab	7	-	35
		Cloacal swab	8	-	35
Serum		9	-	12	
Clot		10	-	12	
b. Pooled and individual (lesion) samples from saw-shelled turtles					
Location collected					
Alligator Creek	Oral swab	11	-	31	
	Cloacal swab	12	-	32	
	Lesion swab	-	3	-	
	Lesion scrapings	-	3	-	
	Serum	13	-	9	
	Serum	14	-	8	
	Clot	15	-	9	
	Clot	16	-	8	
c. Pooled samples from Krefft's ( <i>Emydura macquarii krefftii</i> ) and saw-shelled ( <i>Myuchelys latisternum</i> ) turtles					
Location collected					
Ross River	Oral swab	17	Krefft's: 33 Saw-shelled: 4	37	
	Cloacal swab	18	Krefft's: 31 Saw-shelled: 4	35	

protocols (Manire et al. 2008; Li et al. 2010; Mashkour et al. 2018) (Supplementary File 2, Table S3).

PCR products and clones were sent for Sanger sequencing (Macrogen, South Korea), and only the products that returned relevant sequence information were considered specific.

### Consensus real-time PCR assay for herpesvirus testing of individual samples

Based on the initial HV testing of pooled samples, a new set of consensus primers (CheHV-F1 and CheHV-R1) and TaqMan probe (CheHV-P; Table 1) were designed (<http://www.oligoarchitect.com>) from the alignment (Geneious 11.1.5) of three novel sequences obtained by Sanger sequencing of the specific PCR products. The assay was designed in a region where it would be specific for the three novel HVs

but would not detect other closely related herpesviruses such as chelonid alphaherpesvirus 5 (ChHV5; *Scutavirus chelonidalpha5*). However, we cannot rule out that it would detect other unknown closely related herpesviruses.

The assay was then used to amplify a 124 bp region of the three novel HVs in individual oral and cloacal swabs, and lesion samples. The optimised TaqMan probe-based PCR reaction was carried out in a 20 µL reaction mixture containing 2 µL of DNA extracts, 0.9 µM of each primer, 0.2 µM of probe and 1 × QuantiTect Probe PCR Master Mix (Qiagen). The mixture was initially denatured at 95 °C for 15 min followed by 45 cycles of denaturation at 94 °C for 15 s, and a combined step of annealing and extension at 60 °C for 60 s. PCR products were sequenced at Macrogen (South Korea), and the resulting nucleotide sequences were aligned and then assigned to the original (novel) sequences based on the

percentage identity score of at least 95% (<https://blast.ncbi.nlm.nih.gov/Blast.cgi>).

### Phylogenetic analysis

De novo assembly of the generated sequences was conducted in Geneious 11.1.5 (<https://www.geneious.com>) and contigs were compared with known sequences in GenBank (National Center for Biotechnology Information, Bethesda, Md.) using BLASTN. Multiple sequence alignment of the translated contigs and representative amino acid sequences available in GenBank was performed using MUSCLE (3.8.425) with the default settings. Bayesian phylogenetic analysis of the amino acid alignment was done with MrBayes plugin v3.2.6 in Geneious (Huelsenbeck and Ronquist 2001). The analysis was performed using a fixed poisson rate matrix, gamma-distributed rate variation, 4 heated chains, subsampling frequency of 200, unconstrained branch lengths and discarding the first 25% of 1,100,000 chains as burn-in (Ossiboff et al. 2015). Phylogenetic analysis was also performed in Molecular Evolutionary Genetics Analysis (MEGA) software using the maximum likelihood (ML) method and the best model of amino acid substitution with 1000 bootstrap replications (Le and Gascuel 2008; Kumar et al. 2018; Tamura et al. 2021).

### Next-generation sequencing

Total DNA of representative HV-positive samples was selected for library preparation and next-generation sequencing (NGS) using Illumina NovaSeq-6000 platform at MacroGen (South Korea). Sequencing reads were trimmed to remove low-quality reads and de novo assembled using the default parameters on CLC Genomics Workbench 22.0.2 (Qiagen). The resulting contigs were compared against the non-redundant protein databases using DIAMOND BLASTX (version 2.0.9). Contigs corresponding to HVs were extracted and subjected to BLASTN analysis to identify false positive hits and frameshifts (due to insertions or deletions). Contig extension was done using ContigExtender (Deng and Delwart 2021). Reads were then mapped to the resulting sequences in Geneious 11.1.5, and the sequence coding regions were identified (annotation) by BLASTX searching of nr database. Phylogenetic analyses (maximum likelihood) were performed on the identified HV sequences.

### Statistical analysis

The disease odds ratio ( $\psi_d$ ) (Thrusfield 2007) was used to determine the association between HV infections and the presence of cutaneous lesions in turtles.

## Results

### Molecular detection of novel viruses

Between August 2020 and May 2021, a total of 311 samples were collected from 128 freshwater turtles in Alligator Creek and Ross River, Townsville. These samples were either tested individually or in pools (Table 2). As shown in Table 3a, one pool of cloacal swabs and 16 individual oral and cloacal swabs from Krefft's turtles in Ross River tested positive for two novel HVs by PCR (Supplementary File 2: Table S4). Six individual oral swabs from a negative pooled sample (initially tested by consensus PCR) tested positive for these novel HVs by real-time PCR (Table 3a), indicating an increased sensitivity. None of the Krefft's turtle samples from Alligator Creek tested positive for any of the HVs. A pool of cloacal swabs from Krefft's turtles obtained from Ross River was positive for a novel AdV by consensus PCR (Table 3a; Supplementary File 2: Table S4). All of the individual lesion samples from Krefft's turtles tested negative for papillomavirus and poxvirus.

Of the pooled samples from saw-shelled turtles in Alligator Creek, the cloacal swab pool was positive for another novel HV (Table 3b; Supplementary File 2: Table S4), and upon further testing of individual swabs from this pool, 3 out of 29 were positive (Table 3b). Three individual oral swabs (3/29) from a pool sample that initially tested negative by consensus PCR were positive for this novel HV by real-time PCR (Table 3b). Two pools of oral and cloacal swabs from saw-shelled turtles were found to be positive for three novel AdVs (Table 3b; Supplementary File 2: Table S4). One lesion (1/3) swab tested positive for HV, and none of the lesion samples was positive for AdV, papillomavirus and poxvirus (Table 3b).

As shown in Table 3c, one pool containing oral swabs from both Krefft's and saw-shelled turtles in Ross River tested positive for one of the novel HVs described in Table 3a. Individual sample testing showed that seven out of the 33 oral swabs of Krefft's turtles were positive, and two out of the four saw-shelled oral swabs tested positive for the novel HVs (Table 3c). Eleven Krefft's turtles (11/34) and all of the saw-shelled cloacal swabs (4/4) tested by real-time PCR were positive for the novel HVs, even though the initial pooled sample source was negative. None of these samples tested positive for AdV.

Overall, three pools, one lesion, 18 oral and 28 cloacal swabs from 39 of the 128 (30%) screened turtles were positive for the novel HVs. Positive results were obtained from 28 of the 95 (29%) Krefft's turtles, and 11 of the 33 (33%) saw-shelled turtles captured (Table 4). In Alligator Creek, seven of the 29 saw-shelled turtles were positive

**Table 2** Primers used in this study

Oligo name	Sense	Sequence (5' to 3')	Position on reference sequence	Accession number of reference sequence	Target virus	Source
AlphaFWD1	Plus	AGCATHATYCAGGBCAYAAAY CTSTGYTTYA	15,732–15,762	NC_028891	Herpesvirus	(Okoh et al. 2023)
AlphaREV2	Minus	TTRATBGCVRVCTGYTGYYTTRTC	15,994–15,972			
DFA	Plus	GAYTTYGCNAGYYTNTAYCC	15,711–15,730			(VanDevanter et al. 1996)
ILK	Plus	TCCTGGACAAGC AGCARNYSGCNMTNAA	15,967–15,994			
KG1	Minus	GTCTTGCTCACC AGNTCNACNCCYTT	16,453–16,428			
TGV	Plus	TGTAACCTCGGTG TAYGGNTTYACNGGNGT	16,002–16,030			
IYG	Minus	CACAGAGTCCGTRTCNCRTADAT	16,238–16,215			
CheHV-F1	Plus	TGGGCAGGGATATGCTTT	307–324	OP076950		This study
CheHV-R1	Minus	TTCATGGAGTAGGGCTGC	433–416			
CheHV-P1	Plus	[6FAM]ACATTCACGCCGCTCTGGT CC[BHQ1]	340–359			
pol/F/outer	Plus	TIMGNGGIGGIMGNTGYTAYCC	5984–5963	NC_009989	Adenovirus	(Wellehan et al. 2004)
pol/R/outer	Minus	GTDGCRAAISHICCRTABARIGMRRT	5429–5454			
pol/F/inner	Plus	GTITWYGAYATHTYGGGHATG TAYGC	5928–5903			
pol/R/inner	Minus	CCAICCBDRTRTRTGIARIGTRA	5608–5630			
Low-GC_PanpoxFWD	Plus	ACACCAAAACTCATATAACTTCT	70,398–70,421	NC_008291	Poxvirus	(Li et al. 2010)
Low-GC_PanpoxREV	Minus	CCTATTTTACTCCTTAGTAAATGAT	70,627–70,603			
High-GC_PanpoxFWD	Plus	CATCCCAAGGAGACCAACGAG	120,218–120,239	NC_008030		
High-GC_PanpoxREV	Minus	TCCTCGTCGCCGTCGAAGTC	120,844–120,825			
AR-E1F2	Plus	ATGGTNCAGTGGGCNTATGA	1672–1691	AY904723	Papillomavirus	(Manire et al. 2008)
AR-E1R9	Minus	CATTWG TDGTDAYMAGSAKRGGVGGGCA	2296–2269			
Cm-Pap-109-F	Plus	GCCGATGATGTCCACTTAT	1207–1225	EU493091.1		(Mashkour et al. 2018)
Chm-Pap-109-R	Minus	GCTGAATCCACAGAGGTAG	1315–1297			

for HVs, while none of the Krefft's turtles tested positive. From Ross River, all of the saw-shelled turtles (4/4) and 28 out of the 67 Krefft's tested positive for HVs. Cutaneous lesions were only seen on 20 turtles (7 Krefft's and 13 saw-shelled turtles) captured from Alligator Creek. Of these 20 saw-shelled turtles, six (30%) tested positive for HVs. Only one of the 37 turtles (21 Krefft's and 16 saw-shelled turtles) without cutaneous lesions tested positive for HV (Table 4). Three pooled samples from saw-shelled turtles (one each of oral and cloacal swabs) and Krefft's turtles (one cloacal swab) were positive for AdVs, and no testing was done to detect AdV in individual samples.

### Statistical analysis

The disease odds ratio ( $\psi_d$ ) applied to this data indicate that there was no association between the occurrence of HVs and cutaneous lesions of freshwater turtles in Alligator Creek (0.7929; 95% CI: 0.1845 to 3.4066).

### Sanger sequencing and phylogenetic analysis

The initial sequencing of the PCR product from the three pooled samples that tested positive for HVs produced relevant sequences of appropriate size (215 bp). These pools included one cloacal swab from Alligator Creek (Table 3b) and two swabs (oral and cloacal; Tables 3a and 3b) from Ross River. A modified second-round nested PCR using primers DFA and IYG (VanDevanter et al. 1996) returned longer DNA polymerase fragments (413–458 bp) for two of these pools (oral and cloacal swabs from Ross River). These DNA polymerase fragments showed 81–90% similarity to each other following sequence alignments. The outputs of BLASTN analyses for the generated sequences are shown in Supplementary File 2, Table S4. The Bayesian phylogenetic analysis based on the amino acid sequences of DNA polymerase revealed three novel HVs, which are placed within the subfamily *Alphaherpesvirinae* and clustered most closely to ChHV5 (YP\_009207091) with a Bayesian posterior

**Table 3** a. PCR results for herpesvirus, adenovirus, papillomavirus and poxvirus of samples from Krefft's turtles collected from Alligator Creek and Ross River

Location collected	Sample type	Pool identifier	<sup>a</sup> Herpesvirus pooled	<sup>b</sup> Herpesvirus individual (positive/tested)	<sup>a</sup> Adenovirus pooled	<sup>a</sup> Papillomavirus individual	<sup>a</sup> Poxvirus individual
Alligator Creek	Oral swab	1	NEG	0/28	NEG	-	-
	Cloacal swab	2	NEG	0/28	NEG	-	-
	Lesion swab	-	-	0/2	NEG	0/2	0/2
	Lesion scrapings	-	-	0/2	NEG	0/2	0/2
	Serum	3	NEG	0/9	NEG	-	-
	Serum	4	NEG	0/8	NEG	-	-
	Clot	5	NEG	0/9	NEG	-	-
	Clot	6	NEG	0/8	NEG	-	-
Ross River	Oral swab	7	NEG	6/34	NEG	-	-
	Cloacal swab	8	POS	10/35	POS	-	-
	Serum	9	NEG	0/12	NEG	-	-
	Clot	10	NEG	0/12	NEG	-	-
b. PCR results of samples from saw-shelled turtles collected from Alligator Creek and tested for herpesvirus, adenovirus, papillomavirus and poxvirus	-	-	-	-	-	-	-
Location collected	Sample type	Pool identifier	<sup>a</sup> Herpesvirus pooled	<sup>b</sup> Herpesvirus individual (positive/tested)	<sup>a</sup> Adenovirus pooled	<sup>a</sup> Papillomavirus individual	<sup>a</sup> Poxvirus individual
Alligator Creek	Oral swab	11	NEG	3/29	POS	-	-
	Cloacal swab	12	POS	3/29	POS	-	-
	Lesion swab	-	-	1/3	NEG	0/3	0/3
	Lesion scrapings	-	-	0/3	NEG	0/3	0/3
	Serum	13	NEG	0/9	NEG	-	-
	Serum	14	NEG	0/8	NEG	-	-
	Clot	15	NEG	0/9	NEG	-	-
	Clot	16	NEG	0/8	NEG	-	-
c. PCR results of samples from Krefft's ( <i>Emydura macquarii krefftii</i> ) and saw-shelled ( <i>Myuchelys latisternum</i> ) turtles collected from Ross River and tested for herpesvirus, adenovirus, papillomavirus and poxvirus	-	-	-	-	-	-	-

**Table 3** (continued)

Location collected	Sample type	Pool identifier	<sup>a</sup> Herpesvirus pooled	<sup>b</sup> Herpesvirus individual (positive/tested)	<sup>a</sup> Adenovirus pooled	<sup>a</sup> Papillomavirus individual	<sup>a</sup> Poxvirus individual
Location collected	Sample type	Pool identifier	<sup>a</sup> Herpesvirus pooled	<sup>b</sup> Herpesvirus individual (positive/tested)	<sup>a</sup> Adenovirus pooled	<sup>a</sup> Papillomavirus individual	<sup>a</sup> Poxvirus individual
Ross River	Oral swab	17	POS	7/33 Krefft's 2/4 saw-shelled	NEG	-	-
	Cloacal swab	18	NEG	11/31 Krefft's 4/4 saw-shelled	NEG	-	-

POS positive, NEG negative

<sup>a</sup>Tested with consensus PCR assay

<sup>b</sup>Tested with real-time PCR assay

probability of 0.67 (Fig. 2a). These viruses were tentatively named chelid herpesvirus 1 (ChelHV-1), chelid herpesvirus 2 (ChelHV-2) and chelid herpesvirus 3 (ChelHV-3) and have been accessioned in GenBank (OP076949-OP076951). Following real-time PCR testing of individual samples and subsequent sequencing by the Sanger method, relevant sequencing data were obtained for 30 of 44 submitted PCR products from 38 turtles. Of these, ChelHV-2 was detected in the oral and cloacal swabs of 22 turtles (2 saw-shelled and 20 Krefft's) while ChelHV-3 was detected in the lesion, oral and cloacal swabs samples of six saw-shelled turtles. Inadequate sequencing data returned for some samples (14 submitted PCR products) made it difficult to assign sequences to ChelHV-1.

For AdV positive pools (two saw-shelled oral and cloacal swabs from Alligator Creek and one Krefft's cloacal swab from Ross River), sequencing of the DNA polymerase PCR amplicons yielded 259 to 314 bp products (after editing sequences). A modified second-round nested PCR of the positive pooled saw-shelled cloacal swab from Alligator Creek using both inner forward and outer reverse primers (Supplementary File 2, Table S4), produced another product (459 bp) that was 100% similar to the sequence obtained for pooled Krefft's turtle cloacal swab from Ross River. Sequence

alignments of all products showed three distinct polymerase sequences with 67–79% similarity to each other. The outputs of BLASTN analyses for the generated sequences are shown in Supplementary File 2, Table S4. Three novel AdVs that clustered with representative members of the genus *Testadenovirus* were identified following an ML phylogenetic analysis based on the amino acid sequence of DNA polymerase gene (Fig. 2b). We have tentatively named these viruses as saw-shelled turtle adenovirus 1 (SsTAdV-1), saw-shelled turtle adenovirus 2 (SsTAdV-2) and saw-shelled turtle adenovirus 3 (SsTAdV-3). These novel sequences have been deposited in GenBank under the accession numbers OL791322, OP076952 and OP076953 respectively.

### Next-generation sequencing of chelid herpesviruses

Next-generation sequencing produced 73,549,106, 71,205,296 and 68,252,498 reads for three libraries constructed from samples with  $C_T$  values of 30.47, 29.65 and 37.58 respectively. All of the sequencing data are available at the NCBI SRA under BioProject PRJNA916530. The trimmed reads were de novo assembled to produce 1,555,961, 1,566,516 and 1,850,721 contigs respectively. A total of 46 contigs (maximum length of 3300 bp) were

**Table 4** Detection of herpesvirus in two populations of freshwater turtles

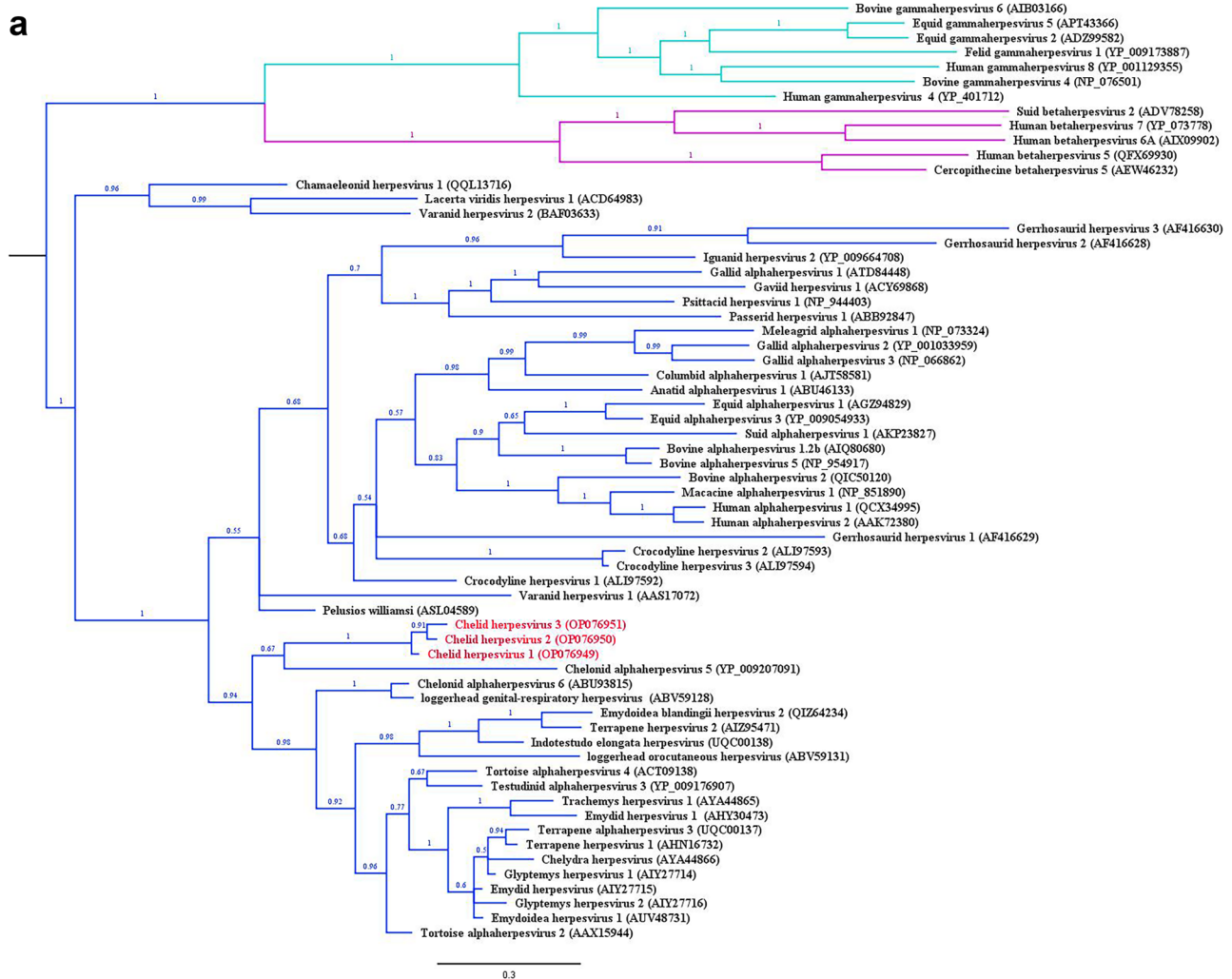
Species	Positive/number tested				Total
	Alligator creek		Ross River		
	Lesion*	No lesion	Lesion	No lesion	
Krefft's	0/7	0/21	0/0	28/67	28/95
Saw-shelled	6/13	1/16	0/0	4/4	11/33
Total	6/20	1/37	0/0	32/71	39/128
Disease odds ratio ( $\psi_d$ )	0.7929 (95% CI: 0.1845 to 3.4066)				

\*A turtle was regarded as positive for "lesions" regardless of whether they had multiple or only one lesion



assigned to the family *Herpesviridae* following blast analysis (DIAMOND BLASTX-2.0.9). These contigs were further subjected to BLASTN analysis to remove false positive hits and identify frameshifts. Consequently, only four contigs from two libraries of ChelHV-2 and ChelHV-3 were considered adequate for read mapping and annotation. The sequences matched different genome fragments (46–54% identity; coverage depth of 1–3x) of ChHV5 (AAR28061.1, YP\_010795529.1, YP\_010795561.1 and YP\_010795506.1), and included the partial sequences of glycoprotein B (gB;

675 bp; OR030823), capsid protein (454 bp; OR030824), helicase-primase primase subunit (602 bp; OR030825) and uracil DNA glycosylase (UDG; 249 bp; OR030826) genes (Supplementary File 2, Table S5). There were no sequences matching the polymerase gene; hence, we could not compare these sequences with the novel sequences of ChelHVs earlier identified in this study. However, phylogenetic analyses based on the amino acid sequences of UDG and gB further confirmed the novelty and relatedness of the ChelHVs to ChHV5 (Supplementary File 2, Fig. S1).



**Fig. 2 a.** Midpoint-rooted Bayesian phylogenetic tree of predicted amino acid sequences of herpesviral DNA-dependent DNA polymerases. Bayesian posterior probabilities are shown next to branches. The analysis involved 64 protein sequences ranging from 58 to 1250 amino acid residues in length. Alpha herpesviruses, beta herpesviruses and gamma herpesviruses are highlighted in blue, pink and green branches respectively. The novel chelid herpesviruses (ChelHV1-3) are shown in red. GenBank accession numbers are shown in parentheses after the virus name. The scale bar indicates the number of amino acid substitutions per site. **b.** Midpoint-rooted maximum likeli-

hood tree (using LG+G model) of predicted amino acid sequences of adenoviral DNA-dependent DNA polymerases. The percentage of trees in which the associated taxa clustered together is shown next to the branches (1000 bootstrap replications). The analysis involved 29 protein sequences (86–1341 amino acid residues in length). The novel adenoviruses are shown in parentheses after the virus name. The tree is drawn to scale, with branch lengths measured in the number of substitutions per site. Evolutionary analyses were conducted in MEGA11

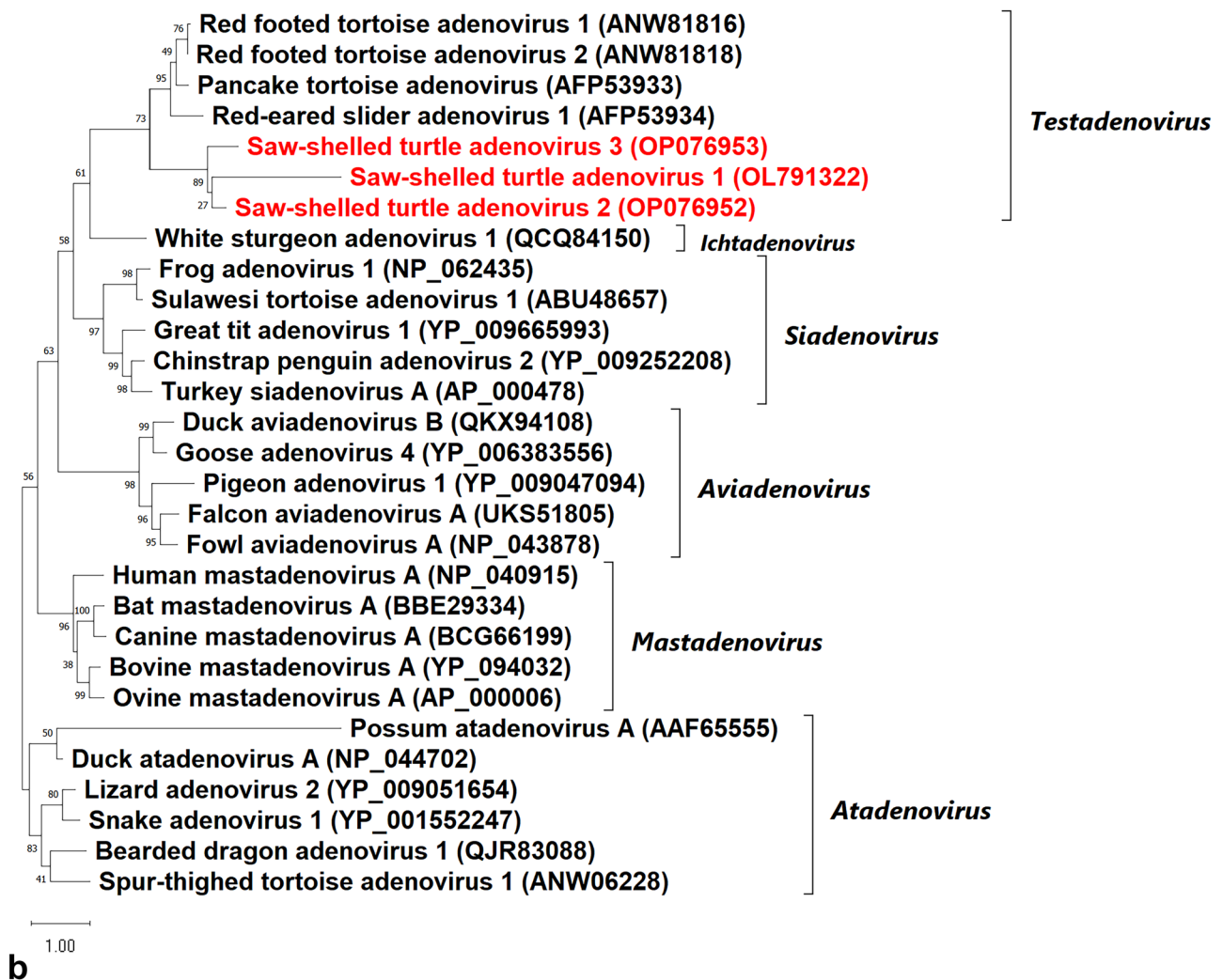


Fig. 2 (continued)

## Discussion

The identification of novel viruses (HVs and AdVs) in wild Australian freshwater turtles is critical to understanding potential threats as well as monitoring disease emergence. In this study, three novel herpesviruses were detected in healthy turtles as well as turtles with cutaneous lesions (apart from the cutaneous lesions seen, no overt clinical signs were observed) using universal PCR assays. Several attempts to identify herpesviruses in Australian freshwater turtles by previous researchers have been unsuccessful (Cowan et al. 2015; Wirth et al. 2020). For instance, Cowan et al. (2015) obtained positive PCR amplicons for HV using a universal PCR assay and demonstrated eosinophilic intranuclear inclusion bodies in the skin lesion tissues of captive Australian Krefft's river turtles. However, they were not able to generate useful

sequence data using Sanger sequencing technology. To the best of our knowledge, the finding in our study represents the first identification and partial characterisation of HV in any species of Australian freshwater turtles.

Interestingly, the novel ChelHVs form a distinct lineage with the tumour-associated ChHV5 that has been detected in the fibropapillomatous lesions of sea turtles (Mashkour et al. 2021; Page-Karjian et al. 2021; Zamana et al. 2021). The ChelHVs also form a clade with other chelonian herpesviruses (Fig. 2a), some of which have been associated with cutaneous lesions. For instance, *Emydoidea herpesvirus 2* and *Terrapene herpesvirus 2*, which share 85% sequence homology with each other, have been associated with squamous cell carcinoma (in a Blanding's turtle) and fibropapillomas (in eastern box turtles) respectively (Andersson et al. 2021; Yonkers et al. 2015). Closely related viral species are most likely to share pathogenic and epidemiologic traits (Gorbalenya and Lauber

2017; Geoghegan and Holmes 2018), thus implicating the ChelHVs as potential factors contributing to the pathogenesis of the cutaneous lesions seen in this study. However, PCR testing indicates that the novel ChelHVs were not associated with the cutaneous lesions, suggesting that the ChelHVs are likely host-adapted pathogens and may not be linked to the disease presentation. Previous studies have discovered HVs in clinically healthy turtles, which further indicates that HVs can cause subclinical or latent infection in adaptive hosts (Aplasca et al. 2019; Ossiboff et al. 2015; Winter et al. 2020). Given that infection of host-adapted HVs in closely related or naïve host species can cause severe disease, it is therefore necessary to further investigate the health implications of these novel ChelHVs in freshwater turtles.

All of the reptilian HVs genetically characterised to date are grouped into the subfamily *Alphaherpesvirinae* (Gatherer et al. 2021; Okoh et al. 2021). The ChelHVs also clustered within this subfamily and formed a distinct clade with ChHV5. The marked lineage variation of ChelHVs from other freshwater turtle HVs is not clearly understood. We can postulate that viruses are known to coevolve with their hosts and most of the previously identified freshwater turtle HVs have been from Cryptodiran turtles, which are genetically and evolutionary different from the Australian species (Pleurodira), and this may have influenced the lineage variation. However, conclusions on the clustering pattern of ChelHVs cannot be drawn in this study as the phylogenetic analysis was based on the partial DNA polymerase sequences of ChelHVs and other reptilian HVs. The availability of full-length sequences would allow for a more adequate or elaborate analysis, which in turn would provide a better insight into the evolutionary history and topology of reptilian HVs.

To further characterise and provide better insights into the molecular and evolutionary genomics of the novel viruses identified in this study, we attempted to sequence the complete or partial genome of ChelHV1-3 directly from clinical samples. Unfortunately, we obtained very low HV genome coverage (1–3x), recovering only four gene fragments for ChelHV-2 and 3. Sequencing non-isolated viruses is often problematic especially if the viruses are present in low amounts (Houldcroft et al. 2017; Maurier et al. 2019). These challenges can be overcome by either performing ultra-deep sequencing or primer walking the genome; however, these approaches are cost and time-intensive (Houldcroft et al. 2017; Maurier et al. 2019) and beyond the scope of this study.

Herpesviruses can cause severe diseases when they infect naïve, young, or immuno-compromised reptile populations (Sehrawat et al. 2018; Okoh et al. 2021). Therefore, a good understanding of the epidemiology of HVs may aid in the prevention and control of disease outbreaks in wild and captive populations. We could not clearly differentiate the individual species of ChelHVs based on their host and location

preferences; however, preliminary results suggest that the ChelHV-3 is host-specific and predominantly infects saw-shelled turtles. ChelHV-1 and 2 were mostly detected in turtles sampled from the Ross River (Supplementary File 1, Table S4). Overall, a prevalence of 30% was recorded for ChelHVs in the two wild populations of freshwater turtles. Slightly higher prevalence rates were observed for saw-shelled (33%) than the Krefft's turtles (29%). The prevalence rates of HVs observed for saw-shelled and Krefft's turtles in this study were similar to the 31.3% reported for terrapene herpesvirus 1 in free-ranging eastern box turtles in the USA (Kane et al. 2017), but lower than the 40% and 51.5% prevalence reported in captive eastern box turtles and free-ranging bog turtles respectively (Ossiboff et al. 2015; Sim et al. 2015). Future investigations should focus on characterising the epidemiology of HVs in Australian freshwater turtles to provide a better understanding of the importance of these viruses to the overall health of their hosts.

Adenoviruses have been detected in many species of reptiles and most commonly infect various species of lizards (Marschang 2011). These viruses are distributed worldwide, and infections are characterised by anorexia, which can lead to lethargy and wasting (Ariel 2011; Marschang 2011; Ascher et al. 2013). Other reported clinical signs include diarrhoea, rhinorrhoea, neurological complications, stomatitis, dermatitis and sudden death (Heldstab and Bestetti 1984; Perkins et al. 2001; Ariel 2011; Marschang 2011; Doneley et al. 2014; Bak et al. 2018). In chelonians, AdVs are associated with severe systemic disease, biliverdinuria, wasting, severe bleeding and mortality (Marschang 2011; Rivera et al. 2009; Schumacher et al. 2012); though, some infections are asymptomatic (Franzen-Klein et al. 2020; Nieto-Claudin et al. 2022; Vincent et al. 2023). Generally, the pathogenicity of AdVs and their ability to cause primary disease is yet to be elucidated as many clinical cases of adenoviral infections in chelonians have been associated with several cofactors such as coinfection, stress and immunosuppression (Adamovicz et al. 2018; Behncke et al. 2013; Farkas and Gál 2009; Garcia-Morante et al. 2016; Gibbons and Steffes 2013; Kim et al. 2002; Marschang 2011; Rivera et al. 2009; Wilkinson 2004). In this current study, three novel AdV species (SsTAdV1-3) were detected in two populations of freshwater turtles. Some turtles in these populations had cutaneous lesions characterised by irregular, contracted, white-tan foci on the dorsal surface of tails, legs and necks. The data obtained in this study does not support SsTAdVs as the causative agent of the cutaneous lesions. This finding is typical of members in the genus *Testadenovirus*, which have so far not been associated with clinical diseases (Doszpoly et al. 2013; Salzmann et al. 2021). However, the occurrence of novel AdVs in this population of freshwater turtles should

not be ignored since AdVs can potentially cause diseases of conservation concerns (Marschang 2011; Marschang et al. 2020). Therefore, there is a need to sustain disease surveillance in this population of freshwater turtles and further characterise the newly discovered viruses (SsTAdV1-3) to ascertain their pathogenicity.

Papillomavirus and poxvirus were not detected in any of the lesion samples tested in this study. Previous studies have identified these viruses as the causative agents of various cutaneous lesions in reptiles (Jacobson et al. 1979, 1982; Huchzermeyer et al. 1991; Penrith et al. 1991). Also, coinfection of these viruses with other pathogens such as HVs may cloud the causative relationship and exacerbate disease presentation (Hughes et al. 2020; Mashkour et al. 2021). Our observation in this study conforms to the findings of Wirth et al. (2020), thus lending support to the exclusion of papillomavirus as a possible cause of the cutaneous lesions. However, it is possible that the limited sensitivity often associated with degenerate PCR protocols may have resulted in the missed diagnosis of the virus in both studies. This assumption may be true for the poxvirus. We further tested for papillomavirus with another assay (Mashkour et al. 2018) and still obtained negative results; though the specificity of this assay to any freshwater turtle papillomavirus (that may be associated with the lesions) was not known. Therefore, the health status of this population of freshwater turtles should be continuously assessed for the presence of potential pathogenic viruses as new and improved assays are developed.

## Conclusions

The discovery of novel viruses in wildlife species is essential in providing insights and identifying potential factors of conservation concerns. Herpesviruses and adenoviruses are clinically important pathogens of wildlife species, though the ecology of disease in some species including reptiles remains uncertain. In this study, we identified and characterised six novel HVs and AdVs in two species of Australian freshwater turtles. Routine surveillance and further characterisation of these novel viruses may help to provide better insights into their epidemiological and conservation significance.

**Supplementary Information** The online version contains supplementary material available at <https://doi.org/10.1007/s10344-023-01714-x>.

**Acknowledgements** The authors would like to thank the JCU turtle health team, Dr. Sara Kophamel, Rebecca Diggins and other volunteers that assisted with field works and sample collection.

**Author contribution** Conceptualization, G. R. O., E. A., D. W. and P. F. H.; methodology, G. R. O., E. A. and P. F. H.; software, G. R. O.; validation, G. R. O. and P. F. H.; formal analysis, G. R. O.; investigation, G. R. O.; resources, P. F. H. and E. A.; data curation, G. R. O.;

writing—original draft preparation, G. R. O.; writing—review and editing, G. R. O., E. A., W. W., D. W. and P. F. H.; visualization, G. R. O.; supervision, E. A., D. W. and P. F. H.; project administration, G. R. O., E. A. and P. F. H.; funding acquisition, G. R. O., E. A., D. W. and P. F. H.

**Funding** Open Access funding enabled and organized by CAUL and its Member Institutions. This research was funded through an Australian Wildlife Society University Student Grant and a JCU Higher Degree Research Enhancement Scheme Grant.

**Data availability** The data presented in this study are openly available in GenBank and NCBI Sequence Read Archive (SRA) databases under accession numbers OP076949, OP076950, OP076951, OL791322, OP076952, OP076953, OR030823, OR030824, OR030825 and OR030826 (GenBank); and PRJNA916530 (SRA).

## Declarations

**Institutional review board statement** Permits (WA0012830) and Ethics approval (A2587) for this study were obtained from the Department of Environment and Science, and James Cook University Animal Ethics Committee respectively.

**Conflict of interest** The authors declare no competing interests.

**Open Access** This article is licensed under a Creative Commons Attribution 4.0 International License, which permits use, sharing, adaptation, distribution and reproduction in any medium or format, as long as you give appropriate credit to the original author(s) and the source, provide a link to the Creative Commons licence, and indicate if changes were made. The images or other third party material in this article are included in the article's Creative Commons licence, unless indicated otherwise in a credit line to the material. If material is not included in the article's Creative Commons licence and your intended use is not permitted by statutory regulation or exceeds the permitted use, you will need to obtain permission directly from the copyright holder. To view a copy of this licence, visit <http://creativecommons.org/licenses/by/4.0/>.

## References

- Adamovicz L, Allender M.C, Archer G, Rzakowska M, Boers K, Phillips C, Driskell E, Kinsel MJ, Chu C (2018) Investigation of multiple mortality events in eastern box turtles (*Terrapene carolina carolina*). *PLoS ONE* 13:e0195617. <https://doi.org/10.1371/journal.pone.0195617>
- Andersson KE, Adamovicz L, Mumm LE, Winter JM, Glowacki G, Teixeira-Neto R, Adkesson MJ, Hostnik ET, Haynes E, Allender MC (2021) Detection of a novel herpesvirus associated with squamous cell carcinoma in a free-ranging Blanding's turtle. *J Vet Diagn Invest* 33:348–351. <https://doi.org/10.1177/1040638721989302>
- Anthony S, Goldstein T, Rejmanek D, Sanchez M, Seimon DT, Fair DJ, Schneider DB, Epstein DJ, Lipkin DI (2013) Laboratory protocols for PREDICT surveillance. PREDICT USAID Columbia University, Version 2:35–36
- Aplasca AC, Titus V, Ossiboff RJ, Murphy L, Seimon TA, Ingerman K, Moser WE, Calle PP, Iv JMS (2019) Health assessment of free-ranging chelonians in an urban section of the Bronx River, New York, USA. *J Wildl Dis* 55:352–362. <https://doi.org/10.7589/2017-12-304>
- Archer GA, Phillips CA, Adamovicz L, Band M, Byrd J, Allender MC (2017) Detection of copathogens in free-ranging Eastern

- box turtles (*Terrapene Carolina Carolina*) in Illinois and Tennessee. *J Zoo Wildl Med* 48(4):1127–1134. <https://doi.org/10.1638/2017-0148r.1>
- Ariel E (2011) Viruses in reptiles. *Vet Res* 42:100. <https://doi.org/10.1186/1297-9716-42-100>
- Ascher JM, Geneva AJ, Ng J, Wyatt JD, Glor RE (2013) Phylogenetic analyses of novel squamate adenovirus sequences in wild-caught Anolis lizards. *PLoS ONE* 8:e60977–e60977. <https://doi.org/10.1371/journal.pone.0060977>
- Australian Bureau of Statistics (2016) 2016 and historical Census data. [https://quickstats.censusdata.abs.gov.au/census\\_services/getproduct/census/2016/quickstat/SSC30040?opendocument](https://quickstats.censusdata.abs.gov.au/census_services/getproduct/census/2016/quickstat/SSC30040?opendocument). Accessed 15 January 2021
- Bak EJ, Jho Y, Woo GH (2018) Detection and phylogenetic analysis of a new adenoviral polymerase gene in reptiles in Korea. *Arch Virol* 163:1663–1669. <https://doi.org/10.1007/s00705-018-3772-3>
- Behncke H, Stöhr AC, Heckers KO, Ball I, Marschang RE (2013) Mass-mortality in green striped tree dragons (*apalura splendida*) associated with multiple viral infections. *Vet Rec* 173:248–248
- Brown GP, Brooks RJ (1993) Sexual and seasonal differences in activity in a northern population of snapping turtles, *Chelydra serpentina*. *Herpetologica* 49:311–318
- Buenviaje GN, Ladds PW, Martin Y (1998) Pathology of skin diseases in crocodiles. *Aust Vet J* 76:357–363. <https://doi.org/10.1111/j.1751-0813.1998.tb12368.x>
- Buhlmann K, Tuberville T, Gibbons JW (2008) *Turtles of the Southeast*, University of Georgia Press.
- Cann J, Sadlier RA (2017) *Freshwater turtles of Australia*. ECO Wear & Publishing.
- Cann J, Spencer RJ, Welsh M, Georges A (2015) *Myuchelys georgesi* (Cann 1997) – Bellinger River turtle. In: Rhodin AGJ, Pritchard PCH, van Dijk PP, Saumure RA, Buhlmann KA, Iverson JB, Mittermeier RA (ed) Conservation biology of freshwater turtles and tortoises: a compilation project of the IUCN/SSC Tortoise and Freshwater Turtle Specialist Group. *Chelonian Res Monogr* 5:1–9. <https://doi.org/https://doi.org/10.3854/crm.5.091.georgesi.v1.2015>
- Cárdenas DM, Cucalón RV, Medina-Magües LG, Jones K, Alemán RA, Alfaro-Núñez A, Cárdenas WB (2019) Fibropapillomatosis in a green sea turtle (*Chelonia mydas*) from the Southeastern Pacific. *J Wildl Dis* 55:169–173. <https://doi.org/10.7589/2017-12-295>
- Chen M, Li D, Fang J, Zhang L, Gu Y, Liu L, Zhang G (2017) Apolipoprotein mediates soft-shelled turtle systemic septicemia spherical virus (STSSSV) infection. *Aquaculture* 473:501–507
- Chiari Y, Cahais V, Galtier N, Delsuc F (2012) Phylogenomic analyses support the position of turtles as the sister group of birds and crocodiles (Archosauria). *BMC Biol* 10:1–15. <https://doi.org/10.1186/1741-7007-10-65>
- Cowan M, Raidal S, Peters A (2015) Herpesvirus in a captive Australian Krefft's river turtle (*Emydura macquarii krefftii*). *Aust Vet J* 93:46–49. <https://doi.org/10.1111/avj.12290>
- Davies PM, Stewart BA (2013) Aquatic biodiversity in the Mediterranean climate rivers of southwestern Australia. *Hydrobiologia* 719:215–235. <https://doi.org/10.1007/s10750-013-1600-z>
- Deng Z, Delwart E (2021) ContigExtender: a new approach to improving de novo sequence assembly for viral metagenomics data. *BMC Bioinformatics* 22:119. <https://doi.org/10.1186/s12859-021-04038-2>
- Doneley R, Buckle K, Hulse L (2014) Adenoviral infection in a collection of juvenile inland bearded dragons (*Pogona vitticeps*). *Aust Vet J* 92:41–45. <https://doi.org/10.1111/avj.12136>
- Doszpoly A, Wellehan JF Jr, Childress AL, Tarján ZL, Kovács ER, Harrach B, Benkő M (2013) Partial characterization of a new adenovirus lineage discovered in testudinoid turtles. *Infect Genet Evol* 17:106–112. <https://doi.org/10.1016/j.meeqid.2013.03.049>
- Farkas SL, Gál J (2009) Adenovirus and mycoplasma infection in an ornate box turtle (*Terrapene ornata ornata*) in Hungary. *Vet Microbiol* 138:169–173. <https://doi.org/10.1016/j.vetmic.2009.03.016>
- Fischer S, Strutzberg-Minder K, Müller G, Homuth M (2006) Molecular biological diagnosis of herpes virus infection of a juvenile Russian tortoise (*Agrionemys horsfieldii*) with skin and lung lesions. *Berl Tierarztl Wschr* 119:28–34
- Franzen-Klein D, Adamovicz L, McRuer D, Carroll SA, Wellehan JFX, Allender MC (2020) Prevalence of box turtle adenovirus in Eastern box turtles (*Terrapene carolina carolina*) presented to a wildlife rehabilitation center in Virginia, USA. *J Zoo Wildl Med* 50:769–777. <https://doi.org/10.1638/2018-0238>
- García-Morante B, Péntez JJ, Costa T, Martorell J, Martínez J (2016) Hyperplastic stomatitis and esophagitis in a tortoise (*Testudo graeca*) associated with an adenovirus infection. *J Vet Diagn Invest* 28:579–583. <https://doi.org/10.1177/1040638716659903>
- Gatherer D, Depledge DP, Hartley CA, Szpara ML, Vaz PK, Benkő M, Brandt CR, Bryant NA, Dastjerdi A, Doszpoly A, Gompels UA, Inoue N, Jarosinski KW, Kaul R, Lacoste V, Norberg P, Oraggi FC, Orton RJ, Pellett PE, Schmid DS, Spatz SJ, Stewart JP, Trimpert J, Waltzek TB, Davison AJ (2021) ICTV Virus taxonomy profile: Herpesviridae 2021. *J Gen Virol* 102:001673. <https://doi.org/10.1099/jgv.0.001673>
- Geoghegan JL, Holmes EC (2018) The phylogenomics of evolving virus virulence. *Nat Rev Genet* 19:756–769. <https://doi.org/10.1038/s41576-018-0055-5>
- Gibbons PM, Steffes ZJ (2013) Emerging infectious diseases of chelonians. *Vet Clin North Am Exot Anim Pract* 16:303–317. <https://doi.org/10.1016/j.cvex.2013.02.004>
- Gorbalenya AE, Lauber C (2017) Phylogeny of viruses. Reference Module in Biomedical Sciences. 2017:B978-0-12-801238-3.95723-4. <https://doi.org/10.1016/B978-0-12-801238-3.95723-4>
- Heldstab A, Bestetti G (1984) Virus associated gastrointestinal diseases in snakes. *J Zoo Anim Med* 15:118–128
- Houldcroft CJ, Beale MA, Breuer J (2017) Clinical and biological insights from viral genome sequencing. *Nat Rev Microbiol* 15:183–192. <https://doi.org/10.1038/nrmicro.2016.182>
- Huchzermeyer FW, Huchzermeyer KD, Putterill JF (1991) Observations on a field outbreak of pox virus infection in young Nile crocodiles (*Crocodylus niloticus*). *J S Afr Vet Assoc* 62:27–29
- Huelsenbeck JP, Ronquist F (2001) MRBAYES: Bayesian inference of phylogenetic trees. *Bioinformatics* 17:754–755. <https://doi.org/10.1093/bioinformatics/17.8.754>
- Hughes CM, Liu L, Davidson WB, Radford KW, Wilkins K, Monroe B, Metcalfe MG, Likafi T, Lushima RS, Kabamba J, Nguete B, Malekani J, Pukuta E, Karhemere S, Muyembe Tamfum JJ, Okitolonda Wemakoy E, Reynolds MG, Schmid DS, McCollum AM (2020) A tale of two viruses: coinfections of monkeypox and varicella zoster virus in the Democratic Republic of Congo. *Am J Trop Med Hyg* 104:604–611. <https://doi.org/10.4269/ajtmh.20-0589>
- Hunt CJ (2006) Herpesvirus outbreak in a group of Mediterranean tortoises (*Testudo* spp). *Vet Clin North Am Exot Anim Pract* 9:569–574. <https://doi.org/10.1016/j.cvex.2006.05.018>
- Jacobson ER, Popp JA, Shields RP, Gaskin JM (1979) Poxlike skin lesions in captive caimans. *J Am Vet Med Assoc* 175:937–940
- Jacobson ER, Gaskin JM, Clubb S, Calderwood MB (1982) Papilloma-like virus infection in Bolivian side-neck turtles. *J Am Vet Med Assoc* 181:1325–1328
- Jacobson ER, Gaskin JM, Roelke M, Greiner EC, Allen J (1986) Conjunctivitis, tracheitis, and pneumonia associated with herpesvirus infection in green sea turtles. *J Am Vet Med Assoc* 189:1020–1023
- Kane LP, Allender MC, Archer G, Dzhaman E, Pauley J, Moore AR, Ruiz MO, Smith RL, Byrd J, Phillips CA (2017) Prevalence of terrapene herpesvirus 1 in free-ranging Eastern box turtles (*Terrapene Carolina Carolina*) in Tennessee and Illinois, USA. *J Wildl Dis* 53:285–295. <https://doi.org/10.7589/2016-06-138>

- Kim DY, Mitchell MA, Bauer RW, Poston R, Cho DY (2002) An outbreak of adenoviral infection in inland bearded dragons (*Pogona vitticeps*) coinfecting with dependovirus and coccidial protozoa (*Isospora* sp.). *J Vet Diagn Invest* 14:332–334. <https://doi.org/10.1177/104063870201400411>
- Kumar S, Stecher G, Li M, Knyaz C, Tamura K (2018) MEGA X: molecular evolutionary genetics analysis across computing platforms. *Mol Biol Evol* 35:1547–1549
- Le SQ, Gascuel O (2008) An improved general amino acid replacement matrix. *Mol Biol Evol* 25:1307–1320. <https://doi.org/10.1093/molbev/msn067>
- Li Y, Meyer H, Zhao H, Damon IK (2010) GC content-based pan-pox universal PCR assays for poxvirus detection. *J Clin Microbiol* 48:1:268–276. <https://doi.org/10.1128/JCM.01697-09>
- Lindemann DM, Allender MC, Thompson D, Adamovicz L, Dzhaman E (2018) Development and validation of a quantitative PCR assay for detection of Emydoidea herpesvirus 1 in free-ranging Blanding's turtles (*Emydoidea blandingii*). *J Virol Methods* 254:40–45. <https://doi.org/10.1016/j.jviromet.2018.01.006>
- Lovich JE, Ennen JR, Agha M, Gibbons JW (2018) Where have all the turtles gone, and why does it matter? *Bioscience* 68:771–781. <https://doi.org/10.1093/biosci/biy095>
- Lyu S, Yuan X, Zhang H, Shi W, Hang X, Liu L, Cao Z, Wu Y (2019) Complete genome sequence and analysis of a new lethal arterivirus, Trionyx sinensis hemorrhagic syndrome virus (TSHSV), amplified from an infected Chinese softshell turtle. *Arch Virol* 164:2593–2597. <https://doi.org/10.1007/s00705-019-04324-8>
- Manire CA, Stacy BA, Kinsel MJ, Daniel HT, Anderson ET, Wellehan JFX (2008) Proliferative dermatitis in a loggerhead turtle, *Caretta caretta*, and a green turtle, *Chelonia mydas*, associated with novel papillomaviruses. *Vet Microbiol* 130:227–237. <https://doi.org/10.1016/j.vetmic.2008.01.013>
- Marschang RE (2011) Viruses Infecting Reptiles *Viruses* 3:2087–2126. <https://doi.org/10.3390/v3112087>
- Marschang R, Heckers K, Heynol V, Weider K, Behncke H (2015) Herpesvirus detection in clinically healthy West African mud turtles (*Pelusioscastaneus*). *Tierarztl Prax Ausg K Kleintiere Heimtiere* 43:166–169
- Marschang RE, Origgi FC, Stenglein MD, Hyndman TH, Wellehan JFX, Jacobson ER (2020) Viruses and viral diseases of reptiles. In: Jacobson ER, Garner MM (eds) *Infectious Diseases and Pathology of Reptiles*, 2nd edn. Color Atlas and Text, Boca Raton, LA, pp. 575–703
- Mashkour N, Maclaine A, Burgess GW, Ariel E (2018) Discovery of an Australian *Chelonia mydas* papillomavirus via green turtle primary cell culture and qPCR. *J Virol Methods* 258:13–23. <https://doi.org/10.1016/j.jviromet.2018.04.004>
- Mashkour N, Jones K, Wirth W, Burgess G, Ariel E (2021) The concurrent detection of chelonid alphaherpesvirus 5 and *Chelonia mydas* papillomavirus 1 in tumoured and non-tumoured green turtles. *Animals* 11:697. <https://doi.org/10.3390/ani11030697>
- Maurier F, Beury D, Fléchon L, Varré JS, Touzet H, Goffard A, Hot D, Caboche S (2019) A complete protocol for whole-genome sequencing of virus from clinical samples: application to coronavirus OC43. *Virology* 531:141–148. <https://doi.org/10.1016/j.virol.2019.03.006>
- Nieto-Claudin A, Esperón F, Apakupakul K, Peña I, Deem SL (2022) Health assessments uncover novel viral sequences in five species of Galapagos tortoises. *Transbound Emerg Dis* 69:e1079–e1089. <https://doi.org/10.1111/tbed.14391>
- Okoh GR, Horwood PF, Whitmore D, Ariel E (2021) Herpesviruses in reptiles. *Front Vet Sci* 8:642894. <https://doi.org/10.3389/fvets.2021.642894>
- Okoh GR, Lockhart M, Grimsey J, Whitmore D, Ariel E, Butler J, Horwood PF (2023) Development of subfamily-based consensus PCR assays for the detection of human and animal herpesviruses. *Eur J Clin Microbiol Infect Dis*. <https://doi.org/10.1007/s10096-023-04605-w>
- Ossiboff RJ, Raphael BL, Ammazalorso AD, Seimon TA, Newton AL, Chang TY, Zarate B, Whitlock AL, McAloose D (2015) Three novel herpesviruses of endangered *Clemmys* and *Glyptemys* turtles. *PLoS ONE* 10:e0122901. <https://doi.org/10.1371/journal.pone.0122901>
- Page-Karjian A, Whitmore L, Stacy BA, Perrault JR, Farrell JA, Shaver DJ, Walker JS, Frandsen HR, Rantonen E, Harms CA, Norton TM, Innis C, Yetsko K, Duffy DJ (2021) Fibropapillomatosis and chelonid alphaherpesvirus 5 infection in Kemp's Ridley sea turtles (*Lepidochelys kempii*). *Animals* 11:3076. <https://doi.org/10.3390/ani11113076>
- Penrith ML, Nesbit JW, Huchzermeyer FW (1991) Pox virus infection in captive juvenile caimans (*Caiman crocodilus fuscus*) in South Africa. *J S Afr Vet Assoc* 62:137–139
- Perkins LEL, Campagnoli RP, Harmon BG, Gregory CR, Steffens WL, Latimer K, Clubb S, Crane M (2001) Detection and confirmation of reptilian adenovirus infection by in situ hybridization. *J Vet Diagn Invest* 13:365–368. <https://doi.org/10.1177/104063870101300418>
- Petrov K, Lewis J, Malkiewicz N, Van Dyke JU, Spencer RJ (2018) Food abundance and diet variation in freshwater turtles from the mid-Murray River, Australia. *Aust J Zool* 66:67–76
- Rebell G, Rywlin A, Haines H (1975) A herpesvirus-type agent associated with skin lesions of green sea turtles in aquaculture. *Am J Vet Res* 36:1221–1224
- Rivera S, Wellehan JF Jr, McManamon R, Innis CJ, Garner MM, Raphael BL, Gregory CR, Latimer KS, Rodriguez CE, Diaz-Figueroa O, Marlar AB, Nyaoke A, Gates AE, Gilbert K, Childress AL, Risatti GR, Frasca S Jr (2009) Systemic adenovirus infection in Sulawesi tortoises (*Indotestudo forsteni*) caused by a novel siadenovirus. *J Vet Diagn Invest* 21:415–426. <https://doi.org/10.1177/104063870902100402>
- Robben DM, Palaniappan P, Loganathan AL, Subbiah VK (2023) Increased prevalence and new evidence of multi-species chelonid herpesvirus 5 (ChHV5) infection in the sea turtles of Mabul Island, Borneo. *Animals (Basel)*, 13. <https://doi.org/10.3390/ani13020290>
- Salzmann E, Müller E, Marschang RE (2021) Detection of testadenoviruses and atadenoviruses in tortoises and turtles in Europe. *J Zoo Wildl Med* 52:223–231. <https://doi.org/10.1638/2020-0078>
- Scheyer TM (2009) Conserved bone microstructure in the shells of long-necked and short-necked chelid turtles (Testudinata, Pleurodira). *Foss Rec* 12:47–57. <https://doi.org/10.1002/mmng.200800009>
- Schumacher VL, Innis CJ, Garner MM, Risatti GR, Nordhausen RW, Gilbert-Marcheterre K, Wellehan JFX, Childress AL, Frasca S (2012) Sulawesi tortoise adenovirus-1 in two impressed tortoises (*Manouria impressa*) and a Burmese star tortoise (*Geochelone platynota*). *Zoo Wildl Med* 43:501–510. <https://doi.org/10.1638/2011-0228R.1>
- Seddon JM, Georges A, Baverstock PR, McCord W (1997) Phylogenetic relationships of chelid turtles (Pleurodira: Chelidae) based on mitochondrial 12S rRNA gene sequence variation. *Mol Phylogenet Evol* 7:55–61. <https://doi.org/10.1006/mpev.1996.0372>
- Sehrawat S, Kumar D, Rouse BT (2018) Herpesviruses: harmonious pathogens but relevant cofactors in other diseases? *Front Cell Infect Microbiol* 8:177. <https://doi.org/10.3389/fcimb.2018.00177>
- Shilton CM, Jerrett IV, Davis S, Walsh S, Benedict S, Isberg SR, Webb GJ, Manolis C, Hyndman TH, Phalen D, Brown GP, Melville L (2016) Diagnostic investigation of new disease syndromes in farmed Australian saltwater crocodiles (*Crocodylus porosus*) reveals associations with herpesviral infection. *J Vet Diagn Invest* 28:279–290. <https://doi.org/10.1177/1040638716642268>
- Sim RR, Norton TM, Bronson E, Allender MC, Stedman N, Childress AL, Wellehan JFX Jr (2015) Identification of a novel herpesvirus in captive Eastern box turtles (*Terrapene carolina carolina*). *Vet*

- Microbiol 175:218–223. <https://doi.org/10.1016/j.vetmic.2014.11.029>
- Sim RR, Allender MC, Crawford LK, Wack AN, Murphy KJ, Mankowski JL, Bronson E (2016) Ranavirus epizootic in captive Eastern box turtles (*Terrapene Carolina Carolina*) with concurrent herpesvirus and mycoplasma infection: management and monitoring. *J Zoo Wildl Med* 47:256–270. <https://doi.org/10.1638/2015-0048.1>
- Široký P, Frye FL, Dvořáková N, Hostovský M, Prokop H, Kulich P (2018) Herpesvirus associated dermal papillomatosis in Williams' mud turtle *Pelusios williamsi* with effects of autogenous vaccine therapy. *J Vet Med Sci* 80:1248–1254. <https://doi.org/10.1292/jvms.18-0126>
- Spencer RJ, Van Dyke J, Petrov K, Ferronato B, McDougall F, Austin M, Keitel C, Georges A (2018) Profiling a possible rapid extinction event in a long-lived species. *Biol Conserv* 221:190–197. <https://doi.org/10.1016/j.biocon.2018.03.009>
- Stacy BA, Wellehan JF, Foley AM, Coberley SS, Herbst LH, Manire CA, Garner MM, Brookins MD, Childress AL, Jacobson ER (2008) Two herpesviruses associated with disease in wild Atlantic loggerhead sea turtles (*Caretta caretta*). *Vet Microbiol* 126:63–73. <https://doi.org/10.1016/j.vetmic.2007.07.002>
- Stöhr AC, Blahak S, Heckers KO, Wiechert J, Behncke H, Mathes K, Günther P, Zwart P, Ball I, Rüschoff B, Marschang RE (2013) Ranavirus infections associated with skin lesions in lizards. *Vet Res* 44:84. <https://doi.org/10.1186/1297-9716-44-84>
- Tamura K, Stecher G, Kumar S (2021) MEGA11: molecular evolutionary genetics analysis version 11. *Mol Biol Evol* 38:3022–3027. <https://doi.org/10.1093/molbev/msab120>
- Thrusfield M (2007) Observation studies. Veterinary epidemiology. Blackwell Science, London.
- Uğurtas IH, Özyiğit MO, Akkoc A, Dorrestein GM, Akkaya A (2008) Cutaneous lesions associated with reo-like virus in a green lizard (*Lacerta viridis* Laurenti 1768). *J Biol Environ Sci* 2:11–14.
- Van Dyke JU, Spencer RJ, Thompson MB, Chessman B, Howard K, Georges A (2019) Conservation implications of turtle declines in Australia's Murray River system. *Sci Rep* 9:1998. <https://doi.org/10.1038/s41598-019-39096-3>
- VanDevanter DR, Warrener P, Bennett L, Schultz ER, Coulter S, Garber RL, Rose TM (1996) Detection and analysis of diverse herpesviral species by consensus primer PCR. *J Clin Microbiol* 34:1666–1671. <https://doi.org/10.1128/JCM.34.7.1666-1671.1996>
- Vincent EC, Fayette MA, Griffioen JA, Litwiler G, Adamovicz L, Ospina E, Allender MC (2023) Health assessment of painted turtles (*Chrysemys Picta*) in a restored wetland habitat in North-western Indiana, USA *J Wildl Dis*. <https://doi.org/10.7589/jwd-d-22-00088.10.7589/jwd-d-22-00088>
- Waltzek TB, Stacy BA, Ossiboff RJ, Stacy NI, Fraser WA, Yan A, Mohan, S, Koonin EV, Wolf YI, Rodrigues TCS, Viadanna PHO, Subramaniam K, Popov VL, Guzman-Vargas V, Shender LA (2022) A novel group of negative-sense RNA viruses associated with epizootics in managed and free-ranging freshwater turtles in Florida, USA. *PLOS Pathogens* 18:e1010258. <https://doi.org/10.1371/journal.ppat.1010258>
- Wellehan JFX, Johnson AJ, Harrach B, Benkö M, Pessier AP, Johnson CM, Garner MM, Childress A, Jacobson ER (2004) Detection and analysis of six lizard adenoviruses by consensus primer PCR provides further evidence of a reptilian origin for the adenoviruses. *J Virol* 78:13366–13369. <https://doi.org/10.1128/JVI.78.23.13366-13369.2004>
- Wilkinson R (2004) Clinical pathology. In *Medicine and Surgery of Tortoises and Turtles* (pp. 141–186). <https://doi.org/10.1002/9780470698877.ch7>
- Winter JM, Mumm L, Adamovicz LA, Andersson KE, Glowacki GA, Allender MC (2020) Characterizing the epidemiology of historic and novel pathogens in Blanding's turtles (*Emydoidea blandingii*). *J Zoo Wildl Med* 51:606–617. <https://doi.org/10.1638/2019-0154>
- Wirth W, Schwarzkopf L, Skerratt LF, Tzamouzaki A, Ariel E (2019) Dose-dependent morbidity of freshwater turtle hatchlings, *Emyura macquarii krefftii*, inoculated with Ranavirus isolate (Bohle iridovirus, Iridoviridae). *J Gen Virol* 100:1431–1441. <https://doi.org/10.1099/jgv.0.001324>
- Wirth W, Elliott E, Rudd D, Hayes L, Maclaine A, Mashkour N, Ahasan S, Gorm Dahl J, Drane K, Ariel E (2020) Cutaneous lesions in freshwater turtles (*Emyura macquarii krefftii* and *Myuchelys latisternum*) in a Rainforest Creek in North Queensland, Australia *Front Vet Sci* 7:33. <https://doi.org/10.3389/fvets.2020.00033>
- Woźniakowski G, Samorek-Salamonowicz E (2015) Animal herpesviruses and their zoonotic potential for cross-species infection. *Ann Agric Environ Med* 22:191–194. <https://doi.org/10.5604/12321966.1152063>
- Yonkers SB, Schneider R, Reavill DR, Archer LL, Childress AL, Wellehan JF Jr (2015) Coinfection with a novel fibropapilloma-associated herpesvirus and a novel *Spirorchis* sp. in an eastern box turtle (*Terrapene carolina*) in Florida. *J Vet Diagn Invest* 27:408–413. <https://doi.org/10.1177/1040638715589612>
- Zamana RR, Gattamorta MA, Cruz Ochoa PF, Navas-Suárez PE, Sacristán C, Rossi S, Grisi-Filho JHH, Silva IS, Matushima ER (2021) High occurrence of chelonid alphaherpesvirus 5 (ChHV5) in green sea turtles *Chelonia mydas* with and without fibropapillomatosis in feeding areas of the São Paulo Coast, Brazil. *J Aquat Anim Health* 33:252–263. <https://doi.org/10.1002/aah.10142>
- Zhang J, Finlaison DS, Frost MJ, Gestier S, Gu X, Hall J, Jenkins C, Parrish K, Read AJ, Srivastava M, Rose K, Kirkland PD (2018) Identification of a novel nidovirus as a potential cause of large scale mortalities in the endangered Bellingier River snapping turtle (*Myuchelys georgesi*). *PLoS One* 13:e0205209. <https://doi.org/10.1371/journal.pone.0205209>

**Publisher's Note** Springer Nature remains neutral with regard to jurisdictional claims in published maps and institutional affiliations.