



Endovascular revascularization of critical limb ischemia: the role of ultrasound-guided popliteal sciatic nerve block for the procedural pain management

Andrea Discalzi¹ · Claudio Maglia¹ · Floriana Nardelli¹ · Andrea Mancini¹ · Denis Rossato¹ · Pierluigi Muratore¹ · Lorenzo Gibello² · Fabio Gobbi³ · Marco Calandri¹

Received: 28 December 2022 / Revised: 7 May 2023 / Accepted: 6 June 2023
© The Author(s), under exclusive licence to European Society of Radiology 2023

Abstract

Objectives To evaluate the impact of the ultrasound-guided popliteal sciatic nerve block (PSNB) for pain management during endovascular treatment of chronic limb-threatening ischemia (CLTI).

Material and Methods From November 2020 to January 2022, 111 CLTI patients that underwent endovascular procedures were prospectively enrolled in this prospective single-arm interventional study. Ultrasound-guided PSNB was used for procedural pain control. Pain intensity was evaluated throughout the procedure (baseline, 10 min after the block, pain peak, and at the end of the procedure) with the visual analog scale (VAS).

Results Forty-six patients underwent above-the-knee revascularization (ATK), 20/111 below-the-knee (BTK) revascularization, 20/111 to both ATK and BTK revascularization. In 25 cases, no endovascular option was feasible at diagnostic angiography. The PSNB was effective in 96% of patients, with no need for further pain management with a statistically significant reduction ($p < 0.0001$) in the mean value of the VAS from 7.86 ± 1.81 (pre-procedural) to 2.04 ± 2.20 after 10 min from the block and up to 0.74 ± 1.43 at the end of the procedure (mean time 43 min). Only 1 complication related to the popliteal sciatic nerve block was registered (a temporary foot drop, completely resolved within 48 h). The time necessary to perform the block ranged between 4 and 10 min.

Conclusion Ultrasound-guided PSNB is a feasible and effective method to manage patients with rest pain and increase comfort and compliance during endovascular procedures.

Clinical relevance statement An ultrasound-guided popliteal sciatic nerve block is a safe, feasible, and effective technique to manage pain during endovascular treatment of chronic limb-threatening ischemia, especially in frail patients with multiple comorbidities who are poor candidates for deep sedoanalgesia or general anesthesia.

Key Points

- Endovascular treatment of CLTI may require long revascularization sessions in patients with high levels of pain at rest, which could be exacerbated during the revascularization procedure.
- The PSNB is routinely used for anesthesia and analgesia during foot and ankle surgery, but the experience with lower limb revascularization procedures is very limited and not included in any international guideline.
- Ultrasound-guided PSNB is a feasible and effective regional anesthesia technique to relieve procedural and resting pain. Because of its safety and availability, every interventional radiologist should know how to perform this type of loco-regional anesthesia.

Keywords Critical limb ischaemia · Intraoperative pain management · Ultrasound-guided regional anesthesia · Popliteal sciatic nerve block · Endovascular treatment

✉ Floriana Nardelli
floriana.nardelli22@gmail.com

¹ Department of Surgical Sciences, Radiology Unit, University of Torino, Via Genova 3, 10126 Turin, Italy

² Department of Surgical Sciences, Division of Vascular Surgery, University of Torino, Turin, Italy

³ Department of Anesthesiology, Ospedale Humanitas Gradenigo, Turin, Italy

Abbreviations

ATK	Above the knee
BTK	Below the knee
CKD	Chronic kidney disease
CLTI	Chronic limb-threatening ischemia
GA	General anesthesia
PAD	Peripheral arterial disease
PSNB	Popliteal sciatic nerve block
VAS	Visual analog scale

Introduction

Peripheral arterial disease (PAD) includes a broad spectrum of clinical conditions of chronic arterial perfusion: from mild claudication to the most advanced stages of chronic limb-threatening ischemia (CLTI). CLTI is defined as the presence of atherosclerotic disease associated with ischemic rest pain or tissue loss (ulceration or gangrene). CLTI often affects patients with multiple comorbidities and it is burdened by a high rate of mortality, limb amputation, pain, and worsening of quality of life [1–4]. The treatment of CLTI is based on limb revascularization with surgical (bypass) or endovascular approach [5]. Endovascular treatment of CLTI may require long revascularization sessions in patients with high levels of pain at rest, which could be exacerbated during the angiographic series and the revascularization maneuvers. The patient's inability to collaborate increases the duration of the procedure, exposes him to greater acquisition of radiographic series with a consequent increase in the dose of radiation and contrast medium delivered and could, in some cases, preclude treatment. Therefore, it is crucial to control and reduce pain with adequate analgesia.

Recent CIRSE Standards of Practice on Below-the-Knee Revascularization [6] suggested intravenous sedation to reduce the pain in patients with rest pain and/or painful wounds until blood flow has been restored. General anesthesia (GA) should be reserved, with the anesthesiology team, for patients unable to cooperate, lay flat, remain immobile, or those unwilling to undergo the procedure without GA. Notably, locoregional anesthesia is not mentioned in the CIRSE Standard of Practice.

Ultrasound-guided popliteal sciatic nerve block (PSNB) [7] has been recently preliminarily proposed in the management of distal leg and forefoot pain as a safer and less invasive way to obtain an adequate analgesia, avoiding the side effects of more invasive approaches such as GA or sedoanalgesia. The potentiality of the ultrasound-guided PSNB is even more relevant in the CLTI setting in the presence of frail patients with multiple comorbidities that make them poor candidates for deep sedoanalgesia or GA. In addition, even if correctly performed, procedural sedation and analgesia may increase morbidity and mortality during the intervention. Therefore

loco-regional anesthesia could play a key role in the management of patients with critical limb ischemia.

The high availability of ultrasound scanners in the angiography suites and the possibility of performing the PSNB immediately before the revascularization procedures directly from the operator represent the main advantages of this technique.

The aim of the study is to evaluate the safety and effectiveness of the PSNB in the perioperative management of ischemic pain in patients undergoing endovascular revascularization.

Material and methods

Patients

This prospective interventional single-arm monocentric study was carried out by the vascular interventional radiology center of a tertiary referral hospital on 111 consecutive patients receiving endovascular treatment for CLTI. From November 2020 to January 2022, patients with CLTI received PSNB in order to relieve ischemic foot pain prior to an endovascular procedure, thus improving patient comfort and preventing unnecessary limb movements during the treatment.

IRB approval was obtained (AC no. 0033871).

Two senior interventional radiologists and two interventional radiology fellows assessed patients before the procedures.

Previous experience of major allergic reactions to local anesthetics agents, history of sensory or motor neurologic deficit in the lower limb, and pregnancy were established as exclusion criteria. Prior to initiation of a sciatic block, all patients received extensive information about signs of local anesthetic toxicity such as circumoral numbness, metallic taste, light-headedness, dizziness, visual and auditory disturbances such as difficulty focusing and tinnitus, disorientation, and drowsiness.

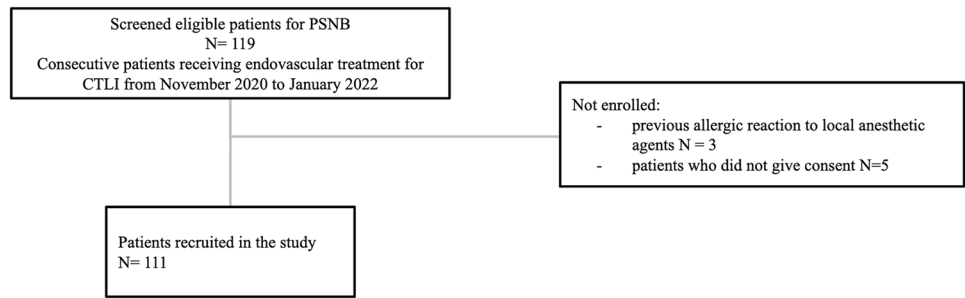
A flow diagram of patient selection and exclusion criteria is available in Fig. 1.

Collected data included stages of CLTI (according to Fontaine and Rutherford classification), cardiovascular risk factors (diabetes, smoking habit, hypertension, chronic kidney disease (CKD)), and the type of surgery performed, whether exclusively diagnostic angiographic examination or whether assisted by endovascular revascularization maneuvers (and in this case the anatomical region involved, above the knee (ATK) or below the knee (BTK)).

Block procedure

Vital signs were monitored with non-invasive blood pressure measurement, continuous ECG tracing, and pulse oximetry. Premedication with anxiolytics was not routinely administered because cooperation with an alert patient was required. Ultrasound-guided PSNB was performed by the

Fig. 1 Flow diagram of patient selection and exclusion criteria



same interventional radiologist or fellow who evaluated the patient before the endovascular procedure.

The PSNB was performed in aseptic conditions, with the patient lying prone or in a lateral position on the angiographic table, by positioning a linear 9–13 MHz ultrasound probe transversely across the popliteal fossa and advancing a 21G 90 mm Quincke-type needle with in-plane approach after recognition of the vascular structures (artery and popliteal vein) and the nerve structures (sciatic nerve) (Fig. 2). The tip of the needle was positioned at the common epineural sheath surrounding the tibial nerve and the common peroneal nerve bifurcation (Vloka’s sheath), distally from the sciatic trunk. Needle tip position was confirmed by tactile feedback, aptly named “fascial pop or click,” as the needle is advanced through

paraneural sheath; and also by observing the separation of tibial and common peroneal nerve trunks upon injection of local anesthetic solution. At this point, 10 ml of a ropivacaine 7.5%, diluted with 10 ml of normal saline, was slowly injected forming an anechoic cuff around the nerves (Fig. 3). The needle tip was repositioned under ultrasound guidance if in the first attempt neural swelling was observed or local anesthetic spread was deemed suboptimal during injection, or if the patient complained of paresthesia. Pain levels were recorded in resting conditions, 10 min after PSNB, at the highest level of pain experienced by the patient during the procedure and at the end of the procedure using a visual analog scale (VAS). Standard endovascular recanalization procedures were performed in accordance with guidelines for the treatment of

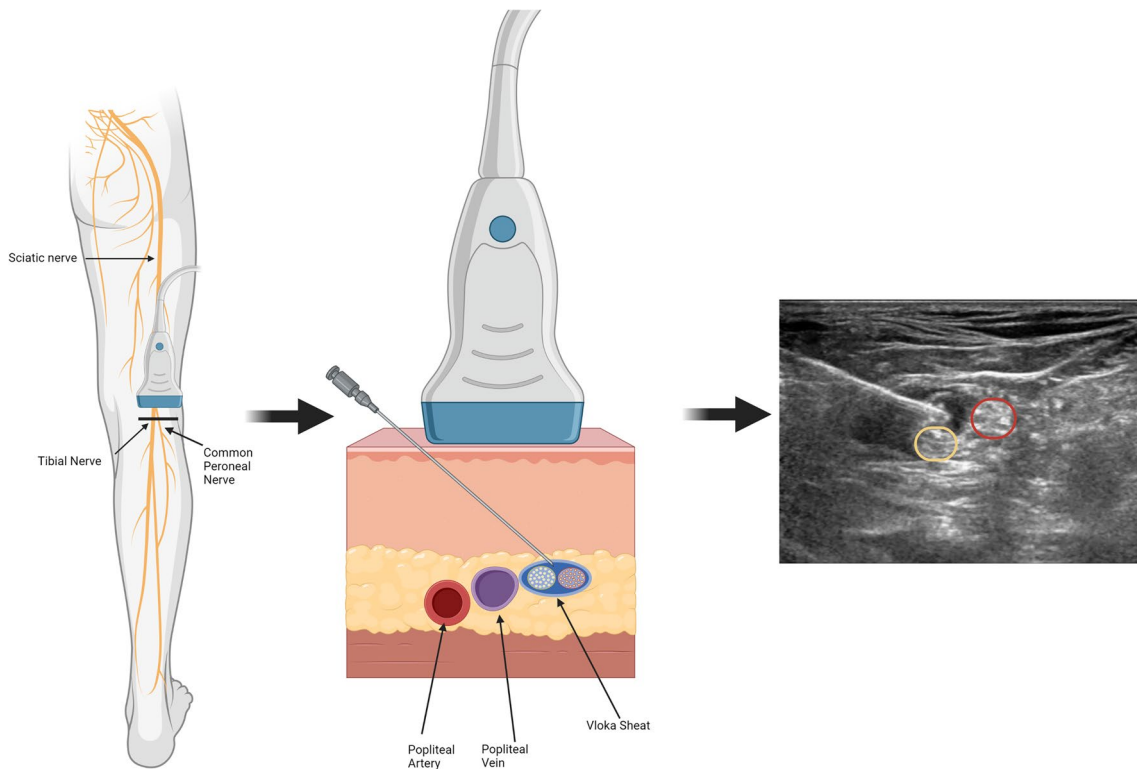


Fig. 2 PSNB technique: linear ultrasound probe position across the popliteal fossa; anatomical details: popliteal artery and vein and sciatic nerve—in-plane approach puncture; needle tip advanced to the

epineural sheath surrounding the tibial nerve (yellow circle) and the common peroneal nerve (red circle) bifurcation

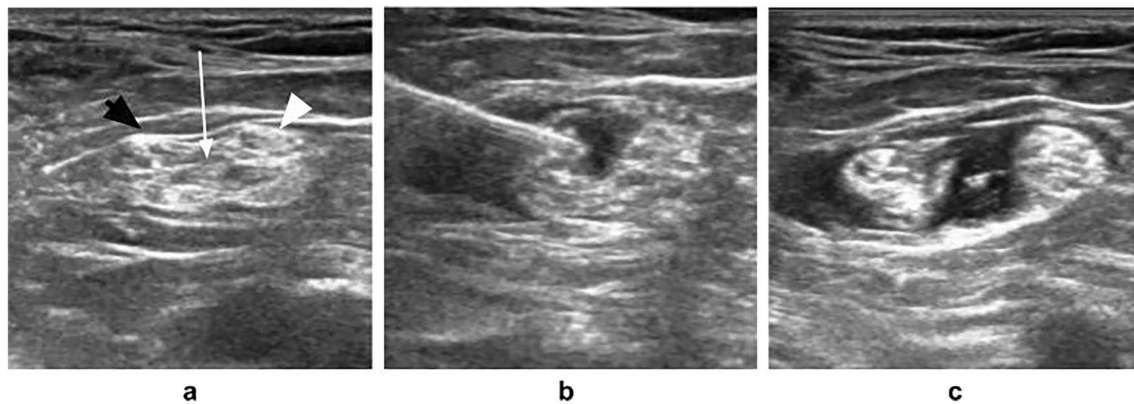


Fig. 3 **a** Correct site for popliteal sciatic nerve block: tibial nerve (black arrowhead) and common peroneal nerve (white arrowhead) distally from sciatic bifurcation. Please note Vioka's sheath (white arrow). **b** Needle tip positioned at the common epineurial sheath sur-

rounding the tibial nerve and the common peroneal nerve bifurcation (Vioka's sheath). **c** Correct anechoic cuff formed by local anesthetic solution around tibial and common peroneal nerve

CLTI. In cases of breakthrough pain, the additional drugs for managing the limb pain administered were recorded.

Statistical analysis

The normality assumption of the data was assessed using the Shapiro–Wilk test. Wilcoxon signed-rank test was calculated to study effectiveness variables pre-post changes in quantitative variables. For independent variables, the Mann–Whitney U test for continuous variables was applied as appropriate. A p value < 0.05 was considered significant for all variables. All the data were analyzed using SPSS software version 26.0 (IBM Corp. SPSS Statistics).

Results

Patients and endovascular procedures

One hundred and eleven patients (39 female, mean age 74.68 ± 10.25 years, range 49–93 years) received an ultrasound-guided PSNB prior to the endovascular procedure. One hundred and two patients were classified as stage IV of Fontaine (or category 5–6 or Rutherford); nine patients were classified as stage III of Fontaine (or category 4 of Rutherford). Sixty-five patients had type 2 diabetes mellitus, 24 were active smokers and 15 were ex-smokers, 100 had arterial hypertension, 49 were affected by dyslipidemia, 44 had CKD with glomerular filtration < 60 mL/min/1.73 m².

The endovascular procedures involved the ATK region in 46 cases, the BTK region in 20 cases, and both ATK and BTK region in 20 cases; in 25 cases a diagnostic angiography was performed with no endovascular interventions because surgical bypass treatment was indicated.

Data regarding cardiovascular risk factors, CLTI stage, and anatomical site of revascularization are shown in Table 2.

Six endovascular procedure-related complications were registered (1 femoral pseudoaneurysm, 1 hematoma of femoral access site, 4 distal embolizations).

PSNB procedure and pain reduction

The PSNB was performed by an expert operator (97 cases) or by an interventional radiology resident supervised by an expert operator (15 cases).

The PSNB was effective in 107/111 (96%) patients without the use of further pain management with a statistically significant reduction ($p < 0.0001$) in the mean value of the VAS from 7.86 ± 1.81 (pre-procedural) to 2.04 ± 2.20 after 10 min from the block and up to 0.74 ± 1.43 at the end of the procedure (mean time 43 min, 95% confidence interval 38.4–49.2 min).

Procedure characteristics and post-block VAS reduction are summarized in Fig. 4 and Table 1.

In the 4 patients where PSNB failed, further pain management for CTLI-related pain was necessary (paracetamol for 2 patients, morphine for 1 patient, fentanyl for 1 patient). VAS score < 5 was registered at the end of the procedure in these patients.

The time to perform the PSNB ranged between 4 and 10 min for both experienced operators and interventional radiology residents with a mean time of 5.20 ± 1.2 min.

In 109 patients, only one needle insertion was needed to perform the nerve block; in the remaining two cases (one performed by an expert IR block and one performed by an IR fellow) a second needle puncture was required due to a non-optimal anesthetic delivery around the sciatic nerve at the first attempt.

Only 1 complication related to the PSNB was recorded: an injury of the external popliteal sciatic nerve, with a temporary foot drop symptom, completely resolved within 48 h.

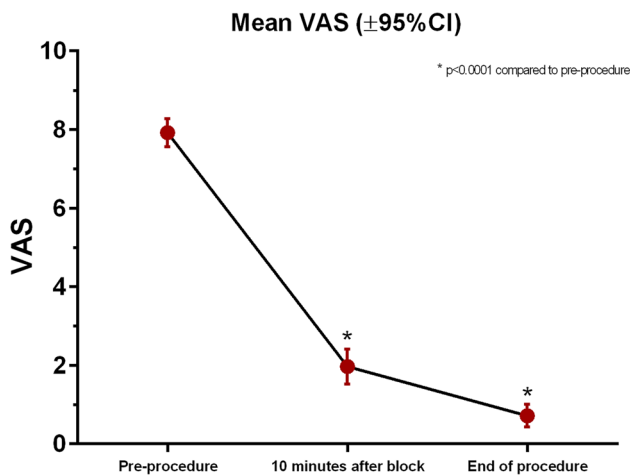


Fig. 4 Mean VAS reduction relative to the time of PSNB

No further complications directly related to the nerve block (infection at the injection site, bleeding, and local anesthetic toxicity) occurred.

No significant differences in pain reduction were found with respect to the stage of CLTI or the anatomic region involved in revascularization procedures. Regarding cardiovascular risk factors, no significant differences were observed in the study population except for the CKD subgroup: a significant reduction of the mean post-procedural VAS was observed in CKD patients (0.34 ± 0.68 in patients with CKD and 1.00 ± 1.71 in non-CKD patients, p -value 0.04).

The impact of the collected data on PSNB outcome is summarized in Table 2.

Discussion

The results of this prospective single-arm interventional study suggest that CLTI procedural pain can be safely and effectively managed by ultrasound-guided PSNB.

Most of the BTK revascularization procedures are performed using local anesthesia at the puncture site but in

patients with rest pain and/or painful wounds unable to cooperate or lay flat, intravenous sedation or GA must be evaluated. This approach is also endorsed by recent CIRSE Standards of Practice on Below-the-Knee Revascularization [6].

However, the prevalence of comorbid conditions (limited physiological reserve, cognitive impairment, and frailty) in patients with CLTI sometimes makes it difficult to administer opioids to this population. [7]

The presence of the anesthesiology team is recommended for critically ill patients with severe cardiovascular comorbidities but, with the shortage of anesthesiologists in many Healthcare systems (exacerbated by the COVID-19 pandemic [8]) non-anesthesia professionals have been increasingly involved in the administration of procedural sedation [6, 9]. Lastly, even if correctly performed, procedural sedation and analgesia may increase the risk of morbidity and mortality during the therapeutic intervention [9].

In this context, loco-regional anesthesia could play a key role in the management of CLTI patients.

The PSNB is routinely used for anesthesia and analgesia during foot and ankle surgery [10] but conversely, the experience of lower limb revascularization procedures is very limited. Consequently, this type of anesthesia was not included in the Recent CIRSE Standards of Practice on BTK revascularisation. Also, SVS and ESVS practice guidelines on the management of CLTI do not mention loco-regional anesthesia regarding pain control.

In 2017, Tureli et al. [7] preliminary reported the potentiality of PSNB during urgent endovascular treatment of CLTI with resting pain. Thirty patients were included in their analysis, reporting a significant VAS pain score reduction to 0 in 26 patients and 1–3 in 4 patients.

Recently in 2022, Danisan et al. [11] demonstrated that subgluteal sciatic nerve block provides a highly effective and safe pain management modality compared to pharmacological therapy in 60 patients undergoing endovascular revascularization of BTK occlusions.

To the best of our knowledge, this is the largest series in the literature evaluating the efficacy of PSNB during lower-limb endovascular procedures.

Table 1 VAS score and endovascular procedure time

	N	Minimum	Maximum	Mean	Std. deviation
Pre-procedural VAS	111	3	10	7.92	1.809
10 min post-block VAS	111	0	8	1.97	2.231
End of procedure VAS	111	0	8	.72	1.427
Block time (min)	111	4	10	5.20	1.201
Expert operator block time (min)	97	4	10	5.18	1.09
Residents block time (min)	15	4	10	5.40	1.63
Endovascular procedure time (min)	111	5	145	43.85	28.589

Table 2 Block efficacy in relation to cardiovascular risk factors, CLTI stage, and anatomical site of revascularization

	<i>N</i> (%)	Mean pre—procedural VAS ± SD	<i>p</i> value VAS PRE	Mean post-procedural VAS ± SD	<i>p</i> value VAS POST
Diabetes	65 (59%)	7.85 ± 1.84	0.893	0.55 ± 1.18	0.139
Non-diabetes	46 (41%)	7.89 ± 1.79		1.00 ± 1.70	
Arterial hypertension	11 (10%)	7.84 ± 1.84		0.73 ± 1.47	
Non-arterial hypertension	100 (90%)	8.09 ± 1.64	0.736	0.82 ± 0.98	0.353
Active + formal-smokers	39 (35%)	7.59 ± 2.21	0.391	0.54 ± 1.02	0.329
Non-smokers or formal-smokers	72 (65%)	8.01 ± 1.63		0.85 ± 1.60	
CKD	44 (40%)	7.75 ± 1.85	0.671	0.34 ± 0.68	0.040
Non-CKD	67 (60%)	7.94 ± 1.80		1.00 ± 1.71	
Fontaine grade 3	9 (8%)	7.56 ± 1.13		1.44 ± 1.74	
Fontaine grade 4	102 (92%)	7.89 ± 1.86	0.374	0.68 ± 1.39	0.079
ATK revascularization	46	7.57 ± 2.01	0.394	0.72 ± 1.10	0.630
BTK revascularization	20	7.65 ± 1.95		0.85 ± 1.87	
ATK + BTK revascularization	20	8.20 ± 1.15		0.50 ± 1.23	
Diagnostic angiography	25	8.32 ± 1.70		0.88 ± 1.74	

Bold emphasis for statistical significance (0.040)

The PSNB was immediately effective as reported by the statistically significant drop in VAS score values from the first 10-min check. The greater than 95% efficacy is similar to that reported by Tureli. According to their experience, also in our population, even not sedated, patients spontaneously fall asleep during endovascular intervention: patients with severe resting limb pain suffer from chronic insomnia and once the pain subsides following PSNB, they tend to sleep from exhaustion.

In the PSNB setting the choice of the administered drug can be challenging. Indeed, endovascular revascularization procedures could be time-consuming (even more than 2 h, as in our study). Therefore, we preferred long-acting (longer than 6 h) amide local anesthetics and specifically Ropivacaine (Naropin, AstraZeneca), which has high safety profile with a selective action on the pain-transmitting nerve fibres: compared with bupivacaine, ropivacaine is equally effective in sensory analgesia in terms of onset, quality, and duration of the sensory block but produces less motor block and has, in addition, a reduced cardiovascular toxicity [12, 13].

Compared to nerve stimulation or classic paraesthesia techniques, ultrasound-guided PSNB requires a smaller volume of local anesthetic [14]; a reasonable block volume for PSNB may be between 10 and 30 ml of Ropivacaine. In our series, according to Jeong et al. [14], 10 ml of local anesthetic for all patients was administered.

According to the literature [15] most common complications of all peripheral nerve blocks include nerve injury, bleeding, infection, and local anesthetic systemic toxicity. Permanent (greater than six months) peripheral nerve injury

is a very rare condition after nerve blocks and is estimated at about 0.09% [15].

In our series, a single case of a transient inability to dorsiflex the ankle, completely resolved in 48 h was observed.

Regarding the data collected on the relationship between PSNB and cardiovascular risk factors, our results are different from what is already found in the literature: in fact, no differences were observed in the efficacy of PSNB between diabetic and nondiabetic patients although studies demonstrating greater block efficacy in diabetic patients are reported in the literature [16]. Conversely, in our series, PSNB seemed to be more effective in patients with chronic kidney disease, a finding that differs from another report in the literature regarding brachial plexus block with ropivacaine [17].

This study has some limitations. Despite being a prospective study, the absence of randomization with a control group may limit the generalization of the findings.

The evaluation of the operator learning curve was not performed; however, the PSNB seems in our experience an easy-to-learn procedure; indeed, the number of puncture attempts and the PSNB procedural time were similar between the experienced radiologists and the fellow. Furthermore, the only one reported complication (“foot drop”) occurred during a procedure performed by a senior operator. The data collected on the relationship between PSNB and cardiovascular risk factors are also discordant with what is reported in the literature: further trials with larger sample sizes are needed to confirm these pieces of evidence and to evaluate sub-groups of patients in whom it may be necessary to vary anesthetic administration in relation to underlying pathology.

Conclusion

In conclusion, ultrasound-guided PSNB is a feasible and effective regional anesthesia technique to relieve procedural and resting pain. Because of its safety and availability, every interventional radiologist should know how to perform this type of loco-regional anesthesia.

Funding The authors state that this work has not received any funding.

Declarations

Guarantor The scientific guarantor of this publication is Professor Paolo Fonio, Head of Department—Radiology Unit, University of Torino—pfonio@unito.it.

Conflict of interest The authors of this manuscript declare no relationships with any companies whose products or services may be related to the subject matter of the article.

Statistics and biometry No complex statistical methods were necessary for this paper.

Informed consent Written informed consent was obtained from all patients in this study. Consent for publication was obtained for every individual person's data included in the study.

All procedures performed in studies involving human participants were in accordance with the ethical standards of the institutional and/or national research committee and with the 1964 Helsinki Declaration and its later amendments or comparable ethical standards.

Ethical approval Institutional Review Board approval was obtained (AC no. 0033871).

Study subjects or cohorts overlap Study subjects or cohorts have not been previously reported.

The preliminary results of the study were presented at Barcellona CIRSE Congress 2022 as an electronic poster.

Methodology

- prospective
- observational study
- performed at one institution

References

1. Fowkes FGR, Rudan D, Rudan I et al (2013) Comparison of global estimates of prevalence and risk factors for peripheral artery disease in 2000 and 2010: a systematic review and analysis. *Lancet* 382:1329–1340. [https://doi.org/10.1016/S0140-6736\(13\)61249-0](https://doi.org/10.1016/S0140-6736(13)61249-0)
2. Conte MS, Bradbury AW, Kolh P et al (2019) Global vascular guidelines on the management of chronic limb-threatening ischemia. *Eur J Vasc Endovasc Surg* 58:S1–S109.e33. <https://doi.org/10.1016/j.ejvs.2019.05.006>
3. Duff S, Mafilios MS, Bhounsule P, Hasegawa JT (2019) The burden of critical limb ischemia: a review of recent literature. *Vasc Health Risk Manag* 15:187–208. <https://doi.org/10.2147/VHRM.S209241>
4. Hardman RL, Jazaeri O, Yi J, Smith M, Gupta R (2014) Overview of classification systems in peripheral artery disease. *Semin Interv Radiol* 31:378–388. <https://doi.org/10.1055/s-0034-1393976>
5. Dominguez A, Bahadorani J, Reeves R, Mahmud E, Patel M (2015) Endovascular therapy for critical limb ischemia. *Expert Rev Cardiovasc Ther* 13:429–444. <https://doi.org/10.1586/14779072.2015.1019472>
6. Spiliopoulos S, Del Giudice C, Manzi M, Reppas L, Rodt T, Uberoi R (2021) CIRSE Standards of Practice on Below-the-Knee Revascularisation. *Cardiovasc Intervent Radiol* 44:1309–1322. <https://doi.org/10.1007/s00270-021-02891-5>
7. Tureli D, Deniz S, Unlukaplan A, Oguzkurt L (2018) Ultrasound-guided popliteal sciatic block provides adequate analgesia during urgent endovascular treatment of critical limb ischemia with resting pain. *Cardiovasc Intervent Radiol* 41:43–48. <https://doi.org/10.1007/s00270-017-1802-2>
8. Simoneaux R (2022) Are We Facing an Anesthesiologist Shortage? *ASA Monit* 86:1–5
9. Romagnoli S, Fanelli F, Barbani F et al (2020) CIRSE Standards of Practice on analgesia and sedation for interventional radiology in adults. *Cardiovasc Intervent Radiol* 43:1251–1260. <https://doi.org/10.1007/s00270-020-02536-z>
10. Karmakar MK, Reina MA, Sivakumar RK, Areeruk P, Pakpirom J, Sala-Blanch X (2021) Ultrasound-guided subparaneural popliteal sciatic nerve block: there is more to it than meets the eyes. *Reg Anesth Pain Med* 46:268–275. <https://doi.org/10.1136/rapm-2020-101709>
11. Danisan G, Taydas O (2022) Ultrasound-guided subgluteal sciatic nerve block for pain management during endovascular treatment for below-the-knee arterial occlusions. *J Vasc Interv Radiol* 33:279–285. <https://doi.org/10.1016/j.jvir.2021.10.018>
12. Hansen TG (2004) Ropivacaine: a pharmacological review. *Expert Rev Neurother* 4:781–791. <https://doi.org/10.1586/14737175.4.5.781>
13. Kaur A, Singh RB, Tripathi RK, Choubey S (2015) Comparison between bupivacaine and ropivacaine in patients undergoing forearm surgeries under axillary brachial plexus block: a prospective randomized study. *J Clin Diagn Res* 9:UC01-06. <https://doi.org/10.7860/JCDR/2015/10556.5446>
14. Jeong JS, Shim JC, Jeong MA, Lee BC, Sung IH (2015) Minimum effective anaesthetic volume of 0.5% ropivacaine for ultrasound-guided popliteal sciatic nerve block in patients undergoing foot and ankle surgery: determination of ED₅₀ and ED₉₅. *Anaesth Intensive Care* 43:92–7. <https://doi.org/10.1177/0310057X1504300114>
15. Sites BD, Taenzer AH, Herrick MD, Gilloon C, Antonakakis J, Richards J et al (2012) Incidence of local anesthetic systemic toxicity and postoperative neurologic symptoms associated with 12,668 ultrasound-guided nerve blocks: an analysis from a prospective clinical registry. *Reg Anesth Pain Med* 37:478–482. <https://doi.org/10.1097/AAP.0b013e31825cb3d6>
16. Baeriswyl M, Taffé P, Kirkham KR, Bathory I, Rancati V, Crevoisier X et al (2018) Comparison of peripheral nerve blockade characteristics between non-diabetic patients and patients suffering from diabetic neuropathy: a prospective cohort study. *Anaesthesia* 73:1110–1117. <https://doi.org/10.1111/anae.14347>
17. Pere P, Salonen M, Jokinen M, Rosenberg PH, Neuvonen PJ, Haasio J (2003) Pharmacokinetics of ropivacaine in uremic and nonuremic patients after axillary brachial plexus block. *Anesth Analg* 96:563–9. table of contents <https://doi.org/10.1097/0000539-200302000-00048>

Publisher's note Springer Nature remains neutral with regard to jurisdictional claims in published maps and institutional affiliations.

Springer Nature or its licensor (e.g. a society or other partner) holds exclusive rights to this article under a publishing agreement with the author(s) or other rightsholder(s); author self-archiving of the accepted manuscript version of this article is solely governed by the terms of such publishing agreement and applicable law.