



P3227 A sinister *Vibrio fluvialis* bacteremia in an elderly gentleman.

Edahayati Ahmad Tajudin (1), Nabilah Ismail (2), Ummu Salamah Faisal (3), Ummu Afeera Zainulabid (4)

(1) Hospital Sultanah Maliha - Langkawi, Kedah (Malaysia), (2) Universiti Sains Malaysia - Kubang Kerian, Kelantan (Malaysia), (3) National Defence University of Malaysia - Sungai Besi, Kuala Lumpur (Malaysia), (4) International Islamic University Malaysia - Kuantan, Pahang (Malaysia)

Background

Vibrio sp. causes gastroenteritis, wound infection and bacteremia in humans after exposure to seawater or contaminated seafood. Human infections caused by *V. fluvialis* are mostly gastroenteritis. Here, we described a sinister case of *V. fluvialis* bacteremia in an elderly gentleman.

Case(s) Description

A 65-year-old male with a history of diabetes mellitus, hypertension, and chronic kidney disease was admitted to the hospital after he sustained multiple fractures following a motor vehicle accident. On day 30 of admission, the patient was noted to be unresponsive and tachypnoeic. Upon assessment, the patient appeared confused, in septic shock, and required high oxygen support. Arterial blood gas showed severe metabolic acidosis. Abdominal examination is normal and per rectal examination shows old maleana. Subsequently, he was intubated for airway protection. His laboratory investigation revealed severe metabolic acidosis, hemoglobin dropped from 8.0 g/dL to 4.4 g/L, white blood cell of $13 \times 10^9/L$, and platelet of $128 \times 10^9/L$. He was found to have acute on chronic kidney disease, with a deranged liver function test. A blood culture was sent to the laboratory immediately. He was started with intravenous ceftriaxone 2g once daily. Urgent OGDS revealed Forrest IIc ulcer at D1/D2 junction. Inotropic support and other supportive measures were commenced. Unfortunately, the patient succumbed to the illness. Blood culture taken prior to the event revealed a *Vibrio* sp. growth, which was subsequently identified as *V. fluvialis* based on biochemical, API 20E test (98.5% identification), and MALDI-TOF (good consistent identification score of 2.25). According to the caretaker, the patient had a history of having mild diarrhea episodes prior to the event, however stool culture was not sent. She volunteered a history of patients taking normal meals, some containing seafood brought by family members throughout the ward stay. Family members were all in good health during the timeline of the event.

Figure 1. *V. fluvialis* on Blood and MacConkey agar

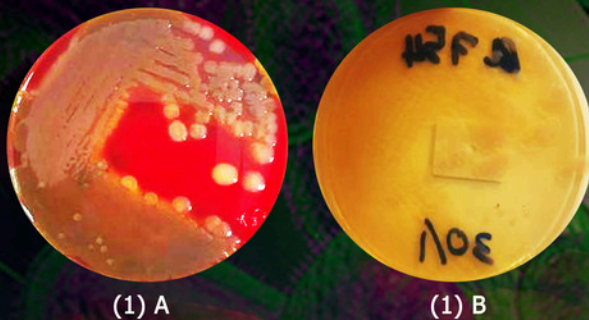


Figure 1. A) *V. fluvialis* colony appearance on blood agar plate after 24 hours; large, opaque β -hemolytic colonies resembling *Acromonas* spp. B) Colony appearance on MacConkey agar, large, round, non-lactose fermenting colonies obtained on MacConkey agar resembling *Aeromonas* spp.

Figure 2. *V. fluvialis* on TCBS agar

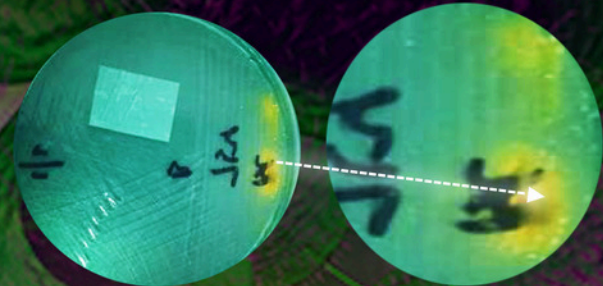


Figure 2. *V. fluvialis* colony appearance on thiosulfate-citrate-bile salts sucrose (TCBS) agar after 24 hours; translucent colonies, yellowish.

Figure 3. API 20E Test

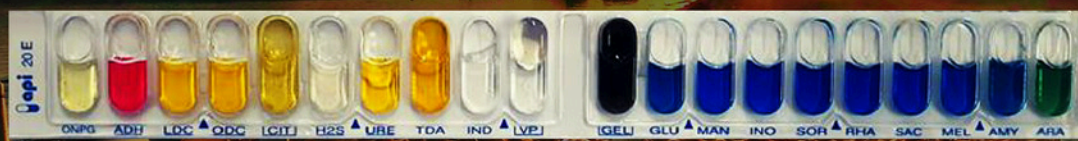

Figure 3. APE 20E test : significant taxa yield *Vibrio fluvialis* with 98.5 identification.

Discussion

The present case described the involvement of duodenal ulceration preceded by diarrhea and subsequent bacteremia caused by *V. fluvialis*, with rapid analysis of cultures and blood proving the culprit. The relative suppressed immunity due to underlying diabetes mellitus and pre-existing chronic kidney disease might also increase the risk of invasive disease.

Fwd: ECCMID 2023 - Your abstract result


eda hayati <edahayati@gmail.com>
To: <ummuafeera@gmail.com>

Mon, 30 Jan at 9:17 PM

----- Forwarded message -----

From: **ECCMID Secretariat** <eccmidinfo@escmid.org>
Date: Mon, 30 Jan 2023 at 8:51 PM
Subject: ECCMID 2023 - Your abstract result
To: <edahayati@gmail.com>

33rd ECCMID **Copenhagen, Denmark**
15–18 April 2023

The congress of  **ESCMID**

Basel, 30/01/2023

Dear Edahayati Ahmad Tajudin,

Thank you for submitting an abstract to the 33rd European Congress of Clinical Microbiology and Infectious Diseases - [ECCMID 2023](#).

Abstract number: 00210

Title: **A sinister *Vibrio fluvialis* bacteraemia in an elderly gentleman**

The ECCMID 2023 Programme Committee is pleased to inform you that your abstract has been accepted for an poster presentation, and allocated to the following session:

Session type: Poster Session

Poster number : P3227

Session title: 13b. Bacterial infections

Session date: 18/04/2023

Session time and location : 12:00 in Poster Area

Due to the hybrid nature of ECCMID 2023, in addition to the paper posters presented onsite, all accepted posters must be uploaded as ePoster to our platform no later than the **1st of April 2023**. You will receive ePoster upload detailed instructions after you complete registration for the congress.

Please make sure to include the provided poster number on the printed and electronic versions of your poster. You will find additional [technical instructions](#) and poster [templates](#) on our website

If you are not the presenting author of this abstract, please forward this notification to the presenting author and inform the Abstract Team at eccmidabstracts@escmid.org.

Please note

- the upcoming ECCMID 2023 will take place in Copenhagen, Denmark, on **15-18 April 2023** as a hybrid event. In addition to onsite presence, the event will be live-streamed online for participants unable to join us in Copenhagen
- the presenting author must register before **1st of April 2023**. Abstracts without a registered presenting author will not be included in the final ECCMID 2023 programme
- if you are unable to attend onsite or online, please inform us about abstract withdrawal before **1st of April 2023**
- early-bird registration is available until the **8th of February 2023**

To register now, please visit the [congress website](#). For any inquiries regarding registration please get in touch with eccmidregistration@escmid.org.

ECCMID 2023 registration includes access to six online-only events that will take place before and after the congress. The [Pre- & Post-ECCMID Days](#) are an integral part of the 2023 scientific programme and will feature the following:

Pre-ECCMID events

- Emerging Public Health challenges - 15th February 2023, 16:00 - 19:00 CET
- Global Health issues post-COVID - 16th February 2023, 16:00 - 19:00 CET
- Controversies in AMS - 15th March 2023, 16:00 - 19:00 CET
- AMR - old problems, new challenges - 16th March 2023, 16:00 - 19:00 CET

Post-ECCMID events

- Viral diseases, just not COVID - 24th May 2023, 16:00 - 19:00 CEST
- Advances in infection diagnosis - 25th May, 16:00 - 19:00 CEST

We congratulate you on the acceptance of your abstract and are looking forward to seeing you in Copenhagen. If you have any questions or need assistance, please contact us at eccmidabstracts@escmid.org.

Yours sincerely,

ECCMID Abstract Team

c/o ESCMID Executive Office

[Gerbergasse 14, 4001 Basel](#)

[Switzerland](#)

Phone +41 61 508 01 59

Email : eccmidabstracts@escmid.org

www.eccmid.org

You received this email because you are the submitter/presenting author of an abstract submitted to ECCMID 2023. If you have any questions in regards to this, please contact the scientific secretariat at: eccmidinfo@escmid.org. Please quote your abstract number in the email subject line.

13. Case reports and case series (n<10)

13b. Bacterial infections

Likely attendance

Onsite

Edahayati Ahmad Tajudin ¹, Nabilah Ismail ², Ummu Salamah Faisal ³, Ummu Afeera Zainulabid ⁴

¹Hospital Sultanah Maliha - Langkawi, Kedah (Malaysia), ²Universiti Sains Malaysia - Kubang Kerian, Kelantan (Malaysia), ³National Defence University of Malaysia - Sungai Besi, Kuala Lumpur (Malaysia), ⁴International Islamic University Malaysia - Kuantan, Pahang (Malaysia)

Background

Vibrio sp. causes gastroenteritis, wound infection, and bacteremia in humans after exposure to seawater or contaminated seafood. Human infections caused by *V. fluvialis* are mostly gastroenteritis. Here, we described a sinister case of *V. fluvialis* bacteremia in an elderly gentleman.

Case(s) description

A 65-year-old male with a history of diabetes mellitus, hypertension, and chronic kidney disease was admitted to the hospital after he sustained multiple fractures following a motor vehicle accident. On day 30 of admission, the patient was noted to be unresponsive and tachypnoeic. Upon assessment, the patient appeared confused, in septic shock, and required high oxygen support. Arterial blood gas showed severe metabolic acidosis. Abdominal examination is normal and per rectal examination shows old maleana. Subsequently, he was intubated for airway protection. His laboratory investigation revealed severe metabolic acidosis, hemoglobin dropped from 8.0 g/dL to 4.4 g/L, white blood cell of $13 \times 10^9/L$, and platelet of $128 \times 10^9/L$. He was found to have acute on chronic kidney disease, with a deranged liver function test. A blood culture was sent to the laboratory immediately. He was started with intravenous ceftriaxone 2g once daily. Urgent OGDS revealed Forrest IIc ulcer at D1/D2 junction. Inotropic support and other supportive measures were commenced. Unfortunately, the patient succumbed to the illness. Blood culture taken prior to the event revealed a *Vibrio sp.* growth, which was subsequently identified as *V. fluvialis* based on biochemical, API 20E test (98.5% identification), and MALDI-TOF (good consistent identification score of 2.25). According to the caretaker, the patient had a history of having mild diarrhea episodes prior to the event, however stool culture was not sent. She volunteered a history of patients taking normal meals, some containing seafood brought by family members throughout the ward stay. Family members were all in good health during the timeline of the event.

Discussion

The present case described the involvement of duodenal ulceration preceded by diarrhea and subsequent bacteremia caused by *V. fluvialis*, with rapid analysis of cultures and blood proving the culprit. The relative suppressed immunity due to underlying diabetes mellitus and pre-existing chronic kidney disease might also increase the risk of invasive disease.

Figure 1. *V. fluvialis* on Blood and MacConkey agar

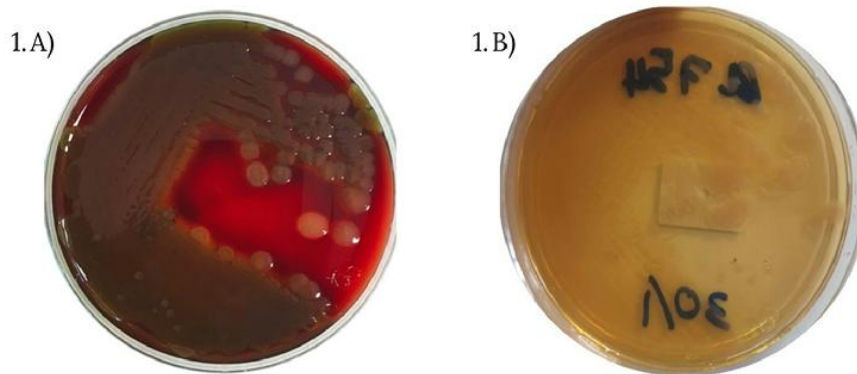


Figure 1. A) *V. fluvialis* colony appearance on blood agar plate after 24 hours; large, round, opaque beta-hemolytic colonies resembling *Aeromonas* spp. **B)** colony appearance on MacConkey agar; large, round, non-lactose fermenting colonies obtained on MacConkey agar resembling *Aeromonas* spp.

Figure 2. *V. fluvialis* on TCBS agar

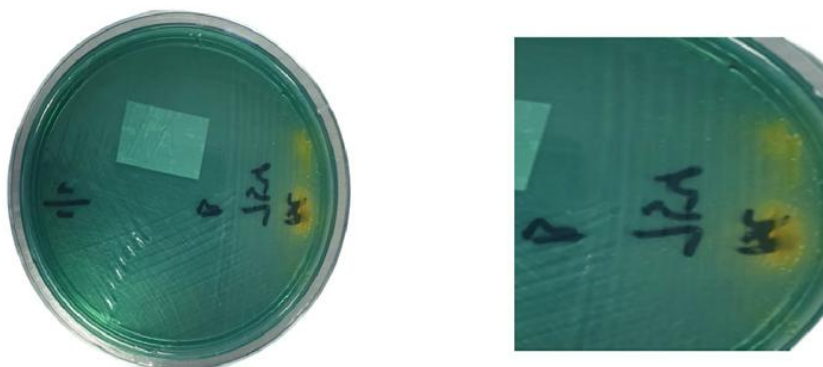


Figure 2. *V. fluvialis* colony appearance on thiosulfate-citrate-bile salts sucrose (TCBS) agar after 24 hours; translucent colonies, yellowish.

Figure 3. API 20E Test

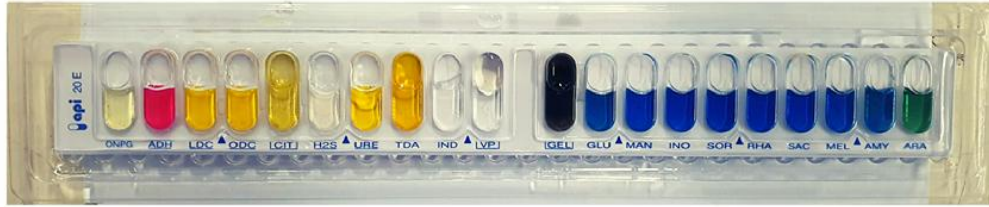

Figure 3. API 20E test : significant taxa yield *Vibrio fluvialis* with 98.5% identification

Keyword 1

Bacteria and bacterial infections

Keyword 2

Sepsis and bloodstream infections

Keyword 3

Vibrio fluvialis

Conflicts of interest

Do you have any conflicts of interest to declare?

No



33rd

ECCMID

Copenhagen, Denmark
15–18 April 2023

ESCMID Executive Office
Gerbergasse 14
4001 Basel
Switzerland
info@escmid.org
www.escmid.org
Phone +41 61 508 01 56

Basel, 28th April 2023

ECCMID 2023 Paper Poster presentation certificate

To whom it may concern:

We hereby confirm that the below abstract was submitted, accepted, and presented during poster session at the 33rd ECCMID (European Congress of Clinical Microbiology and Infectious Diseases), which took place in Copenhagen, Denmark, from 15 – 18 April 2023.

Title: A sinister *Vibrio fluvialis* bacteraemia in an elderly gentleman

Presenting author: Ahmad Tajudin Edahayati

Authors and Affiliation: Edahayati AHMAD TAJUDIN [1], Nabilah ISMAIL [2], Ummu Salamah FAISAL [3], Ummu Afeera ZAINULABID [4] - [1] Hospital Sultanah Maliha, Malaysia, [2] Universiti Sains Malaysia, Malaysia, [3] National Defence University of Malaysia, Malaysia, [4] International Islamic University Malaysia, Malaysia
[1] Hospital Sultanah Maliha, Malaysia, [2] Universiti Sains Malaysia, Malaysia, [3] National Defence University of Malaysia, Malaysia, [4] International Islamic University Malaysia, Malaysia

Session Title: 13b. Bacterial infections

Abstract/ePoster Number: 210/P3227

Sincerely yours,

Jacob Moran-Gilad
ECCMID Programme Director



33rd

ECCMID

Copenhagen, Denmark
15–18 April 2023

ESCMID Executive Office
Gerbergasse 14
4001 Basel
Switzerland
info@escmid.org
www.escmid.org
Phone +41 61 508 01 56

Basel, 28th April 2023

ECCMID 2023 ePoster presentation certificate

To whom it may concern:

We hereby confirm that the below abstract was submitted, accepted, and presented at the 33rd ECCMID (European Congress of Clinical Microbiology and Infectious Diseases), which took place in Copenhagen, Denmark, & online from 15 – 18 April 2023.

ePoster Title: A sinister *Vibrio fluvialis* bacteraemia in an elderly gentleman

Presenting Author: Ahmad Tajudin Edahayati

Authors and Affiliation: Edahayati AHMAD TAJUDIN (1), Nabilah ISMAIL (2), Ummu Salamah FAISAL (3), Ummu Afeera ZAINULABID (4) - (1) Hospital Sultanah Maliha, Malaysia, (2) Universiti Sains Malaysia, Malaysia, (3) National Defence University of Malaysia, Malaysia, (4) International Islamic University Malaysia, Malaysia
(1) Hospital Sultanah Maliha, Malaysia, (2) Universiti Sains Malaysia, Malaysia, (3) National Defence University of Malaysia, Malaysia, (4) International Islamic University Malaysia, Malaysia

Session Title: 13b. Bacterial infections

Abstract/ePoster Number: 210/P3227

Sincerely yours,

Jacob Moran-Gilad
ECCMID Programme Director