



Dermatology Reports

<https://www.pagepress.org/journals/index.php/dr/index>

eISSN 2036-7406



Publisher's Disclaimer. E-publishing ahead of print is increasingly important for the rapid dissemination of science. **Dermatology Reports** is, therefore, E-publishing PDF files of an early version of manuscripts that undergone a regular peer review and have been accepted for publication, but have not been through the copyediting, typesetting, pagination and proofreading processes, which may lead to differences between this version and the final one. The final version of the manuscript will then appear on a regular issue of the journal. E-publishing of this PDF file has been approved by the authors.

Please cite this article as: Restrepo Vanegas LR, Rojas Urrea A, Corredor Torres JM, et al. Septic embolism due to periorbital cellulitis caused by pimple drainage. Dermatol Rep 2023 [Epub Ahead of Print] doi: 10.4081/dr.2023.9779

 © the Author(s), 2023
Licensee [PAGEPress](https://www.pagepress.org/), Italy

Note: The publisher is not responsible for the content or functionality of any supporting information supplied by the authors. Any queries should be directed to the corresponding author for the article.

All claims expressed in this article are solely those of the authors and do not necessarily represent those of their affiliated organizations, or those of the publisher, the editors and the reviewers. Any product that may be evaluated in this article or claim that may be made by its manufacturer is not guaranteed or endorsed by the publisher.

Septic embolism due to periorbital cellulitis caused by pimple drainage

Luis Carlos Restrepo Vanegas^a. Alejandro Rojas Urrea^a. Juan Manuel Corredor Torres^a.
Lorena García Agudelo^b. Luis Carlos Avellaneda Curcho^{b-c}.

^a Emergency Department, Regional Orinoquia Hospital, Yopal- Casanare. Colombia

^b Investigation Department, Regional Orinoquia Hospital, Yopal- Casanare. Colombia

^c Neurosurgery Department, Regional Orinoquia Hospital, Yopal- Casanare. Colombia

Corresponding author: Luis Carlos Avellaneda Curcho.

Neurosurgery, and Investigation Department, Regional Orinoquia Hospital, Calle 15 N 07-95
Manzana L Vía Marginal de la Selva 850001 – Yopal, Colombia

Tel: 6344650

E-mail: LuisCarlosAvellaneda92@gmail.com

Key words: Sepsis, Embolism, Cellulitis, Pimple, Sinus Thrombosis.

Study approval statement: This study protocol was reviewed and approved by research committee of the Orinoquia Regional Hospital.

Consent to publish statement: written informed consent was obtained from participants for publication of the details of their medical case and any accompanying images.

Conflict of Interest Statement: The authors have no conflicts of interest to declare.

Funding: The authors declare that the study was carried out and financed with the authors' own resources. We didn't receive external contributions.

Author Contributions

It is mentioned that all the authors were involved in the bibliographic search, preparation and revision of the manuscript.

Data Availability Statement

All data generated or analyzed during this study are included under the references section of this article. Further inquiries can be directed to the corresponding author.

Abstract

At some point in everyone's life homemade pimple drainage has been part of the routine, especially in the early years of adult life and teenagers' days. However, pimple drainage has its special considerations as a mild medical procedure most of the time, even more in patients with serious skin diseases. Even when it is rare to see these kinds of clinical cases in daily medical practice, here we present the case of a 22 years-old female who made (as usual) a home pimple drainage that ended up in periorbital cellulitis and septic embolism. This case highlights the importance of early recognition and appropriate management of periorbital cellulitis to prevent the development of septic embolism.

Introduction

Periorbital cellulitis is an infection of the eyelid and adjacent tissues that, if not properly identified and treated, can cause serious morbidity ¹. Periorbital cellulitis is often a localized infection; however, it can very infrequently lead to serious consequences including septic embolism ^{2,3}. When infectious material travels through the bloodstream and settles in distant organs or tissues, it can cause septic embolism, which can lead to localized infections or abscesses. It is a rare but potentially fatal illness when periorbital cellulitis develops into a septic embolism. Here we present the first case of a woman who suffered some serious complications after nasal pimple drainage.

Case Report

A 22-year-old female arrived at the emergency room referring to a 7-day history of the left side of the face swelling and erythema associated with headache. On physical examination, these were evidenced, and occipital pain palpation was also present. Visual acuity was within normal limits, and extraocular movements were intact. As additional information, the patient referred to non-quantified fever, asthenia, and adynamic. The remainder of the physical examination was unremarkable. The patient refers to the symptoms that started after removing a pimple at the nasal septum. Considering a local infection, an ultrasonography and routine labs were requested to assess the presence of collections.

On the second day, the patient's symptoms worsened with bilateral periorbital edema and more intense headache with nausea and vomiting. As well, left jaw pain was associated. The CT-Scan and renal function were normal, however, the hemogram showed a mild leukocytosis and neutrophilia but the ultrasonography showed an increased echogenicity of the subcutaneous tissue, with the presence of fluid bands without evidence of collections. We considered periorbital cellulitis with a high risk of cavernous sinus septum thrombosis, so we initiated broad-spectrum antibiotic. (Figure 1)

On the third day, the patient suffered from hypotension and swelling worsening, fever, chills, vertigo, and gait disturbances were presented. Blood cultures showed a gram-positive coccobacillus on the preliminary report. On the neck Ct-Scan, we discovered a fat collection near the left masseter, due to the worsening the patient was diagnosed with Sepsis with a periorbital focus and coccobacillus bacteremia, so antibiotics were adjusted and escalated.

On the 4th day the patient presented pleuritic chest pain and oxygen levels below the average, so we initiated supplementary oxygen, we ran a Thorax CT-Scan that showed pulmonary findings compatible with an evolving infectious process, septic pulmonary embolisms not ruled out as the first etiology and mediastinal nodes of reactive appearance were evidenced as well as pleural effusion. Blood cultures indicated a *Staphylococcus aureus* infection. Antibiotics were adjusted. Thoracentesis was not made due to an absence of interventional radiology in our institution.

On the 5th day, the patient was with a neck mass, swallowed, with tenderness, erythema, and limited mouth opening. It was considered a right neck abscess without surgical indications according to the surgery department.

Due to the torpid evolution considering alteration of the sleep pattern, poor pain modulation, the persistence of the infectious picture, and adjacent lesions in the jaw and neck. Brain resonance was requested, which showed findings of thrombophlebitis in the right cavernous sinus, findings linked to partial thrombosis in the transverse/sigmoid sinuses and internal jugular vein on the right side, optic sheath ectasia indicating endocranial hypertension, right mumps, right masticatory compartment myositis, right otomastoiditis, and chronic sinusopathy. Neck Resonance showed thrombophlebitis in the right hemi-neck with superficial and deep venous involvement. The neurological physical exam was normal. Anticoagulant therapy was initiated.

On the 12th day, the face edema was resolving, and the routine labs were with a leucocyte count reduction but with platelets increment. The next day the patient was transferred to a more complex unit to be evaluated for head and neck surgery and vascular surgery due to compromise evidenced in the resonances.

After 30 days the patient returned to our institution to finalize antibiotic therapy, facial erythema, and edema resolved, extra-institutionally a single pulmonary nodule was found without systemic-related symptoms. Urinary tract infection and pyelonephritis due to *Klebsiella pneumoniae* were reported on the urinary analysis. The patient completed in-hospital antibiotic therapy without any complications.

Discussion

Septic embolism is a rare but serious complication that can arise from periorbital cellulitis, with the potential for significant morbidity and mortality ^{4,5}. This case report highlights the importance of recognizing and managing this uncommon but potentially life-threatening condition.

In our case, the patient initially presented with typical signs and symptoms of periorbital cellulitis, including periorbital swelling, erythema, and pain. These findings prompted the initiation of empirical antibiotic therapy. However, despite the appropriate initial treatment, the patient's clinical status worsened. These alarming signs lead to further investigation including radiological images that showed the intracranial and perilesional compromise.

A septic embolism occurs when infected material from a local infection, such as periorbital cellulitis, enters the bloodstream and disseminates to distant sites, resulting in localized infections or abscesses ^{1,3,5}. The emboli can reach various organs, including the lungs, brain, and heart, leading to serious complications ^{2,6,7}. In our case, the patient had a sinus thrombosis due to pimple drainage localization.

Prompt recognition and appropriate management of periorbital cellulitis are crucial to prevent the development of septic embolism. Early initiation of empirical antibiotic therapy targeting the common causative pathogens, such as *Staphylococcus aureus* and *Streptococcus* species, is essential. However, in cases where there is no response to initial treatment or signs of clinical deterioration, a thorough evaluation for complications, including septic embolism, should be pursued.

A multidisciplinary approach should be made, in our case, vascular surgery was included considering the referred complication, as well, as head and neck surgery, internal medicine, and infectiology among other medical specialties were included for the patient's well-being.

Some limitations of our case include its retrospective nature and the lack of a large sample size. Further research and larger studies are warranted to better understand the incidence, risk factors, and optimal management strategies for septic embolism secondary to periorbital cellulitis due to pimple drainage.

Conclusions

Literature regarding pulmonary embolism and cellulitis after pimple drainage is very scarce. There is a lack of information on incidence and complications due to bad drainage techniques and immunological systems. According to the available literature and the presented case, we acknowledge that routine laboratories, images, and clinical expertise are essential to early detect complications and give the best medical and surgical approach. More literature is needed to establish gold-standard management. Also, public health campaigns should be taken ahead to avoid homemade procedures with specific pimples or skin infections.

References

1. Georgakopoulos CD, Eliopoulou MI, Stasinou S, Exarchou A, Pharmakakis N, Varvarigou A. Periorbital and orbital cellulitis: A 10-year review of hospitalized children. *Eur J Ophthalmol* 2010;20(6):1066–72.
2. Branson S V., McClintic E, Yeatts RP. Septic Cavernous Sinus Thrombosis Associated with Orbital Cellulitis: A Report of 6 Cases and Review of Literature. *Ophthalm Plast Reconstr Surg* 2019;35(3):272–80.
3. Bae C, Bourget D. Periorbital Cellulitis. *StatPearls* 2022;
4. Stawicki S, Firstenberg M, Lyaker M, Russell S, Evans D, Bergese S, et al. Septic embolism in the intensive care unit. *Int J Crit Illn Inj Sci* 2013;3(1):58.
5. Lee S, Yen MT. Management of preseptal and orbital cellulitis. *Saudi J Ophthalmol* 2011;25(1):21–9.
6. Cendani Goller AA, Tini K. Cavernous Sinus Thrombosis as Complications of Cellulitis Orbital: Case Report. *Int J Res Rev* 2021;8(10):248–51.
7. Aloua R, Kerdoud O, Slimani F. Cavernous Sinus Thrombosis related to Orbital Cellulitis Serious Complication to Prevent: a case report and literature review. *Ann Med Surg* 2021;62:179–81.

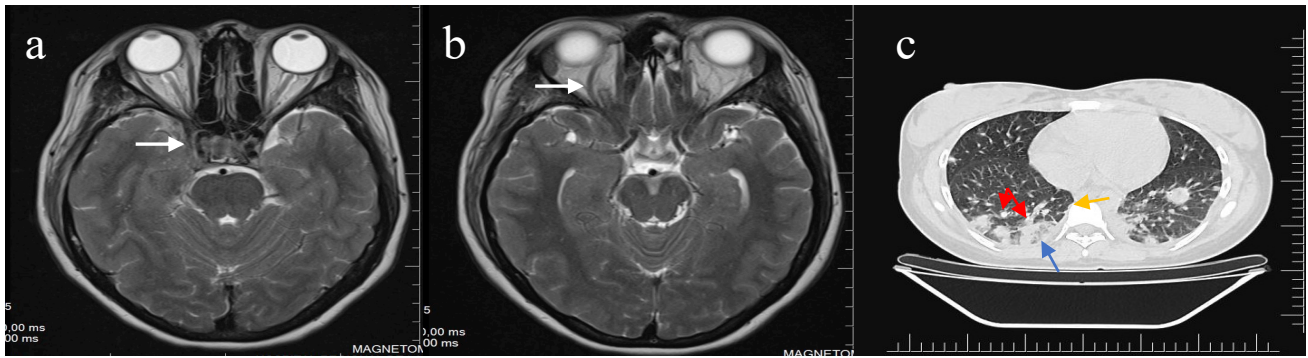


Figure 1 shows a) MRI without contrast in axial slices at the level of the middle fossa, the white arrow shows an increase in the diameter of the right cavernous sinus, which also shows signal alteration predominantly hyperintense on T2 around of the ICA. b) The white arrow shows an increased flow at the level of the superior ophthalmic artery. c) Show images of a Lung CT scan without contrast in axial slices in the parenchyma window. the arrow blue shows multiple consolidative processes at the peripheral level that predominate on the right side, additionally, we can observe multiple adjacent noddles, which converge whit the consolidative zones (red arrow). the orange arrow shows little reactive adenopathies at the level lateral of the trachea.

Table 1.

Laboratory studies								
	27/04/23	29/04/23	1/5/2023	3/5/2023	5/5/2023	7/5/2023	7/5/2023	3/6/2023
	Hemogram							
Leukocytes	14.47 * 10 ³ /mm ³	17.95* 10 ³ /mm ³	19.98* 10 ³ /mm ³	23.42* 10 ³ /mm ³	25.21* 10 ³ /mm ³	16.75* 10 ³ /mm ³	12.74* 10 ³ /mm ³	9.26 * 10 ³ /mm ³
Neutrophils	92%	84.90%	72.00%	81.00%	82.00%	74.90%	63.40%	79.70%
Lymphocytes	2.10%	11.10%	17.00%	13.90%	12.00%	17.80%	31.40%	16.30%
Monocytes	3%	3.50%	1.00%	4.10%	3.00%	6.20%	4.00%	2.20%
Hemoglobine	13 mg/dL	10.7 mg/dL	11.5 mg/dL	10.9 mg/dL	9.6 mg/dL	9.2 mg/dL	10.1 mg/dL	11.8 mg/dL
Hematocrit	37.80%	32.20%	34.40%	33.20%	29.30%	28.70%	32.60%	35.40%
Platelets	245 * 10 ³ /mm ³	173* 10 ³ /mm ³	150* 10 ³ /mm ³	356* 10 ³ /mm ³	625* 10 ³ /mm ³	776* 10 ³ /mm ³	878* 10 ³ /mm ³	313* 10 ³ /mm ³
CRP	-	192 mg/dL	-	-	-	-	-	6 mg/dL