

Methadone Maintenance Therapy after Aneurysmal Subarachnoid Hemorrhage: A Case Report

Austin Smith¹ | Aaron Cook^{2,3} | Kevin Hatton⁴

¹College of Medicine, University of Kentucky

²2UKHealthcare, Pharmacy Services

³Department of Pharmacy Practice and Science, College of Pharmacy, University of Kentucky

⁴Division of Critical Care Medicine, Department of Anesthesiology, University of Kentucky

Correspondence

Kevin Hatton

Email: kwhatt2@uky.edu

Publication Date

March 24, 2023

MJM 2023 (21) 1

<https://doi.org/10.26443/mjm.v21i1.933>



www.mjmmed.com



This work is licensed under a Creative Commons BY-NC-SA 4.0 International License.

ABSTRACT

There is limited information on the effects of continued methadone maintenance therapy (MMT) following aneurysmal subarachnoid hemorrhage (aSAH). However, with the increasing incidence of opioid use disorder (OUD) in the US, there is a need to define best practices for the management of pain and prevention of acute withdrawal syndrome in patients with pre-existing OUD who develop aSAH. In this case report, we describe the use of MMT in a patient with aSAH and discuss important considerations, including sedation or confusion that might mimic acute neurologic changes seen in cerebral vasospasm or delayed cerebral ischemia, cardiac complications related to QTc prolongation, and liver or kidney interactions associated with aSAH routine treatment. Our patient recovered from her aSAH without any adverse events and, with increased monitoring and collaborative team-based care including input from those with expertise in OUD or aSAH, we believe MMT can be safely continued in most aSAH patients.

LEARNING POINTS

- Methadone maintenance therapy (MMT) may cause sedation that mimics the acute neurologic changes seen in cerebral vasospasm, a severe complication of aneurysmal subarachnoid hemorrhage (aSAH).
- Sedation can be differentiated from acute neurologic changes due to aSAH complications by the absence of radiologic or angiographic changes on computed tomography (CT) or digital subtraction angiography (DSA) and by the reversal of sedative effects when sedative agents are discontinued or when specific sedative antagonists (e.g. naloxone for opioids) are administered.
- Both aSAH and MMT may increase the QTc interval. This combination may therefore significantly increase the risk of QTc prolongation and Torsades de Pointes. Continuous EKG monitoring is recommended during the first few days of MMT in aSAH patients.

KEYWORDS

Subarachnoid hemorrhage, Opioid withdrawal syndrome, Prolonged QTc syndrome

- Methadone is primarily metabolized by CYP2B6, a CYP450 family enzyme, and may significantly alter the metabolism of some medications. Although most medications traditionally used in aSAH care are not affected, pharmacy consultation is recommended in aSAH patients who undergo continuation of their MMT after aSAH.

1 | INTRODUCTION

Opioid use disorder (OUD) is an important public-health problem, affecting over 15 million people worldwide and over 2 million in the United States alone. (1) Methadone, a long-acting mu-receptor agonist, is sometimes used in patients with OUD as an oral opioid replacement for heroin, fentanyl or other intravenously-injected illicit opioids. Daily methadone maintenance therapy (MMT), prescribed and overseen by an approved methadone clinic, has been associated with reduced symptoms of drug withdrawal, drug craving, and relapse compared to opioid abstinence alone. It has also been associated with a reduced risk of viral or bacterial bloodstream infection and illegal drug and money-seeking behaviors compared to continued intravenous illicit opioid use. (2)

Aneurysmal subarachnoid hemorrhage (aSAH) is a devastating form of hemorrhagic stroke, resulting from acute rupture of an intracranial aneurysm, that causes a significant risk of mortality and long-term neurologic disability. (3) Approximately 1% of aSAH patients will also have a diagnosis of OUD at the time of their aneurysm rupture and may be receiving MMT as a part of their OUD treatment. (4) The safety and efficacy of MMT after aSAH is unknown. In this case report, we describe a patient with a history of MMT in the setting of OUD who developed aSAH. We also highlight potential complications of MMT in aSAH patients and provide recommendations for continuing MMT in aSAH patients.

2 | CASE DESCRIPTION

A 32-year-old female presented to hospital with acute onset of severe headache and lethargy shortly after awakening. A non-contrast computed tomography (CT) scan of her head demonstrated diffuse subarachnoid hemorrhage (SAH). The patient was placed on a nicardipine infusion to reduce her blood pressure and was transferred to our hospital. On arrival, she underwent a repeat non-contrast CT of the head and CT angiography (CTA) of the head and neck. These scans revealed diffuse SAH, an 8mm right posterior inferior cerebellar artery (PICA) aneurysm, and moderate hydrocephalus. On examination, she was lethargic with a Glasgow Coma Score =13 (Eye=3, Motor=6, Verbal=3) and Hunt and Hess Score = 3. Her medical history was significant for recent pregnancy, daily MMT, and a remote history of intravenous opioid use more than 1 year prior to aneurysm rupture. Unfortunately, more detail regarding her MMT, OUD, and other medication history was not obtainable from the patient at that time.

Due to worsening lethargy, she was intubated for airway protection and an extraventricular drain (EVD) was placed. Propofol and hydromorphone infusions were initiated for sedation and analgesia, respectively. The hydromorphone infusion was also used to prevent opioid withdrawal symptoms (OWS) until more details about her OUD and MMT could be obtained. Later that day, she underwent diagnostic angiography. A left posterior inferior cerebellar artery aneurysm was identified and endovascular coils were placed for aneurysm obliteration. On post-bleed day 1 (PBD1), the patient was significantly more alert and was successfully extubated. Of note, both her propofol and hydromorphone infusions were discontinued at that time. Following extubation a more detailed medical history was conducted, and the patient reported that her daily methadone dose was 95 mg/day and this dose was subsequently confirmed with the prescribing physician. After an electrocardiogram (EKG) demonstrated no QTc prolongation, 95 mg of methadone was given orally on the morning of PBD1 and this dosage was continued daily throughout her hospitalization. Continuous bedside telemetry and formal

EKG on PBD5 were used to monitor for QTc prolongation. After aneurysm obliteration, she was treated per our routine aSAH protocol, including scheduled nimodipine therapy, daily transcranial Doppler (TCD) assessment, blood pressure control, and serum sodium monitoring. Her EVD was left open to drain at 0 cm H₂O and on PBD9, as the patient had had no evidence of cerebral vasospasm (CV) or delayed cerebral ischemia (DCI), her EVD was weaned per protocol. The EVD was removed on PBD11 and she was discharged from the ICU later that day.

Throughout her hospitalization, the patient received appropriate ancillary care, including treatment for pain (primarily headache), constipation and electrolyte abnormalities. The patient's pain scores, stool frequency, and serum electrolytes were continuously monitored per protocol throughout her ICU stay. After extubation, the patient reported 10/10 pain due to headache. This was treated with scheduled acetaminophen-codeine. Despite this therapy, she continued to report significant headache pain through PBD4 that significantly improved to less than 2/10 through the rest of her hospitalization. Bowel function was monitored throughout her hospitalization and constipation was successfully treated on PBD6 with oral polyethylene glycol and bisacodyl with no additional reoccurrence of constipation during hospitalization. Her serum electrolytes were replaced per routine hospital protocol to ensure they remained within a normal range via oral and intravenous routes, as appropriate.

The patient was discharged from hospital to an acute rehabilitation facility on PBD16. At the time of her discharge, she remained on 95 mg/day of methadone and was scheduled to continue this regimen throughout her rehabilitation. At routine clinical follow-up on PBD90, she was recovering well. Her only complaint was minimal persistent headaches and she remained on MMT through her pre-existing provider. The patient provided written consent to publish this case report.

3 | DISCUSSION

This case report highlights the safe and effective early re-initiation of chronic MMT to prevent OWS in a patient with aSAH. In the care of this patient, we were not able to identify relevant published literature on the use of MMT in aSAH patients. For this reason, we discussed the potential complications and considerations, including concerns that early initiation of MMT might result in sedation or confusion that could mimic acute neurologic changes similar to those seen in cerebral vasospasm, that MMT could cause cardiac complications related to QTc prolongation, and that MMT could cause liver or kidney interactions with other medications routinely used in patients with aSAH. Although we did not detect any of these issues in our patient, they were important potential complications that were considered during her hospitalization.

Methadone is an opioid-agonist primarily active at the opioid mu receptor. It is used to prevent OWS in opioid-dependent patients and to treat acute and chronic pain in certain patient populations. (5) Daily MMT is used to blunt the distressing components of OWS, including anxiety, nausea, sweating, vomiting, abdominal pain, and diarrhea, that can occur with abrupt discontinuation of opioids in opioid-dependent patients. This patient did not develop any OWS-related symptoms; this was likely attributable to the early use of a hydromorphone infusion during sedation and then re-initiation of oral MMT in a timely manner.

The ability to conduct accurate serial neurological exams is critical after aSAH to detect the subtle acute neurological changes that portend potentially devastating sequelae, such as cerebral vasospasm and/or delayed cerebral ischemia. While we were concerned that MMT may cause inappropriate sedation or confusion, we believed that, with appropriate communication and discussion, we could balance the potentially conflicting goals of neurologic monitoring and continued opioid therapy. Our plan in the setting of new or unexplained mental status changes was to evaluate the patient, use early non-invasive radiographic imaging including computed tomography (CT) or computed tomography angiography

(CTA) and, if needed, perform invasive digital subtraction angiography (DSA) to exclude organic brain disease. If radiographic testing did not explain the neurologic changes, we would then temporarily discontinue MMT and monitor for improvements in her neurologic status. Because methadone has a very long half-life (up to 59 hours), MMT discontinuation alone would have taken a prolonged period to see resolution of neurologic symptoms. (6) For this reason, emergent opioid antagonist therapy (naloxone) was also considered; however, because emergent naloxone likely would have precipitated OWS, it was only to be used after direct discussion of the risks and benefits between the neurosurgery and critical care attendings.

One of our concerns was the possibility of prolonged QTc syndrome, which has been linked to mortality through Torsade de Pointes (TdP). Because both aSAH and methadone are known to prolong the QTc interval, the combination of chronic MMT and aSAH may therefore significantly prolong the QTc and increase the risk of TdP. (7, 8) In aSAH patients, the development of prolonged QTc syndrome is most likely to occur in female patients and in patients with serum hypokalemia. (9) Other variables, including age, aSAH severity, aneurysm site and other serum electrolyte abnormalities were not associated with an increased risk of prolonged QTc syndrome. Our patient was continuously monitored through bedside cardiac telemetry and formal 12-lead EKGs obtained on PBD1 and PBD5 did not exhibit a significantly prolonged QTc. These time points were chosen, after consultation with the clinical pharmacist. The former represents the baseline state before re-initiation of therapy; the latter represents the state after 5 dosing intervals had passed, a time when serum methadone steady-state had likely been achieved.

Another concern was the possibility of unique drug interactions that may exist between methadone and various medications frequently used in patients with aSAH. Methadone is primarily metabolized to an inactive metabolite, known as EDDP, by CYP2B6 in the liver. (10) Other CYP450 enzymes including CYP3A4, CYP2C19, CYP2D6, CYP2C9, and CYP2C8 are involved in methadone metabolism to a lesser degree.(11) As

such, we were concerned about potential drug interactions; however, none of the medications used, including antibiotics, nifedipine, nimodipine, or levetiracetam, are known to be metabolized by or affected by this hepatic metabolic pathway based on reviews of the published literature. Further review of the literature revealed no significant CYP2B6 inducer and inhibitor agents frequently used in the treatment of aSAH, alleviating some our concerns regarding the inclusion of MMT in this patient's treatment plan.

In summary, this case report describes the successful re-initiation of MMT in a patient with aSAH. Although continued MMT introduced the potential for additional sedation, mental status abnormalities, cardiac complications and drug interactions, we believed the potential benefits of continuing MMT, included mitigation of OWS symptoms and the continued blunting of opioid cravings, outweighed the potential risks. The patient recovered well and had no apparent complications from this treatment. Figure 1 highlights a potential clinical pathway for future patients with aSAH who are being considered for re-initiation of their chronic MMT therapy. We recommend that the neurologic status and other organ systems or complications be evaluated and stabilized prior to consideration of MMT. When stable and appropriate, we recommend pharmacist consultation to evaluate for potential drug interactions with methadone and to provide alternative safer recommendations, if appropriate. We also recommend careful QTc monitoring for, at least, the first few days as the normal cardiac abnormalities from aSAH subside and methadone serum concentrations reach steady state. (12) Formal 12-lead EKG is warranted prior to the first dose of MMT after aSAH and may be considered after 5 doses when methadone has achieved serum steady-state concentration; however, for most patients, continuous telemetry monitoring is likely adequate unless other therapies known to prolong QTc are added. In the event of increasing or prolonged QTc, alternate opiate therapies without the risk of QTc prolongation should be used to prevent complications of acute OWS. These alternatives should be discussed with the pharmacist and cardiology consultation may be considered. Finally, we

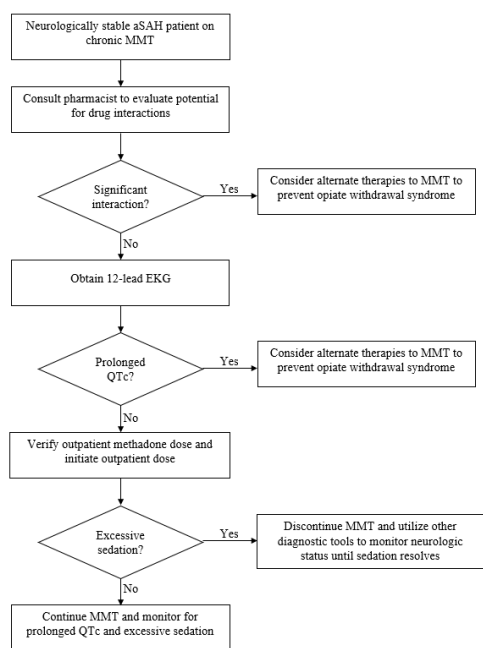


FIGURE 1 Care pathway for re-initiation of methadone maintenance therapy (MMT) in patients with aneurysmal subarachnoid hemorrhage (aSAH). CT = computed tomograph scan, CTA = computed tomography angiography scan, DSA = digital subtraction angiography.

recommend careful monitoring for excessive sedation, which may be confused with altered mental status, and the development of an evaluation and management plan with the neurosurgical team prior to MMT, including the use of early radiography or angiographic tests to exclude the possibility of organic brain disease. Following this protocol, we were able to re-initiate MMT after aSAH with no apparent related adverse effects. We believe MMT may be considered for patients on chronic MMT, without obvious exclusionary conditions, at the time of aneurysm rupture.

REFERENCES

1. Chang HY, Kharrazi H, Bodycombe D, Weiner JP, Alexander GC. Healthcare costs and utilization associated with high-risk prescription opioid use: a retrospective cohort study. *BMC Med.*

- 2018;16(1):69. DOI: 10.1186/s12916-018-1058-y
2. Krambeer LL, von McKnelly W, Jr., Gabrielli WF, Jr., Penick EC. Methadone therapy for opioid dependence. *Am Fam Physician.* 2001;63(12):2404-10.
3. Connolly ES, Jr., Rabinstein AA, Carhuapoma JR, Derdeyn CP, Dion J, Higashida RT, et al. Guidelines for the management of aneurysmal subarachnoid hemorrhage: a guideline for healthcare professionals from the American Heart Association/American Stroke Association. *Stroke.* 2012;43(6):1711-37. DOI: 10.1161/STR.0b013e3182587839
4. Martini ML, Neifert SN, Yaeger KA, Hardigan T, Ladner TR, Nistal DA, et al. Increased Risk of Transient Cerebral Ischemia After Subarachnoid Hemorrhage in Patients with Premorbid Opioid Use Disorders: A Nationwide Analysis of Outcomes. *World Neurosurg.* 2020;141:e195-e203. DOI: 10.1016/j.wneu.2020.05.075
5. Toombs JD, Kral LA. Methadone treatment for pain states. *Am Fam Physician.* 2005;71(7):1353-8.
6. Grissinger M. Keeping patients safe from methadone overdoses. *P T.* 2011;36(8):462-6.
7. Behzadi M, Joukar S, Beik A. Opioids and Cardiac Arrhythmia: A Literature Review. *Med Princ Pract.* 2018;27(5):401-14. DOI: 10.1159/000492616
8. Alinejad S, Kazemi T, Zamani N, Hoffman RS, Mehrpour O. A systematic review of the cardiotoxicity of methadone. *Excli j.* 2015;14:577-600. DOI: 10.17179/excli2015-553
9. Fukui S, Katoh H, Tsuzuki N, Ishihara S, Otani N, Ooigawa H, et al. Multivariate analysis of risk factors for QT prolongation following subarachnoid hemorrhage. *Crit Care.* 2003;7(3):R7-R12. DOI: 10.1186/cc2160
10. Ahmad T, Valentovic MA, Rankin GO. Effects of cytochrome P450 single nucleotide polymorphisms on methadone metabolism and pharmacodynamics. *Biochem Pharmacol.* 2018;153:196-204. DOI: 10.1016/j.bcp.2018.02.020
11. Volpe DA, Xu Y, Sahajwalla CG, Younis IR, Patel V. Methadone Metabolism and Drug-Drug Interactions: In Vitro and In Vivo Literature Review. *J Pharm Sci.* 2018;107(12):2983-91. DOI: 10.1016/j.xphs.2018.08.025
12. Ichinomiya T, Terao Y, Miura K, Higashijima U, Tanise T, Fukusaki M, et al. QTc interval and neurological outcomes in aneurysmal subarachnoid hemorrhage. *Neurocrit Care.* 2010;13(3):347-54. DOI: 10.1007/s12028-010-9411-9