

# A Split-Mouth Randomized Controlled Trial to Compare the Rate of Canine Retraction after a Soft Tissue Procedure Compared Against a Corticotomy Procedure for Accelerated Tooth Movement

U Gopalakrishnan, R Madasamy, R Mathew<sup>1</sup>, FF Alsulaimani<sup>2</sup>, M Sayed<sup>3</sup>, M Mugri<sup>4</sup>, HA Baeshen<sup>2</sup>, S Bhandi<sup>5</sup>, L Testarelli<sup>6</sup>, L Mahendra, J Muruganandhan<sup>7</sup>, AT Raj<sup>7</sup>, S Patil<sup>8</sup>

Department of Orthodontics, Sri Venkateswara Dental College and Hospital, Chennai, <sup>7</sup>Department of Oral Pathology and Microbiology, Sri Venkateswara Dental College and Hospital, Chennai, Tamil Nadu, India, <sup>1</sup>Department of Oral and Maxillofacial Radiology, College of Dental Medicine, Midwestern University, Illinois, <sup>5</sup>College of Dental Medicine, Roseman University of Health Sciences, South Jordan, UTAH, <sup>8</sup>College of Dental Medicine, Roseman University of Health Sciences, South Jordan, USA, <sup>2</sup>Department of Orthodontics, Faculty of Dentistry, King Abdulaziz University, Jeddah, <sup>3</sup>Department of Prosthetic Dental Sciences, College of Dentistry, Jazan University, Jazan, <sup>4</sup>Department of Maxillofacial Surgery and Diagnostic Sciences, College of Dentistry, Jazan University, Jazan, Saudi Arabia, <sup>6</sup>Department of Oral and Maxillofacial Sciences, Sapienza University, University of Rome, Rome, Italy

**ABSTRACT**

**Background and Aim:** Various methods to accelerate the orthodontic tooth movement have been used, among which corticotomy is considered to be the most common one. The suggested reasoning for such acceleration was the regional acceleratory phenomenon (RAP). Since the RAP is a property of both the hard and soft tissues, we designed a soft tissue flap procedure to compare the effects with the conventional corticotomy procedure. A split-mouth study was conducted where the two procedures were assessed in a single participant. **Patients and Methods:** The total sample size was calculated to be 40 with 20 participants in each group. The rate of tooth movement was the primary outcome measure, and the secondary outcomes were dentoalveolar changes, which were studied in both the conventional corticotomy and the flap-only procedure based on a cone-beam computed tomography (CBCT) wherein the alveolar bone density (BD) around canines, tipping, and rotational changes in canines, premolars, and molars were assessed. **Results:** Corticotomy resulted in greater canine angulation, lesser canine rotation and premolar rotation, and greater molar rotation compared with flap elevation, but these differences were statistically insignificant. **Conclusion:** Though the corticotomy resulted in higher BD, the differences were statistically insignificant. There was no significant difference in the rate of space closure assessed by the two techniques compared.

**KEYWORDS:** Accelerating tooth movement, bone density, corticotomy, flap elevation, rate of tooth movement

## INTRODUCTION

The treatment period in orthodontic treatment is one of the major concerns for patients wearing fixed appliances.<sup>[1]</sup> There has always been an interest among orthodontic patients to have their treatment completed as early as possible. Moreover, an accurate estimate of

**Address for correspondence:** Dr. S Patil, College of Dental Medicine, Roseman University of Health Sciences, South Jordan, UTAH - 84095, USA. E-mail: spatil@roseman.edu

This is an open access journal, and articles are distributed under the terms of the Creative Commons Attribution-NonCommercial-ShareAlike 4.0 License, which allows others to remix, tweak, and build upon the work non-commercially, as long as appropriate credit is given and the new creations are licensed under the identical terms.

**For reprints contact:** WKHLRPMedknow\_reprints@wolterskluwer.com

**How to cite this article:** Gopalakrishnan U, Madasamy R, Mathew R, Alsulaimani FF, Sayed M, Mugri M, et al. A split-mouth randomized controlled trial to compare the rate of canine retraction after a soft tissue procedure compared against a corticotomy procedure for accelerated tooth movement. Niger J Clin Pract 2023;26:666-73.

**Received:**  
24-Mar-2022;  
**Revision:**  
06-May-2023;  
**Accepted:**  
31-May-2023;  
**Published:**  
14-Jul-2023

Access this article online

<p>Quick Response Code:</p> 	<p>Website: <a href="http://www.njcponline.com">www.njcponline.com</a></p>
	<p>DOI: 10.4103/njcp.njcp_209_22</p>

treatment duration would also be helpful to the clinician for proper office management.<sup>[2]</sup> This issue of prolonged treatment time may cause adult patients to avoid orthodontic treatment or seek other methods with lesser treatment duration with less optimal results. Therefore, the main challenge in orthodontic research is to search for methods that decrease the treatment duration without compromising the outcome.<sup>[3]</sup>

Orthodontists have tried various methods to accelerate the treatment process using surgical methods, drugs, lasers, and other nonsurgical interventions.<sup>[1,4-9]</sup> The corticotomy procedure has been widely used as a surgical method to accelerate the treatment time. The rationale behind this is the regional acceleratory phenomenon (RAP) described by Frost (1983), which is a local reaction of the hard and soft tissues to the noxious stimulus, which accelerates the healing ability of the tissues.<sup>[10,11]</sup> The corticotomy procedure that was first introduced by Kole is usually performed broadly by raising the flap, and the cortical bone is scored in the interdental areas.<sup>[12]</sup> Another less-invasive modification is where there is no need for flap reflection; instead, micro-osteoperforations are done with the help of mini-implants.<sup>[13]</sup> The recent systematic review on corticotomy has concluded that such procedures fasten the treatment duration by 2- to 2.3-fold.<sup>[14]</sup> Based on literature evidence that elevation of a full-thickness mucoperiosteal flap alone (without cortical bone cuts) induced RAP, we designed our study to compare the effects of a full-thickness flap against those of a corticotomy procedure.<sup>[15-17]</sup> All the existing procedures related to accelerating tooth movement always involve some or the other form of bone injury. There has been no study in the literature, which assessed the effect of soft tissue procedure alone on acceleration. There are ample studies in the literature assessing the various methods of bone injury including micro-osteoperforation and single corticotomy cut<sup>[18,19]</sup> as an alternative to the conventional corticotomy procedure, but there was a lacuna when it comes to a procedure involving only the soft tissues. Hence, the aim of this study was to compare the acceleration potential of a soft tissue flap-only procedure with a single corticotomy cut with regard to the rate of canine retraction.

With the advent of cone-beam computed tomography (CBCT), a plethora of information was made available to orthodontists. Sectional imaging gives an insight into the inclinations, angulations, and rotations of every single tooth in the arch before and after treatment. The primary outcome of the study is to assess the rate of canine retraction, and the secondary outcomes included the CBCT-based assessment of dentoalveolar changes including the alveolar bone density (BD), angulation, rotations of canines, premolars, and molars.

## MATERIALS AND METHODS

### Patients and study design

The study protocol was reviewed and approved by the Institutional Ethical Committee of Sri Venkateswara Dental College and Hospital, Chennai, India (SVDC/IRB/2/2016). We obtained written informed consent in English and vernacular language from participants and included those who fulfilled the selection criteria. The surgical intervention was clearly explained to the patient before getting consent. The sample size was calculated as 40 with 20 participants in each group using G\*Power v.3.1 software and assuming an alpha error value of 0.05 with 85% power, employing statistical data from a study by Deepak *et al.*<sup>[20]</sup>

Inclusion criteria included patients in the age group of 15–25 years with good oral hygiene and class I bimaxillary protrusion requiring extraction of all the first premolars for their treatment. Patients were randomly allocated to both groups irrespective of gender with 20 patients in each group. The patients with periodontal diseases, marginal bone loss, systemic bone disorders, metal fillings, crown and bridgework, and systemic diseases, which may influence the movement, were excluded from the study.

After recruiting the patients, pretreatment orthodontic records of orthopantomogram (OPG), lateral cephalogram, study models, and photographs were taken. All the cases were set up with McLaughlin, Bennett, Trevisi (MBT) 0.022×0.028 slot (3M Victory Series, USA), and transpalatal bars were used for anchorage preservation. The extraction of all the first premolars was performed before setup. The wire sequence followed was 0.016 NiTi, 17×25 NiTi, 19×25 NiTi 19×25 Stainless steel (SS). At the stage of 19×25 SS, the patients were subjected to a CBCT scan. A CBCT scanner (SkyVIEW, MyRay) with exposure settings of 90 kVp, 92 mAs, and medium field of view (FOV) was used in all the patients.

The interventions were randomly allocated to each half of the arch by the flip coin method. If heads are turned up, the right side of the arch will be subjected to corticotomy with flap reflection and one single osteotomy cut equivalent to the depth of 102 bur in the premolar extraction site, which was considered experimental group I. If the tail turns up, the left side was subjected to a similar procedure. The contralateral side was accordingly subjected to only flap reflection without any corticotomy cuts, which were considered experimental group II. A single operator did both procedures for all the patients to rule out inter-operator bias. Cohen's kappa was used to obtain intraexaminer reliability, and

the minimum level of reliability was set at  $\kappa > 0.6$ . Once the soft tissue full-thickness flap was elevated and corticotomy was done, suturing was done after both procedures, which were removed after a week. Patients were followed up for any postoperative swelling and pain. Immediately after procedures, individual canine retractions were initiated in all the patients with NiTi coil springs on 19×25 SS wire. A force of 150 grams, measured with a Dontrix gauge, was delivered to the canines on both sides. The distance between the canine and the second premolar was noted before the start of activation and was measured once after every activation done at four weeks of interval with a digital caliper at the point of maximum convexity of the surfaces. The metal arms of digital calipers were autoclaved after each measurement. When the canine contacted the mesial surface of the second premolar, it was considered the end of canine retraction and the CBCT was repeated.

### Primary outcome

The primary outcome was the rate of space closure between the distal surface of canine and the mesial surface of the second premolar, which was measured at the point of maximum convexity intraorally at monthly intervals at every activation as T0, T1, T2, etc., till the end of space closure.

### CBCT assessment

The primary outcome was the rate of space closure, and the secondary outcome was the angulation and rotation of canine, premolar, and molar, molar anchor loss, and alveolar density between canine and second premolar regions. The angulation of canine, premolar, and molars was assessed relative to a plane perpendicular to the occlusal plane, which will form the zero line from where the degree of rotations will be measured. The rotation of canine, premolar, and molar was assessed relative to the midpalatal plane as the zero line. Mesial-out rotation was measured for canines, and mesial-in rotations were assessed for premolars and molars. One single radiologist assessed all the CBCT images for eliminating interobserver variability. After CBCT images, the subjects were followed up for further anterior space closure and finishing.

### Statistical analysis and report

The rate of retraction and the differences in canine, premolar, and molar tooth angulations, rotations, and the average BD between the canine and the premolar, before and after corticotomy and flap-only procedures, were measured by CBCT analysis. All the parameters were compared with statistical analysis using Statistical Package for the Social Sciences (SPSS) software version 20 using paired and unpaired *t*-tests for intra- and intergroup comparison, respectively.

## RESULTS

Since there was a dropout of two patients, the analysis was conducted on 18 patients.

Tooth Angulation Analysis [Figures 1 and 2].

### Canine angulation

The mean canine angulations in the corticotomy procedure and flap procedure were 10.3 and 7.93 degrees, respectively. This implies that corticotomy resulted in greater canine angulation compared with flaps. Statistical analysis with an independent-samples *t*-test showed that the difference in the canine angulations between both groups was statistically insignificant ( $P = 0.403$ ) [Table 1].

### Premolar angulation

The mean premolar angulations in the corticotomy procedure and flap procedure were -0.29 and 0.72 degrees, respectively. This implies that corticotomy resulted in negative premolar angulation compared with a slight positive angulation with flaps. Statistical analysis with an independent-samples *t*-test showed that the difference in the premolar angulations between both groups was statistically insignificant ( $P = 0.657$ ) [Table 1].

### Molar angulation

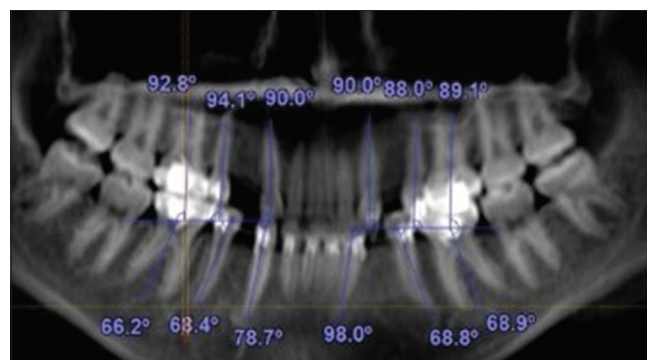
The mean molar angulations in the corticotomy procedure and flap procedure were -2.3 and -2.08 degrees, respectively. This implies that corticotomy resulted in slightly greater negative angulation compared with flaps. Statistical analysis with an independent-samples *t*-test showed that the difference in molar angulations between both groups was statistically insignificant ( $P = 0.893$ ) [Table 1].

CBCT analysis was also used to measure the rotation of teeth in the two different procedures.

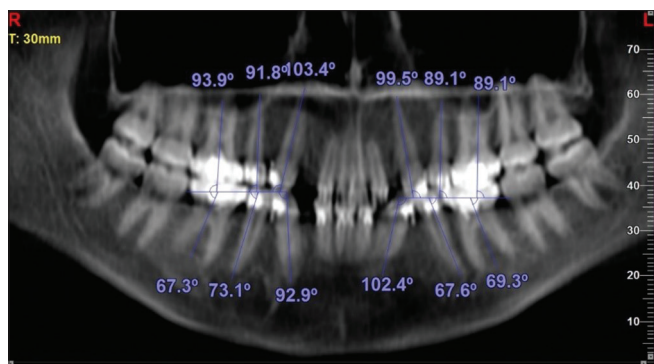
**Tooth rotation analysis** [Figures 3 and 4]

### Canine rotation

The mean canine rotations in the corticotomy procedure and flap procedure were 5.63 and 5.80 degrees, respectively. This implies that corticotomy resulted in lesser canine rotation compared with flaps. Statistical



**Figure 1:** Pretreatment tipping assessment of canine, premolar, and molar

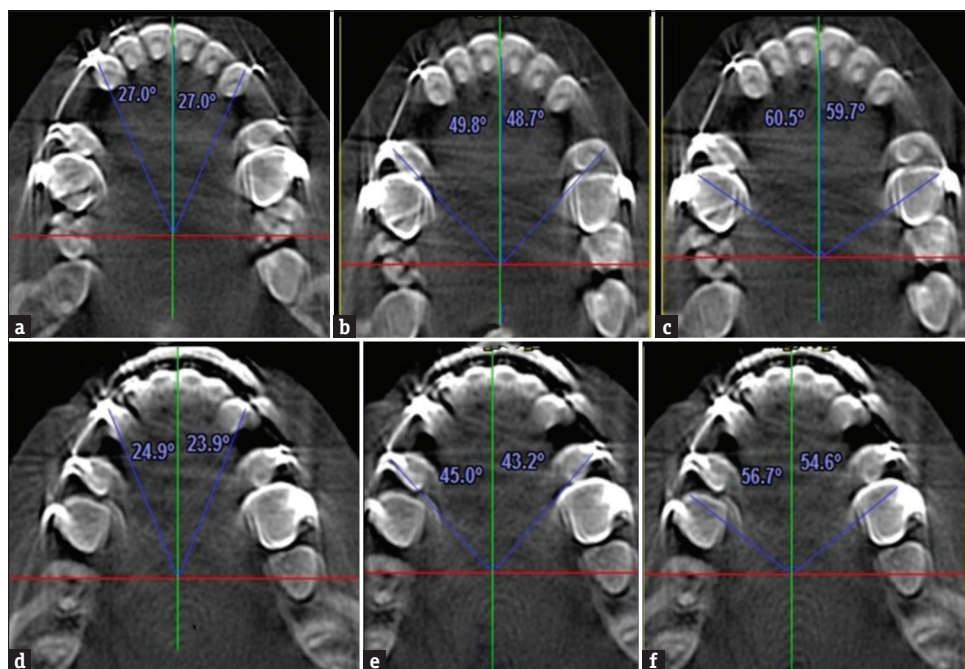


**Figure 2:** Posttreatment tipping assessment of canine, premolar, and molar

analysis with an independent-samples *t*-test showed that the difference in canine rotations between both groups was statistically insignificant ( $P = 0.951$ ) [Table 1].

**Premolar rotation**

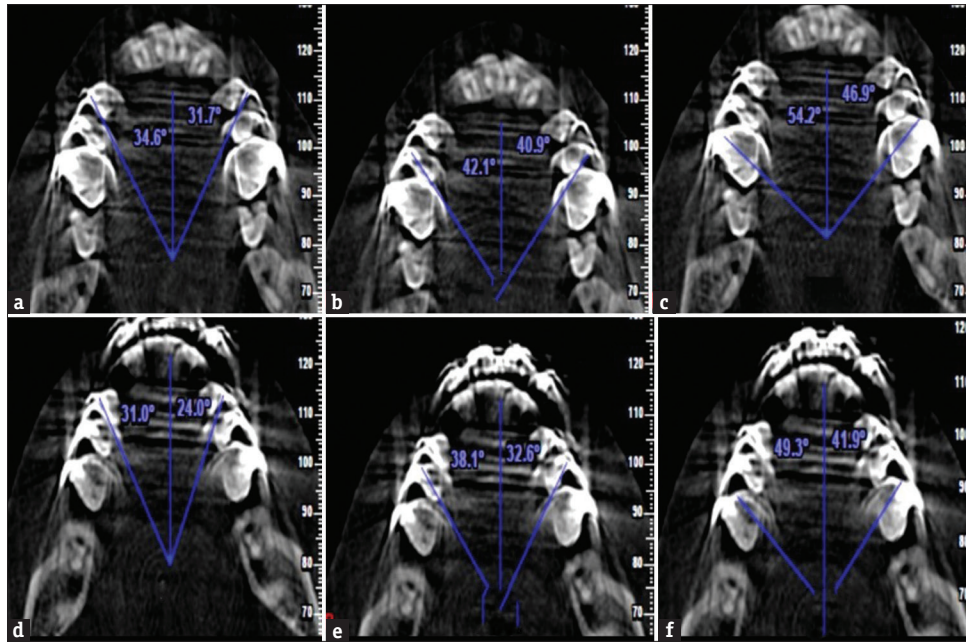
The mean premolar rotations in the corticotomy procedure and flap procedure were 0.08 and 0.39 degrees, respectively. This implies that corticotomy resulted in lesser premolar rotation compared with flaps. Statistical analysis with an independent-samples *t*-test showed that the difference in premolar rotations between both groups was statistically insignificant ( $P = 0.92$ ) [Table 1].



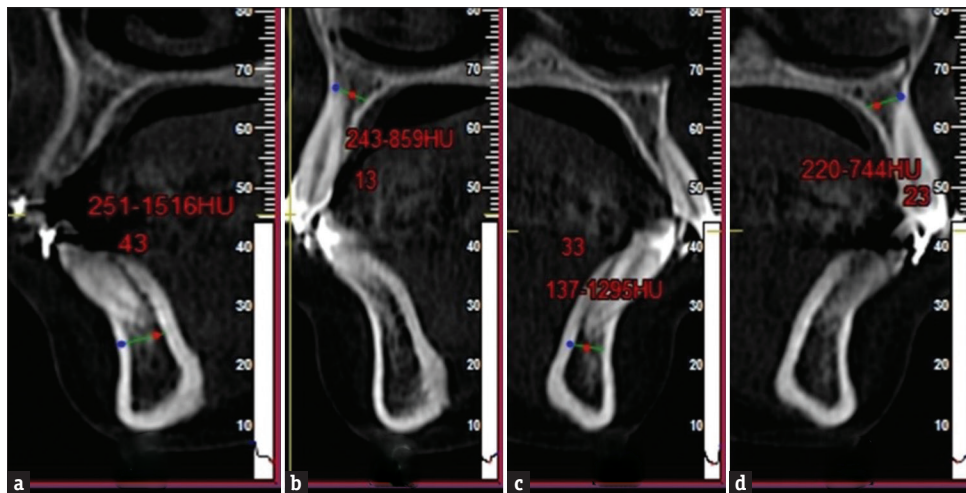
**Figure 3:** (a-c) Pretreatment rotation analysis in the maxillary arch; (d-f) Pretreatment rotation analysis in the mandibular arch

**Table 1: Comparison of density and angulation assessment of canine, premolar, and molar of both groups (values are in degrees)**

	Groups	n	Mean	SD	SE	Mean difference	t	P
Density	Group 1	18	804.85	213.66	50.36	6.27	0.086	0.932
	Group 2	18	798.57	225.89	53.24			
Canine tipping	Group 1	18	10.33	6.97	1.64	2.40	0.846	0.403
	Group 2	18	7.93	9.81	2.31			
Premolar tipping	Group 1	18	-0.29	6.26	1.48	-1.01	-0.448	0.657
	Group 2	18	0.72	7.25	1.71			
Molar tipping	Group 1	18	-2.33	5.46	1.29	-0.25	-0.136	0.893
	Group 2	18	-2.08	5.57	1.31			
Canine rotation	Group 1	18	5.64	8.48	2.00	-0.16	-0.062	0.951
	Group 2	18	5.81	7.77	1.83			
Premolar rotation	Group 1	18	0.08	9.14	2.15	-0.31	-0.101	0.92
	Group 2	18	0.39	9.29	2.19			
Molar rotation	Group 1	18	0.47	5.38	1.27	1.24	0.692	0.493
	Group 2	18	-0.78	5.40	1.27			



**Figure 4:** (a-c) Posttreatment rotation analysis in the maxillary arch; (d-f) Posttreatment rotation analysis in the mandibular arch



**Figure 5:** Pre treatment bone density in (a)43 region (b)13 region (c)33 region (d)23 region

**Molar rotation**

The mean molar rotations in the corticotomy procedure and flap procedure were 0.47 and -0.78 degrees, respectively. This implies that corticotomy resulted in slightly positive rotation compared with negative rotation with flaps. Statistical analysis with an independent- samples *t*-test showed that the difference in molar rotation between both groups was statistically insignificant ( $P = 0.493$ ) [Table 1].

**BD between the canine and the premolar [Figures 5 and 6]**

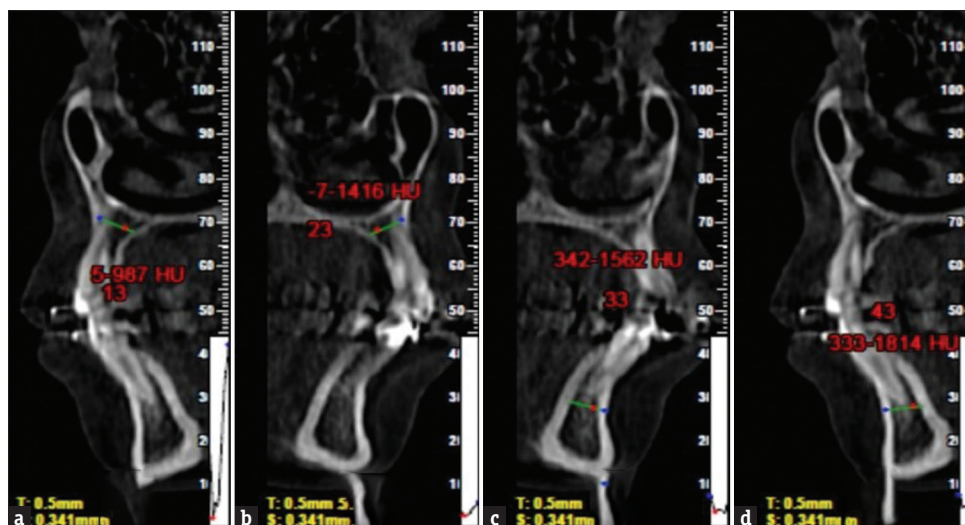
In comparison between the flap method and conventional corticotomy, the BD between the canine and the premolar, that is., the extracted alveolar region, showed

**Table 2: Comparison of rate of space closure in both groups (values are in mm)**

Time period	Flap (GRP II)		Corticotomy (GRP I)		P
	Mean	SD	Mean	SD	
T0-T1	1.65	0.40	1.86	0.30	0.125
T1-T2	1.48	0.32	1.55	0.32	0.134
T2-T3	1.38	0.34	1.43	0.43	0.554
T3-T4	1.36	0.35	1.44	0.32	0.154
T4-T5	1.36	0.41	1.40	0.34	0.164

slight differences with the mean BD with corticotomy at 804.85 and flap treatment at 798.57. Though the corticotomy resulted in higher density, the differences were not statistically significant. Statistical analysis

Downloaded from http://journals.lww.com/njcp by BhDMf5ePHKav1zEoum1tQINna+kLLhEZ9bsIH04XMI0hCQwC1AW nYOp/IIqH3D3D000Ry7TvsF14C13VC1y0abggQZxdwmlKZBYtws= on 07/31/2023



**Figure 6:** Post treatment alveolar bone density in (a)13 region (b)23 region (c) 33 region (d) 43 region

with an independent-samples *t*-test showed that the difference in the bone densities between both groups was statistically insignificant ( $P = 0.932$ ) [Table 1].

#### Rate of space closure with both procedures

In comparison between the flap method and corticotomy procedure, there was no significant difference in the rate of space closure assessed between the canine and the second premolar [Table 2].

#### DISCUSSION

Orthodontic treatment time ranges from 25 to 35 months for extraction patients. Prolonged orthodontic treatment times are always a burden for both the patient and the orthodontist since they are associated with increased root resorption, periodontal problems, decalcification as white spot lesions, and decreased patient compliance.<sup>[7,21–23]</sup> The treatment time can be best reduced by influencing the rate of tooth movement.

Corticotomy has been used as a method of accelerating tooth movement in many studies. This remains still a popular methodology despite the introduction of other means such as chemicals such as drug-related acceleration, lasers, and vibration methods.<sup>[24–26]</sup> The rate of tooth movement is almost doubled with the corticotomy procedure. This increase in the rate of tooth movement is due to the insult inculcated to the bone and the RAP that gets induced after that.<sup>[27]</sup>

The remodeling of alveolar bone is the key component of orthodontic tooth movement, and bone remodeling is accelerated during wound healing. It was suggested that cuts between the teeth could provide faster tooth movement,<sup>[14]</sup> but this was viewed as unnecessarily invasive and was not widely accepted. Remodeling of mineralized tissue is an inflammatory response activating

the localized cell population, which in turn attracts circulating osteoclast precursors. Bone remodeling cells are recruited to the site of remodeling faster if an additional inflammatory stimulus is given.<sup>[10,11,28,29]</sup> The RAP is a response of the tissues to a noxious stimulus that facilitates healing<sup>[30]</sup> The RAP, a response of both the hard and soft tissues, is characterized by acceleration of the normal cellular activities to aid in healing. In hard tissues such as the alveolar bone, the RAP is characterized by increased activation of the basic multicellular units (BMUs), which accelerates ongoing cellular activity.<sup>[10,31–33]</sup> So far, in the orthodontic literature, the hard tissue involvement is only taken into consideration and corticotomy has been widely investigated. Very few studies such as Owen *et al.* have reported on the effects of soft tissue procedures on tooth movement acceleration. Owen *et al.* reported that the flap-only surgery showed a lesser rate of tooth movement as compared to the other conventional techniques reported previously,<sup>[22,27,32–35]</sup> but he concluded that due to the limited effects it may not be justified for tooth movement acceleration. This was in contradiction with our study where we compared the regular corticotomy procedure with a flap-alone procedure. In the present study, the rate of acceleration remained the same for conventional and minimally invasive flap procedures. This is because the full-thickness flap is capable of inducing a resorptive activity of the alveolar bone as shown by various studies from periodontal literature. This is in concordance with the various periodontal studies, which have reported resorptive activity of alveolar bone after full-thickness flap procedures.<sup>[16,17,36]</sup>

Imaging is an essential diagnostic component in addition to the clinical assessment of dental patients. The introduction of panoramic radiography in the 1960s and

its widespread acceptance in the 1970s and 1980s led to a major change in dental radiology, helping clinicians provide a two-dimensional yet comprehensive image of the orofacial region. The introduction of CBCT led to a major shift in the paradigm of two-dimensional to three-dimensional approaches, data reconstruction, and image processing.<sup>[11,29]</sup> CBCT has been used variedly in dentistry and orthodontic practice in particular.<sup>[37]</sup> This study highlights yet another innovative use of this technique.

Although corticotomy and most of the studies compared only the rate of retraction of various methods, the BD, angulation, and rotation of teeth around the corticotomy sites were hardly studied parameters. In our study, we analyzed all these parameters using a CBCT scan. The results of our study were similar to those of the study conducted by Owen KM *et al.*<sup>[32]</sup> where the BD of the medullary bone decreased. In our study, the flap elevation procedure produced a limited bone insult, which was similar to other studies in periodontology where a full-thickness flap alone resulted in bone loss.<sup>[16,17,22,28,34–36,38,39]</sup>

## CONCLUSIONS

There was no statistically significant difference in canine, premolar, and molar angulations in both corticotomy and flap elevation procedures. There was no statistically significant difference in canine, premolar, and molar rotations in both corticotomy and flap elevation procedures. Corticotomy and minimally invasive flap elevation procedures had no statistically significant difference in the rate of tooth movement, dentoalveolar changes, or BD. Within the limits of the current study, we conclude that both the soft tissue flap-only procedure and a single-cut corticotomy accelerated the rate of retraction similarly. Further randomized controlled trials (RCTs) with more sample sizes will be required to confirm this finding since this was the first attempt to study the effect of a soft tissue procedure alone on acceleration.

## Institutional review board statement

The study was conducted according to the guidelines of the Declaration of Helsinki and approved by the Institutional Ethical Committee of Sri Venkateswara Dental College and Hospital, Chennai, India (SVDC/IRB/2/2016).

## Informed consent statement

Informed consent was obtained from all subjects involved in the study.

## Financial support and sponsorship

Nil.

## Conflicts of interest

There are no conflicts of interest.

## REFERENCES

- Fink DF, Smith RJ. The duration of orthodontic treatment. *Am J Orthod Dentofac Orthop* 1992;102:45–51.
- Alger DW. Appointment frequency versus treatment time. *Am J Orthod Dentofacial Orthop* 1988;94:436–9.
- Henneman S, Von den Hoff JW, Maltha JC. Mechanobiology of tooth movement. *Eur J Orthod* 2008;30:299–306.
- Fisher MA, Wenger RM, Hans MG. Pretreatment characteristics associated with orthodontic treatment duration. *Am J Orthod Dentofacial Orthop* 2010;137:178–86.
- Geiger AM, Gorelick L, Gwinnett AJ, Benson BJ. Reducing white spot lesions in orthodontic populations with fluoride rinsing. *Am J Orthod Dentofacial Orthop* 1992;101:403–7.
- Bishara SE, Ostby AW. White spot lesions: Formation, prevention, and treatment. *Semin Orthod* 2008;14:174–82.
- Segal GR, Schiffman PH, Tuncay OC. Meta analysis of the treatment-related factors of external apical root resorption. *Orthod Craniofac Res* 2004;7:71–8.
- Pandis N, Nasika M, Polychronopoulou A, Eliades T. External apical root resorption in patients treated with conventional and self-ligating brackets. *Am J Orthod Dentofacial Orthop* 2008;134:646–51.
- Roykó A, Dénes Z, Razouk G. [The relationship between the length of orthodontic treatment and patient compliance]. *Fogorv Sz* 1999;92:79–86.
- Hassan AH, Al-Saeed SH, Al-Maghlouth BA, Bahammam MA, Linjawi AI, El-Bialy TH. Corticotomy-assisted orthodontic treatment. *Saudi Med J* 2015;36:794–801.
- Frost HM. The regional acceleratory phenomenon: A review. *Henry Ford Hosp Med J* 1983;31:3–9.
- Kole H. Surgical operations on the alveolar ridge to correct occlusal abnormalities. *Oral Surg Oral Med Oral Pathol* 1959;12:515.
- Alikhani M, Raptis M, Zoldan B, Sangsuwon C, Lee YB, Alyami B, *et al.* Effect of micro-osteoperforations on the rate of tooth movement. *Am J Orthod Dentofacial Orthop* 2013;144:639–48.
- Darwiche F, Khodari E, Aljehani D, Gujar AN, Baeshen HA. Comparison of effectiveness of corticotomy-assisted accelerated orthodontic treatment and conventional orthodontic treatment: A systematic review. *J Contemp Dent Pract* 2020;21:701–9.
- Yaffe A, Fine N, Binderman I. Regional accelerated phenomenon in the mandible following mucoperiosteal flap surgery. *J Periodontol* 1994;65:79–83.
- Donnenfeld OW, Marks RM, Glickman I. The apically repositioned flap – A clinical study. *J Periodontol* 1964;35:381–7.
- Huang H, Williams RC, Kyrkanides S. Accelerated orthodontic tooth movement: Molecular mechanisms. *Am J Orthod Dentofacial Orthop* 2014;146:620–32.
- Kilinc B, Baka ZM. Comparison of the effectiveness of piezocision and microosteoperforation in leveling mandibular anterior teeth. *Am J Orthod Dentofac Orthop* 2023;163:491–500.
- Sharma K, Raghavan S, Batra P. Osseous evidence behind micro-osteoperforation. *Am J Orthod Dentofac Orthop* 2021;159:e81.
- Deepak C, Kannan MS, Sukumar MR, Rajesekar L, Datta U. A new approach for evaluation of canine dento alveolar distraction using cone-beam computed tomography. *J Pharm Bioallied Sci* 2015;7:S125-30.

21. Kurol J, Owman-Moll P, Lundgren D. Time-related root resorption after application of a controlled continuous orthodontic force. *Am J Orthod Dentofacial Orthop* 1996;110:303–10.
22. Artun J, Brobakken BO. Prevalence of carious white spots after orthodontic treatment with multibonded appliances. *Eur J Orthod* 1986;8:229–34.
23. Ristic M, Vlahovic Svabic M, Sasic M, Zelic O. Clinical and microbiological effects of fixed orthodontic appliances on periodontal tissues in adolescents. *Orthod Craniofac Res* 2007;10:187–95.
24. Wilcko WM, Wilcko T, Bouquot JE, Ferguson DJ. Rapid orthodontics with alveolar reshaping: Two case reports of decrowding. *Int J Periodontics Restorative Dent* 2001;21:9–19.
25. Wilcko MT, Wilcko WM, Pulver JJ, Bissada NF, Bouquot JE. Accelerated osteogenic orthodontics technique: A 1-stage surgically facilitated rapid orthodontic technique with alveolar augmentation. *J Oral Maxillofac Surg* 2009;67:2149–59.
26. Wilcko W, Wilcko MT. Accelerating tooth movement: The case for corticotomy-induced orthodontics. *Am J Orthod Dentofacial Orthop* 2013;144:4–12.
27. Sebaoun J-D, Kantarci A, Turner JW, Carvalho RS, Van Dyke TE, Ferguson DJ. Modeling of trabecular bone and lamina dura following selective alveolar decortication in rats. *J Periodontol* 2008;79:1679–88.
28. Vannala V, Katta A, Reddy M, Shetty S, Shetty R, Khazi S. Periodontal accelerated osteogenic orthodontics technique for rapid orthodontic tooth movement: A systematic review. *J Pharm Bioallied Sci* 2019;11:97.
29. De Grauwe A, Ayaz I, Shujaat S, Dimitrov S, Gbadegbegnon L, Vande Vannet B, *et al.* CBCT in orthodontics: A systematic review on justification of CBCT in a paediatric population prior to orthodontic treatment. *Eur J Orthod* 2019;41:381–9.
30. P. W. WR Fields HW SD, editor. St Louis, Missouri: Mosby's orthodontic review. Elsevier Ltd. *Contemp Orthod*; 2013. p. 290–3.
31. Verna C. Regional Acceleratory Phenomenon. *Front Oral Biol*. 2016;18:28-35. doi: 10.1159/000351897. Epub 2015. PMID: 26599115.
32. Owen KM, Campbell PM, Feng JQ, Dechow PC, Buschang PH. Elevation of a full-thickness mucoperiosteal flap alone accelerates orthodontic tooth movement. *Am J Orthod Dentofacial Orthop* 2017;152:49–57.
33. McBride MD, Campbell PM, Opperman LA, Dechow PC, Buschang PH. How does the amount of surgical insult affect bone around moving teeth? *Am J Orthod Dentofacial Orthop* 2014;145:S92-9.
34. Lee W, Karapetyan G, Moats R, Yamashita D-D, Moon H-B, Ferguson DJ, *et al.* Corticotomy-/osteotomy-assisted tooth movement microCTs differ. *J Dent Res* 2008;87:861–7.
35. Ruso S, Campbell PM, Rossmann J, Opperman LA, Taylor RW, Buschang PH. Bone response to buccal tooth movements-with and without flapless alveolar decortication. *Eur J Orthod* 2014;36:613–23.
36. Brägger U, Pasquali L, Kornman KS. Remodelling of interdental alveolar bone after periodontal flap procedures assessed by means of computer-assisted densitometric image analysis (CADIA). *J Clin Periodontol* 1988;15:558–64.
37. Kapila SD, Nervina JM. CBCT in orthodontics: Assessment of treatment outcomes and indications for its use. *Dentomaxillofacial Radiol* 2015;44:20140282.
38. Fickl S, Kerschull M, Schupbach P, Zühr O, Schlagenhauf U, Hürzeler MB. Bone loss after full-thickness and partial-thickness flap elevation. *J Clin Periodontol* 2011;38:157–62.
39. Tavtigian R. The height of the facial radicular alveolar crest following apically positioned flap operations. *J Periodontol* 1970;41:412–8.