

'The bubble heart': an unusual natural history told by multimodality imaging- a case report

Gabriella Locorotondo ^{1*}, Elisa Fedele¹, Carmela Napolitano ², and Leonarda Galiuto ¹

¹Department of Cardiovascular Sciences, Fondazione Policlinico Universitario A. Gemelli IRCCS, Largo A.Gemelli 8, Rome 00168, Italy; and ; and ²Department of Radiology, Fondazione Policlinico Universitario A. Gemelli IRCCS, Catholic University of the Sacred Heart, Largo A.Gemelli 8, Rome 00168, Italy

Received 16 February 2020; first decision 25 March 2020; accepted 24 November 2020

Background

Intracardiac thrombosis is a relatively common pathological condition. Often, it is diagnosed at echocardiography during the subacute or chronic phase. In the very acute phase, tissue composition can make thrombus appearance very different from that usually seen. Fresh thrombosis has been previously found also in peripartum cardiomyopathy (PPC), but with imaging features different from our case.

Case summary

A 27-year-old woman was referred to our hospital for PPC, with echocardiographic finding of intraventricular masses, resembling big bubbles. Cardiac magnetic resonance (CMR) allowed definitively diagnosing intracardiac 'very acute' thrombosis, which is rarely detected.

Discussion

Our case provides a practical lesson about management of an unusual presentation of a common problem. When early echocardiography does not allow making a certain diagnosis, CMR can be helpful and decisive, due to its unique ability to provide characterization of intracardiac masses.

Keywords

Intracardiac fresh thrombosis • Intracardiac sub-acute thrombosis • Echocardiography • Cardiac magnetic resonance • T1 and T2-weighted Spin Echo • Case report

Learning points

- Fresh thrombi can show a cystic appearance, with echo-lucent centre and hyperechoic boundaries.
- They appear hypoperfused at the first pass sequences and look very dark in early enhancement sequences.
- Fresh thrombi appear hyperintense in T1 and T2-weighted sequences, depending on presence of oxyhaemoglobin and slowly flowing blood.

Introduction

Intracardiac thrombosis is reported in up to 53% of peripartum cardiomyopathy (PPC), due to the peculiar hypercoagulability state.¹ Early certain diagnosis allows promptly starting anticoagulation therapy, but during the very acute phase it can be challenging, because of the unusual appearance of thrombi as 'bubbles' or 'cysts', as compared to the more widely codified features of high or mid-echo-density masses.² Indeed, very acute fresh thrombosis may appear at echocardiography as mass with a relatively echo-lucent centre and hyperechoic boundaries between fluid and more organized regions.³ Its diagnosis may be confirmed by cardiac magnetic resonance (CMR).⁴

* Corresponding author. Tel: +39 06 30154187, Fax: +39 06 3055535, Email: gabryloc@hotmail.it; gabriella.locorotondo@policlinicogemelli.it

Handling Editor: Dejan Milasinovic

Peer-reviewers: Livia Gheorghie and Hajnalka Vágó

Compliance Editor: Anastasia Vamvakidou

Supplementary Material Editor: Vassilios Parisis Memtsas

© The Author(s) 2020. Published by Oxford University Press on behalf of the European Society of Cardiology.

This is an Open Access article distributed under the terms of the Creative Commons Attribution Non-Commercial License (<http://creativecommons.org/licenses/by-nc/4.0/>), which permits non-commercial re-use, distribution, and reproduction in any medium, provided the original work is properly cited. For commercial re-use, please contact journals.permissions@oup.com

Timeline

Delivery after a normal pregnancy	
8 weeks after delivery	Onset and worsening of dyspnoea
Admission, Day 0	The patient was breathless with pulmonary and peripheral congestion. Blood pressure, heart rate, and respiratory rate were 100/70 mmHg, 130 b.p.m., and 20 breaths per minute, respectively Echocardiography showed severe left ventricular dilation and contractile dysfunction, with several masses with a soft consistency, a smooth surface, a central core of reduced echogenicity, and a hyperechogenic thin cap
Day 1	Cardiac magnetic resonance allowed to diagnose intracardiac fresh thrombosis Therapy with intravenous heparin was started
Day 8	Echocardiography showed solid and fixed thrombi Contrast-enhanced computed tomography confirmed the huge intraventricular thrombosis and excluded concomitant pulmonary thromboembolism Warfarin therapy was started
Day 15	No sign of thrombus was identifiable at echocardiography
Day 20	Urgent transplant due to absence of contractile improvement and onset of ventricular arrhythmias

Case presentation

A 27-year-old woman, with no previous cardiovascular events, but a family history of dilated cardiomyopathy (DCM), was referred to our intensive care unit 2 months after delivery from her first pregnancy, due to onset of worsening dyspnoea. The patient was not taking any medication before admission, since her previous medical history was unremarkable and delivery was uneventful. She started experiencing breathlessness about 6 weeks after delivery. After started, breathlessness rapidly worsened in 2 weeks, so she was hospitalized. On admission, she appeared breathless, with diffuse pulmonary rales and bilateral legs oedema. Although central venous pressure was not measured, the patient had distended jugular veins, thus suggesting high venous pressure. Blood pressure was 100/70 mmHg, heart rate was 130 beats per minute, and respiratory rate was 20 breaths per minute.

A twelve-lead electrocardiogram showed sinus tachycardia, with two ventricular ectopies, low amplitude of R wave in anterior precordial leads, and low amplitude of QRS in peripheral leads. Chest X-ray demonstrated bilateral pleural effusion and pulmonary interstitial oedema. High-sensitivity troponin I was slightly increased (0.09 ng/mL, normal value < 0.04) and NT-pro-B-type natriuretic peptide was

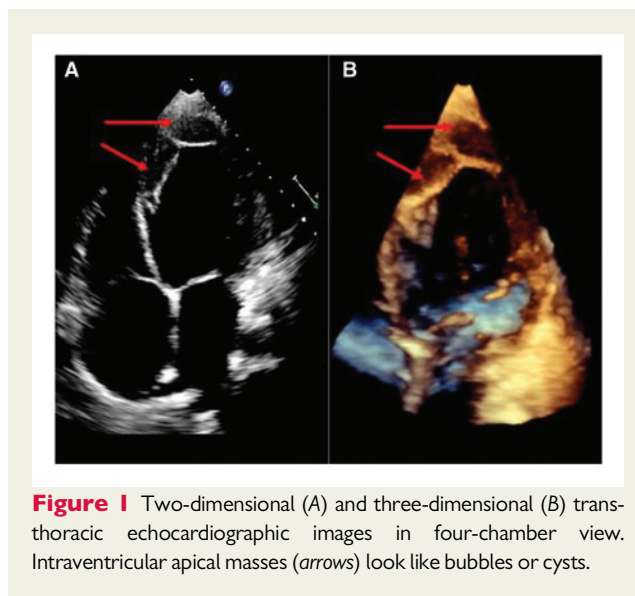


Figure 1 Two-dimensional (A) and three-dimensional (B) transthoracic echocardiographic images in four-chamber view. Intraventricular apical masses (arrows) look like bubbles or cysts.

1973 pg/mL (normal value < 450). Mild elevation of white blood cell count and mild anaemia were also found, without any abnormality in renal and liver functions. Intravenous infusion of furosemide (240 mg per day) and spironolactone (200 mg once daily) were promptly started. A transthoracic echocardiography showed severely dilated and globally hypokinetic left ventricle, with ejection fraction 11% and thinned walls. A significant dilation of both atria together with mild enlargement and hypokinesia of the right ventricle and moderate tricuspid and mitral regurgitations were also found. Moreover, an unusual finding was detected within left ventricular (LV) cavity: the sub-endocardial border of left ventricle seemed entirely covered, from mid-cavity to apex, by several masses, resembling big bubbles. They looked regular, of soft consistency, with a smooth surface and hyperechogenic thin cap with a central core, which appeared with low echogenicity at 3D and mainly 2D echocardiography (Figure 1). No blood flowing inside them was identified by colour Doppler mode, so that non-compaction cardiomyopathy could be excluded. Neither deformation imaging was performed, nor contrast echocardiography for LV opacification, which would have helped with the diagnosis, as the patient was thought to be in a critical condition and ultrasound contrast agent administration was not deemed safe.

A CMR, performed the day after echocardiography, confirmed the severe LV dilatation with global hypokinesia and severe depression of both left and right ventricular systolic function. Endoluminal material was present in the LV chamber, along the subendocardial layer: it obliterated completely the apex, spreading along the septal, inferior and anterior wall and the LV outflow tract and appeared lobulated, hypointense, 'floating' in the cine sequences (Figure 2A–C). These masses were lobulated, with smooth regular surface, hyper intense in both T1 (Figure 2D–F) and T2 (Figure 2G–I)-weighted sequences (with fat suppression), hypo intense during the first pass (Figure 3A–C) and both in the early (Figure 3D–F) and delayed enhancement sequences. Material with the same signal characteristics was also seen in the left atrial appendage that was almost completely obliterated (Figure 3E). No areas of subendocardial or intramural delayed enhancement suggestive of fibrosis were found. The signal characteristics of the

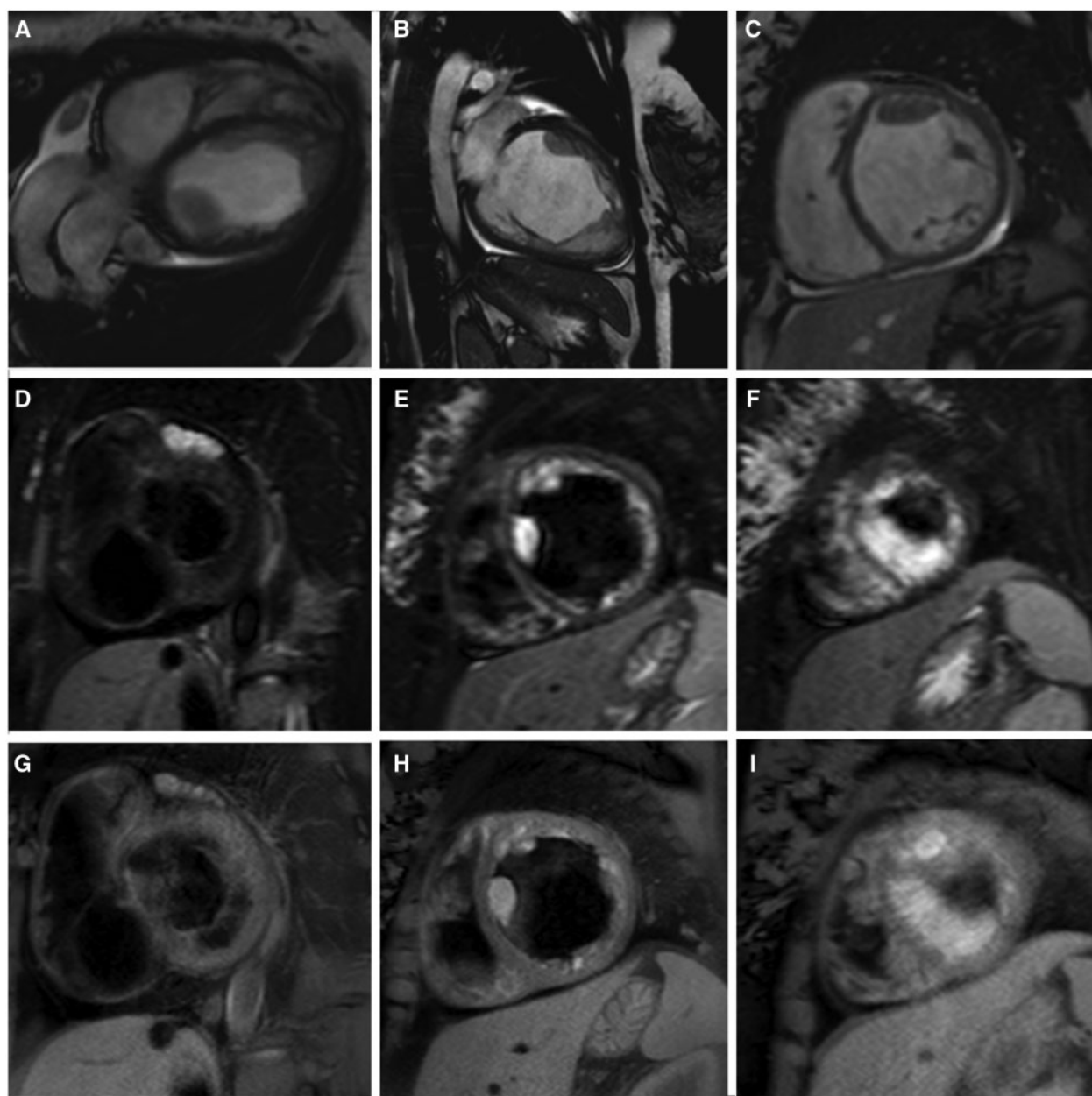


Figure 2 Cardiac magnetic resonance images, in horizontal (A) and vertical (B) long-axis views and in short-axis view (C) by cine Steady State Free Precession sequence. Multislice images in short-axis view from basal (D, G) to apical (F, I), by T1- (D–F) and T2- (G–I) weighted sequences, showing hyperintense signal.

material adhering to the LV and left atrial appendage was similar to that commonly found in early haemorrhage and led to diagnose massive very acute thrombosis in DCM.

Administration of unfractionated heparin (intravenous bolus of 5000 UI followed by continuous infusion of 20 000–40 000 UI per day), based on activated partial thromboplastin time (APTT), in addition to diuretics, bisoprolol 1.25 mg once daily and ramipril 2.5 mg once daily, was introduced. Although APTT was maintained at 1.5–2.0-fold of the control level, about 1 week after CMR and the beginning of heparin therapy, echocardiography showed an unexpected change of

intracardiac masses: in spite of being reduced, they appeared markedly increased in dimension, cone-shaped and hyperechogenic with enhanced consistency, thus fulfilling echocardiographic criteria of solid and fixed thrombi (Figure 4A–C). Contrast-enhanced computed tomography, performed in the same day of latter echocardiography, confirmed the presence of hypodense material, mainly in the LV apex, suggestive of huge intraventricular thrombosis and excluded concomitant pulmonary thromboembolism (Figure 5). Thus, the patient started warfarin 5 mg once daily in addition to unfractionated heparin, by maintaining an APTT constantly at two-fold of the normal

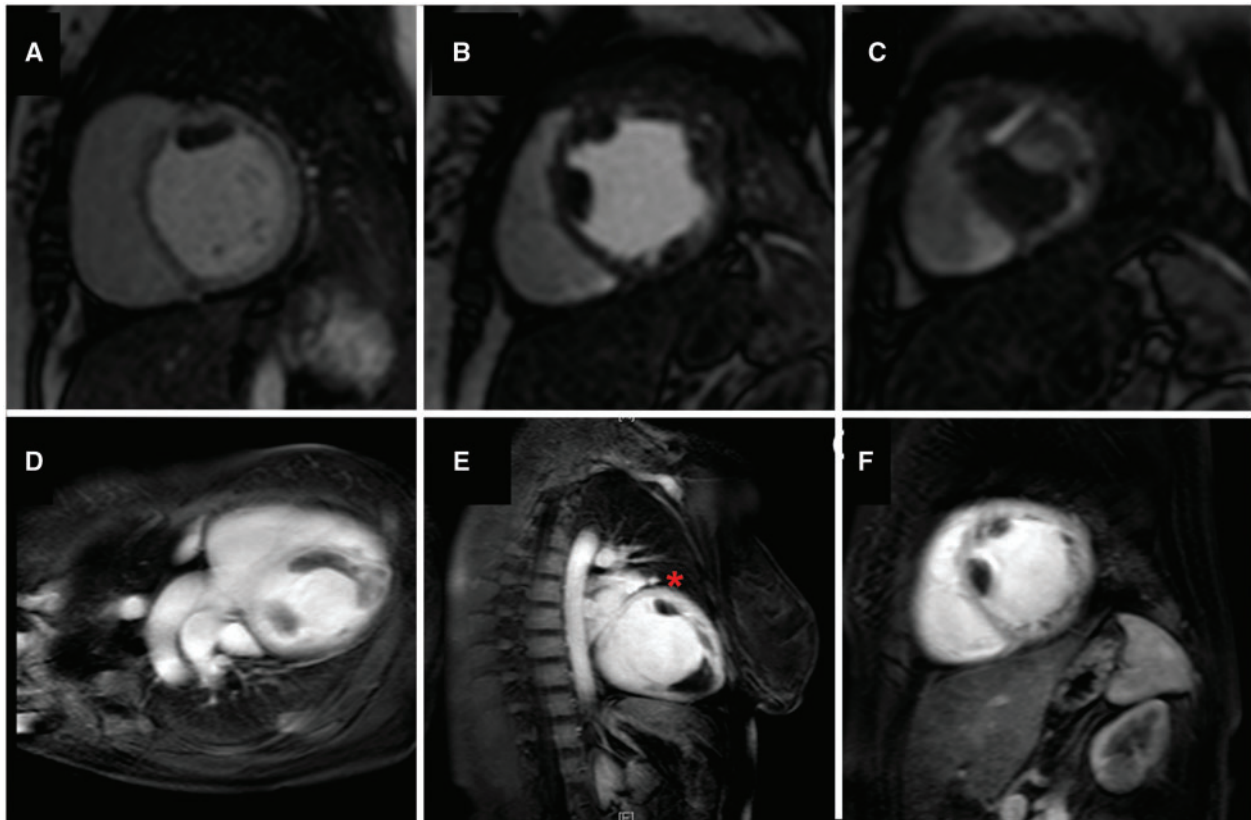


Figure 3 Cardiac magnetic resonance short axis images, from basal (A) to apical (C) levels, during first pass perfusion sequence (A-C), displaying the absence of contrast uptake. Early enhancement sequence images in horizontal (D) and vertical (E) long-axis and in short-axis views (F), showing the hypointense signal of the masses. Thrombus in left atrial appendage is marked by (*).

level. Contemporarily, as central and peripheral congestion was resolved, de-escalation of diuretic therapy up to oral dose of furosemide 25 mg three times a day was done. Then, unfractionated heparin was stopped when international normalized ratio reached 2.5.

One week later, no sign of thrombosis was identifiable any more at echocardiography (Figure 4D). However, the patient could not be discharged at home, due to onset of frequent ventricular arrhythmias, which were treated by intravenous continuous infusion of magnesium sulfate (10 g per day) and amiodarone (900 mg per day). Inotropes, such as dobutamine, which would have been useful to increase LV contractility, were avoided due to risk of worsen ventricular arrhythmia. Similarly, bromocriptine treatment, which would have been useful in our patient because of high rate of full LV recovery reported, could not be administered due to its prothrombotic effect.

About 15 days after starting medical therapy, LV dysfunction persisted associated to electrical instability, so that defibrillator implantation was firstly considered, but, as she was young, heart transplantation was also prematurely proposed. After brief screening, on Day 18th, the patient was urgently transferred to the referring transplant centre in another hospital. Bridge therapy to transplant, such as LV assist device, was planned, while only titration of bisoprolol up to 1.25 mg b.i.d. could be attempted. Further escalation of heart failure therapy could not be realized, due to prohibitive arterial

pressure values. Nephilysin inhibitor was not approved for treatment at the time of patient hospitalization. In the meanwhile, ventricular arrhythmias became more and more frequent and sustained. Thanks to prompt availability of donor, no bridge therapy was actually needed, and the patient was urgently transplanted. No histopathological examination was done on the diseased heart, in order to confirm imaging findings. Unfortunately, we only knew that transplantation was successful, but patient follow-up was missed in our hospital and no other clinical data were available.

Discussion

Subacute or chronic intraventricular thrombi appear, at echocardiography, as solid, hyperechogenic masses, which can be irregular, layered, immobile, and broad-based, located mainly where blood flow slows down. In a previous report of PPC,⁵ 'fresh' thrombi were described as shaggy, irregular, non-laminar, and disappeared after 4 days of intravenous heparin. Besides echo-density and size, a strain rate $\geq 1 \text{ s}^{-1}$ has been proposed to distinguish 'fresh' from old thrombosis.⁶ Deformation imaging was not used at the time of first echocardiographic examination in our case, as thrombotic nature of the masses was not sure, and their appearance could be in keeping with

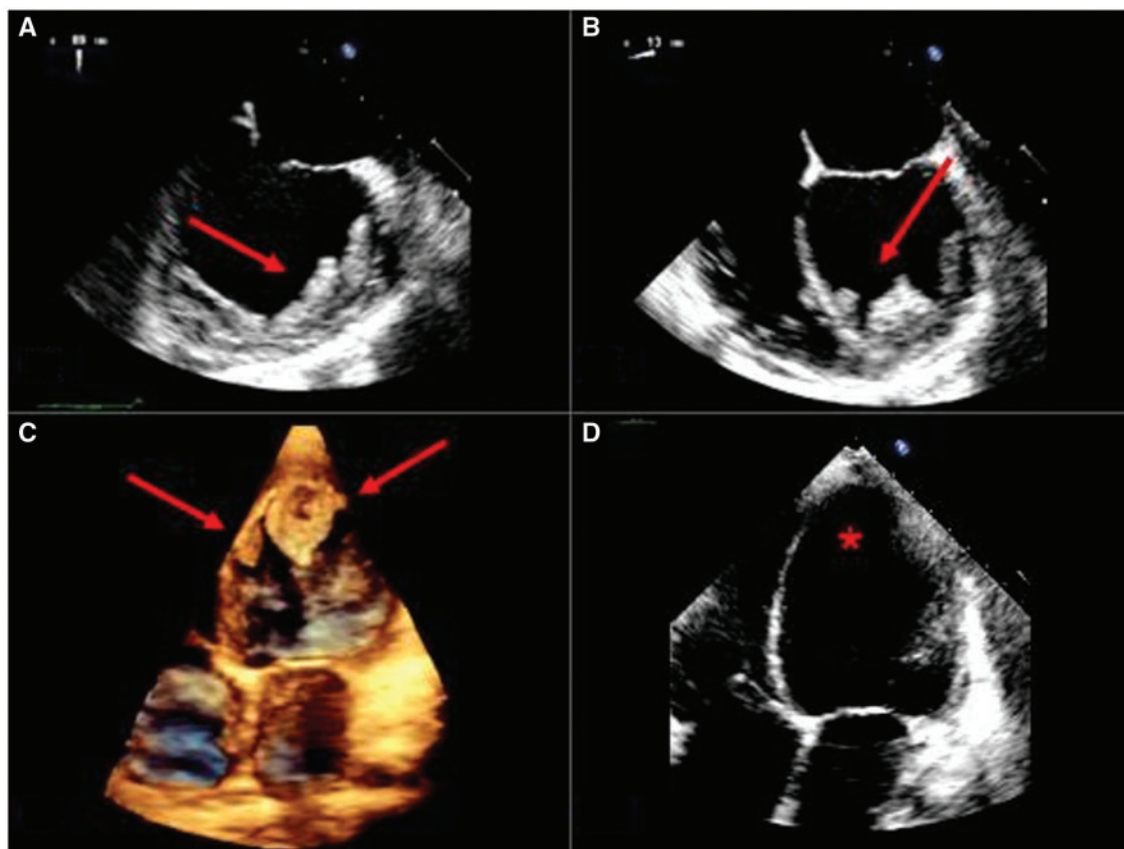


Figure 4 Trans-oesophageal (A, B) and transthoracic (C) echocardiographic images 1 week after starting unfractionated heparin showing changed masses. At discharge (D), disappearance of masses can be seen.

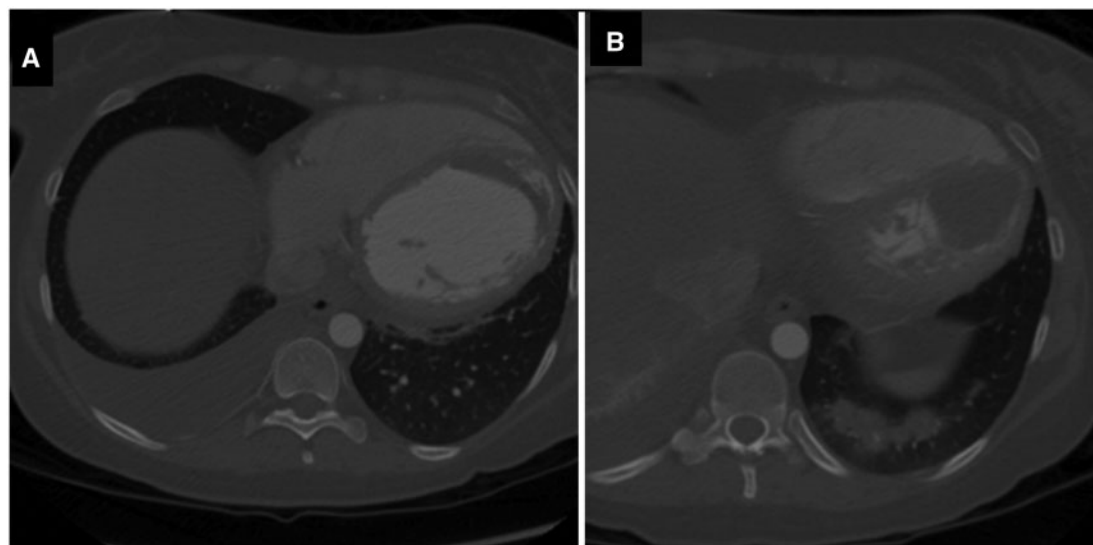


Figure 5 Axial images by computed tomography, acquired at two different levels (A, B) after administration of iodinated contrast agent. Hypodense masses without contrast uptake can be seen filling left ventricular cavity.

cysts. Moreover, in our patient, in the time interval previously defined for 'fresh' thrombosis,⁶ thrombi rapidly evolved from the very acute to the sub-acute phases: whether it is associated to changes in strain rate values is not known. CMR remains the gold standard in tissue characterization of cardiac masses. In cine sequences, thrombi typically appear as filling defects, mobile or attached to the endocardium; they are very dark both in early and delayed enhancement sequences and are usually hypo-perfused at the first pass. In the Spin-Echo T1 and T2-weighted sequences, acute and sub-acute thrombi can be hyperintense, due to red blood cell lysis and accumulation of paramagnetic compounds such as deoxyhaemoglobin and methaemoglobin, while chronic thrombi become isointense or hypointense due to the progressive replacement by fibrous tissue.⁴ Although hyperintensity on T2-weighted images is also typical of tumour masses,⁴ hyperintensity in T1-weighted sequences and strong hypo-intensity at early and delayed enhancement sequences (with an inversion time ≥ 442 ms required to define thrombi with the best diagnostic accuracy) has a decisive role in establishing the thrombotic nature.⁷

Such an extensive left ventricle very acute thrombosis has never been reported before at CMR. It is likely that, in our patient, diuretic therapy used to treat heart failure, together with hypercoagulable state usually persisting for 6 weeks after delivery, might have worsened haemoconcentration, thus favouring the thrombus evolution, despite heparin administration. Thus, diuretics and hemoconcentration could have counterbalanced anticoagulant effect of unfractionated heparin. Previous reports do not strictly fit our findings, which uniquely detected the very early phase of thrombi evolution.

Conclusions

In the very acute phase, LV fresh thrombosis may resemble cyst or bubble, with echocardiographic appearance very different from that usually seen, and therapeutic management may be challenging in hypercoagulability states and hemoconcentration. Specific imaging features reveal diagnosis and may tell the natural history of LV thrombosis throughout different stages.



Lead author biography

Dr Gabriella Locorotondo graduated in Medicine and Surgery in 2007 and specialized in Cardiology

in 2012. She currently practices transthoracic and transoesophageal echocardiography and has skills in myocardial contrast echocardiography, stress echo, coronary reserve, 3D, and strain. Dr Locorotondo is certified for second level competence in cardiac magnetic resonance imaging and has got a certification of competence for percutaneous treatment of valve heart disease. She has published research articles and book chapter about echocardiography, myocardial contrast echocardiography, and cardiac magnetic resonance, including participation in the EACVI textbook of echocardiography.

Supplementary material

Supplementary material is available at *European Heart Journal - Case Reports* online.

Acknowledgements

We thank Dr R. Marano for support in CMR reporting, Prof. A.G. Rebuzzi and Prof. F. Crea for approving the manuscript.

Slide sets: A fully edited slide set detailing this case and suitable for local presentation is available online as [Supplementary data](#).

Consent: The authors confirm that written consent for submission and publication of this case report including images and associated text has been obtained from the patient in line with COPE guidance.

Conflict of interest: none declared.

Funding: none declared.

References

- Demakis JG, Rahimtoola SH, Sutton GC, Meadows WR, Szanto PB, Tobin JR et al. Natural course of peripartum cardiomyopathy. *Circulation* 1971;**44**:1053–1061.
- Nihoyannopoulos P, Smith GC, Maseri A, Foale RA. The natural history of left ventricular thrombus in myocardial infarction: a rationale in support of masterly inactivity. *J Am Coll Cardiol* 1989;**14**:903–911.
- Cemry M, Erkan A, Cengel A. Misleading appearance of a left atrial thrombus as a cystic mass on transoesophageal echocardiography. *Heart* 2002;**87**:112.
- Pazos-López P, Pozo E, Siqueira ME, García-Lunar I, Cham M, Jacobi A et al. Value of CMR for the differential diagnosis of cardiac masses. *JACC Cardiovasc Imaging* 2014;**7**:896–905.
- Nishi I, Ishimitsu T, Ishizu T, Ueno Y, Suzuki A, Seo Y et al. Peripartum cardiomyopathy and biventricular thrombi. *Circ J* 2002;**66**:863–865.
- Niemann M, Gaudron PD, Bijnens B, Störk S, Beer M, Hillenbrand H et al. Differentiation between fresh and old left ventricular thrombi by deformation imaging. *Circ Cardiovasc Imaging* 2012;**5**:667–675.
- Weinsaft JW, Kim HW, Shah DJ, Klem I, Crowley AL, Brosnan R, James OG et al. Detection of left ventricular thrombus by delayed-enhancement cardiovascular magnetic resonance prevalence and markers in patients with systolic dysfunction. *J Am Coll Cardiol* 2008;**52**:148–157.