

## Cantharidin as an Alternative Treatment for Genital Warts: A Case Monitored With Optical Coherence Tomography

Cristel RUIINI<sup>1,2#</sup>, Benjamin M. CLANNER-ENGELSHOFEN<sup>1#</sup>, Markus HEPPT<sup>1</sup>, Thomas HERZINGER<sup>3</sup>, Miklós SARDY<sup>4</sup>, Thomas RUZICKA<sup>1</sup>, Lars E. FRENCH<sup>1</sup> and Markus REINHOLZ<sup>1</sup>

<sup>1</sup>Department of Dermatology and Allergology, University Hospital, Ludwig Maximilian University, Frauenlobstr. 9–11, DE-80337 Munich,

<sup>2</sup>Department of Dermatology, Allergology and Environmental Medicine, Munich Municipal Hospital, Munich, Germany, <sup>3</sup>Division of Dermatology, Queen's University Hospital, Kingston, Canada, and <sup>4</sup>Department of Dermatology, Venereology and Dermato-oncology, Semmelweis University, Budapest, Hungary. E-mail: markus.reinholz@med.uni-muenchen.de

<sup>#</sup>These authors contributed equally.

Accepted Aug 21, 2020; Epub ahead of print Aug 27, 2020

Cantharidin is a well-tolerated drug, used for topical treatment of common warts and molluscum contagiosum (1). Cantharidin is extracted from beetles (genera *Mytilabris* and *Lytta*, family Meloidae) (2). The species *M. phalerata* and *M. cichorii* are used widely in Chinese medicine, and *Lytta vesicatoria* L. (“Spanish fly”) is used in complementary medicine in Europe as an aphrodisiac. Recent studies have shown potential applications for cantharidin in post-herpetic neuralgia and leishmaniasis (3).

As a vesicant, cantharidin induces the degeneration and dissolution of desmosomal plaques, resulting in destruction of the tonofilament-desmosome-complex. While topical application of the drug is painless, it causes acantholytic blistering associated with a mild burning sensation approximately 24 h later. Skin changes resolve in 4–6 days with shedding of the wart.

Reported side-effects are erythema, pain, and post-inflammatory hyperpigmentation. Scarring, lymphangitis, cellulitis, and varicelliform dermatitis have also been reported occasionally (4–6). Cantharidin is of limited use in Germany, due to strict import requirements. In other countries, such as Canada, it is available either as monotherapy (0.7%, 1.0%) or as combination-therapy with podophyllotoxin and salicylic acid (3, 7).

HPV-induced anogenital warts (AGW) is the most common sexually transmitted disease worldwide. HP-viruses are non-enveloped, double-stranded DNA viruses infecting keratinocytes. HPV induces activation of the AIM2 inflammasome and IL1-beta release (8). Low-risk virus subtypes (HPV 6, 11, 40, 42, 43, 44, 54, 61, 70, 72, 81, etc.), in particular, can lead to highly contagious and stigmatizing anogenital warts, which are long-lasting and often subject to frequent recurrences in immunocompromised patients.

Several treatment options are available for AGW. Some treatments are performed directly by physicians (surgical/laser removal, trichloroacetic acid, interferon, cidofovir, photodynamic therapy, cryotherapy), while others are performed by the patient (topical podophyllotoxin, imiquimod, sinecatechins). Patient discomfort and relapse are frequent shortcomings (9–11). New treatments, using mono- or combination therapy, are therefore necessary. Effective follow-up is also necessary to diagnose recurrences early, reduce their burden and the spread of infection. Since clinical examination with

the naked eye might miss early recurrences, especially in the early phase, non-invasive diagnostic methods, such as dermoscopy or optical coherence tomography (OCT), can support the clinician's evaluation. OCT enables the painless and real-time visualization of architectural changes down to the middle dermis, but without cellular resolution.

Based on our experience as a reference centre for sexually transmitted diseases, we report here a case of a patient with recurrent genital warts (GW), who was treated with cantharidin solution in an individual off-label approach.

### CASE REPORT

A 32-year-old heterosexual, Caucasian man presented with a 5-year history of multiple condylomata acuminata on his penis and mons pubis (Fig. 1). He had previously undergone multiple therapeutic attempts, including 0.5% podophyllotoxin and 5% imiquimod, as well as CO<sub>2</sub>-laser therapy, electrocautery and cryotherapy, all resulting in incomplete remission or early relapse. Due to a high level of psychological discomfort, he was avoiding sexual relationships and even social contacts.

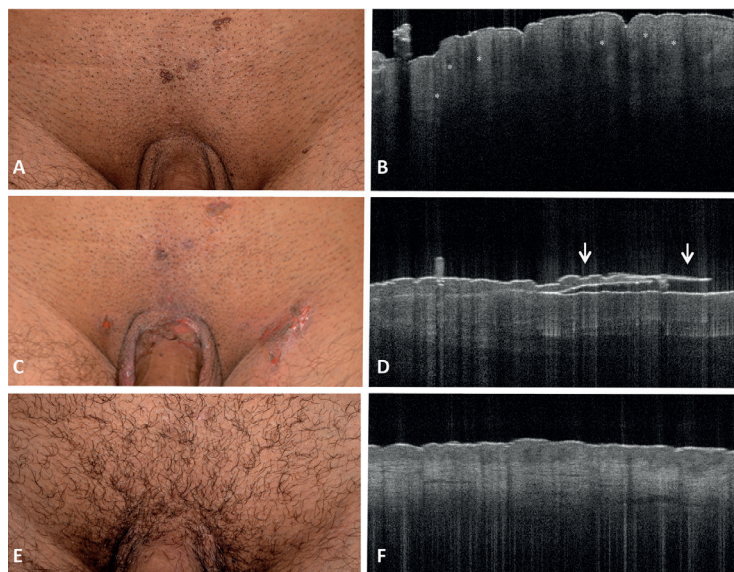
Written informed consent for the off-label treatment was obtained. Cantharidin (Canthacur<sup>®</sup> solution 0.7%, Paladin Labs Inc., Montreal, Canada) was applied to the affected area (25 mm<sup>2</sup>), left under occlusive tape for 8 h, then removed.

Clinical and optical coherence tomography (OCT) images (Vivosight, Michelson Diagnostics Ltd, Maidstone, Kent, UK) were collected immediately before, 1 and 28 days after treatment (Fig. 1). GW appeared on OCT as exophytic lesions with an undulated, broadened acanthotic epidermis; bright intratumoural structures, possibly indicating clusters of coilocytic keratinocytes were also visible (Fig. 1).

Twelve to 24 h after treatment, a strong inflammatory reaction, with erythema, swelling, blistering and erosions developed. Large areflective acanthotic blisters with detachment of the bright epidermal layer were visible on OCT (Fig. 1). The local skin reaction resolved after 7 days with no systemic side-effects. At follow-up (day 28), no relapse was observed; the treated area in OCT showed no scarring, and a normal epidermis with mild remaining vasodilatation was observed (Fig. 1).

### DISCUSSION

A recent meta-analysis of randomized controlled trials reported surgery, ablative therapy + imiquimod, and electrosurgery as the most efficacious therapies for AGW, with podophyllotoxin 0.5% as the most effective patient-administered therapy (11). Although combination



**Fig. 1. Clinical and optical coherence tomography (OCT) imaging of a 32-year-old male patient with therapy-resistant genital warts undergoing local treatment with cantharidin.**

(A, B) Baseline, (C, D) day 1, and (E, F) day 28 (Vivosight®; scan area 6 x 6 mm, depth of focus 1.0 mm, optical resolution < 7.5 µm lateral, < 5 µm axial). In untreated genital warts, exophytic lesions present a broadened, acanthotic epidermis with an undulated appearance (papillomatosis), and bright intratumoural structures, possibly indicating clusters of coilocytic keratinocytes (\*). Day 1: the blistering reaction causes detachment of the epidermal layer (D, arrows). At follow-up (F), the local skin reaction resolved with no scarring, leaving a normal epidermis with mild vasodilatation.

approaches especially are often successful, it is known that conventional topical therapies for AGW often require a long-term approach, repeated application, and are mostly associated with discomfort, while interventional therapies can result in scarring and infections and are less effective in widely scattered warts (9–11). Thus, available treatments tend to result in reduced compliance and lower the expected therapeutic success. Introducing an effective single application topical therapy might be helpful in improving the chances of successful treatment.

At the same time, frequent relapses represent a major matter in the treatment of AGW. OCT has already proven itself useful in monitoring subclinical lesions in the field cancerization (12), as it is able to non-invasively detect epidermal alterations. It might, therefore, be of use in the follow-up of AGW. In particular, measure of epidermal thickness at baseline and follow-up, presence of OCT criteria, such as papillomatosis and intratumoural bright structures and vascularization through dynamic OCT at baseline and follow-up, should be taken into account for an objective evaluation of treatment response.

Cantharidin is an interesting alternative for the local therapy of AGW, with the advantage of a single application at the cost of an extensive local skin reaction. Larger randomized controlled studies, as for molluscum contagiosum (13, 14), are needed to better determine the treatment success and recurrence rate of AGW with cantharidin treatment. Moreover, non-invasive diagnostic techniques, such as OCT, may be useful to monitor topical treatment.

*The authors have no conflicts of interest to declare.*

## REFERENCES

- Lopez D, Vilar Fernandez JM, Losa Iglesias ME, Alvarez Castro C, Romero Morales C, Garcia Sanchez MM, et al. Safety and effectiveness of cantharidin-podophylotoxin-salicylic acid in the treatment of recalcitrant plantar warts. *Dermatol Ther* 2016; 29: 269–273.
- Wang GS. Medical uses of mylabris in ancient China and recent studies. *J Ethnopharmacol* 1989; 26: 147–162.
- Torbeck R, Pan M, DeMoll E, Levitt J. Cantharidin: a comprehensive review of the clinical literature. *Dermatol Online J* 2014; 20: 13030.
- Cathcart S, Coloe J, Morrell DS. Parental satisfaction, efficacy, and adverse events in 54 patients treated with cantharidin for molluscum contagiosum infection. *Clin Pediatr (Phila)* 2009; 48: 161–165.
- Goldfarb MT, Gupta AK, Gupta MA, Sawchuk WS. Office therapy for human papillomavirus infection in nongenital sites. *Dermatol Clin* 1991; 9: 287–296.
- Mathes EF, Frieden IJ. Treatment of molluscum contagiosum with cantharidin: a practical approach. *Pediatr Ann* 2010; 39: 124–130.
- Moed L, Shwayder TA, Chang MW. Cantharidin revisited: a blistering defense of an ancient medicine. *Arch Dermatol* 2001; 137: 1357–1360.
- Reinholz M, Kawakami Y, Salzer S, Kreuter A, Dombrowski Y, Koglin S, et al. HPV16 activates the AIM2 inflammasome in keratinocytes. *Arch Dermatol Res* 2013; 305: 723–732.
- Lacey CJ, Woodhall SC, Wikstrom A, Ross J. 2012 European guideline for the management of anogenital warts. *J Eur Acad Dermatol Venereol* 2013; 27: e263–270.
- Woodhall SC, Jit M, Soldan K, Kinghorn G, Gilson R, Nathan M, et al. The impact of genital warts: loss of quality of life and cost of treatment in eight sexual health clinics in the UK. *Sex Transm Infect* 2011; 87: 458–463.
- Bertolotti A, Ferdynus C, Milpied B, Dupin N, Huiart L, Derancourt C. Local Management of anogenital warts in non-immunocompromised adults: a network meta-analysis of randomized controlled trials. *Dermatol Ther (Heidelb)* 2020; 10: 249–262.
- Ruini C, Hartmann D, Bastian M, Ruzicka T, French LE, Berking C, et al. Non-invasive monitoring of subclinical and clinical actinic keratosis of face and scalp under topical treatment with ingenol mebutate gel 150 mcg/g by means of reflectance confocal microscopy and optical coherence tomography: New perspectives and comparison of diagnostic techniques. *J Biophotonics* 2019; 12: e201800391.
- Guzman AK, Schairer DO, Garelik JL, Cohen SR. Safety and efficacy of topical cantharidin for the treatment of pediatric molluscum contagiosum: a prospective, randomized, double-blind, placebo-controlled pilot trial. *Int J Dermatol* 2018; 57: 1001–1006.
- Coloe Dosal J, Stewart PW, Lin JA, Williams CS, Morrell DS. Cantharidin for the treatment of molluscum contagiosum: a prospective, double-blinded, placebo-controlled trial. *Pediatr Dermatol* 2014; 31: 440–449.