

Pharmacological cardioversion of supraventricular tachycardia in pregnancy during continuous electrophysiological foetal monitoring

Citation for published version (APA):

Francinetti, A., Vullings, R., Dewals, W., & Jochems, L. (2022). Pharmacological cardioversion of supraventricular tachycardia in pregnancy during continuous electrophysiological foetal monitoring: A case report. *European Heart Journal - Case Reports*, 6(6), Article ytac213. <https://doi.org/10.1093/ehjcr/ytac213>

DOI:

[10.1093/ehjcr/ytac213](https://doi.org/10.1093/ehjcr/ytac213)

Document status and date:

Published: 01/06/2022

Document Version:

Publisher's PDF, also known as Version of Record (includes final page, issue and volume numbers)

Please check the document version of this publication:

- A submitted manuscript is the version of the article upon submission and before peer-review. There can be important differences between the submitted version and the official published version of record. People interested in the research are advised to contact the author for the final version of the publication, or visit the DOI to the publisher's website.
- The final author version and the galley proof are versions of the publication after peer review.
- The final published version features the final layout of the paper including the volume, issue and page numbers.

[Link to publication](#)

General rights

Copyright and moral rights for the publications made accessible in the public portal are retained by the authors and/or other copyright owners and it is a condition of accessing publications that users recognise and abide by the legal requirements associated with these rights.

- Users may download and print one copy of any publication from the public portal for the purpose of private study or research.
- You may not further distribute the material or use it for any profit-making activity or commercial gain
- You may freely distribute the URL identifying the publication in the public portal.

If the publication is distributed under the terms of Article 25fa of the Dutch Copyright Act, indicated by the "Taverne" license above, please follow below link for the End User Agreement:

www.tue.nl/taverne

Take down policy

If you believe that this document breaches copyright please contact us at:

openaccess@tue.nl

providing details and we will investigate your claim.

Pharmacological cardioversion of supraventricular tachycardia in pregnancy during continuous electrophysiological foetal monitoring: a case report

Audrey Francinetti ^{1*}, Rik Vullings ², Wendy Dewals ³, and Lisbeth Jochems ¹

¹Department of Gynaecology and Obstetrics UZA, Antwerp University Hospital, Drie Eikenstraat 655, 2650 Edegem, Belgium; ²Signal Processing Systems group, Eindhoven University of Technology, 5612 AZ Eindhoven, Netherlands; and ³Department of Pediatric Cardiology UZA, Antwerp University Hospital, Drie Eikenstraat 655, 2650 Edegem, Belgium

Received 25 October 2021; first decision 10 January 2022; accepted 19 May 2022; online publish-ahead-of-print 24 May 2022

Background

Maternal tachycardia is the most frequently occurring cardiac complication during pregnancy. Often administration of drugs is required as a treatment. The drug of choice is intravenously administered adenosine because it is considered safe, though there are limited studies regarding safety for the foetus with the use of adenosine.

Case summary

We report a conversion of maternal atrio-ventricular (AV) nodal reentry tachycardia during pregnancy with the use of intravenous adenosine whilst continuous electrophysiological foetal monitoring. Four seconds after the maternal conversion, the foetal tracing suggests the presence of a ventricular extrasystole or a transient AV block.

Discussion

This case report illustrates that the administration of adenosine intravenously during pregnancy could have an effect on the foetal conduction system. Therefore, further investigation to assess the electrophysiological effect of adenosine on the foetal electrocardiogram seems required.

Keywords

Pregnancy • Atrio-ventricular nodal reentry tachycardia • Adenosine • Continuous electrophysiological Foetal monitoring • Case report

ESC Curriculum 5.5 Supraventricular tachycardia • 9.8 Pregnancy with cardiac symptoms or disease

Learning points

- If administration of drugs is necessary as a treatment for supra-ventricular tachycardia during pregnancy adenosine is the first choice.
- Administration of adenosine during pregnancy needs more cautiousness, because there could be an effect on the foetal conduction system.

* Corresponding author. Tel: +32472/51.41.90, E-mail: audrey.francinettimail@gmail.com

Handling Editor: Bogdan Enache

Peer-reviewers: Stefano Bordignon; Stefan Simovic

Compliance Editor: Lavanya Athithan

Supplementary Material Editor: Nida Ahmed

© The Author(s) 2022. Published by Oxford University Press on behalf of the European Society of Cardiology.

This is an Open Access article distributed under the terms of the Creative Commons Attribution-NonCommercial License (<https://creativecommons.org/licenses/by-nc/4.0/>), which permits non-commercial re-use, distribution, and reproduction in any medium, provided the original work is properly cited. For commercial re-use, please contact journals.permissions@oup.com

Introduction

During pregnancy, maternal tachyarrhythmia is the most frequently occurring cardiac complication.¹ This is likely due to the combination of haemodynamic, hormonal, and autonomic changes.² The majority of these tachyarrhythmias are supraventricular. Treatment is required to avoid maternal haemodynamic compromise that would in turn jeopardize the mother and similarly the foetus by a reduction of uterine blood flow.³ In the event that vagal manoeuvres and carotid sinus massage fail, administration of drugs is required. Pharmacological treatment can be challenging as some antiarrhythmic drugs may cross the placental barrier and thereby influence foetal heart function. In atrio-ventricular (nodal) reentry tachycardia (AVNRT), the drug of choice is intravenously administered adenosine.¹ Adenosine allegedly is able to cross the placenta; nonetheless, the half-life is very short (< 10 s), thereby minimizing any potential effects the adenosine may have on the foetus.⁴ Adenosine is considered safe and is frequently used during pregnancy for the cardioversion of tachyarrhythmias, though there are limited studies regarding safety for the foetus.⁵ A case report described transient foetal bradycardia of 5 s,⁶ whilst other publications reported an increased incidence of preterm delivery after adenosine administration⁷⁻⁹ though direct causation was not established. We report a case of conversion of maternal AVNRT during pregnancy with the use of intravenous adenosine. Simultaneous foetal monitoring by means of transabdominal foetal electrocardiography permitted the assessment of a potential effect of adenosine on the foetus.

Timeline

Time	Events
Prior to first pregnancy	Brief self-limiting episodes of palpitations.
First pregnancy	Uncomplicated pregnancy, delivery by primary Caesarean section due to breech position.
Second pregnancy	
26 weeks of gestation	Supra-ventricular tachycardia, cardioversion with adenosine.
38 weeks of gestation	Recurrent supra-ventricular tachycardia, cardioversion with adenosine. Repeated Caesarean section brought forward because of spontaneous labour.
4 months postpartum	Ablation of typical AV-nodal re-entrant tachycardia

Case presentation

A 30-year-old, gravida 2, para 1, with no relevant medical history other than previous self-limiting episodes of palpitations, was referred to a regional hospital by her general practitioner on account of palpitations, tachycardia and general malaise at 26 weeks and 3 days gestational age.

First pregnancy has been uncomplicated. Given the early gestational age, she was referred to our tertiary care centre. Clinical examination revealed normal vital parameters besides a heart rate of 184 per minute and a normal auscultation of heart and lungs (no summation gallop). The electrocardiogram (ECG) showed a small QRS tachycardia isoelectric ST-segments and repolarization disorders in leads III and aVF, suggestive of an AVNRT (Figure 1). Transthoracic echocardiography was normal (normal contractility, no chamber dilatation). Biological and biochemical analysis were normal, as was thyroid function. Foetal monitoring was obtained by electrophysiology (Figure 2) and cardiotocography (CTG) displaying a normal pattern with a normal baseline foetal heart rate of 140 beats per minute. Transabdominal ultrasonographic examination showed a foetus in breech position with normal heart rate, normal amniotic fluid, placenta anterior, and an estimated foetal weight of 1100 g.

At the outset, treatment consisted of carotid sinus massage and Valsalva manoeuvre, neither of which was successful. As a second step, pharmacological cardioversion was attempted. Adenosine 6 mg as a bolus was administered intravenously in the right brachial vein with an 18 gauge catheter, which resulted in prompt conversion to sinus rhythm.

Throughout the administration of adenosine, both patient and foetus were under continuous electrocardiographic monitoring. After the administration of adenosine, the CTG showed an abrupt change of maternal heart rate without any discernable change of the foetal heart rate on the CTG (Figure 3). We tried to assess the electrophysiological effect of adenosine on the foetus by analyzing the foetal ECG within the first 60 s after maternal conversion to sinus rhythm. Four seconds after the sudden decrease in maternal heart rate, the tracing (Figure 4) suggests the absence of a QRS complex at the expected time interval (between QRS complex 7 and 8). Depending on how we interpreted the small complexes (Figure 4A and B), we can explain this either by the presence of a ventricular extrasystole (as 'a' could signify a possible QRS complex) with a compensatory pause or as an AV block (as 'a' nor 'b' are showing real resemblance with other ventricular activity seen on this foetal ECG and therefore 'b' possible being a non-conducted P wave).

Following one day of observation, the patient was discharged from the hospital in good general health. She was referred back to her regular obstetric healthcare. At 38 weeks of gestation, she had a recurrent episode of AVNRT which was successfully terminated with an intravenous bolus of 6 mg adenosine. An oral beta-blocker (bisoprolol 2.5 mg) was started to prevent recurrences. Soon after pharmacological cardioversion, she went into spontaneous labour and had an uncomplicated repeat cesarean section, originally scheduled for 39 weeks of gestation. After birth, the neonate was transferred to the neonatal intensive care unit for observation. Apgar scores were normal as was umbilical cord pH. There were no signs of neonatal adverse outcome. Four months post-partum, the patient underwent an uncomplicated ablation of her slow pathway of the AVNRT.

Discussion

To our knowledge, this is the first report that illustrates a possible effect of adenosine on the foetal heart by either the presence of a ventricular extrasystole or even a transient AV block.

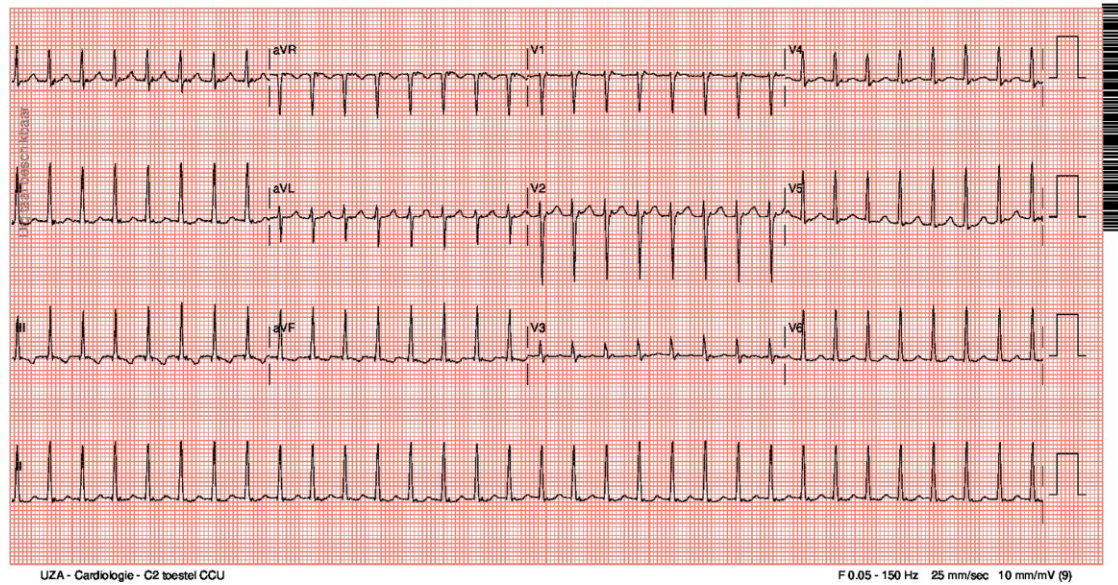


Figure 1 Maternal electrocardiogram showing atrio-ventricular (nodal) reentry tachycardia.

As reported by Dunn *et al.*⁶, the effect was not visible on the CTG. The lack of visibility on the CTG may be the reason that the administration of adenosine during pregnancy is considered safe.⁵

To obtain a clean noninvasive foetal ECG remains challenging because of the multiple interferences and noises in the abdominal recordings such as maternal ECG, power line interference, baseline fluctuations, muscle noise from the mother and foetus, and movement artefacts. In this case report, we used an end-to-end trained deep convolutional neural network for denoising the foetal ECG sig-

nals.¹⁰ The noninvasive foetal ECG displays variations in amplitude. Foetal movements or maternal breathing may cause such variations. Therefore, one cannot draw conclusions based only on amplitude of the foetal ECG. The absence of the QRS complex we can however not explain by maternal breathing nor moving of the foetus as this would not be limited to one single heartbeat.

Adenosine deaminase is reduced by 25% in pregnancy and the effective dose needed for the foetus would be very low (1/60th of the administered dose). This could potentially explain the interpretation of the foetal ECG.

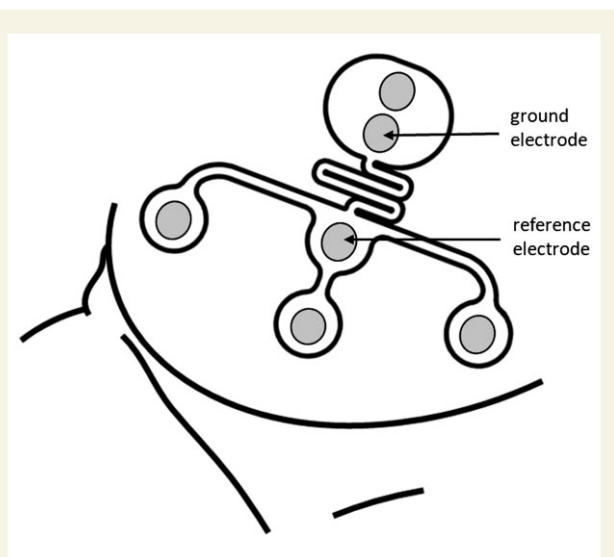


Figure 2 Schematic presentation of Nemo Healthcare: the electrode patch positioned on the maternal abdomen. Four measuring electrodes, plus one ground and one reference electrode.

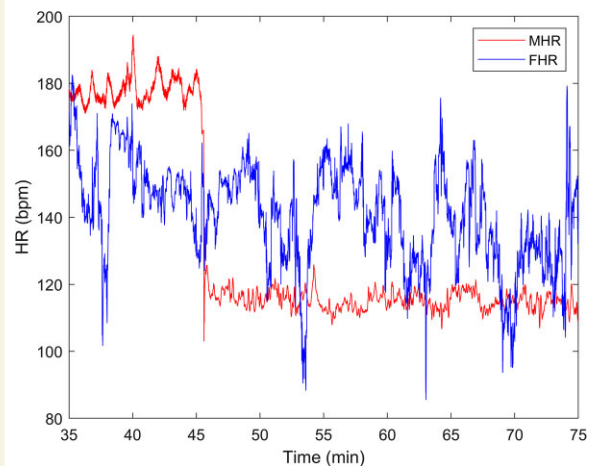


Figure 3 Cardiotocography after the administration of adenosine showing an abrupt change of maternal heart rate without any discernable change of the foetal heart rate.

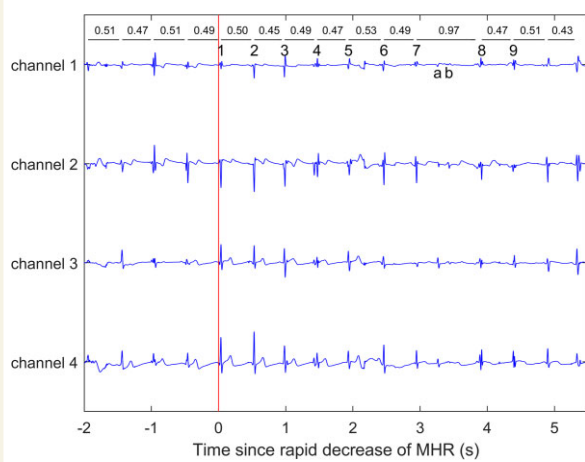


Figure 4 Foetal electrocardiogram within the first seconds after maternal conversion to sinus rhythm. The tracing suggests the absence of a QRS complex at the expected time interval (between QRS complex 7 and 8). Depending on how we interpreted the small complexes (A and B), we can explain this either by the presence of a ventricular extrasystole (as 'a' could signify a possible QRS complex) with a compensatory pause or as an atrio-ventricular block (as a nor b are showing real resemblance with other ventricular activity seen on this foetal electrocardiogram and therefore 'b' possible being a non-conducted P wave).

Our patient went into spontaneous labour while on oral bisoprolol after the second episode of tachycardia. Whether this is related to the administration of the medication tends to be supported by earlier reports^{7–9} but may be physiological since she reached term.

The first choice for prevention of supraventricular tachycardia during pregnancy is a beta-1-selective drug or verapamil. A beta-1-selective drug is preferred above unselective beta-blockers such as atenolol because this last one is associated with foetal growth restriction. The indication to use a preventive drug depends on the severity of symptoms and haemodynamic compromise during tachycardia. In case the first choice therapy fails, it is recommended to use flecainide or catheter ablation.¹¹

Adenosine is the drug of first choice for cardioversion of supraventricular tachycardia. Although administration of adenosine during pregnancy is generally considered to be safe for the foetus, this case report could lead to more cautiousness as there could be an effect on the foetal conduction system. Therefore further investigation to assess the electrophysiological effect of adenosine on the foetal ECG seems required, especially since due to maternal or pharmacological reasons the foetus is exposed to higher adenosine levels. To achieve this, technological improvements to obtain a clean non-invasive foetal ECG are necessary.

Lead author biography



Audrey Francinetti (1992) is a fifth year obstetrics and gynaecology specialist registrar at the Antwerp University Hospital. She obtained her medical degree at the University of Antwerp in 2017. Outside of work, she enjoys spending time with her family and friends.

Acknowledgements

We want to thank dr. Kok R. who guided us while writing this case report.

Slide sets: A fully edited slide set detailing these cases and suitable for local presentation is available online as Supplementary data.

Consent: The authors confirm that written consent, in line with COPE guidelines, for submission and publication of this case report including images and associated text has been obtained from the patient.#

Conflict of interest: None declared.

Funding: None declared.

References

1. Yaksh A, van der Does LJ, Lanter EA, de Groot NMs. Pharmacological therapy of tachyarrhythmias during pregnancy. *Arrhythm Electrophysiol Rev* 2016;**5**:41–44.
2. Enriquez AD, Economy KE, Tedrow UB. Contemporary management of arrhythmias during pregnancy. *Circ Arrhythm Electrophysiol* 2014;**7**:961–967.
3. Merino JL, Perez-Silva A. Tachyarrhythmias and pregnancy. eFESC 9. <https://www.escardio.org/Journals/E-Journal-of-Cardiology-Practice/Volume-9/Tachyarrhythmias-and-Pregnancy> (20 May 2011).
4. Tan HL, Lie KI. Treatment of tachyarrhythmias during pregnancy and lactation. *Eur Heart J* 2001;**22**:458–464.
5. Adamson DL, Nelson-Piercy C. Managing palpitations and arrhythmias during pregnancy. *Heart* 2007;**93**:1630–1636.
6. Jr DJ, Brost BC. Fetal bradycardia after IV adenosine for maternal PSVT. *Am J Emerg Med* 2000;**18**:234–235.
7. Elkayam U, Goodwin TM. Adenosine therapy for supraventricular tachycardia during pregnancy. *Am J Cardiol* 1995;**75**:521–523.
8. Canlorbe G, Azria E, Michel D, lung B, Mahieu-Caputo D. Menace d'accouchement prématuré après administration d'adénosine pour la réduction d'une tachycardie supraventriculaire paroxystique à 30 semaines d'aménorrhée: à propos d'un cas [Preterm labour after adenosine treatment for paroxysmal supraventricular tachycardia during pregnancy, a case report]. *Ann Fr Anesth Reanim* 2011;**30**:372–374.
9. Matsubara S, Kuwata T, Mitsuhashi T. Adenosine for maternal supraventricular tachycardia and preterm delivery. *J Obstet Gynaecol Can* 2011;**33**:794–795.
10. Fotiadou E, Vullings R. Multi-channel fetal ECG denoising with deep convolutional neural networks. *Front Pediatr* 2020;**8**:508.
11. Regitz-Zagrosek V, Roos-Hesselink JW, Bauersachs J, Blomström-Lundqvist C, Cifková R, De Bonis M, et al. 2018 ESC guidelines for the management of cardiovascular diseases during pregnancy. *Eur Heart J* 2018;**39**:3165–3241.