

The challenge of prostate biopsy guidance in the era of mpMRI detected lesion

Citation for published version (APA):

Jager, A., Vilanova, J. C., Misch, M., Wijkstra, H., & Oddens, J. R. (2022). The challenge of prostate biopsy guidance in the era of mpMRI detected lesion: ultrasound-guided versus in-bore biopsy. *British Journal of Radiology*, 95(1131), Article 20210363. <https://doi.org/10.1259/bjr.20210363>

Document license:
TAVERNE

DOI:
[10.1259/bjr.20210363](https://doi.org/10.1259/bjr.20210363)

Document status and date:
Published: 01/03/2022

Document Version:
Publisher's PDF, also known as Version of Record (includes final page, issue and volume numbers)

Please check the document version of this publication:

- A submitted manuscript is the version of the article upon submission and before peer-review. There can be important differences between the submitted version and the official published version of record. People interested in the research are advised to contact the author for the final version of the publication, or visit the DOI to the publisher's website.
- The final author version and the galley proof are versions of the publication after peer review.
- The final published version features the final layout of the paper including the volume, issue and page numbers.

[Link to publication](#)

General rights

Copyright and moral rights for the publications made accessible in the public portal are retained by the authors and/or other copyright owners and it is a condition of accessing publications that users recognise and abide by the legal requirements associated with these rights.

- Users may download and print one copy of any publication from the public portal for the purpose of private study or research.
- You may not further distribute the material or use it for any profit-making activity or commercial gain
- You may freely distribute the URL identifying the publication in the public portal.

If the publication is distributed under the terms of Article 25fa of the Dutch Copyright Act, indicated by the "Taverne" license above, please follow below link for the End User Agreement:

www.tue.nl/taverne

Take down policy

If you believe that this document breaches copyright please contact us at:

openaccess@tue.nl

providing details and we will investigate your claim.

Received:
22 March 2021

Revised:
07 July 2021

Accepted:
10 July 2021

<https://doi.org/10.1259/bjr.20210363>

Cite this article as:

Jager A, Vilanova JC, Michi M, Wijkstra H, Oddens JR. The challenge of prostate biopsy guidance in the era of mpMRI detected lesion: ultrasound-guided versus in-bore biopsy. *Br J Radiol* 2022; **95**: 20210363.

INNOVATIONS IN PROSTATE CANCER SPECIAL FEATURE : COMMENTARY

The challenge of prostate biopsy guidance in the era of mpMRI detected lesion: ultrasound-guided versus in-bore biopsy

¹AUKE JAGER, MD, ²JOAN C VILANOVA, MD, PhD, ³MASSIMO MICH, PhD, ^{1,3}HESEL WIJKSTRA, PhD and ^{1,3}JORG R ODDENS, MD, PhD

¹Department of Urology, Amsterdam University Medical Centers, University of Amsterdam, Amsterdam, The Netherlands

²Department of Radiology, Clinica Girona, Diagnostic Imaging Institute (IDI), University of Girona, Girona, Spain

³Lab of Biomedical Diagnostics, Department of Electrical Engineering, Eindhoven University of Technology, Eindhoven, The Netherlands

Address correspondence to: MR Auke Jager
E-mail: a.jager1@amsterdamumc.nl

Auke Jager and Joan C Vilanova have contributed equally to this study and should be considered as co-first authors.

ABSTRACT

The current recommendation in patients with a clinical suspicion for prostate cancer is to perform systematic biopsies extended with targeted biopsies, depending on mpMRI results. Following a positive mpMRI [i.e. Prostate Imaging Reporting and Data System (PI-RADS) ≥ 3], three targeted biopsy approaches can be performed: visual registration of the MRI images with real-time ultrasound imaging; software-assisted fusion of the MRI images and real-time ultrasound images, and in-bore biopsy within the MR scanner. This collaborative review discusses the advantages and disadvantages of each targeting approach and elaborates on future developments. Cancer detection rates seem to mostly depend on practitioner experience and selection criteria (biopsy naïve, previous negative biopsy, prostate-specific antigen (PSA) selection criteria, presence of a lesion on MRI), and to a lesser extent dependent on biopsy technique. There is no clear consensus on the optimal targeting approach. The choice of technique depends on local experience and availability of equipment, individual patient characteristics, and onsite cost-benefit analysis. Innovations in imaging techniques and software-based algorithms may lead to further improvements in this field.

INTRODUCTION

Currently, there is level 1A evidence that the addition of mpMRI and subsequent MRI-targeted biopsy (TBx) to the diagnostic pathway of prostate cancer (PCa) increases the detection of clinically significant prostate cancer (csPCa) compared to systemic biopsy (SBx) alone.¹⁻³ In case of a positive mpMRI (PI-RADS ≥ 3), the combination of both TBx and SBx finds significantly more csPCa, than either approach on its own, especially in biopsy naïve patients.^{1,2} Consequently, current guidelines strongly recommend a combined biopsy approach in this patient population. In the previous negative biopsy patient population, the additional value of SBx is less obvious, and a TBx only approach is recommended.⁴ The additional value of SBx should be carefully considered, since omitting SBx has the benefit of finding less clinically insignificant prostate cancer (ISUP Grade 1). In the

Cochrane meta-analysis, systematic biopsy detected an additional 9.8% (8.0–11.8%) ISUP Grade 1 PCa compared to the MRI-pathway.¹

In case of a negative mpMRI, the practitioner has a choice to omit biopsy or to perform only SBx. MRI is reported to have a negative predictive value of >90%; however, it still misses approximately 9% of ISUP ≥ 2 PCa.^{1,5} Consequently, omitting biopsy carries the risk of missing csPCa, whereas performing SBx carries the risk of finding clinically insignificant PCa. The choice to omit or perform SBx in this patient population should be based on the level of clinical suspicion and shared decision making.⁴ The clinical suspicion can be judged using tools, such as the “prostate cancer-risk calculator”, a tool that weights MRI results, volume, previous negative biopsies, digital rectal exam, PSA level and age.⁶

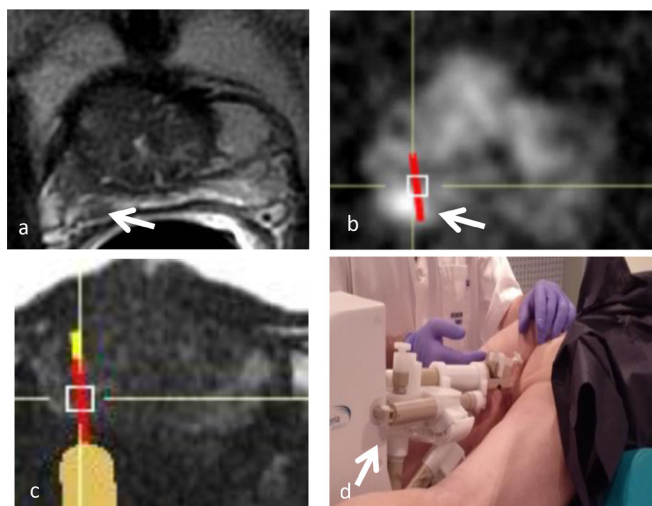
Table 1. Comparison of techniques for MRI targeted prostate biopsies

Parameter	Cognitive-TBx	Fusion-TBx	MRGB
Ease of use ⁷	1	3	4
Time-efficient ⁷	1	3	3
Real-time feedback	1	1	4
Targeting inaccuracies due to prostate deformation	2	3	5
Lesion directly visible on guidance imaging	3	3	1
Accurate lesion <10 mm targeting ⁸	3	2	1
Steep learning curve ⁹	2	3	3
Cost-effectiveness ¹⁰⁻¹³	1	2	3
MRI imaging registration	Visual	Software assisted	Visual
Possibility for systematic biopsies	Yes	Yes	No
Use by urologist	Yes	Yes	No
Robotic approach ¹⁴	Not possible	Possible	Possible

Parameters are scored on a 5-point Likert scale: 1. Extremely applicable, 2. Very applicable 3. Moderately applicable, 4. Not very applicable 5. Not at all applicable.

Scoring results are based on a combination of referred to literature and the authors' opinion and experience.

Figure 1. (a) Robotic MRI in-bore-targeted biopsy (Soteri-aTM). 62-year-old male with a PSA value of 16.6 ng ml⁻¹. Axial T2 WI shows a 6mm focal, PIRADS four lesion on the right peripheral zone (arrow). (b) The desired and planned target for the nodule is shown with restricted diffusion on DWI image (arrow). (c) Oblique axial Fast Imaging Employing Steady-State Acquisition (FIESTA) sequence shows the current position of the needle guide, represented by the orange line overlay from the needle guide with the optimal path after the remote movement of the guide. The needle track and sample core are represented by red line. (d) After the desired target for biopsy has been selected, the robotic device (arrow) is moved remotely to the target as shown (c); the table is moved out of the bore and a biopsy sample is taken with a standard compatible biopsy gun. Biopsy histopathology results showed a Gleason Score 4 + 3=7 adenocarcinoma.



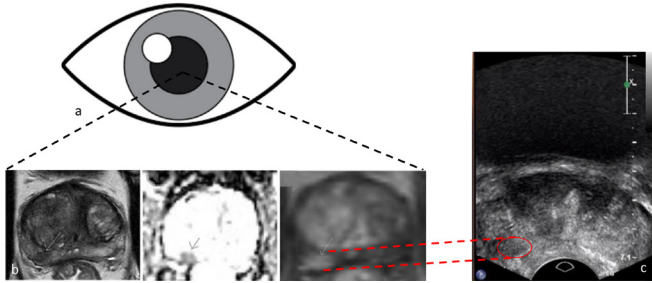
mpMRI followed by systematic and/or targeted biopsy is the currently recommended diagnostic pathway for prostate cancer detection.⁴ A current topic of discussion is which technique to use when performing MRI-targeted biopsies. Following a positive mpMRI, a practitioner can choose between three targeted biopsy techniques: in bore MRI-targeted biopsy (MRGB), ultrasound-guided fusion-targeted biopsy (fusion-TBx) or ultrasound-guided cognitive-targeted biopsy (cognitive-TBx). These three techniques show different features according to their technical characteristics (Table 1). The purpose of this collaborative commentary is to discuss the advantages and disadvantages of each targeted biopsy approach, and to elaborate on potential future developments in imaging guidance.

Biopsy techniques

In-bore MRI biopsy

In-bore MRI-guided biopsy (MRGB) uses MRI visualisation to direct the biopsy needle without image registration (Figure 1). In-bore MRGB is performed in a separate session from the diagnostic mpMRI examination. The current in-bore MRGB technique can be performed using a robotic assistance device with dedicated remote interventional software for planning purposes. The robotic technique has higher accuracy and leads to shorter MRI room occupation time compared to older systems with standard manual in-bore MRI-guided biopsy procedure.⁵ The method allows to confirm direct visibility of the needle path to the lesion on near-real-time MR images, using the same sequences as the diagnostic mpMRI examination, in order to localise the target on T2WI, DWI and ADC images. The method obtains fewer cores for each patient as only the target index lesion is biopsied. Additional sampling of a second lesion can be performed; however, it is important to note that in-bore biopsy does not support SBx.⁷ The most commonly preferred biopsy approach is transrectal, but in-gantry MR imaging-targeted

Figure 2. Cognitive-targeted biopsy. (a/b) Visual registration of a 1.1cm lesion (PIRADS 4) in the right dorsolateral peripheral zone of the midprostate. (c) Targeting of the matching anatomical location of the lesion on real-time ultrasound imaging. Histopathology showed a Gleason score 4 + 3=7 adenocarcinoma in both targeted and systematic biopsies.



prostate biopsy can also be performed using a transperineal or transgluteal approach. The transrectal procedure requires antibiotic prophylaxis without the need for local anaesthesia, for the transperineal or transgluteal approach local anaesthesia (or sedation) is necessary, but antibiotic prophylaxis can be omitted. The transgluteal approach is typically reserved for patients without rectal access and is rarely used in clinical practice.¹⁵

Ultrasound-guided biopsies

Cognitive- vs fusion-targeted biopsy

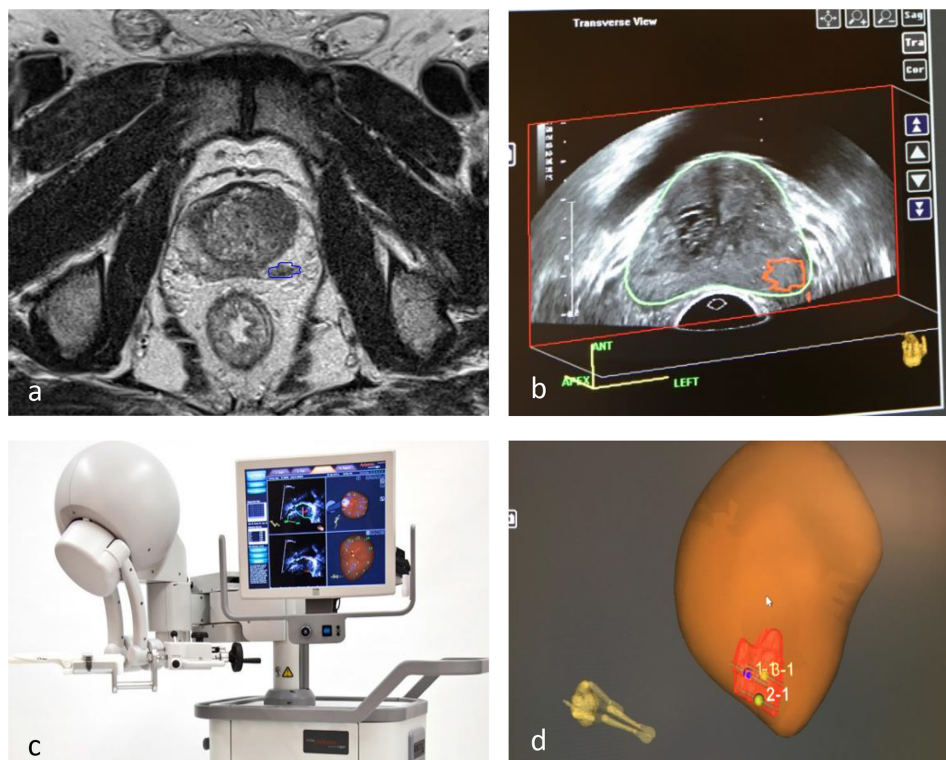
Ultrasound-guided targeted biopsies can be performed using cognitive guidance (cognitive-TBx) or with MRI-TRUS fusion software and navigation systems (fusion-TBx).

In cognitive-TBx, the practitioner visually registers the MRI lesion and uses the prostate anatomy to target this lesion on real-time US imaging (Figure 2). In fusion-TBx, the practitioner uses dedicated software to superimpose suspicious lesions detected on MRI over real-time US images and uses one of the available MRI-US fusion systems to navigate to the lesion (Figure 3). These software-based fusion platforms differ in the image registration and tracking methods. Image registration can be performed using either elastic or rigid fusion methods. It has been suggested that elastic fusion is more accurate because it accounts for prostate deformation, where rigid fusion does not. However, a meta-analysis evaluating these methods showed no difference in csPCa detection rates.¹⁶ Some platforms are available for either the transrectal and transperineal approach, others for both.

Transrectal vs transperineal approach

The prostate can be approached through either the rectal wall or the perineum. Transrectal ultrasound (US)-guided biopsy (TRUS-GB) is the standard of care for obtaining histopathological confirmation of prostate cancer. The transperineal approach has been gaining attention as a result of the associated low infection risk compared to the transrectal approach. A recent meta-analysis confirmed this association, showing a significant decrease in infectious

Figure 3. Example of MRI/TRUS fusion-targeted biopsy (Artemis™) (a) Identification and delineation of lesion on MRI. (b) MRI lesion is superimposed on US imaging. (c) Prostate biopsies are acquired with real-time ultrasound guidance. (d) Targeted biopsy locations are stored.



complications, with a relative risk of 0.55 (95% CI 0.33–0.92).¹⁷ Consequently, the 2021 EAU guideline now strongly recommends using the transperineal approach.⁴ Additionally, transperineal biopsies are reported to lead to superior sampling of the apex as well as the anterior prostate. If this results in higher cancer detection rates (CDR), however, remains to be proven.¹⁸

DISCUSSION

Comparing targeted biopsy techniques

Diagnostic accuracy

First, it is important to look at the diagnostic accuracy. A meta-analysis comparing the three techniques, which included 43 studies with a total of 2497 patients found no significant advantage of any particular technique for csPCa detection.¹⁹ Another meta-analysis, comparing only fusion- and cognitive-TBx using 1714 men from nine studies, concluded there was a trend toward improved csPCa detection rates for fusion-TBx; however, this was not statistically significant.²⁰ Because the studies included in both meta-analyses had small sample sizes and were subject to significant heterogeneity, the results need to be interpreted with caution. In a more recent study, Costa et al evaluated biopsy results from a mixed (prior negative and biopsy naïve) cohort, with MRGB ($n = 103$) performing significantly better than TBx combined with SBx ($N = 300$), reporting csPCa detection rates of 61 and 47%, respectively.²¹ The same group, using a partly overlapping cohort, found significantly more Grade Group upgrading when matching radical prostatectomy histopathology to biopsy results in the TBx/SBx group (27.7%) compared to MRBG (13%).²² The results of these studies show a clear advantage in diagnostic accuracy for MRGB. However, it is difficult to say if these results can be extrapolated to general practice, considering both trials originated from a single centre and have a non-randomised and retrospective design.

In the prior negative biopsy patient population, two randomised-controlled trials evaluated detection rates of the different biopsy techniques. In the FUTURE trial, 234 men with a prior negative biopsy result and a positive mpMRI (PIRADS ≥ 3) were randomised to cognitive-TBx, fusion TBx or MRGB. This study found no significant differences in diagnostic accuracy, with csPCa detection rates of 33.3%, 34.2 and 33.5%, respectively.²³ Arsov et al⁸ randomised 210 patients and also did not find a significant difference, reporting csPCa detection rates of 29% for MRBG and 26% for fusion-TBx.

Operator experience

A factor that does seem to be of importance is the experience of the operator performing a certain biopsy technique, being an independent predictor for csPCa detection in SBx as well as TBx with odds ratios up to 2.40.²⁴

Possibility for systematic biopsies

Another factor to take into account is whether or not SBx is indicated, considering that MRGB does not support a systematic biopsy approach. This may be an issue in biopsy naïve patients where SBx leads to significantly more csPCa detection (4.3–5.0%)¹

Cost-effectiveness

When looking at the financial aspects, multiple studies have shown cost-effectiveness of the MRI pathway (MRI followed by targeted biopsy) compared to SBx.^{10–12} When comparing the three targeting techniques, fusion TBx and MRGB are both more expensive than cognitive-TBx, since they require additional planning, guidance material and time.¹³ Nevertheless, all three techniques provide a cost-effective strategy, because they improve disease stratification and facilitate more appropriate patient selection for prostate biopsies.¹⁹ Better patient selection avoids unnecessary biopsies and can possibly reduce the number of biopsy cores (in TBx only or saturation targeted biopsy (sTB) strategies), leading to a reduction in pathology costs.^{25,26} Additionally, it leads to a decrease in insignificant PCa detection and, therefore, alleviates the patient burden and healthcare costs associated with active surveillance.^{1–3,10,11}

Targeting small lesions (<10mm)

One of the key factors for accurate targeted biopsy is reaching small lesions in specific and difficult to reach (*e.g.*, lateral or anterior) locations. In-bore MRI-guided biopsy can be performed using a software-guided robotic device, allowing for precise target (<10 mm) localisation within any area of the prostate. A similar robotic device is available for US, allowing for pre-programmed biopsy schemes.²⁷ Robotic assistance is currently not widely used; future development might lead to increased accuracy and could decrease the current role of operator experience.²⁴

Targeting inaccuracies

Finally, it is important to consider that, when applying the US-guided biopsy approach, targeting inaccuracies can occur due to prostate deformation, patient positioning, mismatching of imaging planes and, in case of cognitive-TBx, incorrect visual registration. Several MRI-US fusion platforms have been developed to minimise the impact of these issues. Whether one of these platforms has an advantage over the others, or over cognitive-TBx, remains to be proven. A systematic review evaluating a variety of different fusion platforms, could not find significant difference in cancer detection rates (CDR) between them.²⁸ Evidence on CDR of fusion-TBx versus cognitive-TBx is conflicting, with some studies finding no difference and others finding improved CDR for fusion-TBx.^{20,29–31} The benefit of fusion TBx, as well as in-bore biopsy, compared to cognitive-TBx might be more apparent in lesions < 10 mm.³¹ In addition to accurate targeting, raising the number of targeted biopsy cores improves CDR in smaller lesions. The use of sTB templates, in which 10–20 cores are obtained from the lesion and adjacent sectors, shows promising results. Two recent single centre trials showed that sTB had detection rates of 91 and 99% for csPCa compared to TBx combined with SBx.^{13,25} Targeting inaccuracies as a result of image fusion could theoretically be solved by using US as the diagnostic imaging modality, instead of mpMRI. However, conventional greyscale US lacks the diagnostic accuracy to compete with mpMRI. Having said that, novel US modalities, such as micro-ultrasound and computer-aided quantification dispersion imaging (CUDI), have shown great improvements in PCa detection. These novel ultrasound modalities will be further discussed below.

Future perspectives: developments in ultrasound
Considering most biopsy guidance is performed using ultrasound imaging, it is interesting to elaborate on the idea of using advances ultrasound imaging as the diagnostic imaging modality for PCa. If diagnostic accuracy is sufficient, the use of one of these US modalities as biopsy guidance would resolve targeting inaccuracies caused by image fusion errors.

Micro-ultrasound, operating at high frequency (29 MHz), leads to improved resolution and more detailed prostate imaging. The micro-US system (ExactVu) supports MRI-micro-US fusion and initial evaluations show promising results.³² In a recent, multicentre trial, 1040 patients with a clinical suspicion for PCa underwent mpMRI and high-resolution micro-ultrasound before prostate biopsies. Micro-ultrasound reached a sensitivity of 94% for GG \geq 2 PCa compared to 90% in mpMRI. In this study, however, most clinical operators were not blinded for mpMRI results when performing the US targeting, thereby introducing a major source of bias.³³

Another US modality showing promising results is shear wave elastography (SWE). SWE visualises and quantifies solid lesions in soft tissue.³⁴ Studies evaluating SWE, using radical prostatectomy specimens as the reference standard, showed a direct relation between tissue stiffness and presence of PCa, with stiffness (measured as Young's Module) increasing with higher Gleason Grades.^{35,36} A systematic review on 2277 patients originating from 16 studies, showed specificities and sensitivities for PCa detection ranging from 0.69 to 0.85 and 0.71–0.87, respectively.³⁷

Finally, Contrast-Enhanced Ultrasound (CEUS) and its derivative imaging technique Contrast Ultrasound Dispersion Imaging

(CUDI) have also shown great potential in PCa detection. The applicability of CEUS and CUDI in prostate cancer detection is based on visualisation and quantification of abnormalities in the microvascular architecture. Angiogenesis, necessary for PCa growth and progression, causes alternations in the microvascular structures.³⁸ These alternations lead to abnormalities in dispersion and perfusion of the ultrasound contrast agent (UCA) that can be visualised with CEUS. The head-to-head trial comparing CUDI-TBx, mpMRI-TBx and SBx found that CUDI-TBx and mpMRI had comparable detection rates, finding 28 and 29% cSPCa, respectively.³⁹

A major limitation of ultrasound, including SWE, CEUS and CUDI, have been its 2D image acquisition. Advances in US technology have now made it possible to make rapid 3D acquisition, thereby facilitating visualisation of the whole prostate using one bolus of intravascular contrast.^{14,40} By combining multiple US modalities some studies have shown that this multiparametric approach leads to an increase in diagnostic accuracy.^{41,42} This year, a multicenter trial (NCT04605276) will commence to further improve the CUDI-algorithm for 3D multiparametric ultrasound. Future clinical validation trials will have to provide further evidence for both novel US modalities to become standard diagnostic and biopsy guidance imaging modalities.

CONCLUSION

Based on the available data, a definitive answer to which is the optimal biopsy technique cannot be given. Ultimately, the choice should rely on local experience and availability of equipment. The selection of patients based on their individual characteristics and onsite cost-benefit analysis are of utmost importance as well. The development of novel imaging techniques may lead to further shifts in this important diagnostic pathway.

REFERENCES

1. Drost F-JH, Osses D, Nieboer D, Bangma CH, Steyerberg EW, Roobol MJ, et al. Prostate magnetic resonance imaging, with or without magnetic resonance Imaging-targeted biopsy, and systematic biopsy for detecting prostate cancer: a Cochrane systematic review and meta-analysis. *Eur Urol* 2020; 77: 78–94. Epub 2019 Jul 18PMID. doi: <https://doi.org/10.1016/j.eururo.2019.06.023>
2. Rouvière O, Puech P, Renard-Penna R, Claudon M, Roy C, Mège-Lechevallier F, et al. Use of prostate systematic and targeted biopsy on the basis of multiparametric MRI in biopsy-naive patients (MRI-FIRST): a prospective, multicentre, paired diagnostic study. *Lancet Oncol* 2019; 20: 100–9. doi: [https://doi.org/10.1016/S1470-2045\(18\)30569-2](https://doi.org/10.1016/S1470-2045(18)30569-2)
3. van der Leest M, Cornel E, Israël B, Hendriks R, Padhani AR, Hoogenboom M, et al. Head-To-Head comparison of transrectal ultrasound-guided prostate biopsy versus multiparametric prostate resonance imaging with subsequent magnetic resonance-guided biopsy in Biopsy-naïve men with elevated prostate-specific antigen: a large prospective multicenter clinical study. *Eur Urol* 2019; 75: 570–8. doi: <https://doi.org/10.1016/j.eururo.2018.11.023>
4. Mottet N, Bellmunt J, Briers E, Bolla M, Bourke L, Cornford P. *Members of the EAU – ESTRO – ESUR – SIOG prostate cancer guidelines panel. EAU – ESTRO – ESUR – SIOG guidelines on prostate cancer. EDN. Presented at the EAU annual Congress Milan 2021. 978-94-92671-13-4.* Arnhem, The Netherlands: EAU guidelines office; 2021.
5. Sathianathan NJ, Omer A, Harriss E, Davies L, Kasivisvanathan V, Punwani S, et al. Negative predictive value of multiparametric magnetic resonance imaging in the detection of clinically significant prostate cancer in the prostate imaging reporting and data system era: a systematic review and meta-analysis. *Eur Urol* 2020; 78: 402–14. Epub 2020 May 20PMID. doi: <https://doi.org/10.1016/j.eururo.2020.03.048>
6. SWOP. The prostate cancer risk calculators – including the 'future risk' calculator. 2021. Available from: <http://www.prostatecancer-riskcalculator.com/seven-prostate-cancer-risk-calculators>.
7. Vilanova JC, Pérez de Tudela A, Puig J, Hoogenboom M, Barceló J, Planas M, et al. Robotic-Assisted transrectal MRI-guided biopsy: technical feasibility and role in the current diagnosis of prostate cancer: an initial single-center experience. *Abdom Radiol* 2020; 45: 4150–9. doi: <https://doi.org/10.1007/s00261-020-02665-6>
8. Arsov C, Rabenalt R, Blondin D, Quentin M, Hiester A, Godehardt E, et al. Prospective

- randomized trial comparing magnetic resonance imaging (MRI)-guided in-bore biopsy to MRI-ultrasound fusion and transrectal ultrasound-guided prostate biopsy in patients with prior negative biopsies. *Eur Urol* 2015; **68**: 713–20. doi: <https://doi.org/10.1016/j.eururo.2015.06.008>
9. Kasabwala K, Patel N, Cricco-Lizza E, Shimpi AA, Weng S, Buchmann RM, et al. The learning curve for magnetic resonance Imaging/Ultrasound Fusion-guided prostate biopsy. *Eur Urol Oncol* 2019; **2**: 135–40. doi: <https://doi.org/10.1016/j.euo.2018.07.005>
 10. Pahwa S, Schiltz NK, Ponsky LE, Lu Z, Griswold MA, Gulani V. Cost-Effectiveness of Mr imaging-guided strategies for detection of prostate cancer in Biopsy-Naive men. *Radiology* 2017; **285**: 157–66. doi: <https://doi.org/10.1148/radiol.2017162181>
 11. Panebianco V, Valerio MC, Giuliani A, Pecoraro M, Ceravolo I, Barchetti G, et al. Clinical utility of multiparametric magnetic resonance imaging as the first-line tool for men with high clinical suspicion of prostate cancer. *Eur Urol Oncol* 2018; **1**: 208–14. doi: <https://doi.org/10.1016/j.euo.2018.03.008>
 12. de Rooij M, Crienen S, Witjes JA, Barentsz JO, Rovers MM, Grutters JPC. Cost-Effectiveness of magnetic resonance (Mr) imaging and MR-guided targeted biopsy versus systematic transrectal ultrasound-guided biopsy in diagnosing prostate cancer: a modelling study from a health care perspective. *Eur Urol* 2014; **66**: 430–6. doi: <https://doi.org/10.1016/j.eururo.2013.12.012>
 13. Altok M, Kim B, Patel BB, Shih Y-CT, Ward JF, McRae SE, et al. Cost and efficacy comparison of five prostate biopsy modalities: a platform for integrating cost into novel-platform comparative research. *Prostate Cancer Prostatic Dis* 2018; **21**: 524–32. doi: <https://doi.org/10.1038/s41391-018-0056-7>
 14. Schalk SG, Demi L, Smeenge M, Mills DM, Wallace KD, de la Rosette JJMCH, et al. 4-D spatiotemporal analysis of ultrasound contrast agent dispersion for prostate cancer localization: a feasibility study. *IEEE Trans Ultrason Ferroelectr Freq Control* 2015; **62**: 839–51. doi: <https://doi.org/10.1109/TUFFC.2014.006907>
 15. Caglic I, Breznik S, Matela J, Barrett T. Lesion targeted CT-guided Transgluteal prostate biopsy in combination with Prebiopsy MRI in patients without rectal access. *Urol Case Rep* 2017; **10**: 6–8. doi: <https://doi.org/10.1016/j.eucr.2016.09.008>
 16. Venderink W, de Rooij M, Sedelaar JPM, Huisman HJ, Fütterer JJ. Elastic versus rigid image registration in magnetic resonance Imaging-transrectal ultrasound fusion prostate biopsy: a systematic review and meta-analysis. *Eur Urol Focus* 2018; **4**: 219–27. doi: <https://doi.org/10.1016/j.euf.2016.07.003>
 17. Prader B, Veeratterapillay R, Dimitropoulos K, Yuan Y, Omar MI, MacLennan S, et al. Nonantibiotic strategies for the prevention of infectious complications following prostate biopsy: a systematic review and meta-analysis. *J Urol* 2021; **205**: 653–63. doi: <https://doi.org/10.1097/JU.0000000000001399>
 18. Tu X, Liu Z, Chang T, Qiu S, Xu H, Bao Y, et al. Transperineal magnetic resonance Imaging-Targeted biopsy may perform better than transrectal route in the detection of clinically significant prostate cancer: systematic review and meta-analysis. *Clin Genitourin Cancer* 2019; **17**: e860–70. doi: <https://doi.org/10.1016/j.clgc.2019.05.006>
 19. Wegelin O, van Melick HHE, Hooft L, Bosch JHR, Reitsma HB, Barentsz JO, et al. Comparing three different techniques for magnetic resonance Imaging-targeted prostate biopsies: a systematic review of In-bore versus magnetic resonance Imaging-transrectal ultrasound fusion versus cognitive registration. is there a preferred technique? *Eur Urol* 2017; **71**: 517–31. doi: <https://doi.org/10.1016/j.eururo.2016.07.041>
 20. Watts KL, Frechette L, Muller B, Ilinksy D, Kovac E, Sankin A, et al. Systematic review and meta-analysis comparing cognitive vs. image-guided fusion prostate biopsy for the detection of prostate cancer. *Urol Oncol* 2020; **38**: 734.e19–734.e25. doi: <https://doi.org/10.1016/j.urolonc.2020.03.020>
 21. Costa DN, Goldberg K, Leon ADde, Lotan Y, Xi Y, Aziz M, et al. Magnetic resonance imaging-guided In-bore and magnetic resonance Imaging-transrectal ultrasound fusion targeted prostate biopsies: an adjusted comparison of clinically significant prostate cancer detection rate. *Eur Urol Oncol* 2019; **2**: 397–404. doi: <https://doi.org/10.1016/j.euo.2018.08.022>
 22. Costa DN, Cai Q, Xi Y, Recchimuzzi DZ, Subramanian N, Bagrodia A, et al. Gleason grade group concordance between preoperative targeted biopsy and radical prostatectomy histopathologic analysis: a comparison between In-Bore MRI-guided and MRI-Transrectal us fusion prostate biopsies. *Radiol Imaging Cancer* 2021; **3**: e200123. doi: <https://doi.org/10.1148/rycan.2021200123>
 23. Wegelin O, Exterkate L, van der Leest M, Kummer JA, Vreuls W, de Bruin PC, et al. The future trial: a multicenter randomised controlled trial on target biopsy techniques based on magnetic resonance imaging in the diagnosis of prostate cancer in patients with prior negative biopsies. *Eur Urol* 2019; **75**: 582–90. doi: <https://doi.org/10.1016/j.eururo.2018.11.040>
 24. Tadtayev S, Hussein A, Carpenter L, Vasdev N, Boustead G. The association of level of practical experience in transrectal ultrasonography guided prostate biopsy with its diagnostic outcome. *Ann R Coll Surg Engl* 2017; **99**: 218–23. doi: <https://doi.org/10.1308/rcsann.2016.0308>
 25. Hansen NL, Barrett T, Lloyd T, Warren A, Samel C, Bratt O, et al. Optimising the number of cores for magnetic resonance imaging-guided targeted and systematic transperineal prostate biopsy. *BJU Int* 2020; **125**: 260–9. doi: <https://doi.org/10.1111/bju.14865>
 26. Tschirdewahn S, Wiesenfarth M, Bonekamp D, Püllen L, Reis H, Panic A, et al. Detection of significant prostate cancer using target saturation in Transperineal magnetic resonance Imaging/Transrectal Ultrasonography-fusion biopsy. *Eur Urol Focus* 2020; **10** Jul 2020. doi: <https://doi.org/10.1016/j.euf.2020.06.020>
 27. Miah S, Servian P, Patel A, Lovegrove C, Skelton L, Shah TT, et al. A prospective analysis of robotic targeted MRI-US fusion prostate biopsy using the centroid targeting approach. *J Robot Surg* 2020; **14**: 69–74. doi: <https://doi.org/10.1007/s11701-019-00929-y>
 28. Gayet M, van der Aa A, Beerlage HP, Schrier BP, Mulders PFA, Wijkstra H. The value of magnetic resonance imaging and ultrasonography (MRI/US)-fusion biopsy platforms in prostate cancer detection: a systematic review. *BJU Int* 2016; **117**: 392–400. doi: <https://doi.org/10.1111/bju.13247>
 29. Yamada Y, Shiraishi T, Ueno A, Ueda T, Fujihara A, Naitoh Y, et al. Magnetic resonance imaging-guided targeted prostate biopsy: comparison between computer-software-based fusion versus cognitive fusion technique in biopsy-naïve patients. *Int J Urol* 2020; **27**: 67–71. doi: <https://doi.org/10.1111/iju.14127>
 30. Monda SM, Vetter JM, Andriole GL, Fowler KJ, Shetty AS, Weese JR, et al. Cognitive versus software fusion for MRI-targeted biopsy: experience before and after implementation of fusion. *Urology* 2018; **119**: 115–20. doi: <https://doi.org/10.1016/j.urology.2018.06.011>
 31. Marra G, Ploussard G, Fütterer J, Valerio M, .EAU-YAU Prostate Cancer Working Party Controversies in MR targeted biopsy: alone or combined, cognitive versus software-based fusion, transrectal versus transperineal approach? *World J Urol* 2019; **37**: 277–87.

- doi: <https://doi.org/10.1007/s00345-018-02622-5>
32. Wiemer L, Hollenbach M, Heckmann R, Kittner B, Plage H, Reimann M, et al. Evolution of targeted prostate biopsy by adding Micro-Ultrasound to the magnetic resonance imaging pathway. *Eur Urol Focus* 2020;09 Jul 2020. doi: <https://doi.org/10.1016/j.euf.2020.06.022>
 33. Klotz L, Lughezzani G, Maffei D, Sánchez A, Pereira JG, Staerman F, et al. Comparison of micro-ultrasound and multiparametric magnetic resonance imaging for prostate cancer: a multicenter, prospective analysis. *Can Urol Assoc J* 2021; **15**: E11–16. doi: <https://doi.org/10.5489/cuaj.6712>
 34. Bercoff J, Chaffai S, Tanter M, Sandrin L, Catheline S, Fink M, et al. In vivo breast tumor detection using transient elastography. *Ultrasound Med Biol* 2003; **29**: 1387–96. doi: [https://doi.org/10.1016/S0301-5629\(03\)00978-5](https://doi.org/10.1016/S0301-5629(03)00978-5)
 35. Boehm K, Salomon G, Beyer B, Schiffmann J, Simonis K, Graefen M, et al. Shear wave elastography for localization of prostate cancer lesions and assessment of elasticity thresholds: implications for targeted biopsies and active surveillance protocols. *J Urol* 2015; **193**: 794–800. doi: <https://doi.org/10.1016/j.juro.2014.09.100>
 36. Rouvière O, Melodelima C, Hoang Dinh A, Bratan F, Pagnoux G, Sanzalone T, et al. Stiffness of benign and malignant prostate tissue measured by shear-wave elastography: a preliminary study. *Eur Radiol* 2017; **27**: 1858–66. doi: <https://doi.org/10.1007/s00330-016-4534-9>
 37. Anbarasan T, Wei C, Bamber JC, Barr RG, Nabi G. Characterisation of prostate lesions using transrectal shear wave elastography (swe) ultrasound imaging: a systematic review. *Cancers* 2021; **13**: 122. doi: <https://doi.org/10.3390/cancers13010122>
 38. Russo G, Mischi M, Scheepens W, De la Rosette JJ, Wijkstra H. Angiogenesis in prostate cancer: onset, progression and imaging. *BJU Int* 2012; **110**(11 Pt C): E794–808. doi: <https://doi.org/10.1111/j.1464-410X.2012.11444.x>
 39. Mannaerts CK, Engelbrecht MRW, Postema AW, van Kollenburg RAA, Hoeks CMA, Savci Heijink CD. Detection of clinically significant prostate cancer in biopsy-naïve men: head-to-head comparison of systematic biopsy, multiparametric MRI- and contrast ultrasound dispersion imaging-targeted biopsy. *BJU Int* 2020; **378**: 1767.
 40. Wildeboer RR, Van Sloun RJG, Schalk SG, Mannaerts CK, Van Der Linden JC, Huang P, et al. Convective-Dispersion modeling in 3D Contrast-Ultrasound imaging for the localization of prostate cancer. *IEEE Trans Med Imaging* 2018; **37**: 2593–602. doi: <https://doi.org/10.1109/TMI.2018.2843396>
 41. Wildeboer RR, Postema AW, Demi L, Kuenen MPJ, Wijkstra H, Mischi M. Multiparametric dynamic contrast-enhanced ultrasound imaging of prostate cancer. *Eur Radiol* 2017; **27**: 3226–34. doi: <https://doi.org/10.1007/s00330-016-4693-8>
 42. Postema A, Mischi M, de la Rosette J, Wijkstra H. Multiparametric ultrasound in the detection of prostate cancer: a systematic review. *World J Urol* 2015; **33**: 1651–9. doi: <https://doi.org/10.1007/s00345-015-1523-6>