Non-invasive electrophysiologic measurements of the fetus during pregnancy and labor

Non-invasive electrophysiologic measurements of the fetus during pregnancy and labor

Carlijn Lempersz

Non-invasive electrophysiologic measurements of the fetus during pregnancy and labor

Carlijn Lempersz

A catalogue record is available from the Eindhoven University of Technology Library.

ISBN: 978-94-6416-476-3
Cover and layout: Jet Kiks-Schaap, @beaubyjet
Layout: Yasmin Katlich, persoonlijkproefschrift.nl
Printed by: Ridderprint, the Netherlands

Financial support for this thesis has been kindly provided by: University of Technology Eindhoven, Máxima Medisch Centrum, Nemo Healthcare BV.

Non-invasive electrophysiologic measurements of the fetus during pregnancy and labor

PROEFSCHRIFT

ter verkrijging van de graad van doctor aan de Technische Universiteit Eindhoven, op gezag van de rector magnificus prof.dr.ir. F.P.T. Baaijens,
voor een commissie aangewezen door het College voor Promoties, in het openbaar te verdedigen op vrijdag 19 maart 2020 om 13:30 uur

door

Carlijn Lempersz

geboren te Meppel

Dit proefschrift is goedgekeurd door de promotoren en de samenstelling van de promotiecommissie is als volgt:

voorzitter:	prof.dr.ir. A.B. Smolders
1e promotor:	prof.dr. S.G. Oei
copromotor(en):	dr. J.O.E.H. van Laar
	dr.ir. R. Vullings
leden:	prof.dr.ir. J.W.M. Bergmans
	prof.dr. S.A. Scherjon (UMCG)
	dr. D. Ayres-de-Campos (Universidade de Lisboa)
	dr. M.E.M.H. Westerhuis (Máxima Medisch Centrum)
	prof.dr. Y. Jacquemyn (Universitair Ziekenhuis Antwerpen)
adviseur(s):	dr. M.C. Haak (LUMC)
	dr. S.A.B. Clur (Amsterdam UMC)

Het onderzoek of ontwerp dat in dit proefschrift wordt beschreven is uitgevoerd in overeenstemming met de TU/e Gedragscode Wetenschapsbeoefening.

TABLE OF CONTENTS

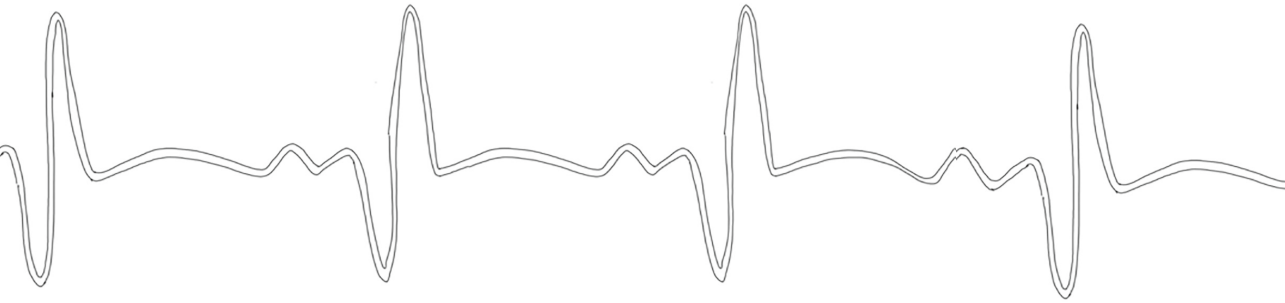

CHAPTER 1

General introduction

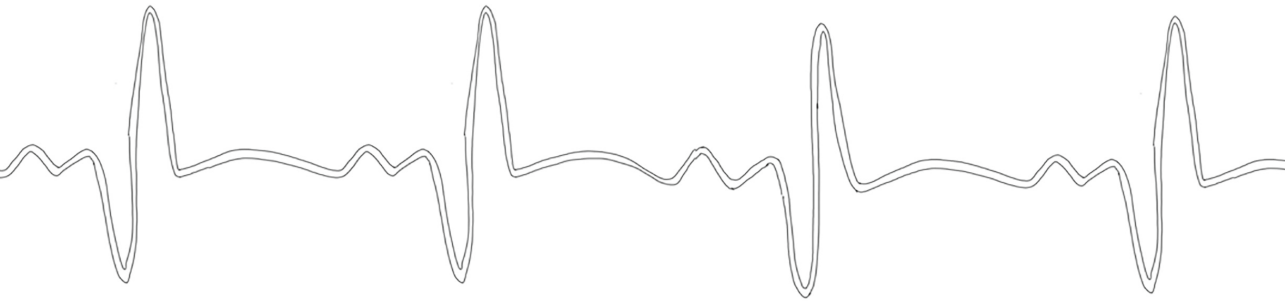

During pregnancy the fetus is safely tucked away in the womb, surrounded by the mother. This is to protect the fetus and give it a safe environment to grow. For monitoring and evaluating fetal health, this comes with challenges, as possibilities to obtain information from the fetus are limited. Over the years multiple techniques have been developed for imaging or monitoring of the fetus. The most common method for fetal imaging is ultrasound. This technique has been used for many years and over time the imaging quality has become better. Fetal monitoring during pregnancy and labor in secondary care is most often done by means of registering a cardiotocogram (CTG). A CTG monitors the fetal heart rate (FHR) and uterine contractions. Unfortunately, ultrasound and CTG have their shortcomings. New techniques are being developed to overcome those shortcomings. A potential new technique that could complement ultrasound and CTG is non-invasive electrophysiology. From these measurements a fetal electrocardiogram (ECG) can be calculated.

Below, a short introduction in the physiology of the fetal circulation and congenital heart disease (CHD) will be given. Furthermore, the current way of imaging and monitoring of the fetus during pregnancy and labor is described in more detail.

Fetal circulation

The fetal heart is the first functioning organ during fetal life and starts beating as early as the fourth week of gestation. By the end of week 8-10 of gestation the heart is developed.[1] What started as a flat disc is formed into a three-dimensional functioning heart by a multitude of cascading actions and reactions. Where pregnancy continues the heart grows and further adapts to the needs of the fetus. Figure 1. shows an overview of the developing heart over time during the first weeks of pregnancy.

The fetal circulation differs from that of a neonate in postpartum life. During fetal life the circulation has three shunts to distribute the oxygenated blood from the placenta more efficiently through the developing fetal body. The oxygen rich blood from the placenta enters via the umbilical vein and continues its way towards the first shunt, the ductus venosus. This way a majority of the blood bypasses the liver and flows into the vena cava inferior. From there the blood continues its way to the right atrium. The foramen ovale between the right and left atrium is the second shunt. To bypass the lungs, the majority of the blood will flow from the right atrium through the foramen ovale into the left atrium. The blood is then transported into the left ventricle and continues its path into the aorta. Blood that is transported from the right atrium towards the right ventricle into the pulmonary artery can shunt through the ductus arteriosus in the aorta, leaving only 12% of the total blood flow to the lungs.[2] Figure 2 illustrates the fetal blood circulation with its three shunts.

During pregnancy the pulmonary circulation and the systemic circulation are in parallel. After birth, both circulations will adapt to circulations in series.[3] When the

child is born the blood transport through the placenta is ceased. This change causes an increase in systemic vascular resistance, inducing an increase in aortic pressure and an increase in the left ventricle and atrial pressure. Furthermore, the pulmonary vascular resistance decreases after the first breath. During pregnancy the blood vessels in the lungs are compressed due to low pressure and because there is a relative hypoxia in the lungs causing vasoconstriction of the pulmonary blood vessels. By taking the first breath the hypoxia is resolved, canceling the vasoconstriction. Combined with the decreased vascular resistance, the pulmonary arterial pressure and the pressure in the right ventricle and right atrium will decrease. The relatively low pressure in the right atrium compared to the higher pressure in the left atrium causes the blood to flow in the opposite direction through the foramen ovale. The valve on the left side of the foramen ovale is pressed against the atrial septum, closing the foramen ovale. Closure of the ductus arteriosus is thought to be caused by the increase in oxygenation of the blood.[2] The pulmonary arterial pressure decreases and the aortic pressure increases causing the oxygen rich blood to flow from the aorta through the ductus arteriosus. The increased oxygen pressure in the blood causes the ductus arteriosus to constrict. One to eight days after birth the ductus arteriosus is closed in most cases. The reason behind the closure of the ductus venosus is not completely understood. It may be caused by the fact that after birth the blood flow through the umbilical vessels is completely ceased. In newborns it is seen that one to three hours after birth the ductus venosus is constricted, causing the blood to no longer bypass the liver as it did in fetal life.[2]

Figure 1. Timeline of the development of the human heart

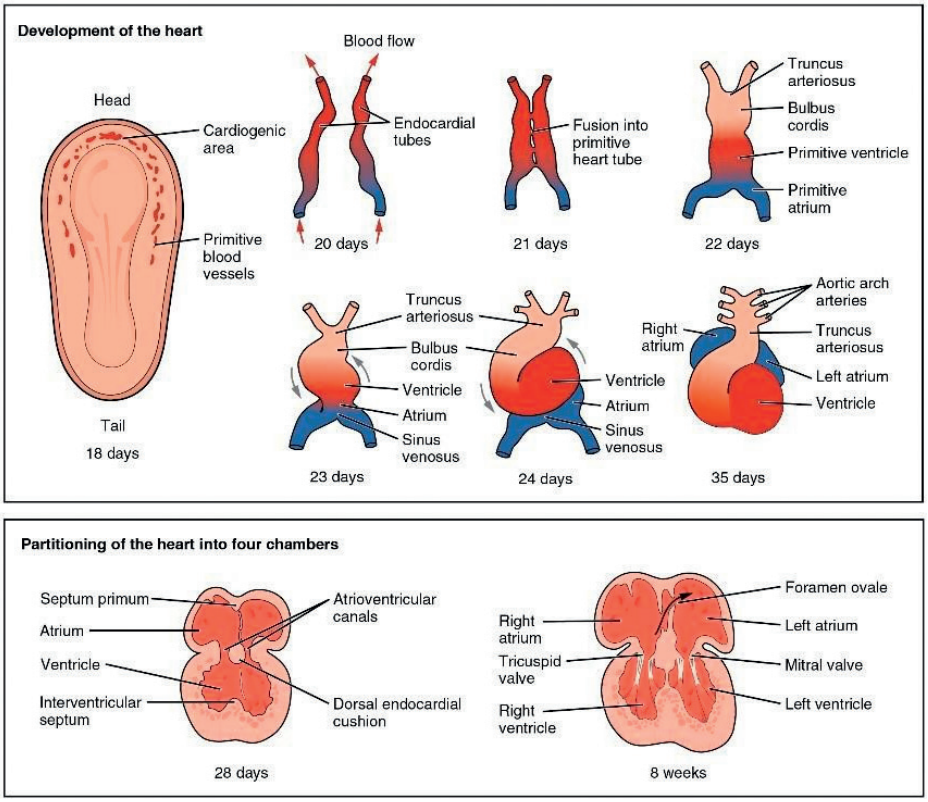

Adapted from: Anatomy & Physiology[4]

Figure 2. The fetal circulation

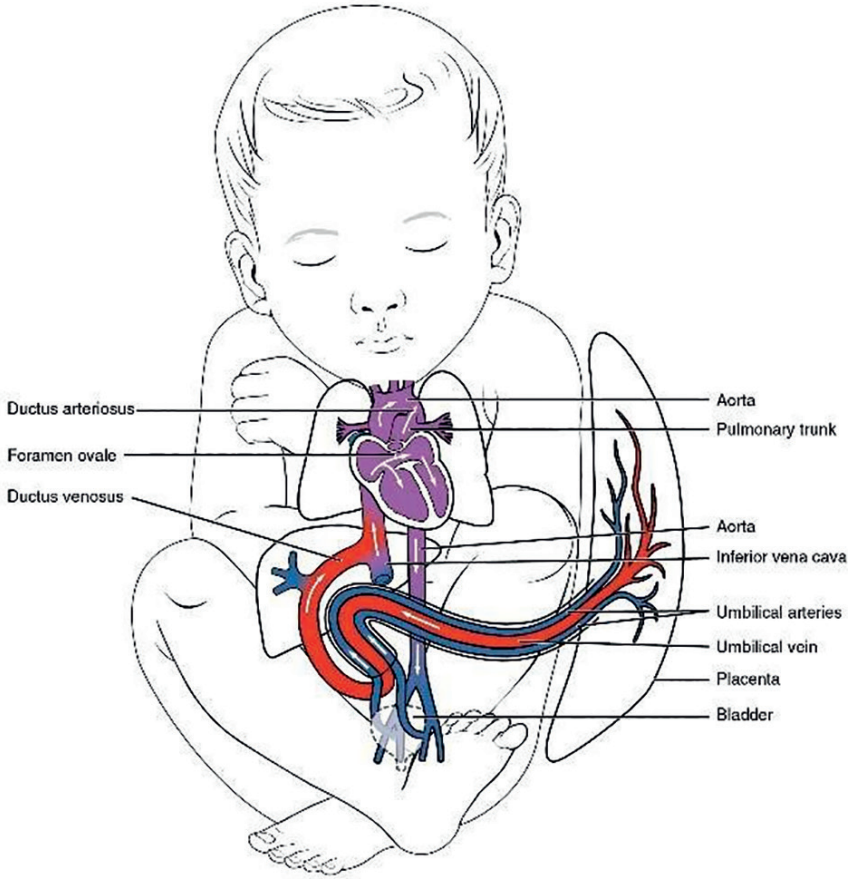

Adapted from: Anatomy & Physiology[5]

Congenital heart disease

In congenital heart disease (CHD) there is a structural defect of the heart or vessels close to the heart. CHD is one of the most common congenital anomalies that occurs in about 8 per 1000 live births.[6–8] 4 per 1000 live births have severe cardiac defects that are incompatible with life and/or need intervention.[9,10]

CHD may be caused by genetic abnormalities, such as trisomy's (e.g. trisomy 21), single gene mutations and small chromosomal deletions/additions (e.g. 22q11.2). For example, about 40% of the patients with Down syndrome have a known CHD.[11] Children born to a mother and/or father with a CHD have an increased risk to develop a CHD.[11] Environmental factors that are known to increase the risk for developing CHD are teratogens, metabolic factors and infections. Teratogens like certain medications (e.g.

lithium, paroxetine) and alcohol abuse during pregnancy give an increased risk for developing CHD. Metabolic factors include diabetes, lupus erythematosus and obesity. From certain infections in the first trimester of pregnancy it is also known that they lead to a higher risk for developing CHD, such as rubella and toxoplasmosis.[11–15]

One can divide CHD into three categories.

- Defects that cause right-to-left shunting. Also called cyanotic congenital heart disease. Examples of defects in this category are Tetralogy of Fallot, transposition of the great arteries, tricuspid atresia and anomalous pulmonary venous connection.
- Defects that cause left-to-right shunting. Atrial septum defects, ventricular septum defects and atrioventricular septal defects are examples of defects in this category.
- Defects that cause an obstruction. For example coarctation of the aorta, pulmonary stenosis/atresia, aortic stenosis/atresia.[11]

Fetal imaging and fetal monitoring

Ultrasound

As mentioned earlier, the fetus is located underneath several layers of tissue which complicates fetal imaging. Fortunately, ultrasound examination enables the clinician to make images of the fetus. In most developed countries pregnant women undergo a fetal anomaly scan in mid-pregnancy. Here, the fetus is checked for multiple anomalies, amongst others anomalies of the heart. In mid-pregnancy the heart is only 1/10th of the size of an adult heart which complicates the imaging. Furthermore, the fetus is able to move and the heart is a beating organ making evaluation of the heart more difficult. Other factors that may influence the quality of the ultrasound examination is maternal body mass index (BMI), the position of the fetus, amount of amniotic fluid and the experience of the sonographer.[16–24]

Standardization of the fetal anomaly scan with the addition of the four chamber view and three vessel view increased detection rates for CHD, which are now 40-60% for routine screening and may rise to 89% in tertiary care centers.[25,26] However, only 10% of the mothers with increased risk for carrying a fetus with CHD are seen in tertiary care hospitals.[27] Prenatal diagnosis improves morbidity and mortality.[28,29] Early diagnosis gives the parents and caregivers time to plan and prepare for delivery in a specialized hospital. Also, it gives room for potential fetal surgery. Furthermore, if diagnosed before the 24th week of gestation parents can opt for termination of pregnancy in case of severe CHD. This makes that there is a need for an additional tool to help screen for and diagnose CHD. Half a century ago, the potential use of the fetal ECG in diagnosing CHD was described by Depasquale et al..[30] In this thesis the potential added value of the fetal ECG will be further explored.

Cardiotocography

Monitoring the fetal heart rate (FHR) and uterine contractions is currently done by means of CTG monitoring. The two most common ways to retrieve the FHR for CTG monitoring is non-invasively via doppler ultrasound (DU) and invasively via a fetal scalp electrode (FSE). The CTG shows the FHR variations and uterine activity over time. Figure 3 shows an example of a CTG registration.

DU uses a button on the maternal abdomen that is held in place with an elastic bands. This button uses Doppler Ultrasound to register the FHR. A major advantage of this technique is that it is non-invasive. This way it can be used during pregnancy, preterm and premature labor and before membranes have ruptured. Disadvantages are that it is susceptible to fetomaternal heart rate confusion, signal loss due to maternal or fetal movement and that the reliability is dependent on maternal BMI.[31–34]

The FSE uses an electrode that is placed on the head of the baby and is considered the gold standard in The Netherlands. Although it is a more reliable method, it is invasive and can therefore only be applied when membranes have ruptured and with sufficient dilation, and comes with increased risk for trauma and infection.[35,36]

Figure 3. Cardiotocogram

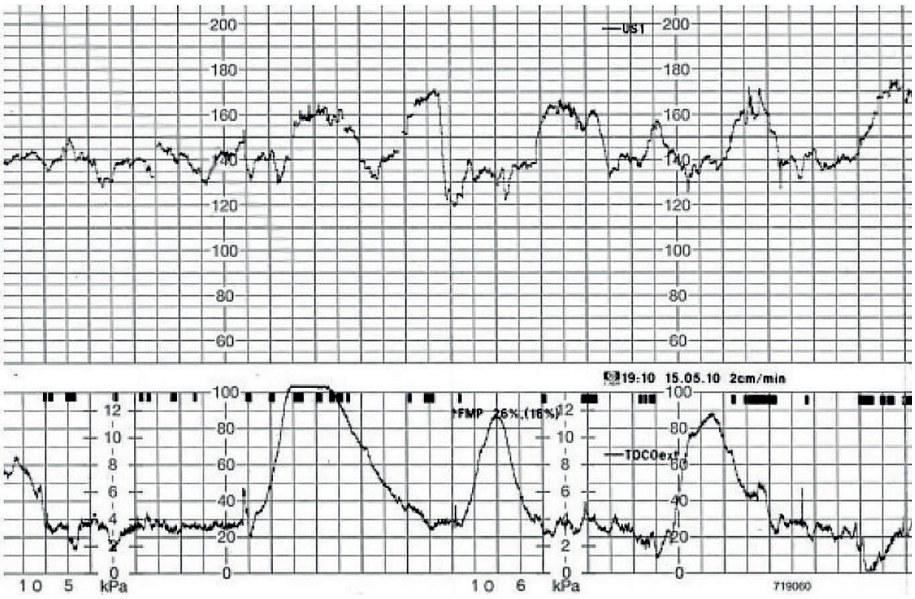

Upper line: fetal heart rate. Lower line: uterine activity.
Adapted from: 'Fetal autonomic cardiac response during pregnancy and labor' [37]

In the early 1970's the CTG was introduced to identify fetuses in distress and reduce neonatal mortality and morbidity. However, in clinical practice there is an ongoing debate about the diagnostic value of CTG monitoring and its poor specificity. After the introduction of the CTG during labor, seizure rates postnatally decreased, but long-term neonatal outcomes did not improve.[38] Furthermore, the introduction of the CTG shows a rise in caesarian sections and instrumental vaginal deliveries. [38] To improve the specificity of the CTG multiple techniques have been developed to complement the CTG, for example fetal blood sampling (FBS) and ST-waveform analysis (STAN). For FBS a clinician makes a small scratch on the head of the baby during labor to retrieve a blood sample. From that blood a pH and/or lactate level can be determined to detect potential acidosis. Multiple studies show that pH and lactate are equivalent in predicting fetal distress during labor. For determining a lactate level a smaller blood sample is needed and therefore this procedure is more often successful. [39,40] A Cochrane metanalysis describes that CTG monitoring combined with FBS may show less neonatal acidosis. [38] Disadvantages of FBS are that it requires the skill of the clinician to retrieve a blood sample, it is an invasive method that comes with risks for infection and trauma, it needs to be repeated when CTG abnormalities persist and it does not guarantee to prevent neonatal asphyxia. [38]

STAN uses a FSE to retrieve an unipolar fetal ECG. The hypothesis is that when ST-elevations are found in combination with CTG abnormalities the fetus is more likely to suffer from hypoxia and an intervention is needed. The ST-segment of an ECG represents the repolarization phase of the heart. This process needs energy. When there is insufficient oxygen, the energy that is normally derived from aerobic metabolism will change to anaerobic metabolism using glycogenolysis. This process causes, amongst others, higher levels of potassium in the myocardium. This may result in ST-elevations seen on the ECG. [41,42] Unfortunately, research regarding STAN during labor didn't show improvement in neonatal outcome. It did however show a decrease in the need for FBS and unnecessary operative deliveries. [43–48]

Other practical disadvantages of FBS and FSE (with or without STAN) other than those mentioned above are that they cannot be used in premature labor before 34 weeks of gestation or in mothers with HIV positive serology, in mothers with hepatitis B positive serology or in mothers with certain clotting diseases.

Non-invasive electrophysiologic measurements of the fetus may overcome the shortcomings of the current monitoring techniques. The measurements can be obtained using non-invasive electrodes placed on the maternal abdomen. In this thesis the potential use of Non-invasive electrophysiologic measurements to create a CTG is described and the potential added value of the fetal ECG, that may be derived from the same measurements, will be elaborated on.

Aims and outline of the thesis.

This thesis studies different applications of electrophysiologic measurements of the fetus during pregnancy and labor to detect threats for the fetus. The electrophysiologic measurements are performed with electrodes placed on the maternal abdomen. From the recorded electrophysiological signals a fetal ECG, the FHR, the MHR and uterine contractions (electrohysterography, EHG) can be retrieved. In this work, we aim to answer the following questions.

1. Can the fetal ECG be of value in screening and diagnosis of congenital heart disease in mid-pregnancy?

In Chapter 2-5 our work on the use of non-invasive fetal ECG for the detection of CHD is described. The fetal ECG could give additional information as it carries information on the propagation of electrical impulses through the heart, which we hypothesized might be affected by CHD. In chapter 2, the study protocol of the Confes study is published. During the study period 328 healthy fetuses and 148 fetuses with CHD were included. Chapter 3 gives the first results for a standardized method to calculate a fetal ECG in mid-pregnancy that is corrected for fetal movements and orientation. There may be different characteristics of the fetal ECG that could aid in the detection of CHD during pregnancy, for example the electrical heart axis. The electrical heart axis represents the main direction of the electrical activity of the heart during one cycle. We hypothesize that the direction of the electrical heart axis may change in CHD. In chapter 4 we determined the normal ranges of the electrical heart axis in healthy fetuses in mid-pregnancy. These normal ranges are used to compare the electrical heart axis of fetuses with a known CHD. These results are shown in chapter 5.

2. Is monitoring the FHR with non-invasive electrophysiologic measurements during labor better compared to FHR monitoring by Doppler Ultrasound?

As described above, during labor the fetus is monitored using CTG. The commonly used techniques, DU and FSE, have some disadvantages that need to be overcome. Non-invasive electrophysiologic measurements for monitoring FHR and potentially a non-invasive fetal ECG may be an alternative to these conventional monitoring techniques. Chapter 6 shows a review of the literature regarding the performance of the non-invasive electrophysiologic measurements as CTG device during labor. A total of 8 studies were included. Furthermore, we conducted a multicentre international (Netherlands, Belgium, Spain) cohort study to validate a non-invasive electrophysiologic measurements device as a CTG device during labor. The results of this study are presented in chapter 7.

3. Is real-time non-invasive fetal monitoring during pregnancy in a home setting a possibility?

Fetal monitoring during pregnancy is usually done by means of CTG monitoring. Currently, a consultation at an obstetric ward or outpatient clinic is often needed to conduct a CTG. Generally, CTG home monitoring is not standard of care and if available it typically cannot provide the means for real-time remote CTG monitoring. In chapter 8 we show the results of a pilot study regarding the usability of a new non-invasive electrophysiologic measurements device for CTG home monitoring. This pilot study was performed to evaluate user experience of this system of both the independent midwives and pregnant women and to evaluate their feelings about CTG home monitoring. As this device is a product in development, this pilot was also developed to evaluate whether the existing device meets the requirements for home monitoring and if not, which adjustments need to be made before using this device in a larger research setting.

References

1. Schoenwolf, Gary C. ; Bleyl, Steven B.; Brauer, Philip R. ; Francis-West PH. Larsen's Human Embryology. Fourth edi. Larsen's Human Embryology. Churchill Livingstone Elsevier; 2009. 337–433 p.
2. Guyton, Arthur C.; Hall JE. Unit XIV Endocrinology and Reproduction. In: Textbook of Medical Physiology. eleventh e. 2006. p. 1042–52.
3. Peeters, L.L.H.; Scherjon SA. De normale zwangerschap: foetus en placenta. In: Obstetrie en gynaecologie. Seventh Ed. Elsevier; 2012. p. 231–53.
4. Unit 4: Fluids and Transport. In: Anatomy & Physiology [Internet]. 2020. p. 823–86. Available from: https://openstax.org/details/books/anatomy-and-physiology
5. Unit 4: Fluids and Transport. In: Anatomy & Physiology [Internet]. 2020. p. 887–974. Available from: https://openstax.org/details/books/anatomy-and-physiology
6. van der Linde D, Konings EEM, Slager MA, Witsenburg M, Helbing WA, Takkenberg JJM, Roos-Hesselink JW. Birth prevalence of congenital heart disease worldwide: a systematic review and meta-analysis. J Am Coll Cardiol. 2011 Nov;58(21):2241–7.
7. Dolk H, Loane M, Garne E. Congenital heart defects in Europe: prevalence and perinatal mortality, 2000 to 2005. Circulation. 2011 Mar;123(8):841–9.
8. Hoffman JIE, Kaplan S, Liberthson RR. Prevalence of congenital heart disease. Am Heart J. 2004 Mar;147(3):425–39.
9. Carvalho JS, Mavrides E, Shinebourne EA, Campbell S, Thilaganathan B. Improving the effectiveness of routine prenatal screening for major congenital heart defects. Heart. 2002 Oct;88(4):387–91.
10. Buskens E, Grobbee DE, Frohn-Mulder IM, Stewart PA, Juttmann RE, Wladimiroff JW, Hess J. Efficacy of routine fetal ultrasound screening for congenital heart disease in normal pregnancy. Circulation. 1996 Jul;94(1):67–72.
11. Systemic Pathology: Disease of Organ Systems. In: Robbins and Cotran Pathologic Basis of Disease. Eighth edi. Saunders Elsevier; 2010. p. 529–87.
12. Cedergren MI, Källén BAJ. Maternal obesity and infant heart defects. Obes Res. 2003 Sep;11(9):1065–71.
13. Watkins ML, Rasmussen SA, Honein MA, Botto LD, Moore CA. Maternal obesity and risk for birth defects. Pediatrics. 2003 May;111(5 Pt 2):1152–8.
14. Wilson PD, Loffredo CA, Correa-Villaseñor A, Ferencz C. Attributable fraction for cardiac malformations. Am J Epidemiol. 1998 Sep;148(5):414–23.
15. Shillingford AJ, Weiner S. Maternal issues affecting the fetus. Clin Perinatol. 2001 Mar;28(1):31–70, vi.
16. Allan L. Fetal cardiac scanning today. Prenat Diagn. 2010 Jul;30(7):639–43.

17. DeVore GR, Medearis AL, Bear MB, Horenstein J, Platt LD. Fetal echocardiography: factors that influence imaging of the fetal heart during the second trimester of pregnancy. J Ultrasound Med. 1993 Nov;12(11):659–63.
18. Friedberg MK, Silverman NH, Moon-Grady AJ, Tong E, Nourse J, Sorenson B, Lee J, Hornberger LK. Prenatal Detection of Congenital Heart Disease. J Pediatr. 2009;155(1):26-31.e1.
19. Garne E, Stoll C, Clementi M. Evaluation of prenatal diagnosis of congenital heart diseases by ultrasound: experience from 20 European registries. Ultrasound Obstet Gynecol. 2001;17(5):386–91.
20. Michelfelder EC, Cnota JF. Prenatal Diagnosis of Congenital Heart Disease in an Era of Near-Universal Ultrasound Screening: Room for Improvement. J Pediatr. 2009;155(1):9–11.
21. Pinto NM, Keenan HT, Minich LL, Puchalski MD, Heywood M, Botto LD. Barriers to prenatal detection of congenital heart disease: a population-based study. Ultrasound Obstet Gynecol. 2012;40(4):418–25.
22. Robinson J, Simpson L, Abuhamad A. Screening For Fetal Heart Disease With Ultrasound. Clin Obstet Gynecol. 2003 Dec;46(4):890–6.
23. Eastwood KA, Daly C, Hunter A, McCance D, Young I, Holmes V. The impact of maternal obesity on completion of fetal anomaly screening. J Perinat Med. 2017;45(9):1061–7.
24. Hunsley C, Farrell T. The influence of maternal body mass index on fetal anomaly screening. Eur J Obstet Gynecol Reprod Biol. 2014;182:181–4.
25. van Velzen CL, Clur SA, Rijlaarsdam MEB, Bax CJ, Pajkrt E, Heymans MW, Bekker MN, Hruda J, de Groot CJM, Blom NA, Haak MC. Prenatal detection of congenital heart disease--results of a national screening programme. BJOG. 2016 Feb;123(3):400–7.
26. Adriaanse BME, van Vugt JMG, Haak MC. Three- and four-dimensional ultrasound in fetal echocardiography: an up-to-date overview. J Perinatol. 2016 Sep;36(9):685–93.
27. Sharland G. Fetal cardiac screening and variation in prenatal detection rates of congenital heart disease: why bother with screening at all? Future Cardiol. 2012 Mar;8(2):189–202.
28. Cloete E, Bloomfield FH, Sadler L, de Laat MWM, Finucane AK, Gentles TL. Antenatal Detection of Treatable Critical Congenital Heart Disease Is Associated with Lower Morbidity and Mortality. J Pediatr. 2019;204:66–70.
29. Brown KL, Ridout DA, Hoskote A, Verhulst L, Ricci M, Bull C. Delayed diagnosis of congenital heart disease worsens preoperative condition and outcome of surgery in neonates. Heart. 2006 Sep;92(9):1298–302.
30. Depasquale NP. Electrocardiogram, Ventricular Gradient and Spatial Vectorcardiogram During the First Week of Life. Am J Cardiol. 1963;12:482.
31. Bakker PC, Colenbrander GJ, Verstraeten AA, Geijn HP Van. The quality of intrapartum fetal heart rate monitoring. Eur J Obstet Gynecol Reprod Biol. 2004 Sep;116(1):22–7.

32. Spencer JAD, Belcher R, Dawes GS. The influence of signal loss on the comparison between computer analyses of the fetal heart rate in labor using pulsed doppler ultrasound (with autocorrelation) and simultaneous scalp electrocardiogram. Eur J Obstet Gynecol. 1987;25(1):29–34.
33. Dawes GS, Visser GHA, Goodman JDS, Levine DH. Numerical analysis of the human fetal heart rate : Modulation by breathing and movement. Am J Obstet Gynecol [Internet]. 1981;140(5):535–44. Available from: http://dx.doi.org/10.1016/0002-9378(81)90230-1
34. Cohen WR, Hayes-Gill B, W.R. C. Influence of maternal body mass index on accuracy and reliability of external fetal monitoring techniques. Acta Obstet Gynecol Scand [Internet]. 2014 Jun;93(6):590–5. Available from: http://onlinelibrary.wiley.com/journal/10.1111/(ISSN)1600-0412
35. Kawakita T, Reddy UM, Landy HJ, Iqbal SN, Huang CC, Grantz KL. Neonatal complications associated with use of fetal scalp electrode: a retrospective study. BJOG An Int J Obstet Gynaecol. 2016;123(11):1797–803.
36. Leatherman J, Parchman ML, Lawler FH. Infection of fetal scalp electrode monitoring sites. Am Fam Physician. 1992 Feb;45(2):579–82.
37. van Laar JOEH. Fetal autonomic cardiac response during pregnancy and labor. Eindhoven University of Technology; 2012.
38. Alfirevic Z, Devane D, Gyte GM, Cuthbert A. Continuous cardiotocography (CTG) as a form of electronic fetal monitoring (EFM) for fetal assessment during labor. Cochrane database Syst Rev. 2017 Feb;2:CD006066.
39. Westgren M, Hormquist P, Ingemarsson I, Svenningsen N, M. W, P. H, I. I. Intrapartum fetal acidosis in preterm infants: Fetal monitoring and long-term morbidity. Obstet Gynecol. 1984;63(3):355–9.
40. Wiberg-Itzel E, Lipponer C, Norman M, Herbst A, Prebensen D, Hansson A, Bryngelsson A-L, Christoffersson M, Sennström M, Wennerholm U-B, Nordström L. Determination of pH or lactate in fetal scalp blood in management of intrapartum fetal distress: randomised controlled multicentre trial. BMJ. 2008 Jun;336(7656):1284–7.
41. Rosén KG, Dagbjartsson A, Henriksson BA, Lagercrantz H, Kjellmer I. The relationship between circulating catecholamines and ST waveform in the fetal lamb electrocardiogram during hypoxia. Am J Obstet Gynecol. 1984 May;149(2):190–5.
42. Greene KR, Dawes GS, Lilja H, Rosén KG. Changes in the ST waveform of the fetal lamb electrocardiogram with hypoxemia. Am J Obstet Gynecol. 1982 Dec;144(8):950–8.
43. Westerhuis MEMH, Visser GHA, Moons KGM, Van Beek E, Benders MJ, Bijvoet SM, Van Dessel HJHM, Drogtrop AP, Van Geijn HP, Graziosi GC, Groenendaal F, Van Lith JMM, Nijhuis JG, Oei SG, Oosterbaan HP, Porath MM, Rijnders RJP, Schuitemaker NWE, Sopacua LM, Van Der Tweel I, Wijnberger LDE, Willekes C, Zuithoff NPA, Mol BWJ, Kwee A. Cardiotocography plus ST analysis of fetal electrocardiogram compared with cardiotocography only for intrapartum monitoring: A randomized controlled trial. Obstet Gynecol. 2010;115(6):1173–80.

44. Saccone G, Schuit E, Amer-Wahlin I, Xodo S, Berghella V. Electrocardiogram ST Analysis During Labor: A Systematic Review and Meta-analysis of Randomized Controlled Trials. Obstet Gynecol. 2016 Jan;127(1):127–35.

45. Potti S, Berghella V. ST waveform analysis versus cardiotocography alone for intrapartum fetal monitoring: a meta-analysis of randomized trials. Am J Perinatol. 2012 Sep;29(8):657–64.

46. Olofsson P, Ayres-de-Campos D, Kessler J, Tendal B, Yli BM, Devoe L. A critical appraisal of the evidence for using cardiotocography plus ECG ST interval analysis for fetal surveillance in labor. Part II: the meta-analyses. Acta Obstet Gynecol Scand. 2014 Jun;93(6):571–8.

47. Belfort MA, Saade GR, Thom E, Blackwell SC, Reddy UM, Thorp JMJ, Tita ATN, Miller RS, Peaceman AM, McKenna DS, Chien EKS, Rouse DJ, Gibbs RS, El-Sayed YY, Sorokin Y, Caritis SN, VanDorsten JP. A Randomized Trial of Intrapartum Fetal ECG ST-Segment Analysis. N Engl J Med. 2015 Aug;373(7):632–41.

48. Blix E, Brurberg KG, Reierth E, Reinar LM, Oian P. ST waveform analysis versus cardiotocography alone for intrapartum fetal monitoring: a systematic review and meta-analysis of randomized trials. Acta Obstet Gynecol Scand. 2016 Jan;95(1):16–27.

CHAPTER 2

Normal ranges for fetal electrocardiogram values for the healthy fetus of 18-24 weeks of gestation: a prospective cohort study

Kim M.J. Verdurmen, Carlijn Lempersz, Rik Vullings, Christian Schroer, Tammo Delhaas, Judith O.E.H. van Laar, S. Guid Oei

BMC Pregnancy Childbirth. 2016 Aug 17;16:227

Abstract

Background: The fetal anomaly ultrasound only detects 65 to 81 % of the patients with congenital heart disease, making it the most common structural fetal anomaly of which a significant part is missed during prenatal life. Therefore, we need a reliable non-invasive diagnostic method which improves the predictive value for congenital heart diseases early in pregnancy. Fetal electrocardiography could be this desired diagnostic method. There are multiple technical challenges to overcome in the conduction of the fetal electrocardiogram. In addition, interpretation is difficult due to the organisation of the fetal circulation in utero. We want to establish the normal ranges and values of the fetal electrocardiogram parameters in healthy fetuses of 18 to 24 weeks of gestation.

Methods/Design: Women with an uneventful singleton pregnancy between 18 and 24 weeks of gestation are asked to participate in this prospective cohort study. A certified and experienced sonographist performs the fetal anomaly scan. Subsequently, a fetal electrocardiogram recording is performed using dedicated signal processing methods. Measurements are performed at two institutes. We will include 300 participants to determine the normal values and 95% confidence intervals of the fetal electrocardiogram parameters in a healthy fetus. We will evaluate the fetal heart rate, segment intervals, normalised amplitude and the fetal heart axis. Three months postpartum, we will evaluate if a newborn is healthy through a questionnaire.

Discussion: Fetal electrocardiography could be a promising tool in the screening program for congenital heart diseases. The electrocardiogram is a depiction of the intimate relationship between the cardiac nerve conduction pathways and the structural morphology of the fetal heart, and therefore particularly suitable for the detection of secondary effects due to a congenital heart disease (hypotrophy, hypertrophy and conduction interruption).

Background

During pregnancy, the condition of the fetus is assessed with different techniques. One of these techniques is ultrasound examination. Between week 18 and 22 of gestation the fetal anomaly ultrasound is performed. During this examination, the fetus is screened for all kind of possible congenital anomalies, including congenital heart disease (CHD). CHD is defined as a "gross structural abnormality of the heart or intra-thoracic large vessels, (possibly) with functional significance".[1] CHD is the most common severe congenital anomaly worldwide [2], the incidence is estimated at 6-12 per 1000 live births. [3–5] CHD is six times more common than chromosomal anomalies and four times more common than neural tube defects.[4,6]

The fetal anomaly ultrasound, including planes of the ventricular outflow tracts and the three-vessel view, only detects 65 to 81 % of the patients with CHD.[6–9] That makes CHD the most common structural fetal abnormality of which a significant part is missed during prenatal life. Therefore, we need a reliable non-invasive diagnostic method which improves the predictive value for the diagnosis CHD. This diagnostic technique should be able to diagnose CHD early in pregnancy for multiple reasons. First, we get the opportunity to identify associated extracardiac and chromosomal anomalies that affect fetal and postnatal prognosis. Second, parents get the chance to opt for termination of pregnancy in case of a severe CHD. Third, one can develop an adequate treatment plan including intra-uterine therapy, timing, mode and location of delivery and planning of immediate treatment after birth. In ductus- and foramen ovale dependent CHDs, it is demonstrated that prenatal diagnosis increases the survival rates and decreases long term morbidity.[10–13]

The currently used two-dimensional ultrasonography provides multiple anatomic planes, relying on the sonographists mental reconstruction of these planes to define the fetal cardiac anatomy. The antenatal diagnostic value is therefore to a great extent depending on the experience of the performer. As stated by Gardiner; "you only see what you look for and identify what you already know".[5] Three- and four-dimensional ultrasonography gives a more fluid and representative image of the fetal cardiac structures, and therefore aids in this mental reconstruction.[14] Spatio-temporal image correlation (STIC) is a new modality using automated volume acquisition of the fetal heart with one sweep of the probe, further facilitating the examination of the fetal heart. Disadvantages of these ultrasound modalities are that they are extremely expensive and only applicable in centres with experienced personnel.

The non-invasive fetal electrocardiogram (ECG) could be a valuable tool for the detection of CHD early in pregnancy. In 1906, Cremer and colleagues were the first to describe fetal ECG extraction through the maternal abdomen [15] and 80 years later, Pardi and colleagues were the first to write a review considering fetal ECG and, amongst others, CHD.[16] Compared to other techniques for fetal monitoring, the development of the

fetal ECG lagged behind. This is mainly because there are multiple technical challenges to overcome. First, at a gestational age of 20 weeks, the fetal heart is about 1/10th of the size of an adult heart. Due to the low voltage of the fetal ECG (1/50 of the maternal ECG), there is a low signal-to-noise ratio. In addition, identifying the fetal signals is challenging due to masking by the maternal ECG and high background noises caused by the maternal electromyogram. The amniotic fluid and maternal tissues that surround the fetus enlarge the distance to the electrodes, and cause a non-homogenous tissue conduction that interferes with signal quality. In addition, the vernix caseosa causes electrical isolation and further diminishes the signal amplitude.[17] This is the main cause of the poor signal-to-noise ratio from 30 to 34 weeks of gestation.[18,19] Second, the fetal ECG has a complex three-dimensional shape, alternating with changes in fetal presentation. Following fetal movements, the electrical signal from each electrode changes frequently. Another challenging factor is the speed of the fetal heart rate, which is two to three times faster compared to the adult heart rate.[20]

Besides the technical difficulties encountered when conducting a fetal ECG, it is also challenging to interpret the fetal ECG. In contrast with postnatal life, the systemic circulation in the fetus is fed from both the left and right ventricle in parallel, with equal intraventricular pressures.[21] The outflow in the right ventricle is slightly larger compared to the outflow in the left ventricle, and increases during gestation; 53% vs 47% at 20 weeks of gestation, 57% vs 43% at 30 weeks of gestation and 60% vs 40% at 38 weeks of gestation.[21] In utero, the O_2-rich blood flows from the umbilical vein to the right atrium. There, the foramen ovale propels a major part of the O_2-rich blood to the left side of the heart and into the systemic circulation, bypassing the fetal lungs. In addition, in the second trimester the ductus arteriosus propels 40% of the combined cardiac output. Because of these major differences between the systemic circulation in utero and postpartum, it is difficult to predict what a normal fetal ECG looks like. Furthermore, due to this organisation of the fetal circulation in utero, in case of a CHD one side of the heart can compensate for an abnormality on the other site, and fetuses affected by a CHD do not always show signs of cardiac failure.

However, before we are able to detect CHD with the fetal ECG, we need to establish the normal range and values of amplitudes and segment intervals of the fetal ECG in a healthy fetus.

Methods/Design

Aim

The aim of this study is to establish the normal ranges and values (mean with 95% confidence intervals) of fetal ECG parameters in a healthy fetus of 18 to 24 weeks of gestation.

Study design

We will perform a prospective cohort study. The study protocol is approved by the medical ethical committee of the Máxima Medical Centre, Veldhoven, the Netherlands (NL48535.015.14).

Setting

Measurements are performed at the Máxima Medical Centre, Veldhoven, the Netherlands and "Diagnostiek voor U" (DvU), Eindhoven, the Netherlands. The Máxima Medical Centre is a tertiary care teaching hospital for obstetrics. DvU is a diagnostic centre which, amongst others, performs blood tests and ultrasounds. Measurements are performed directly before or after the sonographist performed the fetal anomaly scan. The fetal anomaly ultrasound is performed by a certified and experienced sonographist.

Participants

Patients with an uneventful pregnancy, carrying a singleton fetus with a gestational age between 18 and 24 weeks, are included in the study after written informed consent. At the Máxima Medical Centre, this will be patients who visit the outpatient clinic for an appointment. At DvU, this will be patients who visit the centre for their fetal anomaly ultrasound. These patients are generally seen by a midwife or by a doctor at the Máxima Medical Centre for their obstetrical care. Pregnant women must be aged older than 18 years. If any of the fetuses turn out to have a form of CHD, they are excluded from the cohort. Other exclusion criteria are multiple pregnancies, insufficient understanding of the Dutch language, and any known fetal congenital anomalies.

Three months postpartum we will evaluate if the new born is healthy, which is defined as absence of CHD, through a questionnaire. If the neonate turns out to have a CHD, which was missed at the time of the structural anomaly ultrasound, we will exclude the patient from the cohort.

Procedures

The fetal ECG is a non-invasive, transabdominal research method. The pregnant women is lying down in a semi-recumbent position to prevent aortocaval compression. The fetal ECG is conducted with eight electrodes on the maternal abdomen, placed in a fixed configuration (Figure 1; consent for publication is obtained). Before applying the electrodes on the abdomen, the skin is cleaned and prepared by scrubbing the skin

areas with abrasive paper to optimise the skin-electrode impedance. The impedance is measured after the skin is prepared and before the fetal ECG recording is started. On the right side of the abdomen a ground electrode is placed and near the belly a reference electrode is placed. The six recording electrodes give bipolar signals that, among others signals, contain the fetal ECG. The placement of the electrodes is chosen in order to assess the fetal heart with as much accuracy as possible. With the fetus able to move freely in the uterus, at least some of the six electrodes will be close to the fetal heart and thus will give a usable bipolar signal. We will record the fetal ECG for 30 minutes. During this recording, the fetal position is determined four times by ultrasound assessment. Good signal quality is verified via the real-time bedside monitoring system (Figure 2).

Figure 1. Configuration of the electrodes on the maternal abdomen.

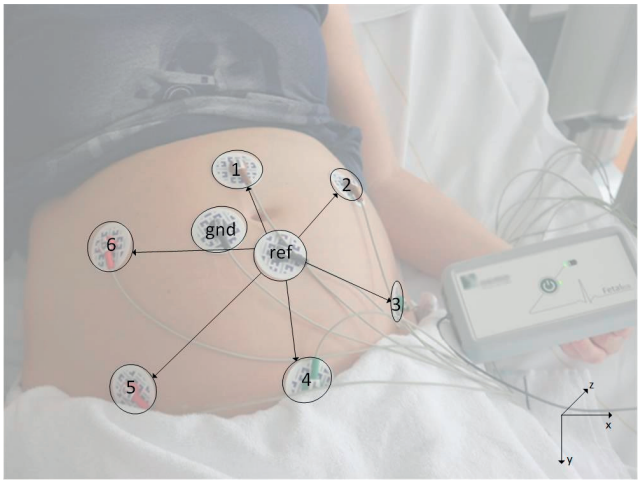

The fetal ECG is recorded with eight electrodes on the maternal abdomen, placed in a fixed configuration. A ground and reference electrode are placed near the belly button. The electrodes are connected to our fetal ECG system, which is connected to a computer. This system records six channels of fetal ECG data

Figure 2. Real-time bedside monitoring system

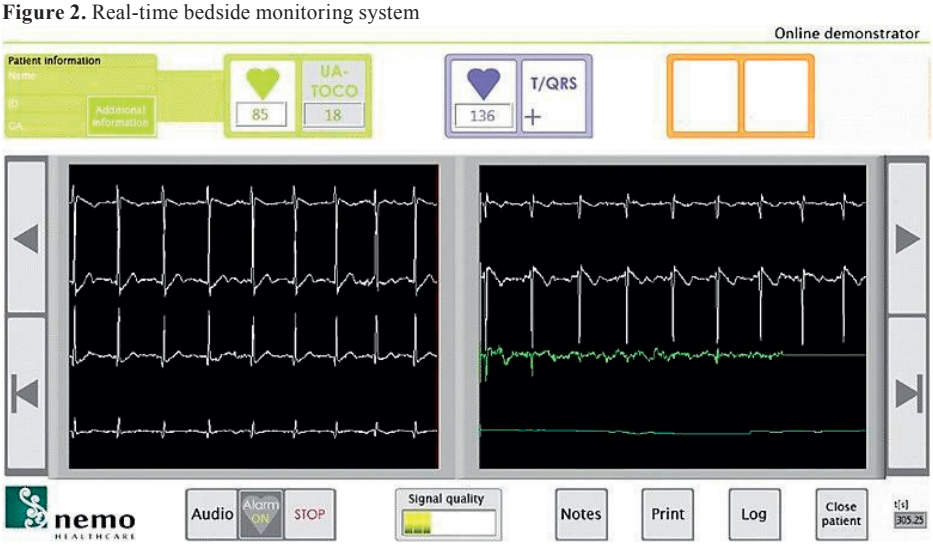

Good signal quality can be verified via the real-time bedside monitoring system. Below the green heart in the top panel on the left, the maternal heart rate is depicted. Right next to this, the uterine activity is shown. Below the blue heart on the right side of the top panel, the fetal heart rate is depicted. The white lines represent the output from the six abdominal electrodes, while the green line is a computation of the fetal signal, after subtraction of the maternal signal. In the lower panel in the middle, an estimate of the signal quality is shown. The user interface can be switched to a different screen in which the cardiotocogram is depicted.

The fetal ECG signals are digitized and stored by a prototype fetal ECG system (NEMO Healthcare BV, the Netherlands). This prototype system comprises of a 6-channel amplifier that is dedicated for electrophysiological recordings during pregnancy. After digitization, the acquired signals are processed by PC-based dedicated signal processing techniques as previously described by Vullings et al. [22,23] to suppress interferences such as maternal ECG, powerline, and electromyographic signals from within the maternal body, and retrieve the fetal ECG. Following, we can calculate the fetal ECG for each of the six electrodes. However, before we can compare ECG values between patients we need to normalise the ECG for different orientations of the fetus within the uterus. A specific electrode would record a different ECG waveform for a fetus in cephalic position versus for a fetus in breech position, also yielding differences in some of the ECG parameters mentioned below.

To normalise for fetal orientation, we calculate the vectorcardiogram (VCG) of the fetus[24]. This VCG entails a 3-dimensional representation of the fetal electrical cardiac activity. As described by Frank et al. [25], in adult electrocardiography the VCG can be used to calculate standardised ECG leads such as Einthoven 1-3, aVF, aVL, and aVR. By mathematically rotating the fetal VCG prior to calculating the ECG, we can create

standardised fetal ECG leads. The amount of rotation required is determined based on a simultaneously performed ultrasound assessment of the fetal presentation. Via these mathematical rotations, we are also capable of detecting and correcting for fetal movements in between the ultrasound assessments, as described previously by Vullings et al.[26] The four ultrasound assessments during the measurements are used to correct for cumulative errors in this correction method and to determine the initial orientation of the fetus. To enhance the signal quality of the measurements, the fetal ECG is filtered further (amongst others by averaging of the ECG waveforms). The detection of segments and intervals is performed semi-automatically. The detection of fetal ECG complexes is computerised, while marking of the fetal ECG intervals (P top, QRS complex, T top) is performed manually by two independent researchers following a protocol that is verified by an experienced paediatric cardiologist. We will calculate the inter-observer variability between the two researchers.

Normal heart rhythm is assumed to show variations in heartbeat intervals smaller than 20% between consecutive beats. In case these variations are larger, this is assumed to be the result of either fetal arrhythmia or erroneous detection of the heartbeat interval, e.g. because of poor signal quality. Assessment of erroneous detection is based on energy of the ECG signal and correlations between consecutive ECG waveforms. The ECG is a quasi-periodic signal, meaning that consecutive ECG waveforms have a similar appearance and similar amplitude/energy. In case of poor ECG signal quality, the energy of the ECG signals is expected to differ from the energy during good quality recordings. Present artefacts or noise cause the energy of the ECG to increase beyond physiologically plausible ranges. Likewise, correlations between consecutive ECG waveforms are reduced in the presence of poor signal quality.

It has to be noted here, that fetal arrhythmia can also cause poor correlation between ECG waveforms. Some arrhythmias are hence expected to be incorrectly classified as poor signal quality. This misclassification affects the detection of fetal arrhythmia, but will not have any impact on other study parameters as these are determined only during normal rhythm and good signal quality. The recording must contain a minimum of 200 ECG complexes that were assessed to have good signal quality and that were corrected for fetal movement.[26]

Study parameters

Multiple outcome values are evaluated:

- Fetal heart rate; mean, standard deviation, 95% confidence intervals and heart rate arrhythmia
- Segment intervals (PQ, QRS, ST etc); mean, standard deviation and 95% confidence intervals

- Normalised amplitudes (P, QRS, T); mean, standard deviation and 95% confidence intervals
- Fetal electrical heart axis
- % of total patients in which the recording contains the required amount of data to perform the analysis

Heart rate arrhythmia is defined based on heuristic rules that dictate that during normal rhythm subsequent heartbeat intervals cannot differ more than 20%. Any rhythm not complying with this rule, and assessed to not be caused by erroneous detection of heartbeats, e.g. as a result of poor signal quality, is labelled as a fetal arrhythmia.

Sample size

There are previously published studies (see Discussion for more details) that describe fetal ECG parameters. However, these studies use different methods for obtaining the fetal signal and do not correct for the fetal position in the uterus. Therefore they are not able to calculate the fetal electrical heart axis. Moreover, all studies describe another parameter of the fetal ECG. Statistical experts calculated that we need a study population of 200 pregnant patients in order to determine normal values and 95% confidence intervals of a healthy fetus.[27] Anticipating on loss to follow-up and insufficient data quality, we will include 300 patients in the initial cohort.

Statistical analysis

The collected data is analysed through SPSS. With the collected data, we perform several analyses. We calculate the normal values and ranges of the fetal heart rate, segment intervals (PQ, QRS, ST etc), normalised amplitudes (P, QRS and T) and the fetal heart axis. Initially, we will calculate the values and ranges for all included patients as one group (18 to 24 weeks of gestational age). Thereafter, we will perform a sub analysis for every group per week of gestational age.

Discussion

Previous studies have been published regarding the normal values and ranges of the fetal ECG. In their review, Pardi et al summarized the normal evolution of the cardiac cycle during gestation.[16] From the 17th week of gestation up to term, the duration of the P-wave increases progressively. This reflects the anatomical development of the atria during pregnancy. Similar, the duration of the QRS-complex increases progressively, parallel with the weight gain of the fetal heart and in particular with the gain in ventricular mass. In fetal life, the intraventricular conduction is delayed compared to adult values, most likely due to anatomical differences of the ventricular conduction tissue. There is a slight increase in PR-interval during pregnancy, indicating development of the atrioventricular conduction tissue.

Recently, longitudinal studies followed pregnancies from 14 to 41 weeks of pregnancy and performed fetal ECG measurements during different stages of gestation.[18,28,29] In the 1960's, Larks and colleagues described the orientation of the electrical fetal heart axis.[30–33] All mentioned studies performed fetal ECG recordings with different conduction and analysis techniques. The amount of electrodes on the maternal abdomen varied from three to sixteen. Average fetal ECG complexes were generated from segments of 60 seconds up to 2.5 minutes. Analyses were performed manually or by computerized signal processing programs. These studies did not take the fetal position in the uterus into account.

In a group around 20 weeks of gestation, the following mean values were found by Chia and Taylor respectively: P wave length 43.9 ms, PR interval 102.1/91.7 ms, QRS duration 47.2/40.7 ms, QT interval 224.0/242.3 ms and T wave duration 123.8ms.[28,29] Larks found a normal range of the fetal heart axis between +100 and +160 degrees, with a mean value of +134 degrees in term fetuses during labour.[33] Due to the lack of correcting for the fetal position in utero, fetuses in breech position showed a negative electrical heart axis (-180 to 0 degrees).[32] In fact, due to the lack of correcting for fetal position, also findings for fetuses in vertex position were unreliable. In their analysis, Larks implicitly assumed that every fetus was facing the frontal plane. In cases where this assumption was incorrect, the measured heart axis must have been incorrect as a consequence. For example, a fetus with an electrical heart axis at +135 degrees will indeed be measured as +135 degrees when facing the frontal plane. When this same fetus, still in vertex position, rotates to face the sagittal plane, the measured heart axis will be +90 degrees. When opposing the frontal plane, the measured heart axis will be +45 degrees.

Up to our knowledge our study is the first to calculate the fetal electrical heart axis, taken the fetal position into account. A reliable calculation of the electrical heart axis is important in interpreting the fetal ECG. In addition, changes in the orientation of the fetal electrical heart axis might be able to aid in the diagnosis of congenital heart disease in the future.

The fetal ECG can be used from early gestation, it is non-invasive, easy to apply and safe to use.[18] One of the big advantages of the fetal ECG is that it potentially is a non-expensive diagnostic test in the long term. In addition, it creates the opportunity to perform measurements anywhere in the world and transmit the raw ECG data to be evaluated elsewhere. The equipment is smaller in comparison to ultrasound machines. Moreover, the fetal ECG is evaluated by semi-computerized algorithms, taking away some of the performer-dependent variability in diagnostic value. The fetal ECG system takes minimum training to be applied.

The fetal ECG could be a promising clinical tool in the screening program for CHD. It is a depiction of the intimate relationship between the cardiac nerve conduction pathways

and the structural morphology of the fetal heart.[8,34] The fetal ECG is likely to be particularly suitable for the detection of secondary effects due to a CHD; hypotrophy, hypertrophy and conduction interruption.

References

1. Mitchell SC, Korones SB, Berendes HW. Congenital heart disease in 56,109 births. Incidence and natural history. Circulation. 1971 Mar;43(3):323–32.
2. van der Linde D, Konings EEM, Slager MA, Witsenburg M, Helbing WA, Takkenberg JJM, Roos-Hesselink JW. Birth prevalence of congenital heart disease worldwide: a systematic review and meta-analysis. J Am Coll Cardiol. 2011 Nov;58(21):2241–7.
3. Donofrio MT, Moon-Grady AJ, Hornberger LK, Copel JA, Sklansky MS, Abuhamad A, Cuneo BF, Huhta JC, Jonas RA, Krishnan A, Lacey S, Lee W, Michelfelder ECS, Rempel GR, Silverman NH, Spray TL, Strasburger JF, Tworetzky W, Rychik J. Diagnosis and treatment of fetal cardiac disease: a scientific statement from the American Heart Association. Circulation. 2014 May;129(21):2183–242.
4. Simpson LL. Screening for congenital heart disease. Obstet Gynecol Clin North Am. 2004;31(1):51–9.
5. Gardiner HM. Keeping abreast of advances in fetal cardiology. Early Hum Dev. 2006 Jun;82(6):415–9.
6. Carvalho JS, Mavrides E, Shinebourne EA, Campbell S, Thilaganathan B. Improving the effectiveness of routine prenatal screening for major congenital heart defects. Heart. 2002 Oct;88(4):387–91.
7. Kirk JS, Riggs TW, Comstock CH, Lee W, Yang SS, Weinhouse E. Prenatal screening for cardiac anomalies: the value of routine addition of the aortic root to the four-chamber view. Obstet Gynecol. 1994 Sep;84(3):427–31.
8. Ogge G, Gaglioti P, Maccanti S, Faggiano F, Todros T. Prenatal screening for congenital heart disease with four-chamber and outflow-tract views: a multicenter study. Ultrasound Obstet Gynecol. 2006 Nov;28(6):779–84.
9. Wu Q, Li M, Ju L, Zhang W, Yang X, Yan Y, Wang W. Application of the 3-vessel view in routine prenatal sonographic screening for congenital heart disease. J Ultrasound Med. 2009 Oct;28(10):1319–24.
10. Brick DH, Allan LD. Outcome of prenatally diagnosed congenital heart disease: an update. Pediatr Cardiol. 2002;23(4):449–53.
11. Hunter LE, Simpson JM. Prenatal screening for structural congenital heart disease. Nat Rev Cardiol. 2014 Jun;11(6):323–34.
12. Brown KL, Ridout DA, Hoskote A, Verhulst L, Ricci M, Bull C. Delayed diagnosis of congenital heart disease worsens preoperative condition and outcome of surgery in neonates. Heart. 2006 Sep;92(9):1298–302.
13. Trines J, Fruitman D, Zuo KJ, Smallhorn JF, Hornberger LK, Mackie AS. Effectiveness of prenatal screening for congenital heart disease: assessment in a jurisdiction with universal access to health care. Can J Cardiol. 2013 Jul;29(7):879–85.

14. Rogers L, Li J, Liu L, Balluz R, Rychik J, Ge S. Advances in fetal echocardiography: early imaging, three/four dimensional imaging, and role of fetal echocardiography in guiding early postnatal management of congenital heart disease. Echocardiography. 2013 Apr;30(4):428–38.
15. Cremer M. Über die direkte Ableitung der Aktionsströme des menschlichen Herzens vom Oesophagus und über das Elektrokardiogramm des Fötus. Munchener medizinische Wochenschrift. 1906;53:811–3.
16. Pardi G, Ferrazzi E, Cetin I, Rampello S, Baselli G, Cerutti S, Civardi S. The clinical relevance of the abdominal fetal electrocardiogram. J Perinat Med. 1986;14(6):371–7.
17. Kimura Y. Recent Advances in Fetal Electrocardiography. Open Med Devices J. 2012 May 31;4(1):7–12.
18. van Laar JOEH, Warmerdam GJJ, Verdurmen KMJ, Vullings R, Peters CHL, Houterman S, Wijn PFF, Aniessen P, van Pul C, Oei SG. Fetal heart rate variability during pregnancy, obtained from non-invasive electrocardiogram recordings. Acta Obstet Gynecol Scand. 2014;93(1):93–101.
19. Oostendorp TF, van Oosterom A, Jongsma HW. The fetal ECG throughout the second half of gestation. Clin Phys Physiol Meas an Off J Hosp Phys Assoc Dtsch Gesellschaft fur Medizinische Phys Eur Fed Organ Med Phys. 1989 May;10(2):147–60.
20. Van Mieghem T, DeKoninck P, Steenhaut P, Deprest J. Methods for prenatal assessment of fetal cardiac function. Prenat Diagn. 2009 Dec;29(13):1193–203.
21. Kiserud T, Acharya G. The fetal circulation. Prenat Diagn. 2004 Dec;24(13):1049–59.
22. Vullings R, Peters CHL, Sluijter RJ, Mischi M, Oei SG, Bergmans JWM, R. V, C.H.L. P, R.J. S, M. M, S.G. O. Dynamic segmentation and linear prediction for maternal ECG removal in antenatal abdominal recordings. Physiol Meas. 2009;30(3):291–307.
23. Vullings R, de Vries B, Bergmans JWM. An adaptive Kalman filter for ECG signal enhancement. IEEE Trans Biomed Eng. 2011 Apr;58(4):1094–103.
24. Vullings R. Bayesian Approach to Patient-Tailored Vectorcardiography. IEEE Trans Biomed Eng. 3AD;57(3):586–95.
25. Frank E. General theory of heat-vector projection. Circ Res. 1954 May;2(3):258–70.
26. Vullings R. Novel Bayesian Vectorcardiographic Loop Alignment for Improved Monitoring of ECG and Fetal Movement. IEEE Trans Biomed Eng. 2013;60(6):1580–8.
27. Altman DG. Practical Statistics for Medical Research. London: Chapman&Hall/CRC; 1990.
28. Chia EL, Ho TF, Rauff M, Yip WCL. Cardiac time intervals of normal fetuses using noninvasive fetal electrocardiography. Prenat Diagn. 2005 Jul;25(7):546–52.
29. Taylor MJO, Smith MJ, Thomas M, Green AR, Cheng F, Oseku-Afful S, Wee LY, Fisk NM, Gardiner HM. Non-invasive fetal electrocardiography in singleton and multiple pregnancies. BJOG. 2003 Jul;110(7):668–78.
30. Larks SD, Larks GG. Components of the fetal electrocardiogram and intrauterine electrical axis: quantitative data. Biol Neonat. 1966;10(3):140–52.

31. Larks SD, Larks GG. Comparative aspects of the fetal and newborn electrocardiograms. Evidence for the validity of the method for calculation of the electrical axis of the fetal heart. Am J Obstet Gynecol. 1966 Oct;96(4):553–5.
32. Larks SD. Estimation of the Electrical Axis of the Fetal Heart. Am J Obstet Gynecol. 1965;91:46.
33. Larks SD, Larks GG. The electrical axis of the fetal heart: a new criterion for fetal well-being or distress. Am J Obstet Gynecol. 1965 Dec;93(7):975–83.
34. Velayo C, Sato N, Ito T, Chisaka H, Yaegashi N, Okamura K, Kimura Y. Understanding congenital heart defects through abdominal fetal electrocardiography: case reports and clinical implications. J Obstet Gynaecol Res. 2011 May;37(5):428–35.

CHAPTER 3

The Standardized 12-lead Fetal Electrocardiogram of the Healthy Fetus in Mid-Pregnancy: a cross-sectional study.

Carlijn Lempersz, Judith O. van Laar, Sally-Ann B. Clur, Kim M. Verdurmen, Guy J. Warmerdam, Joris van der Post, Nico A. Blom, Tammo Delhaas, S. Guid Oei, Rik Vullings

PLoS One. 2020 Apr 30;15(4):e0232606

Abstract

Introduction: The examination of the fetal heart in mid-pregnancy is by ultrasound examination. The quality of the examination is highly dependent on the skill of the sonographer, fetal position and maternal body mass index. An additional tool that is less dependent on human experience and interpretation is desirable. The fetal electrocardiogram (ECG) could fulfill this purpose. We aimed to show the feasibility of recording a standardized fetal ECG in mid-pregnancy and explored its possibility to detect congenital heart disease (CHD).

Materials and methods: Women older than 18 years of age with an uneventful pregnancy, carrying a healthy singleton fetus with a gestational age between 18 and 24 weeks were included. A fetal ECG was performed via electrodes on the maternal abdomen. After removal of interferences, a vectorcardiogram was constructed. Based on the ultrasound assessment of the fetal orientation, the vectorcardiogram was rotated to standardize for fetal orientation and converted into a 12-lead ECG. Median ECG waveforms for each lead were calculated.

Results: 328 fetal ECGs were recorded. 281 were available for analysis. The calculated median ECG waveform showed the electrical heart axis oriented to the right and inferiorly i.e. a negative QRS deflection in lead I and a positive deflection in lead aVF. The two CHD cases show ECG abnormalities when compared to the mean ECG of the healthy cohort.

Discussion: We have presented a method for estimating a standardized 12-lead fetal ECG. In mid-pregnancy, the median electrical heart axis is right inferiorly oriented in healthy fetuses. Future research should focus on fetuses with congenital heart disease.

Introduction

The fetal heart in mid-pregnancy is one of the most difficult organs to examine during the standard anomaly scan. The assessment is made difficult due to the small size of the fetal heart, its movement, and its complicated anatomy. In addition, maternal body mass index highly influences interpretability. Taking all this into consideration, a successful assessment of the heart is highly dependent on the skill of the sonographer.[1]

The timely prenatal detection of CHD has some important advantages. In the case of severe defects parents may choose to terminate the pregnancy. Where the pregnancy is continued, a prenatal diagnosis of CHD allows the parents time to prepare for the arrival of their sick child. Furthermore, it facilitates appropriate changes in obstetric and neonatal management, including intra-uterine therapy, planning of the delivery in a center with the required neonatal and cardiothoracic surgical care facilities, and timely treatment after birth. It has been demonstrated that prenatal diagnosis of CHD increases survival rates and decreases long-term morbidity.[2–6]

An additional tool for the assessment of the fetal heart in mid-pregnancy that is less dependent on human experience and interpretation is desirable. This tool could be the fetal electrocardiogram. Electrocardiography is used worldwide as a relatively simple tool to assist in the diagnosis of heart disease in adults and children as well as in the diagnosis and management of arrhythmias.

Until now, it has not been possible to record a reliable standard non-invasive fetal ECG for fetal heart assessment. Inter- and intra-fetal comparisons are hampered since the fetus is free to move underneath the transabdominal electrodes and thereby can take any orientation with respect to the electrodes. Hence, standardization of the fetal ECG, i.e. normalizing for the fetal orientation, is needed to allow fetal ECG waveform analysis. A published standardization method is currently not available.[7] Moreover, very little is known about what constitutes a normal fetal ECG at around 20 weeks of gestation.

In this paper, we present a method for standardization of the fetal ECG that was applied to a cohort of more than 300 fetuses to show the feasibility of recording a standardized fetal ECG in mid-pregnancy. Furthermore, we compared the normal ECG to the ECGs of two fetuses prenatally diagnosed with congenital heart disease (CHD) to illustrate the potential value of fetal ECG for CHD screening and diagnosis in mid-pregnancy and discuss the possible future applications of the fetal ECG.

Materials and Methods

Ethics statement

The study was approved by the Máxima Medical Centre institutional review board (NL48535.015.14). Participants were included in the study after written informed consent had been obtained.

This study was part of a larger ongoing entity, consisting of a healthy cohort and a group of fetuses with known congenital heart disease (CHD).This trial is registered at the Netherlands Trial Register (NTR5906). The study protocol has been published by Verdurmen et al. [8] Fetal ECG measurements were performed between May 2014 and February 2017 at the Máxima Medical Centre, Veldhoven, The Netherlands and at 'Diagnostiek voor U' diagnostic center, Eindhoven, The Netherlands. Measurements were performed directly before or after the 20-week fetal anomaly scan. This anomaly examination was performed by a certified and experienced ultrasonographist. Three months after birth, the participants received a questionnaire to verify that the child was healthy and did not have CHD. This three month time interval was chosen because in The Netherlands every newborn will have several general check-ups by a primary healthcare doctor within three months after birth.

Women with an uneventful pregnancy, carrying a singleton fetus with a gestational age between 18 and 24 weeks, were included in the study after written informed consent had been obtained. The included pregnant women had to be older than 18 years of age. Fetuses with diagnosed CHD were excluded. Other exclusion criteria were multiple pregnancies, insufficient understanding of the Dutch language, and any known fetal congenital anomalies other than CHD. If the fetus turned out to have a CHD later in pregnancy or postnatally, it was subsequently excluded from further analysis.

To illustrate the potential of fetal electrocardiography for CHD screening, the normal ECG was compared to the ECG of two fetuses prenatally diagnosed with different CHDs. These ECG recordings were performed in the Amsterdam University Medical Center, Amsterdam, the Netherlands and approved by the medical ethics committee of the Amsterdam University Medical Center (2015_221#A201583).

The fetal ECG was recorded with adhesive Ag/AgCl electrodes on the abdomen of the pregnant women in a semi-recumbent position. In total, eight electrodes were placed on the abdomen in a fixed configuration (see Figure 1) in order to yield six channels of bipolar electrophysiological measurements: the other two electrodes served as common reference and ground. Application of the device is comparable to a regular ECG device and takes no more than 5 minutes. For research purposes, the duration of the registration was approximately 30 minutes, during which the fetal position was determined four times by ultrasound assessment. The determination of the fetal position typically took

10-20 seconds. After a short instruction during one measurement medical students were able to perform the measurements and the fetal orientation ultrasounds without supervision.

Figure 1. Measurement setup

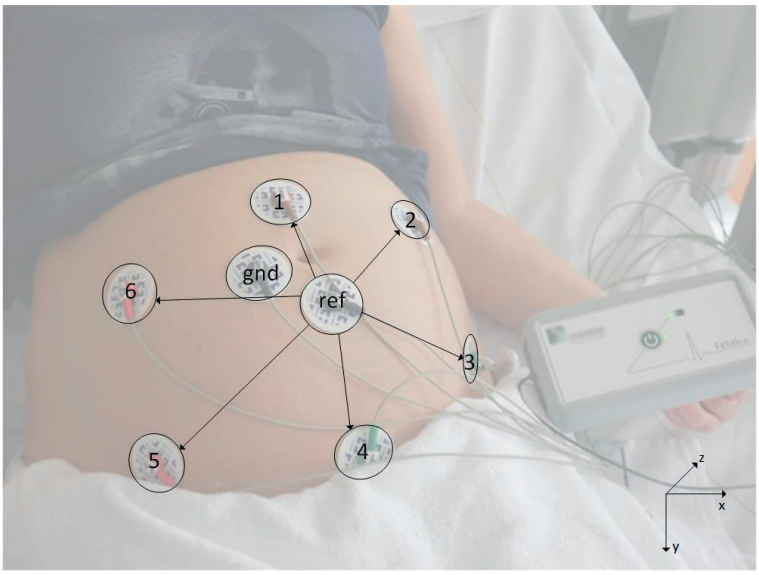

Measurement setup with eight electrodes on the maternal abdomen (six recording electrodes, one common reference (ref), one ground (gnd)) and the prototype fetal monitoring system. The bipolar channels are indicated by the arrows and formed by the electrodes 1-6 with respect to the common reference (eg 1 – ref, 2 – ref). The positions of the electrodes and lead vectors of the recorded channels are defined within the xyz-axis system depicted on the bottom right.

The electrophysiological signals were digitized and stored at 500 Hz sampling frequency by a prototype fetal monitoring system (Nemo Healthcare BV, the Netherlands) to enable analysis in a later stage. After digitization, the acquired signals were processed by PC-based signal processing techniques as previously described by Vullings et al. [9,10] and Warmerdam et al. [11], as illustrated in Figure 2.

Figure 2. Schematic illustration of signal processing to obtain standardized fetal ECG

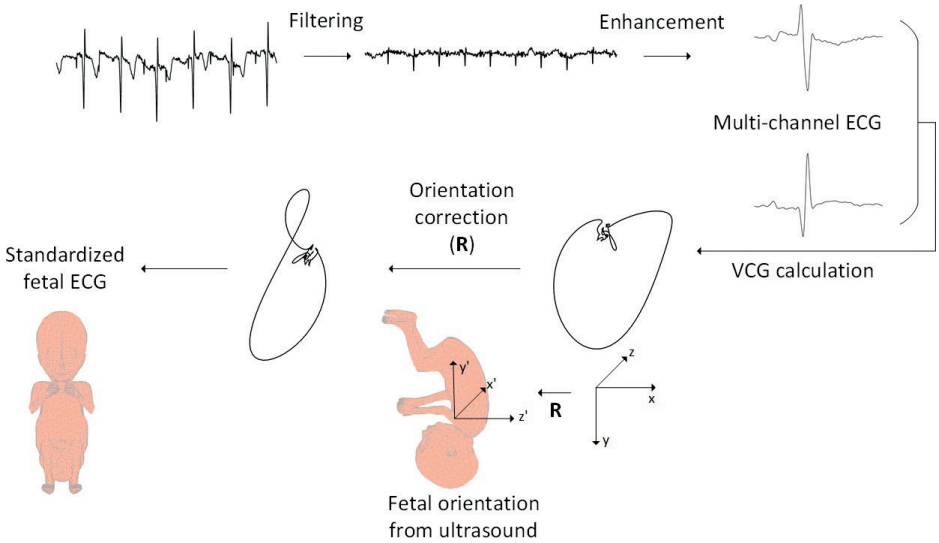

*Schematic illustration of signal processing steps followed to obtain the standardized fetal ECG. From the top left, the consecutive steps are depicted in a clockwise direction. In the first step the raw data was filtered to suppress the maternal ECG. In the next step, the fetal ECG was further enhanced by averaging the ECG over 30 heartbeats. Multi-channel ECG complexes were subsequently combined to calculate the vectorcardiogram (VCG). This VCG is described within a coordinate system (xyz) that is defined with respect to the maternal body. Based on the fetal orientation assessed by ultrasound examination, a mathematical rotation **R** of the VCG was performed to convert the VCG to a coordinate system (x'y'z') that is defined with respect to the fetal body. Finally, the rotated VCG was transformed with the Dower matrix to yield an estimate for the standardized, 12-lead fetal ECG.*

The first step in the process was the suppression of interferences such as the maternal ECG, powerline interference, and electromyographic signals from within the maternal body, using a template-based subtraction technique [10], a Kalman smoother [11], and a bandpass filter[10], respectively. The fetal QRS complexes were then identified using a method described in Warmerdam et al. [12] Subsequently, the fetal ECG signals were segmented in such a way that every segment contained exactly one heartbeat. The length of the segments was defined as mean RR interval (i.e. inter-beat interval) of the particular recording/fetus. The start of each segment was defined such that the R-peak was located at 40% of the segment length. As a consequence, all segments were synchronized on the position of the R-peak.

The QRS detection method of Warmerdam et al. [12] was used to check whether a detected fetal QRS complex was correct or not. This system uses various checks: the interval between successive QRS complexes (i.e. RR-interval) should be in line with the physiological range of the fetal heartbeat (i.e. between 60 and 240 beats-per-minute)

and cannot vary more than 20% between consecutive RR-intervals. Moreover, the morphology of the QRS complexes should be similar between consecutive heartbeats, their energy not be higher than physiologically plausible, and they should not coincide for more than three consecutive heartbeats with the ECG of the mother. The latter criterion was used to prevent the erroneous detection of maternal ECG residues as fetal QRS complexes. When a detected fetal QRS complex did not confirm to all these criteria, it was rejected and excluded from further analysis. We used an average of at least 25 detected fetal QRS complexes per minute as threshold for signal quality. Where this threshold was not met, the entire recording was excluded from further analysis due to low signal quality.

Where the signal quality was assessed as adequate, we enhanced the fetal ECG further by averaging 30 consecutive segments. This procedure was performed for each of the six channels of fetal ECG data.

As mentioned previously, before we could compare ECG waveforms between patients, the ECG needed to be normalized for the fetal orientation. Without such normalization, a specific electrode would record a different ECG waveform for, for example, a fetus in a cephalic position versus the same fetus in a breech position. To normalize for fetal orientation, we first calculated the vectorcardiogram (VCG) of the fetus.[9] This VCG entailed a three-dimensional representation of the fetal electrical cardiac activity, in other words the path of electrical cardiac activation through the heart. The VCG was calculated for each average ECG (i.e. the ECG obtained from averaging 30 consecutive segments). At this point, the fetal VCG was determined in the xyz-coordinate system that was described with respect to the maternal body (see Figure 1, bottom right). In order to facilitate interpretation and standardization of this fetal VCG, it must be placed within a coordinate system that is described with respect to the fetal body. The mathematical rotation that defines this conversion between coordinate systems could be calculated based on an ultrasound assessment of the fetal orientation.

Furthermore, the expectation-maximization algorithm was used to track rotations of the VCG between heartbeats due to fetal movements between the ultrasound assessments (Figure 3).[13] Based on the tracked VCG rotations, we corrected for these fetal movements, using similar mathematical rotations as used for the correction of the fetal orientation. The four ultrasound assessments during the measurements were used to correct for cumulative errors in this movement correction method and to determine the initial orientation of the fetus. After correcting for fetal movements, the VCGs throughout the entire recording were averaged to further enhance signal quality.

Figure 3. Rotation of the VCG between heartbeats due to fetal movement

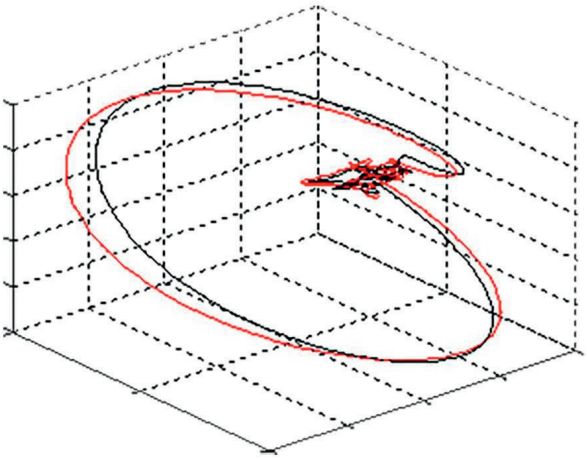

In black the VCG at time t=0, in red the VCG at time t=1. Due to fetal movement there was a rotation of the VCG.

Because clinicians are not used to interpreting a VCG, we chose to visualize the fetal cardiac activity by means of a 12-lead ECG. As described by Dower[14], in adult electrocardiography the VCG can be used to calculate standardized ECG leads. In this study, we used the Dower transformation [15] to calculate a 12-lead ECG from the VCG for each fetus.

The segmentation of the fetal ECG data described above depended on the fetal heart rate during the recording: the length of the segments was defined as the mean RR interval of the fetus during the recording. Because different fetuses have different heart rates, the calculated standardized ECG leads had different lengths across the fetuses. To enable comparison between fetuses, we calculated the average RR interval over all fetuses: in this case a length of 0.44s. Next, we resampled all standardized ECG leads to match this length. As, the R-peak was located at 40% of the segment length for each fetus, after resampling to the uniform segment length of 0.44s, the R-peaks for all fetuses were still at 40% and hence synchronized over all standardized ECG leads.

To assess whether a standardized fetal ECG is feasible, we determined the median amplitude and interquartile range (IQR) for all fetuses with adequate signal quality to yield a median ECG waveform.

Results

Normal hearts

During the study period, informed consent was obtained from 328 participants and a fetal ECG was performed. 37 measurements were excluded from further analysis because we did not receive a postpartum questionnaire (n=14) or because there was no fetal orientation ultrasound available (n=23). In addition two children appeared to have a CHD and three children were diagnosed with a syndrome and were excluded from further analysis. Of the final 286 recordings, 281 were of adequate quality to generate a standardized fetal ECG, yielding a success rate of 98.3 %.

The number of detected QRS complexes in the recordings with sufficient quality ranged from 35 to 156 complexes per minute and from 565 to 6130 detected complexes over the full recording.

Figure 4 shows the median ECG waveform for leads I (left) and aVF (right) in black, with in grey the IQR for the included 299 fetuses.

Figure 4. Normal ECG waveform

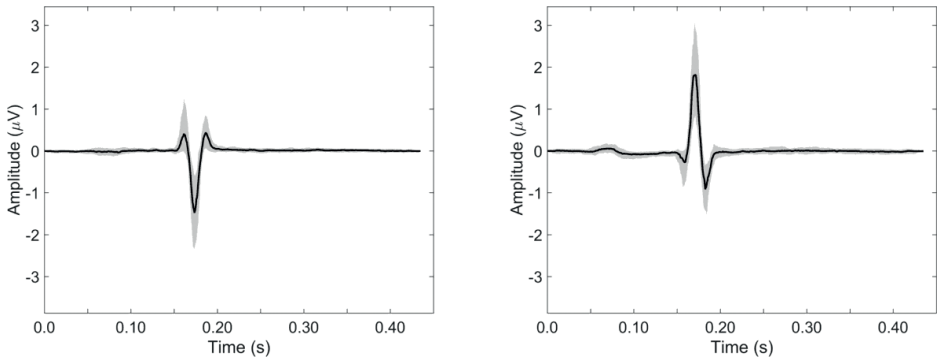

Normal ECG waveform with in black the median over 281 healthy fetuses and in grey the interquartile range, shown for lead I (A) and lead aVF (B).

In Figure 5 the median 12-lead ECG is shown.

Figure 5. 12-lead normal fetal ECG in mid-pregnancy

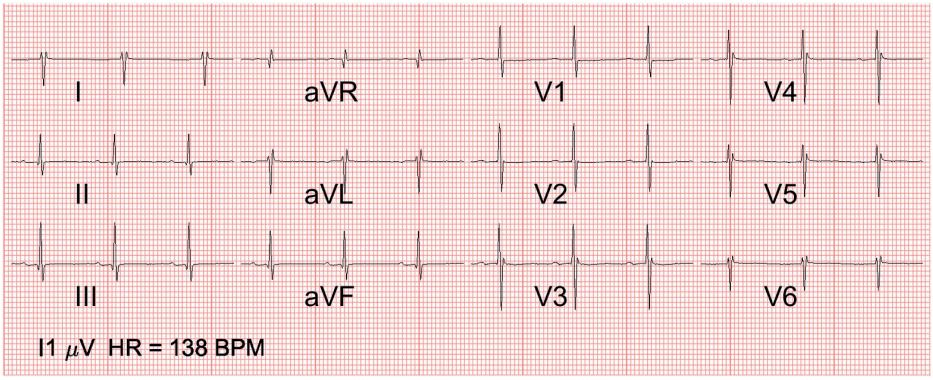

12-lead ECG of the normal fetal heart at 20 weeks of gestation, calculated as the median over 281 healthy fetuses. Note the rightward QRS axis and the right ventricular dominance (positive R wave in V1 with deep S in V6 and failure of R wave progression precordially). The marker on the bottom left indicates the scale at which an amplitude of 1 μV is depicted.

From all the figures, it can be seen that the median ECG waveform indicates an electrical heart axis oriented right inferiorly, based on the negative QRS deflection in lead I and the positive deflection in lead aVF. This suggests a dominant right ventricle, which is in line with the higher cardiac output (volume loading) and pressure loading of this ventricle in-utero.[16–19]

Congenital Heart Disease

ECGs were recorded from two fetuses diagnosed with CHD.

The first patient was diagnosed at 21+2 weeks of gestation with left atrial isomerism (mesocardia, bilateral superior caval veins and polysplenia) and complete atrio-ventricular septal defect (AVSD) with left ventricular dominance. The fetal ECG registration was made at 26+3 weeks of gestation. Postnatally, this baby died suddenly from a group B streptococcal septicemia and the cardiac diagnosis was confirmed at post mortem examination.

The second patient was diagnosed at 16+4 weeks of gestation with a hypoplastic right ventricle, tricuspid stenosis and a dysplastic pulmonary valve (hypoplastic right heart). The fetal ECG registration was made at 20+6 weeks of gestation. The diagnosis was confirmed by post mortem examination after termination of the pregnancy.

In Figure 6, the ECG of the fetus with left atrial isomerism and AVSD can be seen. The QRS axis is abnormal (-45 degrees) and there is a prominent left ventricle. In

Figure 7, the ECG of the fetus with the hypoplastic right heart (a ductal dependent lesion) is depicted. The QRS axis is abnormal (+60 degrees) and there is left ventricular dominance, based on the prominent R waves in V5 and V6.

Figure 6. 12-lead fetal ECG of left isomerism and atrioventricular septal defect

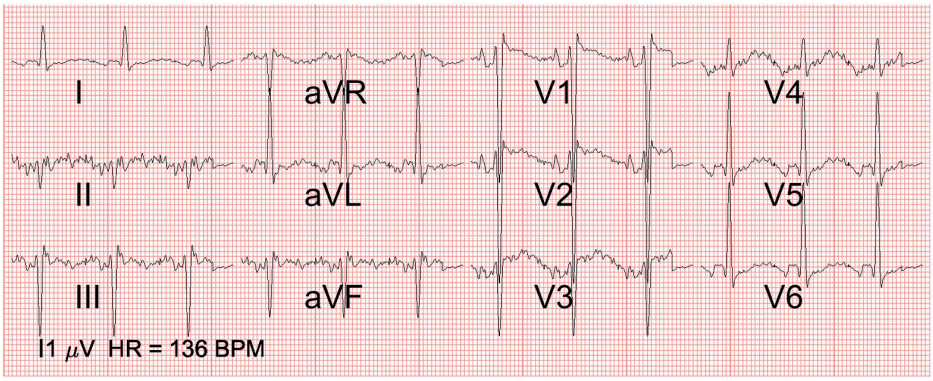

12-lead ECG of case 1 with the atrio-ventricular septal defect: Note the abnormal QRS axis (-45 degrees) and prominent left ventricle (prominent R in V5 and V6 and deep S in V1 and V2 as well as the negative aVR). The marker on the bottom left indicates the scale at which an amplitude of 1 μV is depicted.

Figure 7. 12-lead fetal ECG of hypoplastic right heart

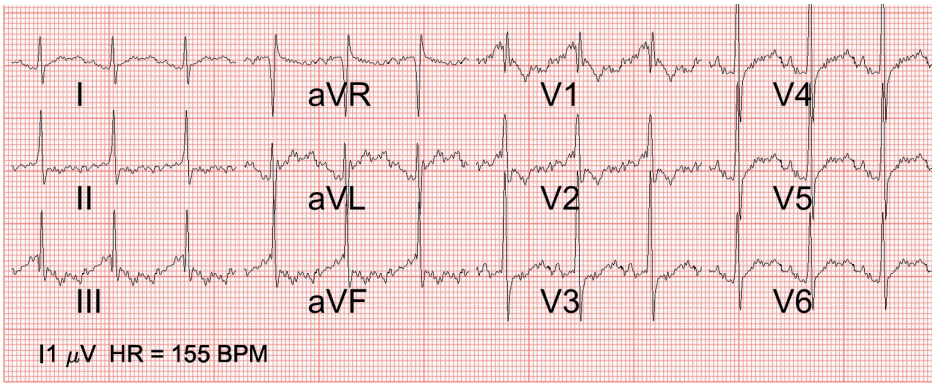

12-lead ECG of case 2 with a hypoplastic right heart (hypoplastic right ventricle, tricuspid stenosis and dysplastic pulmonary valve): Note the abnormal QRS axis (+60 degrees) and left ventricular dominance (prominent R waves in V5 and V6). The marker on the bottom left indicates the scale at which an amplitude of 1 μV is depicted.

To illustrate the difference between these two cases and the normal fetal ECG, in Figure 8 the ECGs of the CHD cases are overlayed on the IQR of the normal for leads I and aVF.

Figure 8. ECG of cases compared to normal ECG

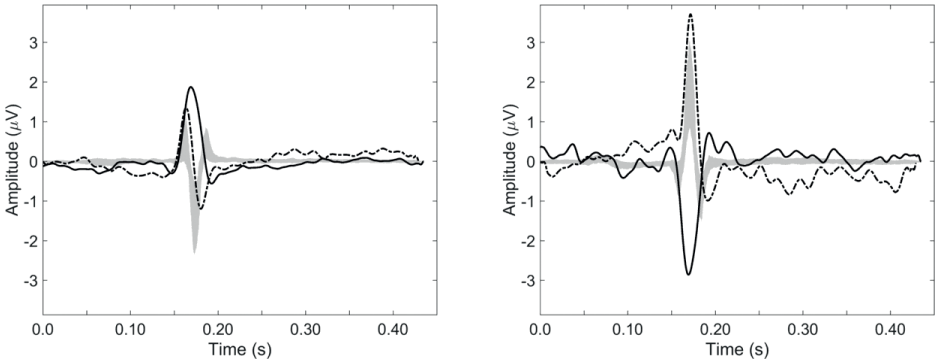

Leads I (A) and aVF (B) for the two CHD cases, plotted together with the IQR of the normal ECG. The gray area represents the IQR of the normal ECG, the solid line represents the fetus with atrio-ventricular septal defect (Figure 6) and the dashed line represents the fetus with hypoplastic right heart (Figure 7).

Discussion

For the first time, we have presented the feasibility of a method for estimating a standardized 12-lead ECG for a healthy fetus around 20 weeks of gestation in which we used ultrasound assessment of the fetal orientation to correct for its influence on the estimated fetal ECG.

When compared to other organs examined during the 20-week anomaly scan, screening of the fetal heart with ultrasound imaging is regarded as the most difficult due to its motion, small size and anatomical complexity. Therefore, CHD in the mid-term fetus is often missed. [20,21] This is especially undesirable because it has been demonstrated that prenatal diagnosis of CHD increases neonatal survival rates and decreases neonatal long-term morbidity.[4–6,22,23] The performance of a fetal ECG could aid screening for CHD in mid-pregnancy in primary care and follow-up in dedicated centers, since it is independent of the experience of the sonographer, difficult fetal imaging due to maternal obesity, an unfavorable fetal position, or reduced amniotic fluid. The fetal ECG might also give more information about the evolution of the CHD during pregnancy and, with that, the health status of the fetus. Although there is no reference to compare our results with, our results show the reproducibility of the 'mean' ECG in all 281 participating fetuses. Furthermore, it can be seen that the standardized ECG has, conform expectations, a right ventricular dominance e.g. a right oriented electrical heart axis. The electrical heart axis represents the median vector of the electrical activity through the heart during one cardiac cycle and gives information about the muscle distribution of the heart. CHD may alter this distribution. The electrical heart axis could thus be a potential indicator for CHD in mid-pregnancy.

The potential use of the fetal ECG in CHD screening was further illustrated by the examination of ECG recordings from the two cases with CHD (Figures 6 and 7). Both cases showed ECG abnormalities (e.g. abnormal QRS axis) when compared to the IQR of the normal ECG (Figure 8).

In the first CHD case, left atrial isomerism with AVSD, there was an abnormal axis due to the altered cardiac conduction system anatomy (causing a left anterior hemi-block) and left ventricular hypertrophy due to the atrio-ventricular valve regurgitation in utero. This case died unexpectedly of septicemia as a neonate but had this not occurred, we would have expected the baby to develop cardiac failure from around two weeks of age and she would have required a complete surgical correction before the age of three months. Case two was a ductal dependent lesion where a prenatal detection is extremely important to ensure the timely postnatal administration of intravenous prostaglandins to keep the arterial duct open. Failure to do so could be life-threatening due to inadequate pulmonary perfusion resulting in acidosis, organ failure, neurological damage and death. Both cases could have been detected by fetal ECG screening.

The high success rate of 98.3% shows the promise of a reliable additional tool for clinical practice, which may be less subject to human interpretation and experience. Besides signal quality, the applicability of this method also depends on the availability to estimate the fetal orientation (e.g. from simultaneous ultrasound examination). Without accurate information on the fetal orientation, normalization for this orientation is not possible and analysis of the fetal ECG has to be limited to the analysis of ECG intervals.

Limitations

The signal analysis methods that were used in our study to enable standardization of the fetal ECG have four main limitations. First, in the calculation of the VCG, information of the amplitude of the fetal ECG and VCG was lost, because the distance between the fetal heart and each of the transabdominal electrodes is different. The thickness of the layers of maternal tissue in between the fetal heart and the electrode varies between the different electrodes and therefore, attenuation of the ECG signal due to conduction of the signal from the heart to electrode will be different for each electrode. Our method for VCG calculation can compensate for such variations in attenuation, but only with normalization of all amplitudes. Besides compensating for inter-electrode differences in ECG signal attenuation, this method has the capacity that inter-patient variations in ECG signal attenuation are also compensated for. Such inter-patient variations could originate from differences in BMI, amount of amniotic fluid, distribution of muscle and fat tissue in the abdomen, and properties of the skin. Second, the calculation of the 12-lead ECG from the VCG via the Dower matrix is based on assumptions about geometrical and conductive properties of the adult thorax that may not fully apply to the fetal thorax. Interpretation of the fetal ECG should therefore not be based on guidelines used for 12-lead adult ECG. The third limitation is that to further enhance signal quality, averaging

over 30 segments (i.e. heartbeats) took place. This entails a trade-off between gain in fetal ECG signal quality and loss of inter-beat variability in the ECG. The gain in signal quality allows for possible diagnosis of structural malformations of the heart, but the concomitant loss of inter-beat variability hampers arrhythmia diagnosis.

Averaging over multiple heartbeats emphasizes the part of the ECG that is common between heartbeats. Structural malformations will affect every heartbeat in more or less the same way and hence be visible in the average ECG. The fourth limitation is that the data was evaluated retrospectively. However, pseudo real-time implementations (i.e. only a few seconds delay) of the described technology are being developed.

Future research should focus on defining normal ranges and values for the fetal ECG in mid-pregnancy, including the electrical heart axis. When normal ranges and values are established research could focus on the application of the fetal ECG for the detection and follow-up of fetal heart disease. An abnormal fetal ECG may expedite a referral for an advanced fetal echocardiogram in dedicated centers in the future.

Conclusion

To conclude, we demonstrated that it is possible to determine a fetal ECG for a healthy fetus at 20-weeks of gestation and standardize this ECG for the fetal orientation. As a result, we have presented the first standardized ECG for a healthy 20-week fetus.

To illustrate the clinical relevance of this standardized fetal ECG, we showed that the standardized ECG thus derived is clearly different from 2 cases with congenital heart disease. Although the recording of a 12-lead fetal ECG is feasible with non-invasive fetal ECG technology, more research is needed to study its implications for clinical practice.

References

1. Tegnander E, Eik-Nes SH. The examiner's ultrasound experience has a significant impact on the detection rate of congenital heart defects at the second-trimester fetal examination.
2. Mahle WT, Clancy RR, McGaurn SP, Goin JE, Clark BJ. Impact of prenatal diagnosis on survival and early neurologic morbidity in neonates with the hypoplastic left heart syndrome. Pediatrics. 2001 Jun;107(6):1277–82.
3. Tworetzky W, McElhinney DB, Reddy VM, Brook MM, Hanley FL, Silverman NH. Improved surgical outcome after fetal diagnosis of hypoplastic left heart syndrome. Circulation. 2001 Mar;103(9):1269–73.
4. Franklin O, Burch M, Manning N, Sleeman K, Gould S, Archer N, Radcliffe J, Way H. Prenatal diagnosis of coarctation of the aorta improves survival and reduces morbidity. 2002;67–70.
5. van Velzen CL, Haak MC, Reijnders G, Rijlaarsdam MEB, Bax CJ, Pajkrt E, Hruda J, Galindo-Garre F, Bilardo CM, de Groot CJM, Blom NA, Clur SA. Prenatal detection of transposition of the great arteries reduces mortality and morbidity. Ultrasound Obstet Gynecol. 2015;45(3):320–5.
6. Brown KL, Ridout DA, Hoskote A, Verhulst L, Ricci M, Bull C. Delayed diagnosis of congenital heart disease worsens preoperative condition and outcome of surgery in neonates. Heart. 2006;92(9):1298–302.
7. Verdurmen KMJ, Lempersz C, Eijsvoogel NB, Vullings R, Schroer C, van Laar JOEH, Oei SG. A systematic review of prenatal screening for congenital heart disease by fetal electrocardiography. Int J Gynecol Obstet. 2016;135(2):129–34.
8. Verdurmen K, Lempersz C, Vullings R, Schroer C, Delhaas T, van Laar JOEH, Oei SG. Normal ranges for fetal electrocardiogram values for the healthy fetus of 18-24 weeks of gestation: a prospective cohort study. BMC Pregnancy Childbirth. 2016 Aug;16(1):227.
9. Vullings R. Bayesian Approach to Patient-Tailored Vectorcardiography. IEEE Trans Biomed Eng. 3AD;57(3):586–95.
10. Vullings R, Peters CHL, Sluijter RJ, Mischi M, Oei SG, Bergmans JWM, R. V, C.H.L. P, R.J. S, M. M, S.G. O. Dynamic segmentation and linear prediction for maternal ECG removal in antenatal abdominal recordings. Physiol Meas. 2009;30(3):291.
11. Warmerdam GJJ. A Fixed-Lag Kalman Smoother to Filter Power Line Interference in Electrocardiogram Recordings. IEEE Trans Biomed Eng. 2017;64(8):1852–61.
12. Warmerdam GJJ, Vullings R, Schmitt L, Laar JOEH Van, Bergmans JWM. Hierarchical Probabilistic Framework for Fetal R-Peak Detection, Using ECG Waveform and Heart Rate Information. IEEE Trans Signal Process. 2018;66(16):4388–97.
13. Vullings R. Novel Bayesian Vectorcardiographic Loop Alignment for Improved Monitoring of ECG and Fetal Movement. IEEE Trans Biomed Eng. 2013;60(6):1580–8.
14. Dower GE. A lead synthesizer for the Frank system to simulate the standard 12-lead electrocardiogram. J Electrocardiol. 1968;1(1):101–16.

15. Dower GE, Machado HB, Osborne JA. On deriving the electrocardiogram from vectoradiographic leads. Clin Cardiol. 1980 Apr;3(2):87–95.
16. Depasquale NP. Electrocardiogram, Ventricular Gradient and Spatial Vectorcardiogram During the First Week of Life. Am J Cardiol. 1963;12:482.
17. Larks SD. Estimation of the Electrical Axis of the Fetal Heart. Am J Obstet Gynecol. 1965;91:46.
18. Rutledge J, Bricker JT. Congenital Diseases of the Heart: Clinical-Physiological Considerations (Fully Revised and Updated Second Edition). Texas Hear Inst J. 2001;28.
19. Verdurmen KMJ, Hulsenboom ADJ, van Laar JOEH, Wijn PFF, Vullings R, Oei SG. Orientation of the electrical heart axis in mid-term pregnancy. Eur J Obstet Gynecol Reprod Biol. 2016;207:243–6.
20. van Velzen CL, Clur SA, Rijlaarsdam MEB, Bax CJ, Pajkrt E, Heymans MW, Bekker MN, Hruda J, de Groot CJM, Blom NA, Haak MC. Prenatal detection of congenital heart disease--results of a national screening programme. BJOG. 2016 Feb;123(3):400–7.
21. Friedberg MK, Silverman NH, Moon-Grady AJ, Tong E, Nourse J, Sorenson B, Lee J, Hornberger LK. Prenatal Detection of Congenital Heart Disease. J Pediatr. 2009;155(1):26-31.e1.
22. Mahle WT, Clancy RR, Mcgaurn SP, Goin JE, Clark BJ, Background A. Impact of Prenatal Diagnosis on Survival and Early Neurologic Morbidity in Neonates With the Hypoplastic Left Heart Syndrome. 2018;107(6).
23. Tworetzky W, Mcelhinney DB, Reddy VM, Brook MM, Hanley FL, Silverman NH. Hypoplastic Left Heart Syndrome. 2001;

CHAPTER 4

The electrical heart axis of the fetus between 18 and 24 weeks of gestation: a cohort study.

Carlijn Lempersz, Lore Noben, Sally-Ann B. Clur, Edwin van den Heuvel, Zhouzhao Zhan, Monique Haak, S. Guid Oei, Rik Vullings, Judith O. E. H. van Laar



Abstract

Introduction: A fetal anomaly scan in mid-pregnancy is performed, to check for the presence of congenital anomalies, including congenital heart disease (CHD). Unfortunately, 40% of CHD is still missed. The combined use of ultrasound and electrocardiography might boost detection rates. The electrical heart axis is one of the characteristics which can be deduced from an electrocardiogram (ECG). The aim of this study was to determine reference values for the electrical heart axis in healthy fetuses around 20 weeks of gestation.

Material and methods: Non-invasive fetal electrocardiography was performed subsequent to the fetal anomaly scan in pregnant women carrying a healthy singleton fetus between 18 and 24 weeks of gestation. Eight adhesive electrodes were applied on the maternal abdomen including one ground and one reference electrode, yielding six channels of bipolar electrophysiological measurements. After removal of interferences, a fetal vectorcardiogram was calculated and then corrected for fetal orientation. The orientation of the electrical heart axis was determined from this normalized fetal vectorcardiogram. Descriptive statistics were used on normalized cartesian coordinates to determine the average electrical heart axis in the frontal plane. Furthermore, 90% prediction intervals (PI) for abnormality were calculated.

Results: Of the 328 fetal ECGs performed, 281 were included in the analysis. The average electrical heart axis in the frontal plane was determined at 122.7° (90% PI: -25.6°; 270.9°).

Discussion: The average electrical heart axis of healthy fetuses around mid-gestation is oriented to the right, which is, due to the unique fetal circulation, in line with muscle distribution in the fetal heart. However, the electrical heart axis alone is not suitable for screening for CHD due to the wide prediction interval.

Introduction

In developed countries, a fetal anomaly scan in mid-pregnancy is performed, to check for the presence of congenital anomalies, including congenital heart disease (CHD). The importance of prenatal CHD detection was shown in previous research that found a reduction in neonatal morbidity and mortality when CHD was diagnosed prenatally. [1,2] The introduction of a standardized screening program for the fetal anomaly scan in mid-pregnancy has led to an increase in prenatal CHD detection rates in the Netherlands up to 40-60%. However, 40% of CHD is still missed.[3] Ultrasound detection of CHD is difficult due to fetal body movements, the small size and rhythmic movements of the fetal heart. Furthermore, detection rates depend on the experience of the sonographer, fetal position and BMI of the mother.[4–13] To further increase prenatal detection of CHD, new diagnostic tools are needed.

This tool might be the non-invasive fetal electrocardiogram (NI-fECG). NI-fECG enables the production of a 12-lead electrocardiogram by means of a standardized method. ST-segment elevations are seen in ischemia and deviation of the electrical heart axis occurs in some cardiac malformations cardiac malformations (e.g. hypoplastic right heart syndrome, atrioventricular septal defect). [14–16]. The electrical heart axis is one of the characteristics which can be deduced from an ECG. It represents the median vector of the electrical activity through the heart during one cardiac cycle and provides information about the muscle distribution of the heart.

Verdurmen et al. found a right-oriented electrical heart axis in healthy fetuses.[17] This has also been described in term fetuses during labor and neonates. [18,19] The right-oriented electrical heart axis in healthy fetuses can be explained by the fetal circulation that has a unique physiology with multiple shunts to bypass the lungs, so that the right ventricle pumps 60% of the cardiac output, leading to a right ventricular dominance. After birth the pulmonary vascular resistance drops and the venous return to the left atrium increases leading to an increase in the cardiac output of the left ventricle. The left ventricle pumps against the high resistance systemic system once the placental circulation is eliminated.[20] With time the left ventricular muscle mass gradually increases and a leftwards shift of the electrical heart axis occurs. We hypothesize that the presence of certain CHD can already cause a deviated electrical heart axis in utero.

The aim of this paper was to determine reference values for the electrical heart axis in mid-term healthy fetuses.

Materials and Methods

The study protocol was previously published by Verdurmen et al.[21] Ethical approval by the institutional review board of the Máxima Medical Center was obtained before enrolment (NL48535.015.14). Fetal ECG measurements were performed from May 2014 until September 2018 at the Máxima Medical Centre Veldhoven, The Netherlands, a

tertiary care referral center for obstetrics and at 'Diagnostiek voor U' diagnostic center, Eindhoven, The Netherlands.

Study population

Pregnant women carrying a singleton fetus without known congenital anomalies and a gestational age between 18 and 24 weeks of gestation were included. All patients were older than 18 years and gave written informed consent prior to the fetal ECG measurement.

Patients who did not understand the Dutch language well and/or had multiple pregnancies were excluded. If CHD was found later in pregnancy or after birth, the measurement was excluded from analysis.

The following data was gained prospectively: maternal gravidity and parity, as well as obstetric and general medical history. Parents received a questionnaire three months after birth to confirm that the child was healthy and did not have any congenital diseases. We chose this three-month cut-off point as at this age, all children in the Netherlands have had their second medical check-up by a doctor, who, among other things, evaluated cardiac health.

fECG Measurements and signal processing

Singular fetal ECG measurements were performed subsequent to the fetal anomaly scan. Women lay in a semi-recumbent position to prevent aortocaval compression. To yield six channels of bipolar electrophysiological measurements, eight electrodes were placed on the maternal abdomen in a fixed configuration. Two electrodes served as common reference and ground electrodes respectively (Figure 1 [22]). Before application of the electrodes the skin was washed with water and soap after which skin preparation was performed with medical abrasive paper (Red DotTM Trace Prep, 3M Health Care, Ontario, Canada) to optimize skin impedance. Each measurement lasted around 30 minutes during which fetal orientation was ultrasonographically checked following a protocol at four fixed time intervals. After a short training by an experienced researcher, gynecologist or sonographer the researcher (usually a medical student) was able to determine the fetal orientation. The protocol described how the ultrasound should be made and in which planes. The researcher than depicted those planes on a form. Furthermore, the ultrasound pictures with the position of the probe were printed so they could later be checked by a fellow researcher or gynecologist.

Figure 1. Measurement set-up of the non-invasive fetal electrocardiogram.

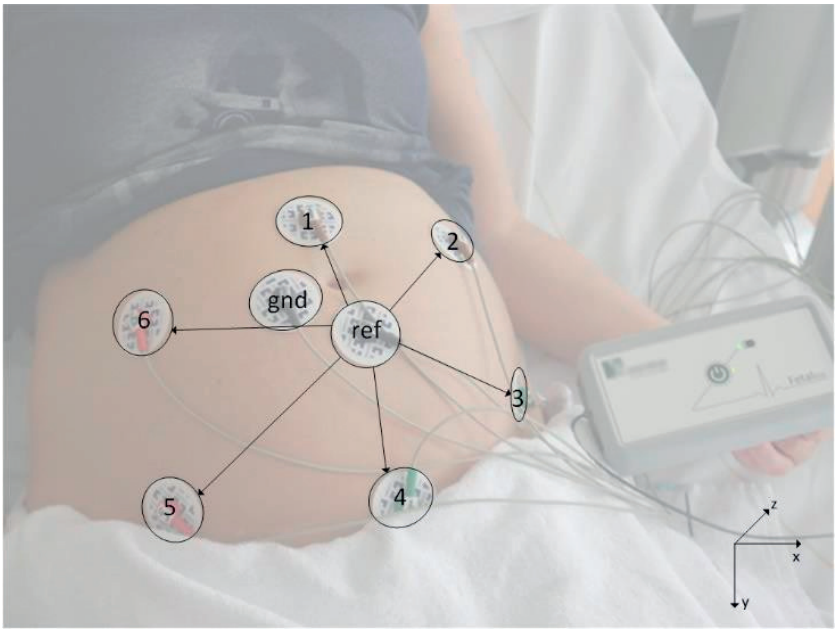

Eight electrodes were placed on the maternal abdomen in a fixed configuration. Two electrodes served as common reference (Ref) and ground (Gnd). The cartesian coordinate system as used in our analyses is displayed in the bottom right corner.[22]

Fetal ECG measurements were performed with a 6-channel electrophysiological amplifier (Nemo Healthcare BV, The Netherlands) using adhesive Ag/AgCl electrodes (Red DotTM, 3M Health Care, Ontario, Canada) on the maternal abdomen. The measured electrophysiological signals were digitized at 500 Hz sampling frequency and stored on a computer for offline analysis.

This offline analysis consisted of a series of signal processing steps, aimed to suppress interferences and standardize the fetal ECG signals for fetal orientation, so that the fetal electrical heart axis could be measured. These signal processing steps have been described in more detail in Lempersz et al. 2020.[22] In the first step of signal processing, interferences from the maternal ECG, abdominal muscles, and extracorporal sources were suppressed by an adaptive template-based method [23]. As a result, for each of the six recorded signals a fetal ECG signal was obtained, yet at relatively low signal-to-noise ratio. Because each fetus could have a different orientation with respect to the maternal abdomen and the recording electrodes placed on this abdomen, the fetal ECG signals not only changed between participants, but also within participants due to fetal movement.

The second step in the signal processing aimed to standardize for fetal orientation. To allow for such standardization, a fetal vectorcardiogram was calculated for every

heartbeat first, combining the information from the six abdominal signals into a 3-dimensional fetal ECG complex [24]. This vectorcardiogram could subsequently be tracked over time, detecting fetal movements and correcting for them by rotating the fetal vectorcardiogram in 3-dimensional space. Finally, another rotation in 3-dimensional space was applied that corrected for the fetal orientation, which was assessed from intermittent ultrasound scans. For instance, if the ultrasound indicated that the fetus was in a cephalic position, the recorded fetal vectorcardiogram was rotated by 180 degrees to represent the fetal vectorcardiogram as if the fetus was in a breech position, similar to the position used when making adult ECGs. Similarly, a fetal back to the front was rotated along the longitudinal axis as if the fetal back was to the back. The parts of the measurements of sufficient signal quality, closest to the performance of the ultrasound determining fetal orientation, were used to create the vectorcardiogram.

Finally, to enhance the signal-to-noise ratio, orientation-standardized fetal vectorcardiograms were averaged over multiple heartbeats to yield one fetal vectorcardiogram per measurement.

The orientation of the electrical heart axis was defined as the direction in which the vectorcardiogram had its maximum amplitude.[14] The latter direction was estimated as the average direction of the dominant vectors in the QRS complex, defined as the vectors from the point that the R-wave exceeded 70% of its maximum value until the point that it fell below 70% of the maximum value. The orientation of the fetal heart axis was expressed in degrees ranging from minus 180° to plus 180° and calculated in the frontal plane, where minus 90° is located superiorly.

Statistical analysis

The observed frontal angle was determined in the (x,y)-plane. The normalized coordinates $(\tilde{x}, \tilde{y})$ were calculated as the division of the originate coordinates (x, y) by their Euclidean norm $\sqrt{x^2 + y^2}$.

We calculated descriptive statistics (median with interquartile range (IQR)) on the normalized $(\tilde{x}, \tilde{y})$ Cartesian coordinates. We also reported the average frontal axis with 90% prediction intervals that would function as reference values. Prediction intervals are chosen because they account for the uncertainty in estimating the population mean and the random variation of the individual values.[25] The prediction intervals were calculated, using the lower and upper quantiles of the Von Mises distribution with the estimated parameters.

Statistical analysis was conducted with SAS (version 9.4, SAS Institute Inc., NC, USA) and R (version 3.5.3, R Foundation, Vienna, Austria). Descriptive statistics (median with interquartile ranges) were used to describe baseline characteristics, using IBM SPSS statistics version 25.0 (SPSS Inc., Chicago, Ill., USA).

Data is available upon request.

Results

A total of 328 patients were included. From these, 15 measurements were excluded due to missing or incomplete questionnaires and 23 measurements were excluded due to missing information on the fetal orientation. CHD was found in one neonate and a chromosomal disorder was present in three neonates as reported in the postpartum questionnaire, necessitating their exclusion. Of the remaining 286 inclusions (87.2% of the original 328 included patients), five measurements had to be excluded due to poor quality NI-fECG recordings. A total of 281/286 measurements were available for further analysis giving a success rate of 98%. Table 1 shows the characteristics of the study population. Figure 2 shows a flowchart of the included measurements.

Table 1. Baseline characteristics of participants (N=281)

	Mean (± SD)
Age (years)	31.3 (± 4.0)
GA (weeks)	20.2 (± 1.3)
Nulliparous (%)	52.3
BMI (kg/m^2)	24.4 (± 5.4)

Abbreviations: GA = gestational age, BMI = body mass index.

Figure 2. Flowchart of the included measurements

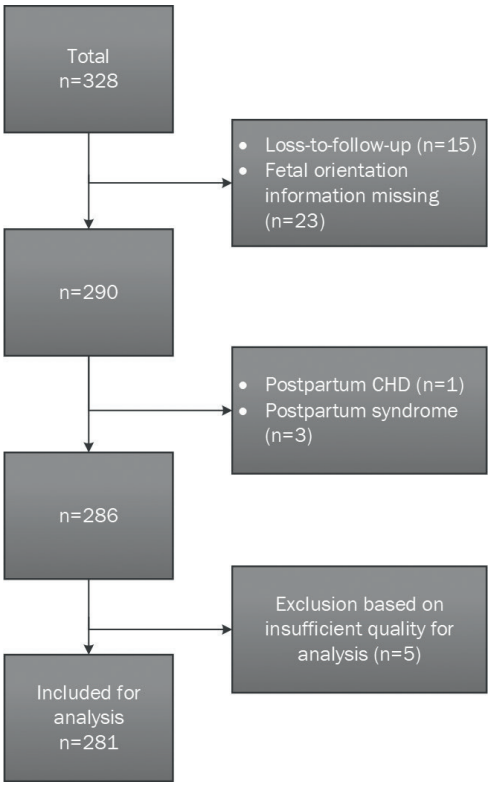

Figure 3 is an example of a fetal electrocardiogram, here one can see a clear QRS-complex.

Figure 3. Example of a fetal electrocardiogram. Lead I and aVF.

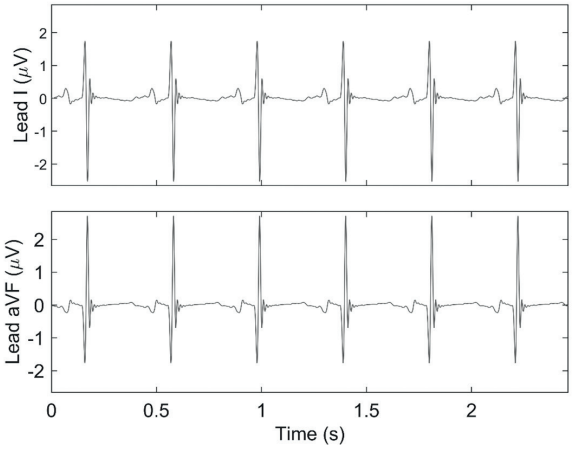

x-axis is time in seconds (s), y-axis is electric potential in microvolts (μV)

The median and interquartile range (IQR) of the $\tilde{x}$ coordinate was 0.347 (1.660) and that of the $\tilde{y}$ coordinate was 0.327 (0.956). Based on these normalized coordinates, the average frontal angle was determined at 122.68° (90% PI: -25.6°; 270.9°). Figure 4 shows the distribution of the orientation of the electrical heart axis of each fetus. The arrow shows the mean electrical heart axis with, in grey, corresponding 90% PI in the frontal plane.

Figure 4. Distribution of the orientation of the electrical heart axis plotted in a circle diagram.

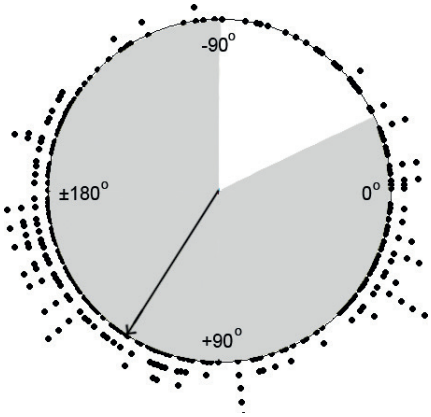

Each dot represents one fetus. The arrow represents the mean electrical heart axis with corresponding 90% PI in the frontal plane in grey.

Discussion

Main Findings

In this paper we present reference values for the electrical heart axis calculated from our cohort of 281 healthy fetuses at mid-gestation. We found that the mean electrical heart axis of the healthy fetus is orientated to the right (122.68°), which is in line with the distribution of fetal cardiac muscle mass due to the unique anatomy of the fetal circulatory system and findings from previous studies. [16–19,26] We found that the prediction intervals based on our cohort are wide, indicating a broad range wherein future observations will fall.

Strengths and Limitations

The main strength of this study is the large group of participants and the low number of recordings excluded due to insufficient data quality. The latter shows that this technology has improved significantly compared to earlier reported research. [27–29] This high success rate is an indispensable characteristic for any technology to be implemented in daily practice. However, the time needed to process the recordings is at this moment the limiting factor for the NI-fECG technology, which currently still takes place offline. Therefore, results are not yet readily available during the measurement. This can be solved by automatization of the signal processing algorithms in the future which can then be incorporated in the measurement hardware. Furthermore, correction for fetal orientation by ultrasound could give minor inaccuracies. To minimize potential inaccuracies, the data recorded closest to the time of fetal orientation determination with ultrasound were used to create a vectorcardiogram.

Interpretation

To our knowledge, this is the first study that determines reference values for the electrical heart axis in healthy midterm fetuses. Recent advances in the signal processing algorithms have made it possible to acquire information on the fetal ECG in the antenatal period in a non-invasive manner. This makes it possible to define reference values for the electrical heart axis in healthy fetuses in mid-pregnancy.

The electrical heart axis reflects the distribution of muscle mass in the fetal heart. In the fetal circulation with its three obligatory shunts and the high resistance pulmonary and low resistance systemic circulations, the right ventricle is dominant and pumps about 60% of the cardiac output. As a consequence the muscle mass of the right ventricle is greater than that of the left ventricle and this results in greater amplitude of depolarization together with decreased speed of depolarization on the right side. [30] Our results confirm this right oriented electrical heart axis in healthy fetuses. The next step towards determining the use of this parameter for screening purposes is to define the electrical heart axis in fetuses with CHD.

Studies in neonates with CHD have already shown changes in the electrical heart axis in certain types of CHD. [14–16] For instance, a deviation of the electrical heart axis to the left is seen in neonates with an atrioventricular septal defect (AVSD). This altered electrical activation is associated with anatomic displacement of the left ventricular (LV) papillary muscles (PM). The fascicles of the left bundle branch end at the insertion places of the PM on the ventricular wall and therefore function as (the) most lateral starting points of LV activation. In the case of an AVSD, the anterior PM is positioned relatively closer to the septum than the posterior PM which causes a delay of activation of the anterior LV free wall and therefore left axis deviation in the frontal plane.[31]

In other CHD, the structural defect directly influences cardiac hemodynamics and the hereby altered distribution of the cardiac musculature might cause deviation of the electrical heart axis. For example, in hypoplastic right heart disease the electrical heart axis is expected to be deviated to the left due under development of the right-sided cardiac structures. In the same way, fetuses with hypoplastic left heart syndrome would be expected to have a right oriented electrical heart axis. In these fetuses, the electrical heart axis alone will not add in differentiating these CHD from the healthy fetal heart. Here, other morphologic changes in the fetal ECG need to be explored in order to optimize the detection rates of these defects. The same applies to conotruncal CHD, which would be expected to have a right-oriented electrical heart axis. [14,32]

Fetal electrocardiography is an easy to use, non-invasive, safe technology with a minimal burden for the pregnant women. Further research towards the electrical heart axis in fetuses with different types of CHD is necessary to determine which defects are associated with a deviated fetal electrical heart axis. Then the NI-fECG could be performed in addition to the fetal anomaly scan around the 20th week of gestation as part of prenatal screening after automatization of the signal processing of the recording. A point of attention is the broad distribution of the electrical heart axis found in our cohort of healthy fetuses in mid-pregnancy. This resulted in wide predictions intervals [-25.6°; 270.9°] making the use of the electrical heart axis alone as a parameter for the screening of CHD less suitable. Future research towards ECG waveform and ECG intervals may add to the development of additional ECG parameters which could further enhance the prenatal detection of CHD.

The use of the electrical heart axis as a screening parameter on its own may not be of great value, however the electrical heart axis may be of value in fetuses with critical aortic or pulmonary stenosis where there may be a change in the electrical heart axis overtime (i.e. more leftward in critical pulmonary stenosis and more rightward in critical aortic stenosis). Here, the electrical heart axis may be used to observe the consequences of the cardiac defect in utero when pregnancy continues. For this purpose normal serial fetal ECG reference ranges are needed. The use of the electrical heart axis in fetuses with a known CHD could be a subject for future research.

Conclusion

Our results confirm that the mean electrical heart axis of healthy fetuses around mid-gestation is oriented to the right. The wide prediction interval for the frontal heart axis found in our cohort, is unfavorable for future implementation of this method for screening purposes. Further research towards the electrical heart axis in fetuses with CHD as well as additional ECG waveform and intervals may elucidate the role of fetal ECG as a screening parameter for the detection of CHD.

References

1. Cloete E, Bloomfield FH, Sadler L, de Laat MWM, Finucane AK, Gentles TL. Antenatal Detection of Treatable Critical Congenital Heart Disease Is Associated with Lower Morbidity and Mortality. J Pediatr. 2019;204:66–70.
2. Brown KL, Ridout DA, Hoskote A, Verhulst L, Ricci M, Bull C. Delayed diagnosis of congenital heart disease worsens preoperative condition and outcome of surgery in neonates. Heart. 2006;92(9):1298–302.
3. van Velzen CL, Clur SA, Rijlaarsdam MEB, Bax CJ, Pajkrt E, Heymans MW, Bekker MN, Hruda J, de Groot CJM, Blom NA, Haak MC. Prenatal detection of congenital heart disease--results of a national screening programme. BJOG. 2016 Feb;123(3):400–7.
4. Allan L. Fetal cardiac scanning today. Prenat Diagn. 2010 Jul;30(7):639–43.
5. DeVore GR, Medearis AL, Bear MB, Horenstein J, Platt LD. Fetal echocardiography: factors that influence imaging of the fetal heart during the second trimester of pregnancy. J Ultrasound Med. 1993 Nov;12(11):659–63.
6. Friedberg MK, Silverman NH, Moon-Grady AJ, Tong E, Nourse J, Sorenson B, Lee J, Hornberger LK. Prenatal Detection of Congenital Heart Disease. J Pediatr. 2009;155(1):31.e1.
7. Garne E, Stoll C, Clementi M. Evaluation of prenatal diagnosis of congenital heart diseases by ultrasound: experience from 20 European registries. Ultrasound Obstet Gynecol. 2001;17(5):386–91.
8. Michelfelder EC, Cnota JF. Prenatal Diagnosis of Congenital Heart Disease in an Era of Near-Universal Ultrasound Screening: Room for Improvement. J Pediatr. 2009;155(1):9–11.
9. Pinto NM, Keenan HT, Minich LL, Puchalski MD, Heywood M, Botto LD. Barriers to prenatal detection of congenital heart disease: a population-based study. Ultrasound Obstet Gynecol. 2012;40(4):418–25.
10. Robinson J, Simpson L, Abuhamad A. Screening For Fetal Heart Disease With Ultrasound. Clin Obstet Gynecol. 2003 Dec;46(4):890–6.
11. Eastwood KA, Daly C, Hunter A, McCance D, Young I, Holmes V. The impact of maternal obesity on completion of fetal anomaly screening. J Perinat Med. 2017;45(9):1061–7.
12. Hunsley C, Farrell T. The influence of maternal body mass index on fetal anomaly screening. Eur J Obstet Gynecol Reprod Biol. 2014;182:181–4.
13. Tegnander E, Eik-Nes SH. The examiner's ultrasound experience has a significant impact on the detection rate of congenital heart defects at the second-trimester fetal examination.
14. Sosi-Pallares D, Pileggi F, Cisneros F, Ginefra P, Portillo B, Medrano GA, Bisteni A. The mean manifest electrical axis of the ventricular activation process (AQRS) in congenital heart disease: a new approach in electrocardiographic diagnosis. Am Heart J. 1958 May;55(5):681–700.
15. Brink AJ, Neill CA. The electrocardiogram in congenital heart disease; with special reference to left axis deviation. Circulation. 1955 Oct;12(4):604–11.

16. Neill CA, Brink AJ. Left axis deviation in tricuspid atresia and single ventricle; the electrocardiogram in 36 autopsied cases. Circulation. 1955 Oct;12(4):612–9.
17. Verdurmen KMJ, Hulsenboom ADJ, van Laar JOEH, Wijn PFF, Vullings R, Oei SG. Orientation of the electrical heart axis in mid-term pregnancy. Eur J Obstet Gynecol Reprod Biol. 2016;207(Dec. 2016):243–6.
18. Depasquale NP. Electrocardiogram, Ventricular Gradient and Spatial Vectorcardiogram During the First Week of Life. Am J Cardiol. 1963;12:482.
19. Larks SD. Estimation of the Electrical Axis of the Fetal Heart. Am J Obstet Gynecol. 1965;91:46.
20. Tissot C, Singh Y, Sekarski N, Sekarski N. Echocardiographic Evaluation of Ventricular Function—For the Neonatologist and Pediatric Intensivist. 2018;6(April):1–12.
21. Verdurmen K, Lempersz C, Vullings R, Schroer C, Delhaas T, van Laar JOEH, Oei SG. Normal ranges for fetal electrocardiogram values for the healthy fetus of 18-24 weeks of gestation: a prospective cohort study. BMC Pregnancy Childbirth. 2016 Aug;16(1):227.
22. Lempersz C, van Laar JOEH, Clur S-AB, Verdurmen KM, Warmerdam GJ, van der Post J, Blom NA, Delhaas T, Oei SG, Vullings R. The standardized 12-lead fetal electrocardiogram of the healthy fetus in mid-pregnancy: A cross-sectional study. PLoS One. 2020;15(4):e0232606.
23. Vullings R, Peters CHL, Sluijter RJ, Mischi M, Oei SG, Bergmans JWM. Dynamic segmentation and linear prediction for maternal ECG removal in antenatal abdominal recordings. Physiol Meas. 2009;30(3):291.
24. Vullings R, Peters CHL, Mossavat I, Oei SG, Bergmans JWM. Bayesian Approach to Patient-Tailored Vectorcardiography. IEEE Trans Biomed Eng. 2010;57(3):586–95.
25. Prediction Intervals [Internet]. [cited 2021 Jan 4]. Available from: https://www.graphpad.com/support/faq/the-distinction-between-confidence-intervals-prediction-intervals-and-tolerance-intervals/
26. Brink AJ, Neill CA, Sodi-Pallares D, Pileggi F, Cisneros F, Ginefra P, Portillo B, Medrano GA, Bisteni A. The mean manifest electrical axis of the ventricular activation process (AQRS) in congenital heart disease: a new approach in electrocardiographic diagnosis. Circulation. 1955 Oct;12(4):612–9.
27. van Laar JOEH, Warmerdam GJJ, Verdurmen KMJ, Vullings R, Peters CHL, Houterman S, Wijn PFF, Aniessen P, van Pul C, Oei SG. Fetal heart rate variability during pregnancy, obtained from non-invasive electrocardiogram recordings. Acta Obstet Gynecol Scand. 2014;93(1):93–101.
28. Verdurmen KMJ, Hulsenboom ADJ, van Laar JOEH, Oei SG. Effect of tocolytic drugs on fetal heart rate variability: a systematic review. J Matern Fetal Neonatal Med. 2017;30(20):2387–94.
29. Noben L, Verdurmen KMJ, Warmerdam GJJ, Vullings R, Oei SG, van Laar JOEH. The fetal electrocardiogram to detect the effects of betamethasone on fetal heart rate variability. Early Hum Dev. 2019 Mar;130:57–64.
30. Hall JE. Guyton and Hall Textbook of Medical Physiology. In: 13th ed. 2016. p. 144–7.

31. Hakacova N, Wagner GS, Idriss SF. Electroanatomic relationships in patients with primum atrioventricular septal defect. JACC Cardiovasc Imaging. 2009 Dec;2(12):1357–65.

32. Benchimol A, Lucena EG. Vectorcardiography in congenital heart disease with the use of the Frank system. Br Heart J. 1965 Mar;27:236–51.

CHAPTER 5

The electrical heart axis in fetuses with congenital heart disease, measured with non-invasive fetal electrocardiography.

L. Noben, C. Lempersz, E.R. van den Heuvel, Z. Zhan, F.P.H.A. Vandenbussche, A.B.C. Coumans, M.C. Haak, R. Vullings, S.G. Oei, S.A.B Clur, J.O.E.H. van Laar

In preparation

Abstract

Objectives: To determine if the electrical heart axis in different types of congenital heart defects (CHD) differs from the electrical heart axis as determined in our healthy cohort at mid-gestation.

Methods: Non-invasive fetal electrocardiography (NI-fECG) was performed in women carrying a singleton fetus with a suspected CHD between 16 and 30 weeks of gestation. The mean electrical heart axis (MEHA) was determined from the fetal vectorcardiogram after correction for fetal orientation. Descriptive statistics were used to determine the MEHA with corresponding 95% confidence intervals (CI) in the frontal plane of all fetuses with CHD and the following subgroups: conotruncal anomalies (CTA), atrioventricular septal defects (AVSD) and hypoplastic right heart syndrome (HRHS). The MEHA of the CHD fetuses was compared to the previously published healthy control group. A spherically projected multivariate linear regression analysis was used to determine differences in the frontal axis between healthy controls and the CHD subgroups. Discriminant analysis was applied to calculate the sensitivity and specificity of the electrical heart axis for CHD detection.

Results: The MEHA was determined in 127 fetuses. The MEHA was 83.0° (95% CI: 6.7°; 159.3°) in the total CHD group, and not significantly different from the control group (122.7°(95% CI: 101.7°; 143.6°). The MEHA was 105.6° (95% CI: 46.8°; 164.4°) in the CTA group (n=54), -27.4° (95% CI: -118.6°; 63.9°) in the AVSD group (n=9) and 26.0° (95% CI: -34.1°; 86.1°) in the HRHS group (n=5). The MEHA of the AVSD and the HRHS subgroups were significantly different from the control group (resp. p=0.04 and p=0.02).The sensitivity and specificity of the MEHA for the diagnosis of CHD was 50.6% (95% CI 47.5% - 53.7%) and 60.1% (95% CI 57.1% - 63.1%) respectively.

Conclusion: The MEHA alone does not discriminate between healthy fetuses and fetuses with CHD. However, the left-oriented electrical heart axis in fetuses with AVSD and HRHS was significantly different from the control group suggesting that cardiac conduction is influenced by the structural defect. More research is required to assess if the fetal ECG performed in addition to the fetal anomaly scan can increase prenatal detection rates of CHD.

Introduction

Congenital heart disease (CHD) is the most common congenital anomaly, with a reported prevalence of 8 per 1000 live births.[1–3] It is a major cause of neonatal morbidity and mortality.[1–10] Prenatal detection of CHD allows for deliberate management to optimize the preoperative neonatal condition and therefore improve neonatal outcome. Furthermore, it keeps the option of pregnancy termination open if the diagnosis is made before the legal limit for pregnancy termination in the said country.[11–16]

Screening for CHD is currently performed by means of the second-trimester anomaly scan around 20 weeks of gestation.[17] Since the introduction of national screening programs, the overall detection rate for CHD in low-risk populations increased up to 50-60% in Europe.[6,8,18–21] The detection rate is strongly correlated with the severity of the CHD.[22] The highest detection rates are those of univentricular defects such as hypoplastic left heart syndrome and heterotaxy, reaching up to 90%.[18,22] The lowest detection rates are seen in CHD involving the outflow tracts, which are not visible on the four chamber view.[22] Recent evaluation showed that adding the three vessel view as part of the screening program significantly increased detection rates of both tetralogy of Fallot (TOF) and transposition of the great arteries (TGA).[23] In specialized tertiary care centers with experienced sonographers, the general detection rate of CHD rose up to 89%.[24] However, only 10% of the infants born with CHD are born to mothers with known risk factors, and therefore end up in tertiary care.[25]

We hypothesize that non-invasive fetal electrocardiography (NI-fECG) can play a role in raising detection rates for CHD, primarily in the low-risk population. We previously showed a right-oriented electrical heart axis in healthy fetuses, due to fetal right ventricular dominance as a result of the unique fetal circulation and differential ventricular cardiac output favoring the right ventricle.[26] Structural anomalies in fetuses with CHD may be associated with an abnormal electrical heart axis as is seen postnatally. The objective of this study was to investigate the possibility to detect CHD based on a deviated electrical heart axis.

Materials and methods

We conducted a multicenter case-cohort study from May 2014 until September 2018 at the following tertiary care hospitals in the Netherlands: Máxima Medical Center Veldhoven, Amsterdam University Medical Center, Radboud University Medical Center Nijmegen, Leiden University Medical Center and Maastricht University Medical Center. The study protocol was approved by the institutional review board of the Máxima Medical Center, Veldhoven, the Netherlands (NL48535.015.14). Written informed consent was obtained prior to enrolment.

Study population

Women pregnant with a fetus suspected for CHD, based on advanced ultrasound evaluation, were asked to participate in this prospective cohort study. Women 18 years or older and pregnant of a singleton between 16 and 30 weeks of gestation were included. In addition, measurements of fetuses who were included in our previously published healthy cohort and diagnosed with CHD postpartum were transferred to the CHD cohort. [27] (ref chapter 4) Exclusion criteria were a fetal cardiac arrhythmia and insufficient understanding of the Dutch language.

The following data was gained prospectively: general medical history, maternal gravidity and parity, obstetrical history, gestational age at inclusion, suspected CHD based on fetal echocardiography. Postpartum, neonatal charts were checked for confirmation of the CHD through echocardiography by a pediatric cardiologist. If the pregnancy was terminated immaturely, post mortem examination reports were consulted if available.

Measurements

Fetal ECG measurements were performed using a prototype fetal ECG system (Nemo Healthcare BV, the Netherlands) after a fetal echocardiographic examination in a tertiary care center. Pregnant women were positioned in a semi-recumbent position to prevent aortocaval compression. Eight adhesive Ag/AgCl electrodes (Red DotTM, 3M Health Care, Ontario, Canada) were placed on the abdomen in a fixed configuration in order to yield six channels of bipolar electrophysiological measurements. Two electrodes functioned as common ground and reference electrode respectively (Figure 1). Before applying the electrodes, the abdominal skin was washed with water and soap and then scrubbed using medical abrasive paper (Red DotTM Trace Prep, 3M Health Care, Ontario, Canada) to optimize skin impedance. Each measurement lasted around 40 minutes. The position of the fetus was determined by ultrasonography at four fixed time intervals during the measurement.

The recordings were digitized at 500Hz sampling frequency and stored on a computer for offline analysis. This offline analysis consisted of a series of signal processing steps, designed to suppress interferences and standardize the fetal ECG signals for fetal orientation, so that the fetal electrical heart axis could be measured. These signal processing steps have been described in more detail in Lempersz et al.[28] In the first step of signal processing, interferences from maternal ECG, abdominal muscles, and extracorporal sources were suppressed by an adaptive template-based method.[29] As a result, for each of the six recorded signals a fetal ECG signal is obtained, yet at relatively low signal-to-noise ratio. Because each fetus could have a different orientation with respect to the maternal abdomen and the recording electrodes placed on the abdomen, the fetal ECG signals could be different between participants, but also within participants due to fetal movement.

The second step in the signal processing aimed to standardize for fetal orientation. To allow for such standardization, first for every heartbeat a fetal vectorcardiogram was calculated, combining the information from the six abdominal signals into a 3-dimensional fetal ECG complex.[30] This vectorcardiogram could subsequently be tracked over time, detecting fetal movements and correcting for them by rotating the fetal vectorcardiogram in 3-dimensional space. Finally, another rotation in 3-dimensional space was applied that corrected for the fetal orientation. For instance, if the ultrasound indicated that the fetus was in cephalic position, the recorded fetal vectorcardiogram was rotated by 180 degrees to represent the fetal vectorcardiogram as if the fetus was in breech position, mimicking the anatomical position. Similarly, a fetal back which was oriented to the maternal abdomen was rotated along the longitudinal axis as if the fetal back was oriented to the maternal spine. The parts of the measurements of sufficient signal quality, closest to the performance of the ultrasound determining fetal orientation, were used to create the vectorcardiogram.

Finally, to enhance the signal-to-noise ratio, orientation-standardized fetal vectorcardiograms were averaged over multiple heartbeats to yield one fetal vectorcardiogram per measurement.

The orientation of the electrical heart axis was defined as the direction in which the vectorcardiogram had its maximum amplitude.[31] The latter direction was estimated as the average direction of the dominant vectors in the QRS complex, defined as the vectors from the point that the R-wave exceeded 70% of its maximum value until the point that it fell below 70% of the maximum value. The orientation of the fetal heart axis was expressed in degrees ranging from minus 180° to plus 180° and calculated in the frontal plane, where minus 90° is located superiorly.

Classification of CHD

CHD were classified in subgroups based on the type of defect and its hemodynamic consequences. Table 1 shows an overview of all included CHD types and their

corresponding subgroup. We included the following three CHD (subgroups) for statistical analysis: conotruncal anomalies (CTA), atrioventricular septal defects (AVSD) and hypoplastic right heart syndrome (HRHS). These were chosen for the following reasons. CTA make up an important part of all CHD and may be missed on the fetal anomaly scan, especially when the outflow tracts are difficult to image due to fetal position and the complex multiplanar evaluation, since the four chamber view may appear normal. Furthermore, some fetuses with undiagnosed CTA, such as transposition of the great arteries (TGA) with intact septum or pulmonary atresia with ventricular septal defect (extreme tetralogy of Fallot [TOF]), may develop acute hypoxia in the first few days postpartum when the arterial duct undergoes physiological closure. Without immediate

intervention, i.e. administration of prostaglandins to keep the arterial duct open, this can be a life-threatening event. We expected the fetal ECG to show a right axis.

Both fetuses with AVSD and HRHS may be expected to have a left-oriented electrical heart axis. We chose to include these CHD where the most overt differences in electrical heart axis can be expected compared to the healthy control group, since literature on the electrical heart axis in fetuses with CHD is scarce.[16,32,33]

Statistical analysis

Results from our CHD cohort were compared using our previously published cohort of healthy fetuses as reference group.[27] (ref chapter 4) Descriptive statistics were used to determine baseline characteristics of our overall CHD cohort. Differences in baseline characteristics between the overall CHD group and the healthy control group were tested using the Mann-Whitney U test for not normally distributed data and an independent T-test for normally distributed data.

Spherical statistics were applied to compare the two-dimensional mean electrical heart axis (MEHA) in the frontal plane between the groups, which required using the individual Cartesian coordinates. The observed frontal angle was determined in the (x,y)-plane, where x represented the left-right horizontal axis and y represented the craniocaudal axis. Since the length of the vector of the electrical heart axis in the frontal plane is influenced by electrical propagation in all directions, the vector of each fetus was normalized to create unit vectors i.e. with equal length. The normalized coordinates $(\tilde{x}, \tilde{y})$ of these unit vectors were calculated as the division of the originate coordinates (x, y) by their Euclidean norm $\sqrt{x^2 + y^2}$.

Descriptive statistics (median with interquartile range (IQR)) were calculated based on the normalized $(\tilde{x}, \tilde{y})$ Cartesian coordinates for the overall CHD group as well as for each of the three selected CHD subgroups. Differences between the overall CHD group as well as each CHD subgroup and the control group were tested using the Kolmogorov-Smirnov test. The mean frontal angle with 95% confidence intervals (CI) were calculated for both the overall CHD group and each CHD subgroup.[34]

A likelihood ratio test (LRT) was used to determine differences in frontal angles between the previously published control group and the overall CHD group assuming equal concentration parameters (i.e. similar to equal variances in 2-sample t-tests).[35] This assumption was verified with a circular concentration test.[35] If the equal concentration assumption was violated, a sensitivity analysis using the non-equal concentration approach suggested by Mardia and Jupp (2000) was performed.[35]

Furthermore, a LRT was also performed to determine the overall difference in frontal angles of the CHD subgroups and the control group. In addition, a spherically projected

multivariate linear (SPML) regression model with the frontal angle as the outcome and the subgroup as a categorical independent variable (control group was considered as the reference level) was fitted to the data, under the assumption that the data follows a von Mises-Fisher distribution (analogous to the normal distribution in linear regression).[36,37]

Circular discriminant analysis was performed on the unit vectors between the healthy control group and the overall CHD group.[38] Sensitivity and specificity were calculated based on 1000 Monte Carlo cross validation samples (20% of the original sample was randomly selected as the testing sample and the rest used as training sample).

Descriptive statistics were used to describe baseline characteristics, using IBM SPSS statistics version 25.0 (SPSS Inc., Chicago, Ill., USA). Statistical analysis was conducted with SAS (version 9.4, SAS Institute Inc., NC, USA) and R (version 3.5.3, R Foundation, Vienna, Austria). Significance level for all tests was set at 0.05.

Results

A total of 148 women were included carrying a fetus with suspected CHD after fetal echocardiography. The inclusion process is depicted in Figure 2. The electrical heart axis was determined in 127 fetuses with CHD. Within the overall CHD group, 54 fetuses were allocated to the CTA group, 9 to the AVSD group and 5 to the HRHS group. Table 1 shows an overview of all included CHD types and their corresponding subgroup. Baseline characteristics are shown in Table 2. The CHD group was not different to the normal control group for maternal age, parity or maternal BMI. The gestational age during the NI-fECG measurement for the control group was on average three weeks earlier than for the CHD group (p=0.00).

Table 1. Distribution of the different types of CHD included in the study population.

CHD group	n	CHD type		n	GA at measurement[$]	% of study population
Overall	*127*	*All*			*23.2 ± 3.2*	*100*
Septal defects	25				23.28 ± 3.2	19.7
		VSD		16	23.4 ± 3.5	12.6
		AVSD		9	23.1 ± 2.7	7.1
Conotruncal anomalies	54				23.2 ± 3.6	42.5
		TGA (IVS and VSD)		27	23.6 ± 3.2	21.3
			TGA + IVS	19	24.1 ± 3.2	15.0
			TGA + VSD	8	21.7 [20.2 - 23.5]	6.3
		TOF		16	23.2 ± 2.9	12.6
		VSD + pulmonary atresia		2	20.7; 23.1	1.6
		DORV + pulmonary stenosis		2	19.4; 21.3	1.6
		TGA + VSD + pulmonary stenosis		2	19.9; 24.3	1.6
		Truncus arteriosus		1	22.1	1.0
		ccTGA		2	26.0; 28.3	1.6
		DORV, no PS		2	20.4; 20.6	1.6
Single ventricle	10				20.6 [20.0 – 24.0]	
		Hypoplastic right heart syndrome		5	20.4 [19.9 – 21.9]	3.9
		Hypoplastic left heart syndrome		5	23.1 ± 4.8	3.9
Complex	15				20.9 [20.1 – 21.7]	
		AVSD combined with other cardiac anomalies		3	20.8 ± 4.0	2.4
		DILV		4	20.5 ± 0.6	3.1
		Ebstein anomaly		5	20.7 [20.4 - 27.0]	3.9
		Other		3	21.0; 21.1; 23.7	2.4
Miscellaneous	5				25.8 ± 2.4	3.9
R/L disproportion	9				26.2 ± 2.9	

Table 1. Continued.

CHD group	n	CHD type	n	GA at measurement[$]	% of study population
		Aortic coarctation	8	25.9 ± 3.0	6.3
		No aortic coarctation	1	28.3	1.0
Vascular ring	6			21.9 ± 1.5	4.7
Chromosomal aberration		Noonan syndrome	3	19.4; 21.0; 28.0	2.4

[$] *Data provided are percentages or mean ± SD. Median [interquartile range] are provided for variables that are not normally distributed. In case of low number of observations per CHD type, individual values are shown.*

Abbreviations: AVSD = atrioventricular septal defect, ccTGA = congenitally corrected transposition of the great arteries (double discordance), CHD = congenital heart disease, DILV = double inlet left ventricle, DORV = double outlet right ventricle, IVS = intact ventricular septum, TGA = transposition of the great arteries, TOF = tetralogy of Fallot, VSD = ventricular septal defect.

Figure 2. Flow diagram of patient inclusion

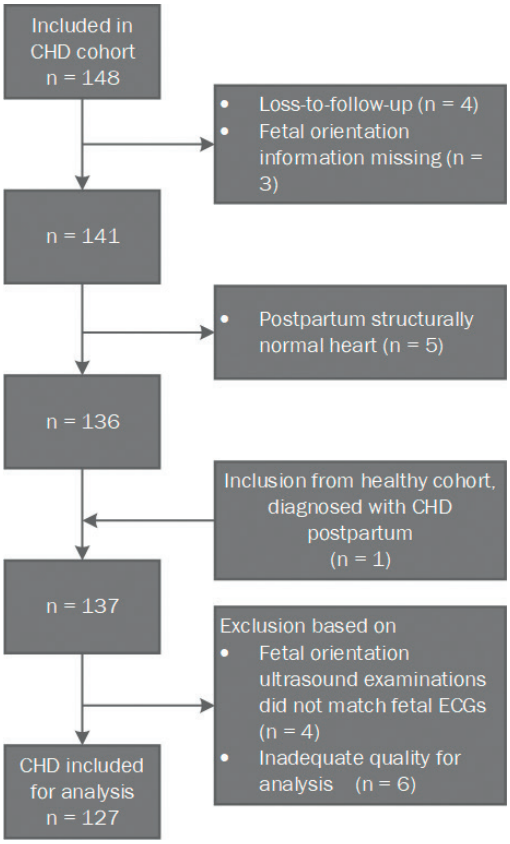

Table 2. Baseline characteristics of participants

	CHD		Healthy cohort		p-value
		n		n	
Maternal Age (years)	30.5 ± 4.6	127	31.0 [26.0 – 36.0]	281	0.09[a]
GA (weeks) at time of measurement	23.2 ± 3.2	127	20.2 ± 1.3	281	0.00[b]
CTA	23.2 ± 3.6	54			
AVSD	23.1 ± 2.7	9			
HRHS	20.8 ± 1.3	5			
Nulliparous (%)	44.1	127	52.0	281	0.14[c]
BMI (kg/m^2)	23.8 [18.4 – 29.2]	125	22.8 [16.7 – 28.9]	280	0.07[a]

Data provided are means ± SD. Median [interquartile range] are provided for variables that are not normally distributed. Differences in baseline characteristics between the CHD group and the healthy cohort were tested using the [a] Mann-Whitney U test, [b] Independent T-test and [c] Chi square test.
Abbreviations: AVSD = atrioventricular septal defect, BMI = body mass index, CHD = congenital heart disease, CTA = conotruncal anomaly, GA = gestational age, HRHS = hypoplastic right heart syndrome, kg = kilograms, m = meter.

No significant difference in distribution of the normalized $\tilde{x}$ and $\tilde{y}$ coordinates were found between the overall CHD group and the control group and between each CHD subgroup and the control group (Table 3).

Table 3. Summary statistics (median [IQR]) on the two dimensions for the overall CHD group and each subgroup compared to the healthy control group.

	Groups								
	Healthy control group n=281	**Overall CHD n=127**		**CHD subgroups**					
				CTA n=54		**AVSD n=9**		**HRHS n=5**	
	Median (IQR)	Median (IQR)	p-value	Median (IQR)	p-value	Median (IQR)	p-value	Median (IQR)	p-value
$\tilde{x}$	-0.35 (1.66)	-0.01 (1.75)	0.22	-0.18 (1.72)	0.78	0.88 (1.49)	0.13	0.63 (0.60)	0.08
$\tilde{y}$	-0.33 (0.96)	-0.24 (0.90)	0.17	-0.33 (1.12)	0.90	0.12 (1.11)	0.10	-0.31 (0.58)	0.90

P-values calculated by means of a Kolmogorov-Smirnov test showed no significant difference in distribution between the overall CHD group as well as each CHD subgroup with respect to the control group on both normalized coordinates.
Abbreviations: AVSD = atrioventricular septal defect, CTA = conotruncal anomaly, HRHS = hypoplastic right heart syndrome, IQR = interquartile range.

We previously described reference ranges using 90% prediction intervals for the electrical heart axis in healthy fetuses, based on data from 281 fetuses between 18 and 24 weeks of gestation. (ref chapter 4) The mean frontal angle for this control group was determined at 122.7° (95% CI: 101.7°; 143.6°).

In our overall CHD group the mean frontal angle was determined at 83.0° (95% CI: 6.7°; 159.3°). For the three CHD subgroups, the mean frontal angles were estimated at 105.6° (95% CI: 46.8°; 164.4°) for the CTA, -27.4° (95% CI: -118.6°; 63.9°) for the AVSD, and 26.0° (95% CI: -34.1°; 86.1°) for the HRHS group. Figure 3 shows the mean frontal angle with corresponding 95% CI of these groups on a circle diagram.

Figure 3. Mean electrical heart axis (MEHA) with corresponding 95% CI in the frontal plane plotted in a circle diagram for each group.

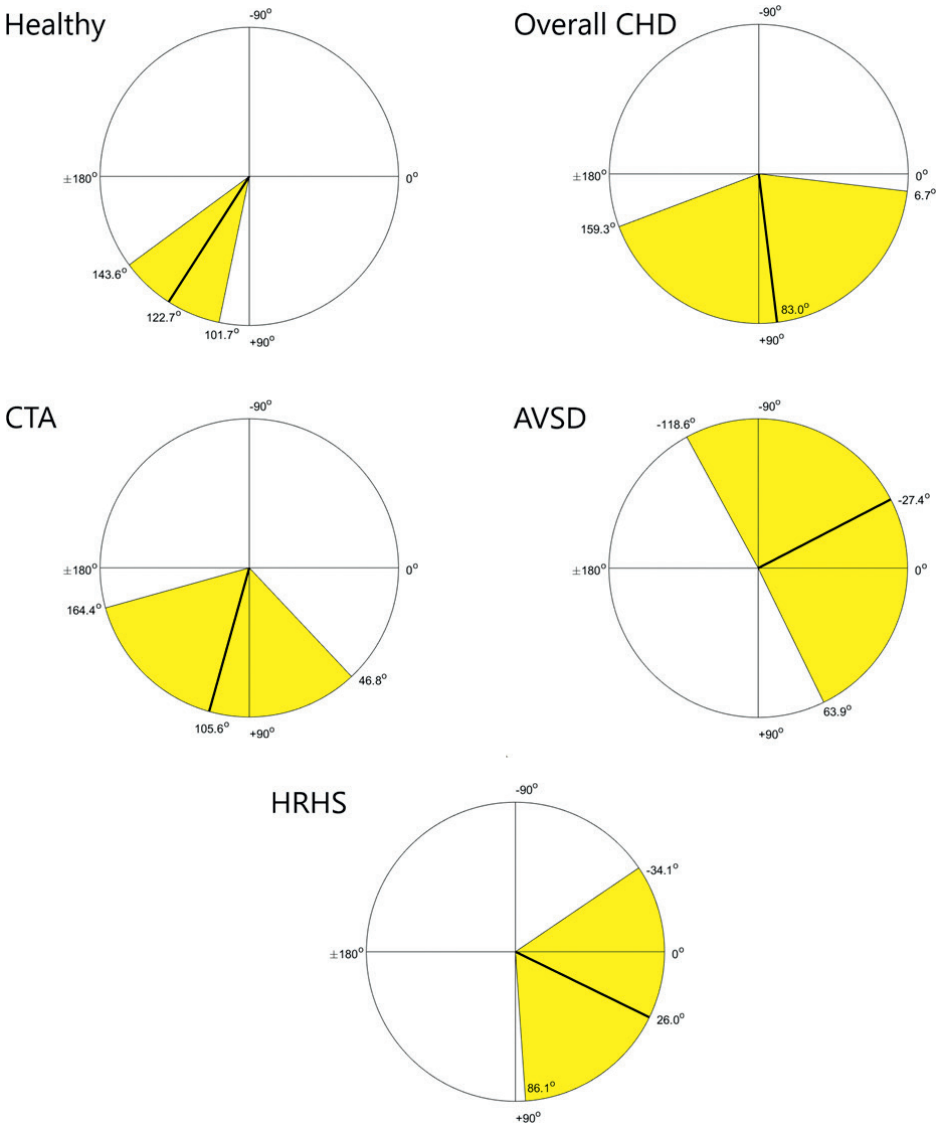

Abbreviations: AVSD = atrioventricular septal defect, CHD = congenital heart disease, CTA = conotruncal anomalies, HRHS = hypoplastic right heart syndrome.

We found no significant difference in electrical heart axis between the overall CHD group and the healthy control group (test statistic=2.17, p=0.14). Since the test for equality of concentration between both groups was significant (test statistic=3.99, p=0.046),

we conducted a sensitivity analysis which confirmed that there was no difference in electrical heart axis between both groups (test statistic =1.22, p= 0.27).

Discriminant analysis between the healthy control group and the overall CHD showed a sensitivity of 50.6% (95% CI 47.5% - 53.7%) and a specificity of 60.1% (95% CI 57.1% - 63.1%) for the detection of CHD.

We found a significant difference in electrical heart axis when comparing the healthy control group with all three CHD subgroups (test statistic=8.35, p=0.04) with equal concentration across the groups (equal concentration test statistic=0.62, p=0.89), indicating a difference in electrical heart axis between these groups. To gain more insight in the difference between each CHD subgroup and the healthy control group, a SPML regression analysis was performed and the results are displayed in Table 4. We found a significant difference in frontal angle between the healthy control group and both the AVSD subgroup (p=0.04) and the HRHS subgroup (p=0.02).

Table 4. Difference in normalized $(\tilde{x}, \tilde{y})$ coordinates between the healthy control group and each CHD subgroup.

	$\tilde{x}$		$\tilde{y}$	
	Estimate (S.E)	p-value	Estimate (S.E)	p-value
Intercept	-0.28 (0.07)	<0.001	-0.36 (0.07)	<0.001
CTA vs healthy	0.17 (0.17)	0.32	0.03 (0.16)	0.86
AVSD vs healthy	0.84 (0.41)	0.04	0.53 (0.37)	0.15
HRHS vs healthy	1.29 (0.54)	0.02	-0.19 (0.52)	0.72

P-values are obtained by means of a spherically projected multivariate linear (SPML) regression analysis with the frontal angle as the outcome and the subgroup as a categorical independent variable. The healthy control group was considered as reference level. Significant results are shown in bold. Abbreviations: AVSD = atrioventricular septal defect, CTA = conotruncal anomaly, HRHS = hypoplastic right heart syndrome, S.E. = standard error.

Discussion

Main findings

To our knowledge this is the first study of NI-fECGs in a large cohort of fetuses with CHD, looking at the MEHA in the frontal plane. We found no significant difference in MEHA between the healthy control group and the overall CHD group, which resulted in low sensitivity and specificity of the electrical heart axis for the detection of CHD. The MEHA of the AVSD and HRHS subgroups were left-oriented and statistically significant from the healthy control group which may be helpful in the prenatal detection of these types of CHD.

Interpretation of findings and comparison with existing literature

We previously described a right-oriented MEHA in healthy fetuses around mid-gestation. (ref chapter 4) This right-oriented axis is still present after birth, but gradually deviates towards the left during the first year of life.[39] These changes reflect the developmental changes from fetus to child where the right ventricle is dominant prenatally pumping a higher cardiac output against high resistance in the fetus, and the dominant left ventricle pumping against high resistance in the child and adult. As the pulmonary vascular resistance declines postnatally the workload of the right ventricle is reduced relative to the left ventricle with an associated change in relative ventricular muscle mass.[26,40]

We found a MEHA in our overall CHD group which is oriented slightly to the left and not significantly different from that of our healthy control group (χ^2(df=1)=2.17, p=0.14). Since we included all types of CHD, it comprised a heterogenous group. As this heterogeneity may have confounded our results, we also looked at three clinically relevant subgroups and compared them with the healthy control group as well.

First, we chose the CTA subgroup which makes up a large part of all CHD. The prevalence of CTA varies between prenatal (2.5-21%) and postnatal (10-12%) series [4,41–43] and is influenced by differing prenatal CHD detection rates between countries. [44–49] CTA comprised 42.5% of all CHD included in our study. As the four-chamber view of the heart in many cases of CTA such as TOF and TGA may be normal, detection rates can be improved by using the outflow tract and three vessel views as part of the fetal anomaly scan for CHD screening.[8,23,50] We found a right-oriented MEHA in our CTA subgroup, which was not significantly different from the healthy control group. This was in line with our expectations, since this subgroup comprises mainly fetuses with TOF and TGA, and a right axis deviation is seen postnatally in these defects due to right ventricular hypertrophy and strain analogous to the fetal situation.

Second, we compared the AVSD group with our healthy control group. Only 2 cases describing the electrical heart axis in AVSD fetuses are available in the literature, with inconsistent results.[32,33] We expected to find a distinctly left-orientated MEHA in these fetuses, as is seen in neonates postpartum with these defects. Left ventricular hypertrophy may contribute to the deviated electrical heart axis in AVSD [51], but anatomic displacement of the left ventricular (LV) papillary muscles (PM) is more important in the altered electrical activation in this condition.[52] The insertion place of the PM on the ventricular wall coincides with the end of the left bundle branch fascicles. In AVSD, the anterior PM is positioned relatively closer to the septum than the posterior PM which produces a delay in activation of the anterior LV free wall, causing a left anterior hemiblock. Our data confirm a left-oriented MEHA in our AVSD subgroup, which was significantly different from the healthy control group (test statistic=0.84, p=0.04). Third, we included fetuses with HRHS. In HRHS there is underdevelopment of the right-sided cardiac structures and thus a relative dominance of the left-sided cardiac

musculature, and an expectation of a left-oriented electrical heart axis. Our findings confirm this left-oriented MEHA our HRHS subgroup, which is significantly different from the healthy control group. (test statistic=1.29, p=0.02).

Strengths and limitations

A major strength of our study is the large cohort of healthy fetuses (n=281) and fetuses with CHD (n=127). As the cohort of CHD was heterogenous, the numbers per individual CHD type were small precluding individual analysis per diagnosis. We thus chose for three groups which are prenatally relevant, either due to prevalence or expected abnormal heart axis.

The number of excluded recordings due to inadequate data quality was low (n=6). However, the NI-fECG technology is currently limited by the lack of real-time results. Offline analysis of the recordings is still required. Automatization of the signal processing steps is ongoing for future implementation in the measurement hardware to address this problem.

The gestational age at time of measurement was three weeks later in the CHD group compared to the healthy control group. As there is limited data available on the course of the electrical heart axis in fetuses during pregnancy, this may have influenced our results. The MEHA of term babies is 110°, ranging from 30° to 180°.[53] This suggests a minimal shift of the electrical heart axis to the left between mid-gestation and term. Therefore, we do not expect this difference in gestational age to have significantly influenced our results.

Clinical and research implications

NI-fECG is a patient-friendly method which requires minimum training for healthcare personnel to apply. With further development of the technology, it could be a non-expensive diagnostic test. Our data show that the electrical heart axis in the frontal plane as a single parameter, measured with NI-fECG, does not discriminate between healthy fetuses and fetuses with CHD. However, the left-oriented MEHA in fetuses with AVSD and HRHS differs significantly from the healthy control group. This supports the idea that electrical conduction may be influenced by the cardiac anatomy. Other ECG characteristics such as ECG morphology and cardiac time intervals may unveil information necessary to distinguish fetuses with CHD. More research is needed to evaluate if the addition of a fetal ECG to current prenatal screening increases CHD detection rates.

Conclusion

The MEHA in our CHD cohort was oriented slightly to the left and not significantly different from that of our healthy control group. Consequently, sensitivity and specificity of the electrical heart axis in the detection of CHD was low. The MEHA in the AVSD and HRHS subgroups was oriented to the left and significantly different from our healthy control group. More research is needed to see if other ECG characteristics can play a role in the detection of CHD in the future.

References

1. van der Linde D, Konings EEM, Slager MA, Witsenburg M, Helbing WA, Takkenberg JJM, Roos-Hesselink JW. Birth prevalence of congenital heart disease worldwide: a systematic review and meta-analysis. J Am Coll Cardiol. 2011 Nov;58(21):2241–7.
2. Dolk H, Loane M, Garne E. Congenital heart defects in Europe: prevalence and perinatal mortality, 2000 to 2005. Circulation. 2011 Mar;123(8):841–9.
3. Hoffman JIE, Kaplan S, Liberthson RR. Prevalence of congenital heart disease. Am Heart J. 2004 Mar;147(3):425–39.
4. Hoffman JIE, Kaplan S. The incidence of congenital heart disease. J Am Coll Cardiol. 2002;39(12):1890–900.
5. Germanakis I, Sifakis S. The impact of fetal echocardiography on the prevalence of liveborn congenital heart disease. Pediatr Cardiol. 2006;27(4):465–72.
6. Khoshnood B, De Vigan C, Vodovar V, Goujard J, Lhomme A, Bonnet D, Goffinet F. Trends in prenatal diagnosis, pregnancy termination, and perinatal mortality of newborns with congenital heart disease in France, 1983-2000: a population-based evaluation. Pediatrics. 2005 Jan;115(1):95–101.
7. Levy DJ, Pretorius DH, Rothman A, Gonzales M, Rao C, Nunes ME, Bendelstein J, Mehalek K, Thomas A, Nehlsen C, Ehr J, Burchette RJ, Sklansky MS. Improved prenatal detection of congenital heart disease in an integrated health care system. Pediatr Cardiol. 2013 Mar;34(3):670–9.
8. van Velzen CL, Clur SA, Rijlaarsdam MEB, Bax CJ, Pajkrt E, Heymans MW, Bekker MN, Hruda J, de Groot CJM, Blom NA, Haak MC. Prenatal detection of congenital heart disease--results of a national screening programme. BJOG. 2016 Feb;123(3):400–7.
9. Marek J, Tomek V, Skovranek J, Povysilova V, Samanek M. Prenatal ultrasound screening of congenital heart disease in an unselected national population: a 21-year experience. Heart. 2011 Jan;97(2):124–30.
10. EUROCAT. Prevalence tables.
11. Kaguelidou F, Fermont L, Boudjemline Y, Le Bidois J, Batisse A, Bonnet D. Foetal echocardiographic assessment of tetralogy of Fallot and post-natal outcome. Eur Heart J. 2008 Jun;29(11):1432–8.
12. Bonnet D, Coltri A, Butera G, Fermont L, Le Bidois J, Kachaner J, Sidi D. Detection of transposition of the great arteries in fetuses reduces neonatal morbidity and mortality. Circulation. 1999 Feb;99(7):916–8.
13. Mahle WT, Clancy RR, McGaurn SP, Goin JE, Clark BJ. Impact of prenatal diagnosis on survival and early neurologic morbidity in neonates with the hypoplastic left heart syndrome. Pediatrics. 2001 Jun;107(6):1277–82.
14. Franklin O, Burch M, Manning N, Sleeman K, Gould S, Archer N, Radcliffe J, Way H. Prenatal diagnosis of coarctation of the aorta improves survival and reduces morbidity. 2002;67–70.

15. Mäkikallio K, McElhinney DB, Levine JC, Marx GR, Colan SD, Marshall AC, Lock JE, Marcus EN, Tworetzky W. Fetal aortic valve stenosis and the evolution of hypoplastic left heart syndrome: patient selection for fetal intervention. Circulation. 2006 Mar;113(11):1401–5.
16. Verdurmen KMJ, Lempersz C, Eijsvoogel NB, Vullings R, Schroer C, van Laar JOEH, Oei SG. A systematic review of prenatal screening for congenital heart disease by fetal electrocardiography. Int J Gynecol Obstet. 2016;135(2):129–34.
17. van Velzen CL, Haak MC, Reijnders G, Rijlaarsdam MEB, Bax CJ, Pajkrt E, Hruda J, Galindo-Garre F, Bilardo CM, de Groot CJM, Blom NA, Clur SA. Prenatal detection of transposition of the great arteries reduces mortality and morbidity. Ultrasound Obstet Gynecol. 2015;45(3):320–5.
18. Jørgensen DES, Vejlstrup N, Jørgensen C, Maroun LL, Steensberg J, Hessellund A, Jørgensen FS, Larsen T, Shalmi A-C, Skibsted L, Zingenberg H, Ekelund C, Tabor A. Prenatal detection of congenital heart disease in a low risk population undergoing first and second trimester screening. Prenat Diagn. 2015;35(4):325–30.
19. Galindo A, Herraiz I, Escribano D, Lora D, Melchor JC, De La Cruz J. Prenatal detection of congenital heart defects: A survey on clinical practice in Spain. Fetal Diagn Ther. 2011;29(4):287–95.
20. Pinto NM, Keenan HT, Minich LL, Puchalski MD, Heywood M, Botto LD. Barriers to prenatal detection of congenital heart disease: A population-based study. Ultrasound Obstet Gynecol. 2012;40(4):418–25.
21. Trines J, Fruitman D, Zuo KJ, Smallhorn JF, Hornberger LK, Mackie AS. Effectiveness of prenatal screening for congenital heart disease: assessment in a jurisdiction with universal access to health care. Can J Cardiol. 2013 Jul;29(7):879–85.
22. van Velzen CL, Ket JCF, van de Ven PM, Blom NA, Haak MC. Systematic review and meta-analysis of the performance of second-trimester screening for prenatal detection of congenital heart defects. Int J Gynecol Obstet. 2018;140(2):137–45.
23. Everwijn SMP, van Nisselrooij AEL, Rozendaal L, Clur S-AB, Pajkrt E, Hruda J, Linskens IH, van Lith JM, Blom NA, Haak MC. The effect of the introduction of the three-vessel view on the detection rate of transposition of the great arteries and tetralogy of Fallot. Prenat Diagn. 2018 Nov;38(12):951–7.
24. Adriaanse BME, van Vugt JMG, Haak MC. Three- and four-dimensional ultrasound in fetal echocardiography: an up-to-date overview. J Perinatol. 2016 Sep;36(9):685–93.
25. Sharland G. Fetal cardiac screening and variation in prenatal detection rates of congenital heart disease: why bother with screening at all? Future Cardiol. 2012 Mar;8(2):189–202.
26. Verdurmen KMJ, Hulsenboom ADJ, van Laar JOEH, Wijn PFF, Vullings R, Oei SG. Orientation of the electrical heart axis in mid-term pregnancy. Eur J Obstet Gynecol Reprod Biol. 2016;207:243–6.
27. Verdurmen K, Lempersz C, Vullings R, Schroer C, Delhaas T, van Laar JOEH, Oei SG. Normal ranges for fetal electrocardiogram values for the healthy fetus of 18-24 weeks of gestation: a prospective cohort study. BMC Pregnancy Childbirth. 2016 Aug;16(1):227.

28. Lempersz C, van Laar JOEH, Clur S-AB, Verdurmen KM, Warmerdam GJ, van der Post J, Blom NA, Delhaas T, Oei SG, Vullings R. The standardized 12-lead fetal electrocardiogram of the healthy fetus in mid-pregnancy: A cross-sectional study. PLoS One. 2020;15(4):e0232606.
29. Vullings R, Peters CHL, Sluijter RJ, Mischi M, Oei SG, Bergmans JWM. Dynamic segmentation and linear prediction for maternal ECG removal in antenatal abdominal recordings. Physiol Meas [Internet]. 2009;30(3):291. Available from: http://stacks.iop.org/0967-3334/30/i=3/a=005
30. Vullings R, Peters CHL, Mossavat I, Oei SG, Bergmans JWM. Bayesian Approach to Patient-Tailored Vectorcardiography. IEEE Trans Biomed Eng. 2010;57(3):586–95.
31. Sosi-Pallares D, Pileggi F, Cisneros F, Ginefra P, Portillo B, Medrano GA, Bisteni A. The mean manifest electrical axis of the ventricular activation process (AQRS) in congenital heart disease: a new approach in electrocardiographic diagnosis. Am Heart J. 1958 May;55(5):681–700.
32. Brambati B, Bonsignore L. The significance of indirect electrocardiography in fetal cardiac arrhythmias. Eur J Obstet Gynecol Reprod Biol. 1983 Mar;14(6):371–3.
33. Velayo C, Sato N, Ito T, Chisaka H, Yaegashi N, Okamura K, Kimura Y. Understanding congenital heart defects through abdominal fetal electrocardiography: case reports and clinical implications. J Obstet Gynaecol Res. 2011 May;37(5):428–35.
34. Davison AC (Anthony C, Hinkley D V. Bootstrap methods and their application. 582 p.
35. Mardia KV, Jupp PE. Directional statistics. 2nd ed. London: John Wiley & Sons; 2000.
36. Paine PJ, Preston SP, Tsagris M, Wood ATA. Spherical regression models with general covariates and anisotropic errors. Stat Comput. 2019 Apr;
37. Presnell B, Morrison SP, Littell RC. Projected Multivariate Linear Models for Directional Data. J Am Stat Assoc. 1998;93(443):1068–77.
38. Morris JE, Laycock PJ. Discriminant Analysis of Directional Data. In: Biometrika. Oxford University Press; 1974. p. 335–41.
39. Goodacre S, Mcleod K. Paediatric electrocardiography. BMJ. 2002;324(June):89–94.
40. Larks SD. Estimation of the Electrical Axis of the Fetal Heart. Am J Obstet Gynecol. 1965;91:46.
41. Samanek M, Voriskova M. Congenital heart disease among 815,569 children born between 1980 and 1990 and their 15-year survival: a prospective Bohemia survival study. Pediatr Cardiol. 1999;20(6):411–7.
42. Rustico MA, Benettoni A, D'Ottavio G, Maieron A, Fischer-Tamaro I, Conoscenti G, Meir Y, Montesano M, Cattaneo A, Mandruzzato G. Fetal heart screening in low-risk pregnancies. Ultrasound Obstet Gynecol. 1995 Nov;6(5):313–9.
43. Grandjean H, Larroque D, Levi S. The performance of routine ultrasonographic screening of pregnancies in the Eurofetus Study. Am J Obstet Gynecol. 1999 Aug;181(2):446–54.

44. Khoshnood B, De Vigan C, Vodovar V, Goujard J, Lhomme A, Bonnet D, Goffinet F. Trends in Prenatal Diagnosis, Pregnancy Termination, and Perinatal Mortality of Newborns With Congenital Heart Disease in France, 1983–2000: A Population-Based Evaluation. Pediatrics. 2005;115(1):95–101.
45. Galindo A, Mendoza A, Arbues J, Graneras A, Escribano D, Nieto O. Conotruncal anomalies in fetal life: accuracy of diagnosis, associated defects and outcome. Eur J Obstet Gynecol Reprod Biol. 2009 Sep;146(1):55–60.
46. Tometzki AJ, Suda K, Kohl T, Kovalchin JP, Silverman NH. Accuracy of prenatal echocardiographic diagnosis and prognosis of fetuses with conotruncal anomalies. J Am Coll Cardiol. 1999 May;33(6):1696–701.
47. Paladini D, Rustico M, Todros T, Palmieri S, Gaglioti P, Benettoni A, Russo MG, Chiappa E, D'Ottavio G. Conotruncal anomalies in prenatal life. Ultrasound Obstet Gynecol. 1996 Oct;8(4):241–6.
48. Sivanandam S, Glickstein JS, Printz BF, Allan LD, Altmann K, Solowiejczyk DE, Simpson L, Perez-Delboy A, Kleinman CS. Prenatal diagnosis of conotruncal malformations: diagnostic accuracy, outcome, chromosomal abnormalities, and extracardiac anomalies. Am J Perinatol. 2006 May;23(4):241–5.
49. Allan LD, Sharland GK, Milburn A, Lockhart SM, Groves AM, Anderson RH, Cook AC, Fagg NL. Prospective diagnosis of 1,006 consecutive cases of congenital heart disease in the fetus. J Am Coll Cardiol. 1994 May;23(6):1452–8.
50. Gorla SR, Chakraborty A, Garg A, Gugol RA, Kardon RE, Swaminathan S. Emerging trends in the prenatal diagnosis of complex CHD and its influence on infant mortality in this cohort. Cardiol Young. 2019;29(January 2000):270–6.
51. Balchum OJ, Blount SGJ, Gensini G. The persistent ostium primum atrial septal defect. Circulation. 1956 Apr;13(4):499–509.
52. Hakacova N, Wagner GS, Idriss SF. Electroanatomic relationships in patients with primum atrioventricular septal defect. JACC Cardiovasc Imaging. 2009 Dec;2(12):1357–65.
53. Park MK. Park's Pediatric Cardiology for Practitioners. 2014. 688 p.

CHAPTER 6

The Non-Invasive Fetal Electrocardiogram during labor, a review of the literature

Carlijn Lempersz, Lore Noben, Bart de Vries, Judith O.E.H. van Laar, Michelle E.M.H. Westerhuis, S. Guid Oei

Obstet Gynecol Surv. 2020 Jun;75(6):369-380

Abstract

Importance: The introduction of the cardiotocogram (CTG) during labor has not been found to improve neonatal outcome. The search for a more reliable, less invasive and patient-friendly technique is ongoing. The non-invasive fetal electrocardiogram (NI-fECG) has been proposed as one such alternative.

Objectives: To review the literature on the performance of NI-fECG for fetal monitoring during labor.

Evidence acquisition: Following the PRISMA guidelines a systematic search in MEDLINE, EMBASE and Cochrane Library was performed. Studies involving original research investigating the performance of NI-fECG during labor were included. Animal studies and articles in languages other than English, Dutch or German were excluded. The QUADAS-2 checklist was used for quality assessment. A descriptive analysis of the results is provided.

Results: Eight articles were included. Pooled analysis of the results of the separate studies was not possible due to heterogeneity. All studies demonstrate that it is possible to apply NI-fECG during labor. Compared to Doppler ultrasound, NI-fECG performs equal or better in most studies.

Conclusions and Relevance: NI-fECG for fetal monitoring is a promising non-invasive and patient-friendly technique that provides accurate information. Future studies should focus on signal quality throughout labor, with the aim to further optimize technical development of NI-fECG.

Target Audience: Obstetricians and gynecologists, family physicians.

Introduction

The cardiotocogram (CTG) for fetal heart rate and contraction monitoring during labor was introduced in the early 1970's to identify fetuses with hypoxia and to reduce neonatal morbidity and mortality. [1] Unfortunately, neonatal outcome has not improved after the introduction of the CTG. [1]

The two most commonly used techniques to acquire fetal heart rate (FHR) for CTG monitoring is via a non-invasive method using Doppler Ultrasound (DU), or with a more invasive method, the fetal scalp electrode (FSE). DU uses a transducer placed on the maternal abdomen and held in place with an elastic band. An advantage of the DU is that it is a non-invasive method that can be used before membranes have been ruptured. Unfortunately, DU is sensitive to signal loss with reported percentages ranging from 5.2% up to 40%. [2–4] This signal loss can partially be due to maternal and fetal movements, a high BMI of the mother and irregularities of the FHR i.e. decelerations, extrasystolic beats, and other cardiac arrythmias. [3–6] Furthermore, this method and the means of attaching the DU device to the maternal abdomen can be experienced as uncomfortable. [7] Invasive monitoring via FSE is a more reliable method and is considered the gold standard for FHR monitoring. However, this method carries an increased risk for complications, such as trauma and infection and can only be applied after membranes have been ruptured and with sufficient dilation. [8,9]

Overall, the specificity of CTG monitoring is poor. [1] Multiple techniques have been added to increase the detection rate of fetal hypoxia, i.e. fetal blood sampling (FBS) and ST waveform analysis (STAN). However, previous studies have demonstrated that these methods do not significantly decrease neonatal morbidity and mortality. [10–16]

The search for other monitoring techniques that can gather accurate information in a safe and patient-friendly way, is still ongoing. Non-invasive fetal electrocardiography (NI-fECG) may be an alternative to conventional monitoring techniques. The NI-fECG retrieves electrophysiologic signals of fetal and maternal heart rate (MHR), as well as the electrohysterogram (EHG) via electrodes placed on the maternal abdomen. This techniques provides more information than fetal heart rate alone as it also provides beat-to-beat information that can be used to assess fetal heart rate variability. Furthermore, the NI-fECG provides a complete fetal ECG waveform that could be assessed for morphologic changes possibly indicating fetal hypoxia. In contrast to STAN, the NI-fECG provides a multilead fetal ECG and therefore may overcome the current shortcomings in ST waveform analysis. [17–19]

NI-fECG is not a new technique, as first recordings were made in the early 1900s. [20] However, difficulties in acquiring and processing the electrophysiologic signals limited development of this technique. Recently, NI-fECG has gained renewed interest due to

technical improvements. Over the last years more research has been performed on NI-fECG as an alternative for intrapartum fetal monitoring.

This paper aims to provide a review of the existing literature on the performance of NI-fECG as a method for fetal monitoring during labor.

Materials and methods

This review was registered in Prospero (#CRD42019124807). A systematic search in the electronic databases MEDLINE (1966-Present), EMBASE (1974-Present and Cochrane library was performed until the 24th of April 2019. The search was conducted following the PRISMA guidelines by two independent researchers (LN and CL) and one trained medical librarian (BdV) from the Máxima Medical Center, Veldhoven, The Netherlands. The following search terms were used: fetus, electrocardiography, cardiotocography, fetal monitoring, non-invasive, labor, intrapartum (full electronic search is available in appendix 1). The main outcome measures of interest were accuracy and reliability of the NI-fECG during labor compared to DU and/or FSE.

We only included original research. If there was any overlap between studies, we used the original article. Animal studies and articles in languages other than English, Dutch or German were excluded.

Articles were initially screened by title and abstract by two independent reviewers (LN and CL). When found appropriate, the full text was evaluated. Furthermore, references of the selected articles were checked for eligible articles. Disagreements were resolved by discussion.

The QUADAS-2 checklist was used as reference for quality assessment of the included studies. [21]

Results

A total of eight out of 658 articles were included in this review after removal of duplicates, title and abstract screening, reading the full text articles and screening reference lists of the included articles. Seven articles describe a prospective study and one article a retrospective study. Figure 1 summarizes the screening and article selection process.

Figure 1. Flowchart article screening and selection process

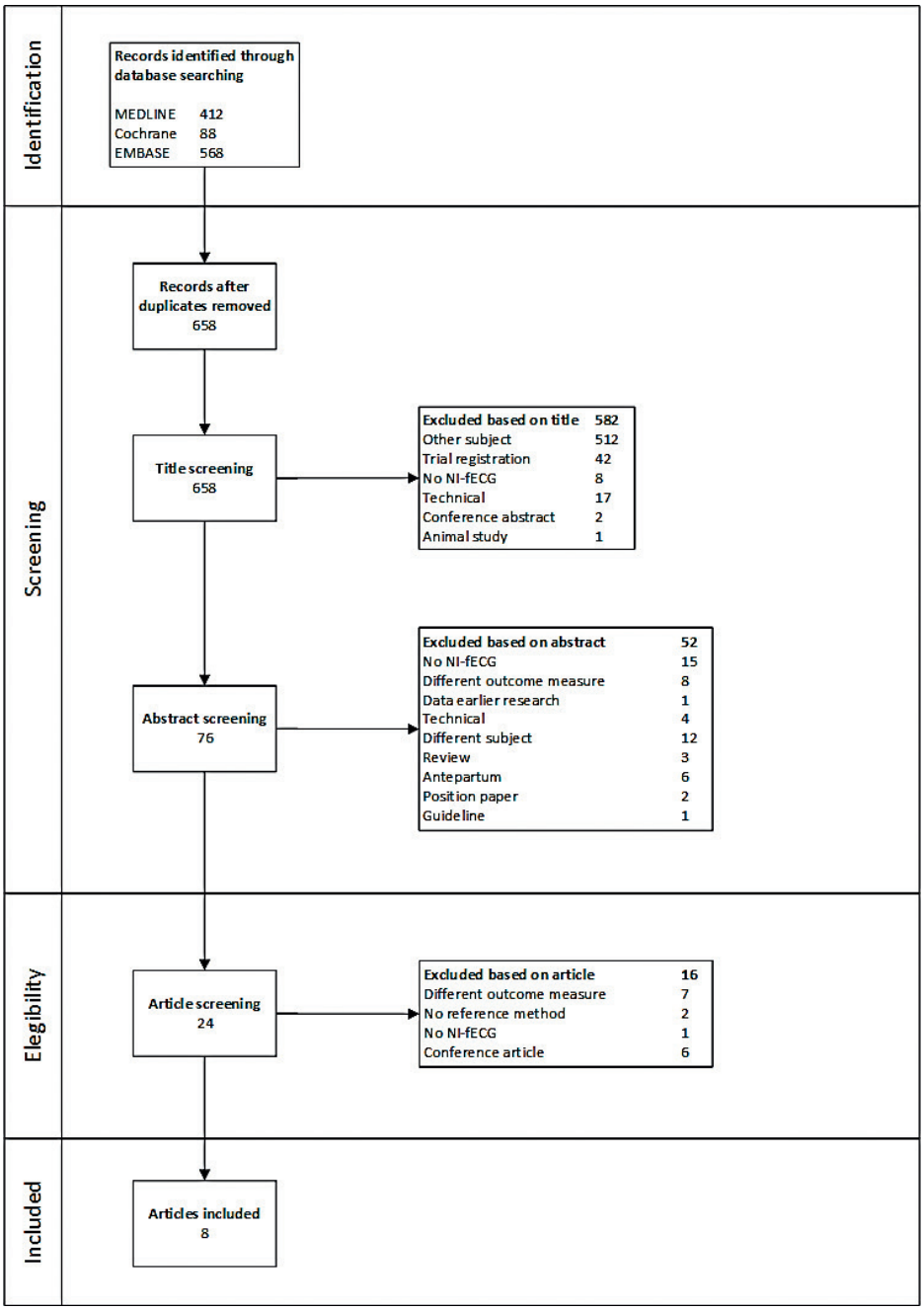

Pooled analysis of the results of the separate studies was not possible due to heterogeneity. Table 1 shows a summary of the quality assessment of the included articles. A summary of the eight included articles is enclosed in appendix 2.

Table 1. Quality assessment of the 8 included articles according to Quadas-2 [21]

	Risk of bias				***Applicability concerns***		
Study	**Patient selection**	**Index test**	**Reference standard**	**Flow and timing**	**Patient selection**	**Index test**	**Reference standard**
Breuker et al. 1976	?	+	+	+	+	-	+
Frank et al. 1992	-	+	+	+	+	-	+
Stampalija et al. 2012	+	+	-	-	+	-	-
Reinhard et al. 2012	+	+	-	+	+	-	+
Cohen et al.2012	-	+	+	-	+	+	+
Reinhard et al. 2013	+	+	-	+	+	-	+
Ashwal et al. 2017	+	+	+	+	+	+	+
Euliano et al. 2017	?	+	+	?	+	+	+

Accuracy

Accuracy is defined as the difference in FHR output from the investigational product (NI-fECG or DU) compared to the reference method (FSE) expressed in root mean square error (bpm). This definition of accuracy was reported in three included studies, using the FSE as the gold standard. Euliano et al. and Cohen et al. reported an overall accuracy of about 5 bpm for NI-fECG. For DU, overall accuracy was reported as 10.9 (± 5.8) bpm by Cohen et al. and 14.3 (± 8.2) bpm by Euliano et al. [22,23]

No difference in accuracy of NI-fECG between labor stages was found by Euliano et al, whereas Cohen et al. found a slight decrease in accuracy to 7.9 (± 4.2) bpm for the second stage of labor. [22,23]

Ashwal et al. reported a higher accuracy of 1.47 (± 0.82) bpm for NI-fECG and 5.39 (± 3.82) bpm for DU, using non-continuous segments for analysis. [24] Although they used segments from each stage of labor, they only report one accuracy value. Reported accuracy values were higher for NI-fECG compared to DU (see appendix 2). [22–24]

Reinhard et al. chose the correlation coefficient to express accuracy for NI-fECG with DU as reference. They found a Spearman's rank correlation coefficient of 0.94 (range -0.11 to 0.99) for the first stage of labor and 0.85 (range -0.73 to 0.99) for the second stage of labor, suggesting a good statistical agreement between both methods. [25]

Frank et al. describe five cases of laboring women monitored by NI-fECG and FSE. Their definition of accuracy is the absolute difference in the R-R interval. They reported that 92.6% of the total time of each NI-fECG measurement lays within 1 bpm difference of the FSE measurement. [26]

Reliability

Reliability is defined as the percentage of time that the investigational product (NI-fECG or DU) generates a FHR output within 10% of the FHR output of the product used as reference (FSE), expressed as positive percent agreement (PPA). Both Cohen et al. and Euliano et al. compared NI-fECG with FSE. They found similar results for overall PPA for NI-fECG (81.7% (± 20.5) in Cohen et al. and 83.4% (± 15.4) in Euliano et al.). For DU, Cohen et al. reported an overall PPA of 73.0% (± 24.6) and Euliano et al. an overall PPA of 62.4% (± 26.5), both significantly lower than NI-fECG.

When the first stage of labor was considered separately, Cohen et al. found a PPA of 84.9% (± 21.5) for NI-fECG and 74.7% (± 28.2) for DU (<0.001). Euliano et al. found a PPA in the first stage of labor of 86.3% (± 14.7) for NI-fECG and 61.3% (± 29.6) for DU (<0.0001). Both Cohen et al. and Euliano et al. describe a drop in reliability percentages for NI-fECG and DU during the second stage of labor (71.9% (± 20.4) and 77.5% (± 15.1) for NI-fECG in Cohen et al. and Euliano et al., respectively, and 61.7% (± 24.8) and 64.8% (± 18.5) for DU). Overall, the reliability of NI-fECG is significantly higher than DU. [22,23] Ashwal et al. also used FSE as golden standard, but found a much higher PPA of 99% (± 1.72) for NI-fECG and 96.6% (± 4.6) for DU. They showed a decrease of 0.5% for NI-fECG and 1.7% for DU during the second stage of labor. [24]

Success rate

Success rate is defined as the percentage of time that NI-fECG or DU provide any output. Stampalija et al. reported an overall success rate of 88.5% (± 16.7) for NI-fECG and 89.4% (± 7.6) for DU (p = 0.77). [27] Cohen et al. found an overall success rate of 83.4% (± 20.1) for NI-fECG and 82.5% (± 21.1) (p = 0.38) for DU. [22] Stampalija et al. found a success rate of 89.8% (± 16.1) in the first stage of labor for NI-fECG and 89.9% (± 7.9) for DU (p = 0.98). In the second stage of labor a success rate of 66.5% (± 21.3) for NI-fECG and 83.7% (± 7.4) for DU (p = 0.001) was found. [27] Cohen et al. reported a success rate of 86.4% (± 20.1) for NI-fECG in the first stage of labor and 82.6% (± 24.4) for DU. In the second stage of labor this was 75.2% (± 19.2) and 77.8% (± 21.1) (p = 0.25), respectively. [22] Reinhard et al. also reported on the success rate of NI-fECG and DU. In the first stage of labor they found a success rate of 97.7% (7.8–100) for NI-fECG and 85.5% (35.1–99.8) for DU. In the second stage of labor this rate dropped to 85.5% (13.4–100) for NI-fECG, but rose to 92.3% (22.5–99.8) for DU. [25] In 2013 Reinhard et al. published another report with results on reliability using the abovementioned definition for success rate. The reliability reported in this paper for NI-fECG was 87.1% (± 19.10) for first stage and 70.5% (± 27.90) for second stage of labor.[28]

Signal loss

Breuker et al. reported on quality defined as signal loss, the percentage of time the NI-fECG did not provide an output. The quality of the NI-fECG was assessed by placing recordings in different categories: excellent (<5% signal loss), good (>5-<10 % signal loss), satisfactory (>10-<20% signal loss), sufficient (>20-<35% signal loss), deficient (>35-<50% signal loss), not interpretable (> 50% signal loss). Overall, 17.3% of the cases were classified as excellent, 23.1% as good, 26.6% as satisfactory, 17.9% as sufficient and 15.0% as deficient. In the first stage of labor, no cases had more than 50% signal loss whereas in second stage of labor this was 30%. [29]

Confusion rate

Stampalija et al., Reinhard et al. and Cohen et al. reported on the percentage of time the investigational product confused maternal heart rate (MHR) for fetal heart rate (FHR). [22,27,28] Stampalija et al. and Cohen et al. used the term confusion rate (CR) in their paper, whereas Reinhard et al. used the term MHR/FHR ambiguity. Stampalija et al. and Reinhard et al. used the NI-fECG as the reference method for MHR. Cohen et al. used pulse oximetry as the reference method for MHR. [22,27,28]

Cohen et al. defined confusion rate as the percentage of FHR determinations for which each external device (DU and NI-fECG) calculated a FHR value that was both more than 5% different from that of the FSE and within 5% of the MHR. [22] Stampalija et al. defined confusion rate as a FHR within 5 bpm of MHR. [27] Reinhard et al. used the same definition but called it MHR/FHR ambiguity. [28]

All three studies found a lower CR for the NI-fECG compared to DU. Stampalija et al. found a CR in the first stage of labor for DU and NI-fECG of 3.9% (± 4.6) and 1.0% (± 1.9), respectively. For the second stage this was 11.3% (± 8.2) and 4.6% (± 5.0) respectively. [27] Cohen et al. found a CR of 9.5% (± 17.8) in the first stage of labor for DU and 11.0% (± 15.4) in second stage of labor, whereas this was 0.3% (± 0.6) and 0.7% (± 0.8) for the NI-fECG, respectively. [22] Reinhard et al. showed an ambiguity of DU in the first stage of labor of 1.22% (± 1.9) and for NI-fECG of 0.70% (± 1.2). For the second stage of labor ambiguity was 6.20% (± 9.0) for DU and 3.30% (± 4.4) for NI-fECG. [28]

Discussion

The most common method of monitoring fetal wellbeing during labor is by monitoring the FHR in relation to uterine contractions. Unfortunately, FSE, considered the gold standard for FHR monitoring, is invasive and carries risks for infection and trauma. Furthermore, FSE can be applied only when sufficient dilation of the cervix is achieved and membranes have ruptured. DU is a non-invasive method, but shows high percentages of signal loss, especially in obese women, and it is often is experienced as uncomfortable by the patient. [7] NI-fECG is a relatively new method based on electrophysiologic monitoring performed non-invasively using electrodes on the abdomen of the mother.

Recent developments in signal processing techniques and improvements of algorithms make it possible to simultaneously monitor FHR, MHR and uterine contractions with one device in a non-invasive manner. Intrapartum monitoring by NI-fECG may therefore be an alternative for monitoring by FSE and DU. This review evaluates the performance of the NI-fECG technique during the last decade.

Performance measures of the NI-fECG

The earliest studies describing the use of NI-fECG during labor date back to the 20th century and therefore describe the performance of NI-fECG devices that are outdated. [26,29] However, such studies substantiate the potential added value of NI-fECG during labor, even when development of the technique was in a premature stage. Breuker et al. found that only 15% of the recordings were of deficient quality and in the 5 cases described by Frank et al. 92.6% of the FHR output of the NI-fECG was within 1bpm of the FHR measured by FSE. [26,29]

Accuracy

All studies found a higher accuracy for the NI-fECG technique compared to DU, when using FSE as reference. [22–24] Both Cohen et al. and Euliano et al. report an accuracy of about 5 bpm, which is noticeably higher than their reported values for DU. However, there is a risk of selection bias in these studies since they only include women who received FSE for fetal monitoring due to insufficient quality of DU. Therefore, results of the performance measures of the DU may be negatively influenced. The insufficient quality of the registration by DU may be partially explained by the high median BMI of both study populations, since it is known that DU performance worsens with increasing maternal BMI. [30,31]

Ashwal et al. found a high accuracy for NI-fECG. Their reported accuracy for DU is also high compared to the literature. Since they used random segments from the total recording, it is likely not to be representative for the total measurement. [24]

Reinhard et al. used the correlation coefficient as an outcome measure to reflect the accuracy of their device, using the DU method as reference. They report a good statistical agreement between NI-fECG and DU (Spearman's rank correlation coefficient of 0.94 for the first stage of labor and 0.85 for the second stage of labor). [25] A correlation coefficient close to 1 means that there is a high level of agreement between the output of both devices. However, this is an inappropriate method for measuring accuracy, as the correlation coefficient only measures the strength of the linear association between variables. [32] In addition, since Reinhard et al. used the DU method, which has poor performance measures compared to FSE, as reference method, this high level of agreement has no clinical importance.

Reliability

A high reliability is an important property for a medical device to be of value in clinical practice. Cohen et al. and Euliano et al. found similar results for overall reliability (81.7 and 83.4 respectively) for NI-fECG monitoring. Overall reliability for DU reported by Cohen et al. and Euliano et al. is lower than NI-fECG (73.0 and 62.4). Reliability percentages decrease during the second stage of labor in both studies, for the NI-fECG as well as the DU technique. [22,23] This decrease in performance is a known disadvantage of the DU method, probably due to maternal movement and increased intra-abdominal pressure during the active pushing phase. Both Euliano et al. and Cohen et al. found higher reliability percentages for NI-fECG compared to the DU technique, also during the second stage of labor. [22,23] Reliability values reported by Ashwal et al. are nearly 100%, for both the NI-fECG and the DU method. As previously described, in this study random segments from the total measurement were used to analyze reliability. [24] The fact that their reported reliability value for the DU technique is 96.6% whereas other literature shows much lower reliability percentages for DU, further supports our explanation that these random segments are not representative for the entire measurement. [22,23]

Success rate

Only three articles reported on the success rate. [22,25,27] Since success rate is defined as the percentage of time the device provides output, it resembles the percentage of signal loss, without providing information on the quality of the registered information. A similar overall success rate for the NI-fECG and DU technique was reported by Cohen et al. and Stampalija et al. [22,27]

In all three articles a decrease in success rate of NI-fECG was noticed as labor progressed. This is also a known pitfall of the DU technique. [2] Cohen et al. found similar success rates between NI-fECG and DU (83.4% and 82.5% respectively). [22] Stampalija et al. found a significantly higher success rate for DU in the second stage of labor as compared to NI-fECG, which was also described by Reinhard et al. [25,27] They also report a rise in success rate between the first and second stage of labor for DU. [25] These results may demonstrate the limitation of success rate as an outcome measure if other outcome measures are not taken into consideration.

Reinhard et al. used a different definition for reliability. They defined reliability as the percentage of available FHR in the recorded time period. According to this definition, they found a significant difference in reliability between NI-fECG and DU during the first stage of labor (87.09 vs. 85.21) but not during the second stage of labor (70.51%vs 76.46%). [28] Since no reference method was used to compare the FHR output from DU and NI-fECG interpretation of these results is difficult. In this setting, their definition for reliability better reflects the definition of success rate; the time the investigational device provides an output.

Confusion rate

From the articles that reported on MHR/FHR confusion only Cohen et al. used a validated method for MHR monitoring, which is pulse oximetry. [22] Reinhard et al. and Stampalija et al. used the NI-fECG device as a reference method for the performance measures being researched in their study. [27,28] Theoretically, by using NI-fECG, confusion between MHR and FHR is unlikely since electrophysiological signals from the mother are relatively strong compared to those of the fetus. Since NI-fECG is measuring both MHR and FHR by a single device, these signals can be separated very well. All three studies demonstrated that confusion of MHR and FHR is significantly lower with NI-fECG as compared to DU. [22,27,28] This is an important characteristic, since confusion of MHR and FHR can lead to unnecessary interventions or failure to intervene where intervention was needed, sometimes leading to a seriously compromised fetus.

General remarks

Overall, this review demonstrates that there is limited research regarding monitoring by NI-fECG during labor. Studies have small sample sizes and comparing them is difficult due to heterogeneity. Furthermore, three studies did not use the FSE as reference. [25,27,28] Therefore, interpretation and clinical validity of their results regarding accuracy, reliability and confusion rate is difficult.

Despite differences in methodology and type of NI-fECG devices, all included studies in this review demonstrate that it is possible to apply NI-fECG during labor. Compared to the currently used standard method for non-invasive fetal monitoring, which is DU, NI-fECG performs equally well, or better in most studies. Even during the second stage of labor, when a decrease in performance is noticed in most reports, it is shown that NI-fECG still performs equally or better compared to DU. [2] Studies that compare NI-fECG and DU with FSE showed that DU and NI-fECG have comparable success rates. However, compared to DU, accuracy and reliability of NI-fECG is higher and confusion rate is lower.

In two studies, the success rate for NI-fECG in the second stage of labor was lower compared to DU. [25,27] These success rates are insufficient according to the FIGO criteria for accepted percentages of signal loss of ≤20%. [33] One of these studies also showed a higher FHR/MHR confusion rate for DU, especially during the second stage of labor. [27] Even though DU may have a higher success rate, the output that is generated may not always be as reliable as NI-fECG. Although in fetal monitoring it is generally desirable to have a good signal quality at all times, it is most important to have a good balance between signal quality and the reliability of the generated output. This review therefore shows NI-fECG to be a more accurate alternative to DU.

In addition to improved test characteristics, patient satisfaction with this type of non-invasive monitoring is also better with NI-fECG, as compared to conventional non-

invasive monitoring by DU. [7] Moreover, non-invasive monitoring by NI-fECG also yields several diagnostic opportunities. It may provide information on a preterm fetus, when invasive monitoring is not an option or discouraged due to contraindications. The NI-fECG provides beat-to-beat fetal heart rate, which enables the use of spectral analysis. [34] Spectral analysis can monitor the modulation of the autonomic nervous system by evaluating oscillations in beat-to-beat fetal heart rate and can differentiate between an asphyxiated and healthy fetus during labor. [35–39] Furthermore, the NI-fECG may provide information on the actual fetal ECG waveform complex, identifying other abnormalities that may indicate fetal distress. This has previously been attempted by combining FSE with ST waveform analysis (STAN). [13–16] Since the NI-fECG uses multiple leads, one of the limitations of STAN, which only uses a single lead scalp electrode, is avoided. [17–19]

To conclude, NI-fECG for FHR monitoring is a promising technique that is non-invasive, patient-friendly and provides accurate information. Future studies should focus on evaluating and improving signal quality of the NI-fECG, especially during the second stage of labor. Prospective studies on several diagnostic opportunities of this technique may help implementing NI-fECG in daily clinical practice.

References

1. Alfirevic Z, Devane D, Gyte GM, Cuthbert A. Continuous cardiotocography (CTG) as a form of electronic fetal monitoring (EFM) for fetal assessment during labour. Cochrane database Syst Rev. 2017 Feb;2:CD006066.
2. Bakker PC, Colenbrander GJ, Verstraeten AA, Geijn HP Van. The quality of intrapartum fetal heart rate monitoring. Eur J Obstet Gynecol Reprod Biol. 2004 Sep;116(1):22–7.
3. Belcher R, Dawes GS. The influence of signal loss on the comparison between computer analyses of the fetal heart rate in labour using pulsed doppler ultrasound (with autocorrelation) and simultaneous scalp electrocardiogram. 1987;25:29–34.
4. Dawes GS, Visser GHA, Goodman JDS, Levine DH. Numerical analysis of the human fetal heart rate : Modulation by breathing and movement. Am J Obstet Gynecol. 1981;140(5):535–44.
5. Herman P. Analysis of heart rate and beat-to-beat variability : Interval difference index. Am J Obstet Gynecol. 1980;138(3):246–52.
6. Cohen WR, Hayes-Gill B. Influence of maternal body mass index on accuracy and reliability of external fetal monitoring techniques. Acta Obstet Gynecol Scand. 2014;93(6):590–5.
7. Thijssen KMJ, Vlemminx MWC, Westerhuis MEMH, Dieleman JP, der Hout-Van der Jagt MB, Oei SG. Uterine Monitoring Techniques from Patients' and Users' Perspectives. AJP Rep. 2018 Jul;8(3):e191.
8. Kawakita T, Reddy UM, Landy HJ, Iqbal SN, Huang CC, Grantz KL. Neonatal complications associated with use of fetal scalp electrode: a retrospective study. BJOG An Int J Obstet Gynaecol. 2016;123(11):1797–803.
9. Leatherman J, Parchman ML, Lawler FH. Infection of fetal scalp electrode monitoring sites. Am Fam Physician. 1992 Feb;45(2):579–82.
10. Bretscher J, Saling E. pH values in the human fetus during labor. Am J Obstet Gynecol. 1967 Apr;97(7):906–11.
11. van den Berg P, Schmidt S, Gesche J, Saling E. Fetal distress and the condition of the newborn using cardiotocography and fetal blood analysis during labour. Br J Obstet Gynaecol. 1987 Jan;94(1):72–5.
12. Westgate J, Greene K. How well is fetal blood sampling used in clinical practice? Br J Obstet Gynaecol. 1994 Mar;101(3):250–1.
13. Westerhuis MEMH, Visser GHA, Moons KGM, Van Beek E, Benders MJ, Bijvoet SM, Van Dessel HJHM, Drogtrop AP, Van Geijn HP, Graziosi GC, Groenendaal F, Van Lith JMM, Nijhuis JG, Oei SG, Oosterbaan HP, Porath MM, Rijnders RJP, Schuitemaker NWE, Sopacua LM, Van Der Tweel I, Wijnberger LDE, Willekes C, Zuithoff NPA, Mol BWJ, Kwee A. Cardiotocography plus ST analysis of fetal electrocardiogram compared with cardiotocography only for intrapartum monitoring: A randomized controlled trial. Obstet Gynecol. 2010;115(6):1173–80.

14. Saccone G, Schuit E, Amer-Wahlin I, Xodo S, Berghella V. Electrocardiogram ST Analysis During Labor: A Systematic Review and Meta-analysis of Randomized Controlled Trials. Obstet Gynecol. 2016 Jan;127(1):127–35.
15. Belfort MA, Saade GR, Thom E, Blackwell SC, Reddy UM, Thorp JMJ, Tita ATN, Miller RS, Peaceman AM, McKenna DS, Chien EKS, Rouse DJ, Gibbs RS, El-Sayed YY, Sorokin Y, Caritis SN, VanDorsten JP. A Randomized Trial of Intrapartum Fetal ECG ST-Segment Analysis. N Engl J Med. 2015 Aug;373(7):632–41.
16. Blix E, Brurberg KG, Reierth E, Reinar LM, Oian P. ST waveform analysis versus cardiotocography alone for intrapartum fetal monitoring: a systematic review and meta-analysis of randomized trials. Acta Obstet Gynecol Scand. 2016 Jan;95(1):16–27.
17. Vullings R, Verdurmen KMJ, Hulsenboom ADJ, Scheffer S, De Lau H, Kwee A, Wijn PFF, Amer-Wåhlin I, Van Laar JOEH, Oei SG. The electrical heart axis and ST events in fetal monitoring: A post-hoc analysis following a multicentre randomised controlled trial. PLoS One. 2017;12(4):1–11.
18. Hulsenboom ADJ, Vullings R, Van LJ, Van Der Hout-Van Der JM, Oei SG. How to improve st-analysis in fetal monitoring: Relative versus absolute t/qrs ratio rises. J Matern Neonatal Med. 2014;27:191–2.
19. Andriessen P, Zwanenburg A, van Laar JOEH, Vullings R, Hermans BJM, Niemarkt HJ, Jellema RK, Ophelders DRMG, Wolfs TGAM, Kramer BW, Delhaas T. ST waveform analysis for monitoring hypoxic distress in fetal sheep after prolonged umbilical cord occlusion. PLoS One. 2018;13(4):1–14.
20. Cremer M. Über die direkte Ableitung der Aktionsströme des menschlichen Herzens vom Oesophagus und über das Elektrokardiogramm des Fötus. Munchener medizinische Wochenschrift. 1906;53:811–3.
21. Whiting P, Rutjes A, Westwood M, Mallett S, Deeks J, Reitsma J, Leeflang M, Sterne J, Bossuyt P. QUADAS-2: A Revised Tool for the Quality Assessment of Diagnostic Accuracy Studies. Ann Intern Med [Internet]. 2011 Oct 18;155(8):529. Available from: http://annals.org/article.aspx?doi=10.7326/0003-4819-155-8-201110180-00009
22. Cohen WR, Ommani S, Hassan S, Mirza FG, Solomon M, Brown R, Schifrin BS, Himsworth JM, Hayes-Gill BR, W.R. C, S. O, S. H, F.G. M, M. S, R. B, B.S. S, J.M. H. Accuracy and reliability of fetal heart rate monitoring using maternal abdominal surface electrodes. Acta Obstet Gynecol Scand. 2012 Nov;91(11):1306–13.
23. Euliano TY, Nguyen MT, Euliano N, Gregg AR, Busowski JD, Darmanjian S. Monitoring Fetal Heart Rate during Labor: A Comparison of Three Methods. J Pregnancy. 2017;2017:1–5.
24. Ashwal E, Shinar S, Aviram A, Orbach S, Yogev Y, Hiersch L, E. A, S. S, A. A, S. O, Y. Y. A novel modality for intrapartum fetal heart rate monitoring. J Matern Neonatal Med. 2019 Mar;32(6):889–95.

25. Reinhard J, Hayes-Gill BR, Schiermeier S, Hatzmann W, Herrmann E, Heinrich TM, Louwen F. Intrapartum signal quality with external fetal heart rate monitoring: a two way trial of external Doppler CTG ultrasound and the abdominal fetal electrocardiogram. Arch Gynecol Obstet. 2012 Nov;286(5):1103–7.
26. Frank TH, Blaumanis OR, Chen SH, Petrie RH, Gibbs RK, Wells RL, Johnson TRB. Noninvasive fetal ECG mode fetal heart rate monitoring by adaptive digital filtering. J Perinat Med. 1992;20(2):93–100.
27. Stampalija T, Signaroldi M, Mastroianni C, Rosti E, Signorelli V, Casati D, Ferrazzi EM. Fetal and maternal heart rate confusion during intra-partum monitoring: comparison of trans-abdominal fetal electrocardiogram and Doppler telemetry. J Matern Fetal Neonatal Med. 2012 Aug;25(8):1517–20.
28. Reinhard J, Hayes-Gill BR, Schiermeier S, Hatzmann H, Heinrich TM, Louwen F. Intrapartum Heart Rate Ambiguity: A Comparison of Cardiotocogram and Abdominal Fetal Electrocardiogram with Maternal Electrocardiogram. Gynecol Obstet Invest [Internet]. 2013;75(2):101–8. Available from: http://www.karger.com/journals/goi/goi_jh.htm
29. Breuker KH, Khalili BD, Bolte A. The abdominal fetal EKG for the analysis of pre and subpartual heart frequency. Arch Gynakol. 1976;221(3):211–35.
30. Brocato B, Lewis D, Mulekar M, Baker S. Obesity's impact on intrapartum electronic fetal monitoring. J Matern Fetal Neonatal Med. 2017 Sep;1–3.
31. Cohen WR. Influence of maternal body mass index on accuracy and reliability of external fetal monitoring techniques. Acta Obstet Gynecol Scand. 2014;93(6):590–5.
32. Zaki R, Bulgiba A, Ismail R, Ismail NA. Statistical Methods Used to Test for Agreement of Medical Instruments Measuring Continuous Variables in Method Comparison Studies : A Systematic Review. 2012;7(5):1–7.
33. The International Federation of Gynecology and Obstetrics. Guidelines for the use of fetal monitoring. Int J Gynecol Obstet. 1987;25(3):159–67.
34. Peters CHL, van Laar JOEH, Vullings R, Oei SG, Wijn PFF. Beat-to-beat heart rate detection in multi-lead abdominal fetal ECG recordings. Med Eng Phys. 2012;34(3):333–8.
35. van Laar JOEH, Peters CHL, Houterman S, Wijn PFF, Kwee A, Oei SG. Normalized spectral power of fetal heart rate variability is associated with fetal scalp blood pH. Early Hum Dev. 2011;87(4):259–63.
36. van Laar JOEH, Porath MM, Peters CHL, Oei SG. Spectral analysis of fetal heart rate variability for fetal surveillance: Review of the literature. Acta Obstet Gynecol Scand. 2008;87(3):300–6.
37. van Laar JOEH, Peters CHL, Vullings R, Houterman S, Bergmans JWM, Oei SG. Fetal autonomic response to severe acidaemia during labour. BJOG An Int J Obstet Gynaecol. 2010;117(4):429–37.

38. Verdurmen KMJ, Warmerdam GJJ, Lempersz C, Hulsenboom ADJ, Renckens J, Dieleman JP, Vullings R, van Laar JOEH, Oei SG. The influence of betamethasone on fetal heart rate variability, obtained by non-invasive fetal electrocardiogram recordings. Early Hum Dev. 2018 Apr;119:8–14.
39. Warmerdam GJJ, Vullings R, Laar JOEH Van, der Hout-Van der Jagt MB Van, Bergmans JWM, Schmitt L, Oei SG. Detection rate of fetal distress using contraction-dependent fetal heart rate variability analysis. Physiol Meas. 2018 Feb;39(2):25008.

Appendix

Appendix 1. Search strategy: MEDLINE (Pubmed, 1966 – Present)

1. “Fetus”[Mesh] OR fetus*[tiab] OR foetus*[tiab] OR fetal[tiab] OR foetal*[tiab]
2. “Electrocardiography”[Mesh] OR electrocardiogra*[tiab] OR ECG[tiab]
3. “Cardiotocography”[Mesh] OR cardiotocogra*[tiab] OR CTG[tiab]
4. #2 OR #3
5. #1 AND #4
6. “Fetal Monitoring”[Mesh]
7. (fetal[tiab] OR foetal[tiab] OR fetus*[tiab] OR foetus*[tiab]) AND monitor*[tiab]
8. #6 OR #7
9. #5 OR #8
10. abdominal[tiab] OR non invasive[tiab] OR external[tiab]
11. #9 AND #10
12. “Labor, Obstetric”[Mesh] OR labor[tiab] OR labour[tiab] OR intrapartum[tiab]
13. #11 AND #12

Appendix 2. Summary of the eight included articles

Author, year	Participants	NI-fECG method	Reference method	Outcome measures	Results during labor	Comments
Breuker 1976	**Inclusion criteria:** during pregnancy and labor	Prototype Hewlett & Packard, modell nr. 15174 A.	FSE	**Quality:** percentage of signal loss	N=173. **Results:** Excellent: N=30 17,3% Good: N=40 23,1% Satisfactory: N=46 26,6% Sufficient: N=31 17,9% Deficient: N=26 15,0% 2nd stage: No clinical evaluation possible: N=34, 30.3%	• Used self-defined outcome measure.
Frank 1992	**Inclusion criteria:** term uncomplicated singleton pregnancy	Prototype Perinatronics Prototype FHR monitor.	FSE	**Accuracy:** Differences in R-R interval	N=5. **Results**: Mean difference R-R interval 0.0056 bpm Accuracy: - Within 1 bpm 92,6% - Within 2 bpm 98,2%	• Different definition of accuracy compared to other studies.

Appendix 2. Summary of the eight included articles

Author, year	Participants	NI-fECG method	Reference method	Outcome measures	Results during labor	Comments
Stampalija 2012	**Inclusion criteria:** uneventful term singleton pregnancy **Exclusion criteria:** multiple pregnancies, fetal abnormalities, presence of maternal pathologies	Monica AN24 [Monica Healthcare, Nottingham, UK]	DU telemetry	**(Overall) success rate of FHR monitoring:** Percentage of the 0.25 seconds epochs where a FHR was produced. **Maternal-fetal heart rate confusion (CR):** FHR within 5bpm from MHR.	N=41. N=21 1st and 2nd stage. N=18 1st stage only. **Results** Success rate: Overall DU 89.4% (±7.6), NI-fECG 88.5% (±16.7) (p0.77). 1st stage DU 89.9% (±7.9), NI-fECG 89.8% (±16.1) (p0.98) 2nd stage DU 83.7% (±7.4), NI-fECG 66.5% (±21.3) (p<0.001). Confusion rate: Overall DU 4.5% (±4.5), NI-fECG 1.3% (±1.9) p<0.001). 1st stage DU 3.9% (±4.6), NI-fECG 1.0 (±1.9) (p<0.001). 2nd stage DU 11.3% (±8.2), NI-fECG 4.6% (±5.0) (p=0.002).	• No gold standard as reference • 2 cases excluded: no FHR in fECG measurements due to high electrical noise • No gold standard used for MHR. MHR derived from Monica AN24

Appendix 2. Summary of the eight included articles

Author, year	Participants	NI-fECG method	Reference method	Outcome measures	Results during labor	Comments
Reinhard 2012	**Inclusion criteria:** Singleton pregnancy, admitted to Marien Hospital Witten for delivery.	Monica AN24 [Monica Healthcare, Nottingham, UK]	DU	**FHR Success rate**: Percentage of time a FHR value was reported divided by total time. **Percentage of patients with FHR signal loss <20% or <15%.** **Correlation:** Correlation between FHR success rate and BMI/stage of labor/ birth weight/epidural	N=144. 1st stage N=138, 2nd stage N=98 **Results** Success rate: 1st stage. DU 85,5% (35.1-99.8%) NI-fECG 97.7% (7.8-100%) (p<0.001) 2nd stage: DU 92.3% (22.5-99.8%), NI-fECG 85.5% (13.4-100%), (p>0.05) Signal loss <20%: 1st stage: DU 89.6%, fECG 81.5% 2nd stage: DU 76.5%, fECG 54.1% Signal loss <15%: 1st stage: DU 80.7%, fECG 77.8% 2nd stage: DU 64.3% fECG 48% Correlation: *1st stage fECG FHR success rate correlation with:* - 2nd stage fECG FHR 0.68 - Birth weight 0.22 - 1st stage CTG FHR 0.34 - 2nd stage CTG 0.15 - EDA 0.10 - BMI 0.00 *2nd stage fECG FHR success rate correlation with:* - DU 1st stage 0.15 - DU 2nd stage 0.41 - BMI -0.14 - Birth weight 0.19 - EDA -0.03	• No gold standard as reference • Intermittent DU • For different baseline characteristics a mean and median is given • Data was excluded if: simultaneous DU and fECG <20min during 1st stage or <5 min during 2nd stage • Outlier removal: data outside a 60–200 bpm, FHR data within 5bpm from MHR, isolated FHR datapoints (FHR <10 s in duration with absolute FHR difference from the baseline of >15 bpm)

Appendix 2. Summary of the eight included articles

Author, year	Participants	NI-fECG method	Reference method	Outcome measures	Results during labor	Comments
Cohen 2012	**Inclusion criteria**: singleton term pregnancy, arrived at the hospital early in or prior to labor. **Exclusion criteria**: known major fetal anomaly, fetal malpresentation, maternal abdominal skin rash or history of adhesive sensitivity, patients only monitored with the two external monitors	Monica AN24 [Monica Healthcare, Nottingham, UK])	FHR: FSE MHR: Pulse oximetry	**Accuracy:** Comparison of FHR output from DU and NI-fECG with the average of FHR of the FSE. **Reliability:** output within 10% of the standard (FSE) **Success rate:** proportion of recording DU and NI-fECG had a non-zero output for FHR **Confusion rate (CR):** percentage of FHR of DU and NI-fECG that was both more than 5% different from that of the FSE and within 5% of the MHR.	N=138. N=75 complete for analysis. **Results** Overall reliability: Overall DU 73% (±24.6), NI-fECG 81,7% (±20.5) (p<0.01) 1st stage DU 74.7%(±28.2), NI-fECG 84.9% (±21.5) (p<0.01) 2nd stage DU 61.7% (±24.8), NI-fECG 71.9% (±20.4) (p<0.01) Accuracy: DU 10.6 bpm, NI-fECG 5.2 bpm (p<0.0001) 1st stage DU 8.7 bpm (±5.7), NI-fECG 4.5 (±2.4) (p<0.0001) 2nd stage DU 16.1 bpm (±7.6), NI-fECG 7.9 (±4.2) (p<0.0001) Success rate: DU 82.5% (±21.1), NI-fECG 83.4% (±20.1) (p=0.38) 1st stage DU 82.6% (±24.4), NI-fECG 86.4% (±21.1) (p=0.12) 2nd stage DU 77.8% (±21.1), NI-fECG 75.2% (±19.2) (p=0.25) Confusion rate (n=47): Overall DU 8.9% (±15.2), NI-fECG 0.4% (±0.6) (p0.0002). 1st stage DU 9.5% (±17.8), NI-fECG 0.3% (±0.6) (p0.0007) 2nd stage DU 11.0% (±15.4), NI-fECG 0.7% (±0.8) (p0.0007)	• FSE was only applied when CTG was abnormal to substitute DU • 63 excluded participants • High mean BMI 32.6 kg/m2

Appendix 2. Summary of the eight included articles

Author, year	Participants	NI-fECG method	Reference method	Outcome measures	Results during labor	Comments
Reinhard 2013	**Inclusion criteria:** singleton pregnancy, admitted to Marien Hospital Witten for delivery.	Monica AN24 [Monica Healthcare, Nottingham, UK]	DU	**Percentage FHR and MHR ambiguity over total recording time:** FHR within 5bpm of MHR. **Reliability:** percentage of success rate of recording FHR data.	N=144. 1st stage N=135, 2nd stage N=98. **Results** Ambiguity 1st stage DU 1.22%, NI-fECG 0,70%($p<0.001$) 2nd stage DU 6.20%, NI-fECG 3,30% ($p<0.001$) Reliability: 1st stage DU 85,2%, NI-fECG 87,1% ($p<0.001$) 2nd stage DU 76,5%, NI-fECG 70,5% ($p>0.05$)	• No gold standard as reference for FHR • No gold standard for MHR. MHR derived from Monica AN24 • Did not use the right definition for reliability. • For multiple characteristics a median and mean is given
Ashwal 2017	**Inclusion criteria:** ≥18 years, singleton term pregnancy, no known fetal anomalies or chromosomal defects, spontaneous rupture of membranes during latent phase of labor. **Exclusion criteria:** signs suggestive for chorioamnionitis, implanted electronic device, maternal allergy to silver, irritated skin or open abdominal wounds	EUM100Pro [OB tools, Nesher, Isreal]	FSE	**Correlation:** between DU and FSE, NI-fECG and FSE FHR traces. **Accuracy:** difference in FHR output of DU and NI-fECG compared to FSE	N=33. **Results** Correlation: DU/FSE and NI-fECG/FSE both $r^2=0.98$ ($p<0.001$). Reliability: Overall DU 96.0%, EUM 98.5%, ($p<0,001$). 1st stage DU 97.1%, NI-fECG 99.0% 2nd stage DU 94.9%, NI-fECG 98.5% Accuracy: DU 5.39 bpm, EUM 1.47bpm	• Only random non-continuous 30 minutes of the recording time was used for analysis from each phase (latent, 1st stage and 2nd stage) of labor. • Mean and median are given for correlation

CHAPTER 7

Intrapartum non-invasive electrophysiological monitoring: a prospective observational study.

C. Lempersz*, L. Noben*, G. Van Osta, M.M.L.H. Wassen, A.P.J. Meershoek, P. Bakker, Y. Jaquemyn, M.J. Cuerva, R. Vullings, M.E.M.H. Westerhuis, S.G. Oei

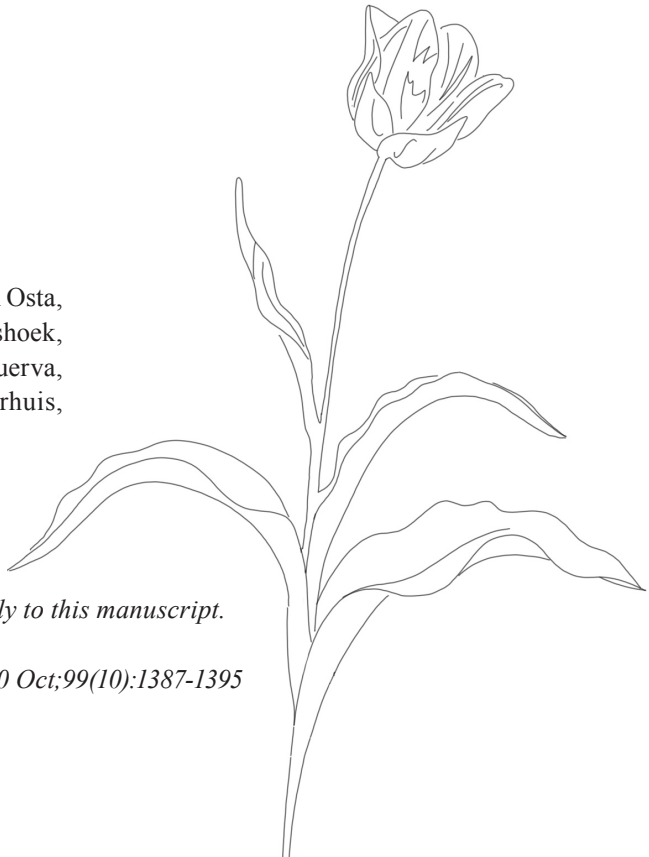

* *Both authors contributed equally to this manuscript.*

Acta Obstet Gynecol Scand. 2020 Oct;99(10):1387-1395

Abstract

Introduction: Doppler ultrasound (DU) cardiotocography (CTG) is a non-invasive alternative which despite its poor specificity is often first choice for intrapartum monitoring. DU suffers from signal loss due to fetal movements and is negatively correlated with maternal BMI. Reported accuracy of fetal heart rate (FHR) monitoring by DU varies between 10.6 and 14.3 beats per minute (bpm) and reliability between 62.4% and 73%. The fetal scalp electrode (FSE) is considered gold standard for fetal monitoring but can only be applied after membranes have ruptured with sufficient cervical dilatation and is sometimes contra-indicated. A non-invasive alternative which overcomes the shortcomings of DU, providing reliable information on FHR could be the answer. Non-invasive fetal electrocardiography (NI-fECG) uses a wireless electrode patch on the maternal abdomen to obtain both fetal and maternal heart rate signals as well as an electrohysterogram. We aimed to validate a wireless NI-fECG device for intrapartum monitoring in term singleton pregnancies, by comparison to the FSE.

Material and methods: We performed a multicenter cross-sectional observational study at labor wards of six hospitals located in the Netherlands, Belgium and Spain. Laboring women with a healthy singleton fetus in cephalic presentation and gestational age between 36 and 42 weeks were included. Participants received an abdominal electrode patch and FSE after written informed consent. Accuracy, reliability and success rate of fetal heart rate were determined, using FSE as reference standard. Analysis was done for the total population and measurement period as well as separated by labor stage and BMI class (≤ 30 and > 30 kg/m^2).

Results: We included a total of 125 women. Simultaneous registrations with NI-fECG and FSE were available in 103 women. Overall accuracy is -1.46 bpm and overall reliability 86.84%. Overall success rate of the NI-fECG is around 90% for the total population as well as for both BMI subgroups. Success rate dropped to 63% during second stage of labor, similar results are found when looking at the separate BMI groups.

Conclusion: Performance measures of the NI-fECG device are good in the overall group and the separate BMI groups. Compared to Doppler Ultrasound performance measures from the literature, NI-fECG is a more accurate alternative. Especially, when patients have a higher BMI, NI-fECG performs well, resembling FSE performance measures.

Introduction

External monitoring of the fetal heart rate (FHR) and uterine activity (UA) by means of Doppler ultrasound (DU) and tocodynamometry (TOCO) is often first choice for intrapartum monitoring. Monitoring by means of fetal scalp electrode (FSE) and intra-uterine pressure catheter (IUPC) remain the gold standard, but healthcare providers are cautious in applying these invasive methods due to risk of injury and infection.[1] Compared to the FSE, performance measures for DU are poor. Previous studies found an accuracy varying between 10.6 and 14.3 beats per minute (bpm) and reliability varying between 62.4% and 73%.[2,3] Furthermore, the performance of both DU and TOCO deteriorates with increasing maternal BMI and are susceptible to signal loss due to fetal and maternal movements.[4,5]

Development of additional technologies to improve the poor specificity of the CTG did not significantly improve perinatal outcome (e.g. ST waveform analysis, fetal blood sampling).[6,7] A reliable non-invasive fetal monitoring method which overcomes the shortcomings of DU and TOCO, with the possibility of obtaining additional information regarding fetal wellbeing could be the answer.

Non-invasive fetal electrocardiography (NI-fECG) is a relatively new technology that uses an electrode patch on the maternal abdomen to monitor both fetal and maternal heart rate (MHR) as well as UA. The NI-fECG technology relies on electrophysiological signals to deliver beat-to-beat information on the FHR, by detecting a real-time ECG. UA can also be monitored using electrophysiology, by means of electrohysterography (EHG). Previous studies have shown that EHG has a higher sensitivity in detecting uterine contractions during labor, especially in obese women.[8,9] In this study, we aimed to validate a wireless NI-fECG device as a non-inferior method to DU for intrapartum fetomaternal monitoring in term singleton pregnancies, by comparison to the FSE. Furthermore, we compared our results with the performance measures of DU from existing literature.[2,3]

Materials and methods

We conducted an international multicenter cross-sectional observational study from February 2018 until July 2018. Women in established labor, carrying a healthy singleton fetus in cephalic presentation, with a gestational age between 36 and 42 weeks were eligible to participate. Exclusion criteria were multiple pregnancy, contra-indications for FSE, dermatologic diseases of the abdomen and signs of fetal distress at the moment of inclusion. After written informed consent, participants received an electrode patch (Nemo Healthcare BV, Veldhoven, the Netherlands) consisting of 6 electrodes (Figure 1). First, to improve signal quality, the skin was washed with water and soap and prepared using medical abrasive paper (Red Dot™ Trace Prep, 3M Health Care, Ontario, Canada). Second, the electrode patch was applied and a wireless amplifier (link) was placed on top

of the patch (Figure 1). Skin impedance was automatically checked and skin preparation was repeated if necessary.

Patients were simultaneously monitored according to standard clinical protocol with DU (Philips Avalon FM30 CTG, Philips Healthcare, Eindhoven, the Netherlands) in the period before rupture of membranes. DU was replaced by our standard reference (FSE) once membranes had ruptured as part of standard clinical practice, which was connected to the CTG monitor (Philips Avalon FM30 or STAN® S31 monitor, Neoventa Medical AB, Mölndal, Sweden). Both the NI-fECG device (Nemo healthcare BV, Veldhoven the Netherlands, not commercially available) and the CTG monitor were connected to an external datalogger (CMS series 50) to ensure parallel data storage from both devices. NI-fECG measurement ended once the woman gave birth, when cesarean delivery was needed, when the woman ended participation or when she wanted to take a bath or shower.

Figure 1. NI-fECG electrode patch and device

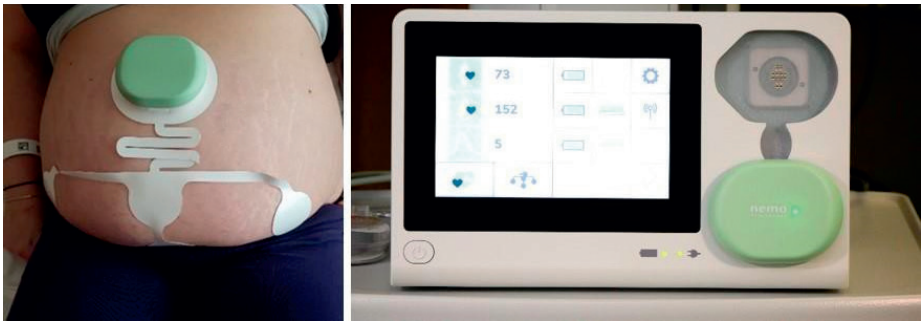

Footnote: The left picture shows the electrode patch with a green amplifier (Link). On the right, a pre-production version of the NI-fECG base station is shown, with two charging positions for individual Links.

Data acquisition and signal processing

Signals recorded by each of the electrodes were digitized and pre-processed by the link and transmitted wirelessly to the base station. Further signal processing was performed via proprietary algorithms and comprises of checking the validity of the received data, suppression of maternal ECG and other interferences (e.g. from abdominal muscles and mains powerline), and subsequent calculation of FHR, MHR, and UA.

The FHR, MHR, and UA values are calculated at 0.25s intervals (4 Hz) and via serial port communicated to aforementioned data logger and central monitoring system. To enable retrospective analysis, calculated FHR, MHR, and UA values, as well as raw data, are also locally stored on the base station.

Statistical analysis

Power calculations
Sample size calculation was performed based on paired data from our pilot study (data not published) in 50 term singleton deliveries at the Máxima Medical Center. A sample size of 100 patients enables the estimation of the standard deviation (SD) with a precision of 0.34*SD. This sample size together with the SD from the pilot study of 8.6 bpm will enable with 80% power for the estimate of the accuracy to lie within 95% confidence within 3.5 bpm. This margin for accuracy was considered to be clinically significant by several obstetric clinicians. Taking into account a missing data rate of 20%, we aimed to include 120 participants.

Analyses were done for the total population and measurement period as well as separated by labor stage (first and second stage)[10] and BMI class based on the preconceptional weight (≤ 30 and > 30 kg/m^2).

Fetal heart rate
The FSE was used as reference standard to determine the performance measures of FHR. We then later compared our results descriptively with DU performance measures as described in the literature.

Accuracy (bpm) was calculated as the difference between NI-fECG and FSE value. To account for multiple observations on the same subject, accuracy was determined following the method of Bland & Altman. The 95% confidence interval (CI) was first determined by averaging accuracies per subject and subsequent calculating mean and SD of these averages. This 95% CI was compared with the aimed accuracy of 3.5 bpm. Limits of agreement (LoA) were determined using the approach for precision of estimated LoA.[11] In addition, FHR values of NI-fECG and FSE were compared through bootstrapping.[12] Each bootstrap sample was generated by drawing a random data-point (1 paired value for NI-fECG and FSE for each patient included in the analysis). Mean difference, SD and LoA were determined for the bootstrap sample. This process was then frequently repeated, leading to large distributions for the mean difference and lower and upper LoA. The average accuracy and 95% CI were then determined by taking the mean of the distribution of mean differences, with associated bootstrap 95% CI as determined by 2.5% and 97.5% percentile of the distribution of 10,000 mean differences from the bootstrap samples. From the 10,000 bootstrap samples also the mean S (SD of the bootstrap sample) was derived. LoA were then defined as mean accuracy +/- 2*mean(S).

Reliability is defined as the percentage of time in which the NI-fECG device delivers a FHR value within 10 bpm of the FSE value, during the period when both devices deliver

output. Reliability was determined for each subject. Mean, SD and 95% CI of the mean reliability were calculated.

Success rate is defined as the percentage of time in which the NI-fECG device delivers a FHR value. Success rate was determined following the same steps as described for reliability. In addition, success rate of the three modalities were compared using a non-parametric test on ranks, adjusted for multiple comparison using Tukey-Kramer.

Maternal heart rate
Accuracy and reliability of MHR monitored by NI-fECG was compared to MHR monitoring by standard of care such as Doppler pulse measurements provided by abdominal pulse oximetry, incorporated in the TOCO button (Philips Avalon FM30 CTG, Philips Healthcare, Eindhoven, the Netherlands) or finger pulse oximetry (LNCS DC-I® Adult digit sensor, Masimo, Neuchatel, Switzerland), depending on local protocol. Accuracy and reliability were determined as described under FHR. The clinically relevant boundaries were set at +/-10 bpm. Both upper and lower LoA should lie within these boundaries.

Uterine activity
We aimed to include 10 women who received an IUPC for contraction monitoring during labor. Due to the rare reported risks of the IUPC, it is not routinely applied during labor and in some hospitals only used on indication.[13,14] Since the EHG algorithm incorporated in this NI-fECG device is an improved version of a previously validated technology[15], we believe that this limited number of IUPC registrations would be sufficient for validation of contraction monitoring.

Ethical approval

The study protocol was approved by the institutional review board of the Máxima Medical Center on the 22nd of December 2017 (NL63732.015.17), University Hospital Antwerp on the 7th of May 2018 (B300201836393), La Paz Hospital Madrid on the 25th of March 2018 (PI-3140) and by local feasibility advisory committees in the remaining Dutch participating centers. The trial was registered in the Dutch trial register (www.trialregister.nl, NTR7064).

Results

From 125 laboring women informed consent was obtained. Figure 2 shows the flow diagram of patient inclusion. Baseline characteristics of 121 participants of which data was available are shown in table 1. These were similar to the baseline characteristics of the subgroup of 103 participants of whom combined registration by FSE and NI-fECG was available for analysis of our main outcome parameters.

Average duration of combined monitoring by NI-fECG and FSE for all participants was 223.6 minutes.

Figure 2. Flow diagram of patient inclusion

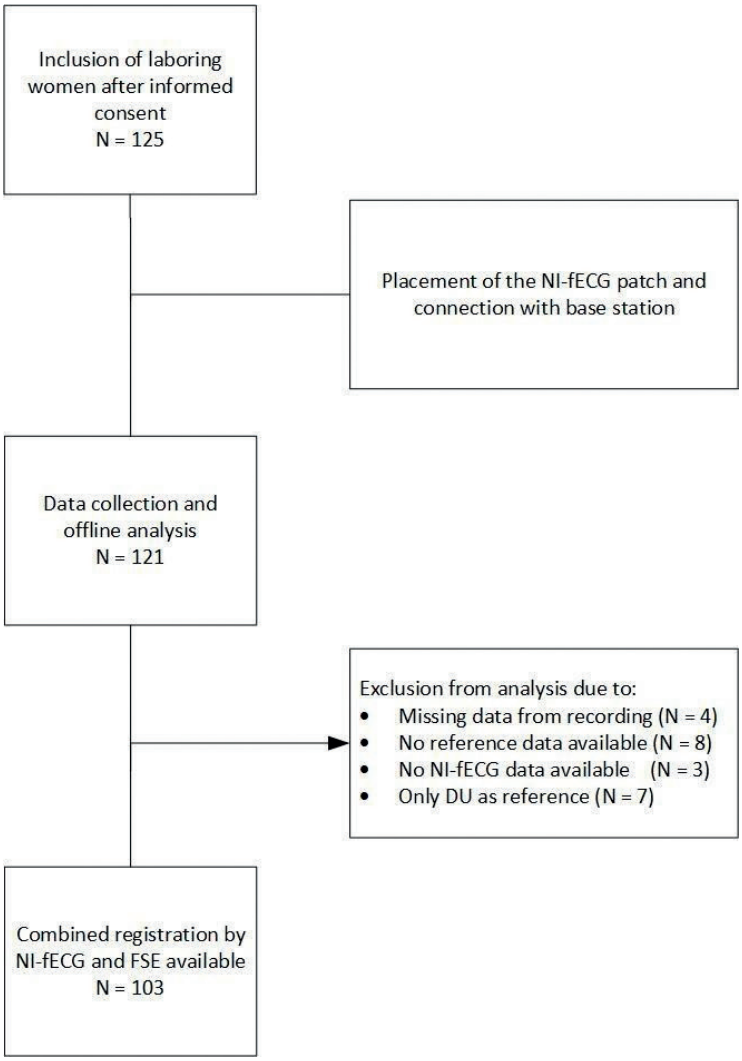

Table 1. Baseline Characteristics

Characteristics	N	
No. patients	121	
Age (years)	121	30.8 ± 4.6
Gestational age (wks)	121	39.5 ± 1.5
Ethnicity (%)		
Caucasian		83.5
Other		16.5
BMI (kg/m^2)		28.1 ± 5.9
BMI category (%)		
≤ 30 kg/m^2	82	67.8
> 30 kg/m^2	38	31.4
Missing	1	0.8
Parity (%)		
Nullipara	61	50.4
Multipara	60	49.6
EDA (%)		
Yes	73	60.3
No	48	39.7

Data provided are percentages (%) or means ± SD. Abbreviations: BMI = body mass index, EDA = epidural analgesia.

Fetal heart rate

Overall accuracy of NI-fECG device is -1.46 bpm (SD 4.22, 95% CI [-3.4, 0.48]) compared to FSE. The results are similar in both first and second stage, the latter having a larger SD leading to a wider 95% CI (table 2). Separate analysis based on BMI showed a slightly better accuracy in the higher BMI class with more narrow LoA (table 2).

Table 2. Accuracy of FHR measurements by NI-fECG as compared to FSE.

						Limits of agreement	
	Accuracy	**SD**	**95% CI**	**Min**	**Max**	**Lower**	**Upper**
All patients							
Overall (N = 103)	-1.5	4.2	-3.4; 0.5	-29.6	7.5	-29.2	26.3
Stage 1 (N = 102)	-1.4	3.7	-3.2; 0.4	-19.0	8.9	-27.2	24.4
Stage 2 (N = 56)	-1.7	8.2	-5.4; 2.0	-38.8	77.8	-42.4	39.0
BMI ≤ 30 kg/m^2							
Overall (N = 68)	-1.7	4.7	-4.2; 0.8	-29.6	5.7	-31.4	28.0
Stage 1 (N = 67)	-1.7	4.0	-4.0; 0.7	-19.0	4.7	-29.5	26.2
Stage 2 (N = 39)	-1.8	9.2	-6.4; 2.7	-38.8	72.6	-45.2	41.5
BMI > 30 kg/m^2							
Overall (N = 34)	-1.0	3.0	-4.2; 2.1	-13.2	2.4	-29.3	27.2
Stage 1 (N = 34)	-1.0	2.6	-3.8; 1.9	-12.6	2.1	-26.8	24.9
Stage 2 (N = 16)	-1.6	6.0	-8.5; 5.3	-17.4	77.8	-47.4	44.1

Accuracy is presented as beats per minute (bpm). Stage refers to stage of labor. Abbreviations: BMI = body mass index, CI = confidence interval, SD = standard deviation, min = minimum, max = maximum.

Sensitivity analysis using bootstrapping to illustrate the relative accuracy showed similar results (data not shown separately). Figure 3 shows bland-Altman plots for this analysis for both first and second stage of labor.

Figure 3. Bland-Altman plot including limits of agreement (LoA) of FHR difference between NI-fECG and FSE for all subjects for stage 1 of labor (left) and for stage 2 of labor (right), using bootstrapping.

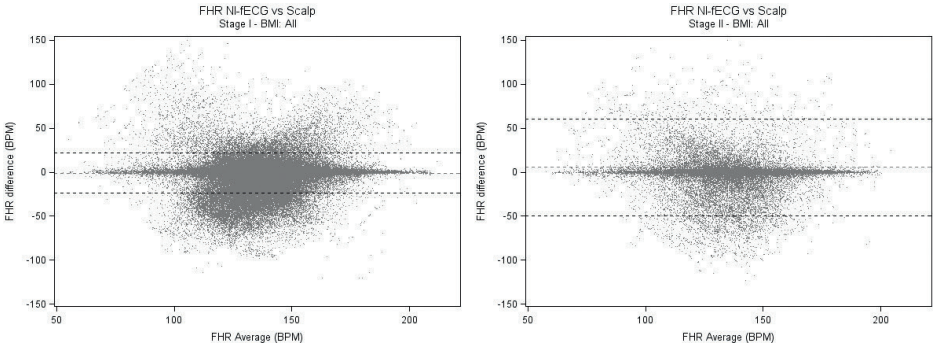

Overall reliability (N = 103) of the NI-fECG device compared to the FSE is 86.8% ± 16.3%, 95% CI [84.17, 89.50]. For the first stage of labor only (N = 102), reliability is slightly higher (88.4% ± 14.6%, 95% CI [86.04, 90.83]). Reliability in the second stage of labor (N = 56) was 68.5% ± 24.5%, 95% CI [62.93, 74.08].

When the different BMI classes were analyzed separately, we found a slightly higher reliability for the higher BMI group (table 3).

Table 3. Reliability of FHR measurements by NI-fECG , according to BMI.

	Mean (± SD)	**95% CI**
BMI ≤ 30 kg/m²		
Overall (N = 68)	85.9 ± 17.7	82.33, 89.5
Stage 1 (N = 67)	87.8 ± 15.5	84.67, 91.0
Stage 2 (N=38)	68.7 ± 25.7	61.70, 75.8
BMI > 30 kg/m²		
Overall (N = 34)	89.1 ± 13.0	85.3, 92.9
Stage 1 (N = 34)	90.1 ± 12.7	86.4, 93.7
Stage 2 (N = 15)	67.8 ± 22.8	57.4, 78.2

Reliability is presented as percentages. Data provided are means ± standard deviation (SD). Stage refers to stage of labor. Abbreviations: BMI = body mass index, CI = confidence interval.

Table 4 shows success rate of all three monitoring techniques used in our study. FSE has the highest success rate with 97.7%. NI-fECG has a higher overall success rate compared to DU. When first and second stage of labor were analyzed separately, success rate of NI-fECG in the first stage of labor is higher than DU, whereas the success rates during

second stage of labor are similar. In the higher BMI class (>30 kg/m^2) success rates of NI-fECG are higher compared to DU (table 4).

Table 4. Success rates of all three monitoring modalities.

	NI-fECG	FSE	DU
All patients			
Overall			
No. patients	118	105	48
Mean (±SD)	89.5[ab] (± 10.8)	97.8 (± 3.3)	82.8[c] (± 23.1)
[95% CI]	[87.9, 91.1]	[97.2, 98.3]	[77.3, 88.4]
Stage 1			
No. patients	118	104	39
Mean (±SD)	91.3[a] (± 9.9)	98.6 (± 3.2)	88.1[c] (± 16.2)
[95% CI]	[89.8, 92.8]	[98.1, 99.1]	[83.7, 92.4]
Stage 2			
No. patients	63	65	12
Mean (±SD)	63.3[a] (± 21.7)	89.3 (± 17.6)	64.6[c] (± 32.2)
[95% CI]	[58.7, 67.8]	[85.7, 93.0]	[47.9, 81.3]
BMI ≤ 30 kg/m^2			
Overall			
No. patients	80	70	32
Mean (±SD)	88.9[ab] (± 11.4)	97.9 (± 2.9)	84.1[c] (± 23.9)
[95% CI]	[86.8, 91.1]	[97.3, 98.5]	[77.90 91.3]
Stage 1			
No. patients	80	69	26
Mean (±SD)	90.7[a] (± 10.7)	98.6 (± 2.4)	89.0[c] (± 18.2)
[95% CI]	[88.7, 92.7]	[98.2, 99.1]	[82.9, 95.1]
Stage 2			
No. patients	44	46	9
Mean (±SD)	62.2[a] (± 21.8)	91.7 (± 13.0)	67.9[c] (± 31.1)
[95% CI]	[56.6, 67.7]	[88.5, 94.9]	[48.6, 87.2]
BMI > 30 kg/m^2			
Overall			
No. patients	37	34	15
Mean (±SD)	91.0[a] (± 9.5)	97.7 (± 3.6)	79.2[c] (± 22.3)
[95% CI]	[88.3, 93.6]	[96.7, 98.8]	[69.1, 89.4]
Stage 1			
No. patients	37	34	12
Mean (±SD)	92.6[a] (± 8.1)	99.2 (± 1.3)	85.3[c] (± 11.7)
[95% CI]	[90.4, 94.9]	[98.8, 99.6]	[79.3, 91.4]
Stage 2			
No. patients	18	18	3
Mean (±SD)	66.4[a] (± 22.4)	82.7 (± 25.4)	54.8 (± 40.2)
[95% CI]	[57.2, 75.6]	[72.2, 93.1]	[-13.1, 122.6]

Success rate is presented as percentages. Data provided are means ± standard deviation (SD). Stage refers to stage of labor. To test for significant differences between the monitoring modalities, post-hoc non-parametric test on ranks was performed with adjustment for multiple comparison using Tukey-Kramer. [a] *p<0.05, NI-fECG vs FSE,* [b] *p<0.05 NI-fECG vs DOPPLER,* [c] *p<0.05 Doppler vs FSE. Abbreviations: NI-fECG = non-invasive fetal electrocardiography, FSE = fetal scalp electrode, DU = doppler ultrasound, BMI = body mass index, CI = confidence interval.*

Maternal heart rate

For MHR monitoring 118 patients were monitored using NI-fECG, with an average monitoring duration of 258.8 minutes. For 83 patients paired data of NI-fECG and conventional MHR monitoring were available, with an average paired monitoring duration of 227.8 minutes.

Overall accuracy of NI-fECG for MHR is 0.54 bpm (SD 1.30, 95% CI [-0.67; 6.50]) compared to conventional MHR monitoring. Separate analysis based on separate labor stages and BMI classes showed similar results.

Overall reliability (N= 80) of the NI-fECG as compared to conventional monitoring is 95.33% ± 10.09%, 95% CI [93.45, 97.21]. For the first stage of labor alone (N = 79), reliability remains equal (95.76% ± 10.32%, 95% CI [93.82, 97.69]). For the 35 patients from whom results from second stage of labor were available, reliability was 89.87% ± 10.55%, 95% CI [86.86, 92.89].

When the different BMI classes were analyzed, we found similar results for reliability percentages in both groups (data not shown).

Overall success rate for MHR monitoring by NI-fECG was higher than conventional monitoring techniques, approaching 100% for all stages of labor as well as for analysis according to BMI class

Uterine activity

We included 10 women who received an IUPC during labor. Unfortunately, skin impedance was too high in 8 of these measurements, making it impossible to extract EHG signals. In the remaining 2 inclusions, EHG registration was sufficient for comparison with the IUPC. In both patients, the recording from both the EHG and the IUPC agree well (Figure 4).

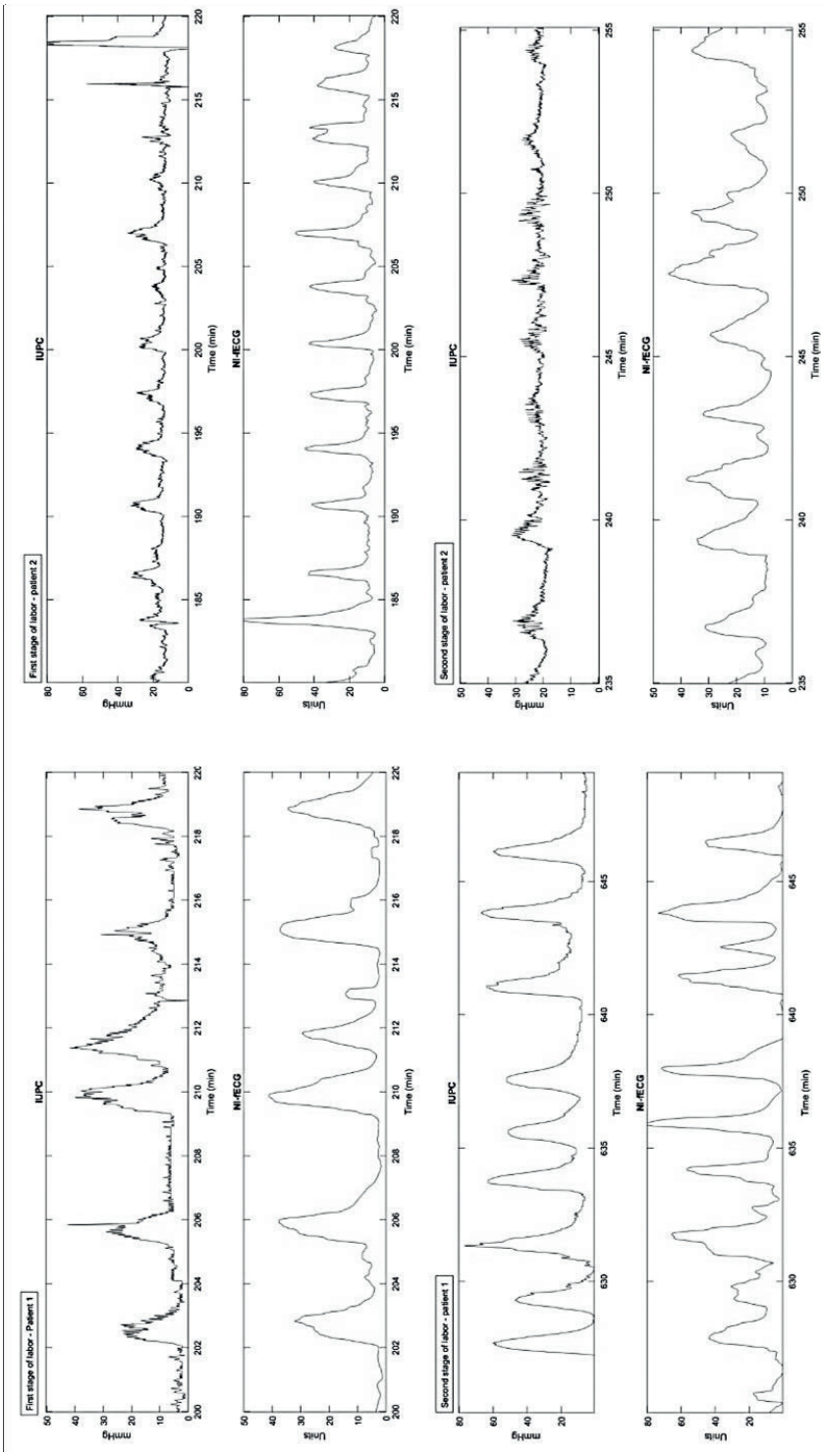

Figure 4. Simultaneously registered contractions with both the intra-uterine pressure catheter (IUPC) and electrohysterogram (EHG) during first (top figure) and second stage (bottom figure) of labor of both patients

Discussion

Main Findings

To validate this technology for intrapartum fetomaternal monitoring, we compared its performance measures to both the gold standard (FSE) and DU performance measures from the literature.[2,3] This study shows that NI-fECG has generally more accurate and reliable FHR tracings compared to DU. Furthermore, performance measures of NI-fECG are not influenced by maternal BMI.

Interpretation of the results in light of other evidence

We found a higher accuracy for NI-fECG (1.46 bpm) compared to that of DU as reported in literature (10.6 bpm – 14.3 bpm) and therefore NI-fECG provides more correct FHR information for all stages of labor.[2,3] Moreover, our overall accuracy lies within our prespecified limit of 3.5 bpm since the 95% CI does not exceed this limit. Furthermore, NI-fECG appears to be a more reliable technology (88.4% ± 14.6%) than DU (62.4% – 73.0%) during first stage of labor.[2,3] However, during second stage reliability of NI-fECG decreases to 68.74%, but remains higher compared to values previously reported for DU (61.7% and 64.5%).[2,3] The decrease in reliability may be explained by that the two outer electrodes are pinched during the pushing phase of the delivery, when women draw their legs toward their chest, causing disturbances in the electrophysiological signals. Placing those two electrodes higher and closer to the midline of the abdomen may reduce these disturbances.

When comparing different modalities for FHR detection, taking into account that each method averages FHR output throughout different heartbeats, occurrence of measurement errors is inevitable. For this reason, we allowed an error width of 10 bpm from the FSE value with minimal clinical relevance. Other studies used less strict error widths of 10%, therefore allowing a larger absolute margin since basal FHR ranges from 110 to 160 bpm.[16] Overall success rate of the NI-fECG (89.49% ± 10.80%) was also higher than that of DU (82.84% ± 23.09%) in our study. Since the risk of fetal hypoxia is highest during second stage of labor, minimizing signal loss is even more important during this phase. Unfortunately, we found similar success rates for both NI-fECG and DU during second stage. Further identification of the causes of signal loss during second stage and optimization of the NI-fECG technology could aid in raising success rates.

We performed a separate analysis for BMI subgroups, since the decrease in performance in obese patients is one of the major limitations of DU technology with the worldwide increasing incidence of obesity.[4,17] Since the risk of unfavorable perinatal outcomes is higher in obese women, adequate fetomaternal surveillance is even more important.[18–22] Previous studies have shown that in obese women monitoring of UA by EHG is more reliable than by TOCO.[5,8,23] In this study we show that in women with a BMI above 30 also monitoring of FHR by NI-fECG is as accurate and even more reliable

when compared to DU.[24] We therefore conclude that the NI-fECG technology is not affected by maternal BMI and could be superior to DU for FHR and UA monitoring in this high-risk population.

Intrapartum monitoring using DU is also susceptible to maternal-fetal HR confusion.[25,26] When left undetected, deterioration of the fetal status can occur and lead to adverse fetal outcome. Simultaneous registration of both the FHR and MHR by one device allows for early detection of maternal-fetal HR confusion. ECG is the gold standard for MHR registration, but requires placement of maternal chest ECG electrodes and equipment, which is undesirable during labor. Finger pulse oximetry is the most common method and easy to use. New CTG monitors also have pulse oximetry technology incorporated in the tocodynamometer, allowing continuous MHR registration without the need for additional equipment. The NI-fECG technology also continuously records MHR. Since detection and subtraction of the maternal ECG is a key element in the NI-fECG algorithm for FHR detection, the NI-fECG provides a simultaneous MHR trace nearly in 100% of cases. Our results show that this built-in MHR recording of the NI-fECG is both accurate and reliable, which is an asset for this wireless method.

Since NI-fECG can be used before membranes have ruptured and without the necessity for cervical dilatation, it may also have applications in antepartum as well as preterm monitoring. Another intrapartum application may be the analysis of fetal ECG waveform changes or fetal heart rate variability, to obtain more specific information on fetal well-being.[27,28] Further research should focus on the applicability of this technology in the abovementioned setting.

Strengths and Limitations

The main strength of our study is that it comprises an international multicenter trial which enlarges the generalizability of our results. Furthermore, we used the gold standard (FSE) for intrapartum monitoring rather than DU as reference method.

A potential weakness of this study relates to the low number of recordings during second stage of labor (n=56). This is caused by patient withdrawal (main reason was showering for pain relieve) or secondary cesarean deliveries. Since the duration of this stage is also shorter, this lower number of observations during this critical part of labor makes results to be more sensitive to potential outliers. This could have influenced the interpretation of our results in a negative manner.

Another limitation relates to the use of the DU performance measures from the literature as comparison which prevented statistical comparison of all three monitoring modalities. Before conducting this study, a pilot study was performed to assess technical and practical difficulties (data not published). This pilot learned that the fixating band of the DU button negatively affects the performance of the wireless patch used in the

current study. Moreover, application of both technologies causes discomfort for the patient. Since two recent studies reported on the performance measures of DU, using a study design similar to ours, we decided to restrict our study design to comparison of the NI-fECG with the FSE.[2,3]

Finally, 80% of our EHG registrations with simultaneous IUPC were not usable for validating the EHG algorithm in the current study due to high skin impedances following incorrect skin preparation. However, visual assessment of the remaining two registrations showed high agreement, both in first and second stage of labor. Previous research has shown that the EHG technology performs better than TOCO during the first stage of labor in non-obese and obese women.[15] Furthermore, the technology is preferred by patients compared to conventional technologies for UA monitoring.[29]

Conclusion

This study shows that monitoring by NI-fECG is not inferior to DU performance measures, when validating this technology to the FSE. We found a higher overall accuracy and higher reliability in the first stage of labor and similar success rates during second stage. Performance measures of the NI-fECG are not influenced by maternal BMI.

References

1. Kawakita T, Reddy UM, Landy HJ, Iqbal SN, Huang C-C, Grantz KL. Neonatal complications associated with use of fetal scalp electrode: a retrospective study. BJOG. 2016 Oct;123(11):1797–803.
2. Euliano TY, Darmanjian S, Nguyen MT, Busowski JD, Euliano N, Gregg AR. Monitoring Fetal Heart Rate during Labor: A Comparison of Three Methods. J Pregnancy. 2017;2017:8529816.
3. Cohen WR, Ommani S, Hassan S, Mirza FG, Solomon M, Brown R, et al. Accuracy and reliability of fetal heart rate monitoring using maternal abdominal surface electrodes. Acta Obstet Gynecol Scand. 2012;91(11):1306–13.
4. Reinhard J, Hayes-Gill BR, Shiermeier S, Hatzmann W, Herrmann E, Heinrich TM, et al. Intrapartum signal quality with external fetal heart rate monitoring: a two way trial of external Doppler CTG ultrasound and the abdominal fetal electrocardiogram. Arch Gynecol Obs. 2012 Nov;286(5):1103–7.
5. Euliano TY, Nguyen MT, Marossero D, Edwards RK. Monitoring contractions in obese parturients: electrohysterography compared with traditional monitoring. Obstet Gynecol. 2007 May;109(5):1136–40.
6. Schuit E, Amer-Wahlin I, Ojala K, Vayssière C, Westerhuis MEMH, Maršál K, et al. Effectiveness of electronic fetal monitoring with additional ST analysis in vertex singleton pregnancies at >36 weeks of gestation: An individual participant data metaanalysis. Am J Obstet Gynecol. 2013;208(3):1–13.
7. Belfort MA, Saade GR, Thom E, Blackwell SC, Reddy UM, Thorp JMJ, et al. A Randomized Trial of Intrapartum Fetal ECG ST-Segment Analysis. N Engl J Med. 2015 Aug;373(7):632–41.
8. Vlemminx MWC, Thijssen KMJ, Bajlekov GI, Dieleman JP, Van Der Hout-Van Der Jagt MB, Oei SG. Could electrohysterography be the solution for external uterine monitoring in obese women? J Perinatol. 2018 May;38(5):580–6.
9. Hayes-Gill B, Hassan S, Mirza FG, Ommani S, Himsworth J, Solomon M, et al. Accuracy and Reliability of Uterine Contraction Identification Using Abdominal Surface Electrodes. Clin Med Insights Women's Heal. 2012;5:CMWH.S10444.
10. Cunningham F, Leveno K, Bloom S, Hauth J, Gilstrap L, Wenstrom K. Williams Obstetrics. 22nd ed. McGraw-Hill Professional; 2005. 1600 p.
11. Bland JM, Altman DG. Statistical methods for assessing agreement between two methods of clinical measurement. Lancet (London, England). 1986 Feb;1(8476):307–10.
12. Efron B. Bootstrap methods: another look at the jackknife. Ann Stat. 1979;7(1):1–26.
13. Harper LM, Shanks AL, Tuuli MG, Roehl KA, Cahill AG. The risks and benefits of internal monitors in laboring patients. Am J Obstet Gynecol. 2013 Jul;209(1):38.e1-6.
14. Wilmink FA, Wilms FF, Heydanus R, Mol BWJ, Papatsonis DNM. Fetal complications after placement of an intrauterine pressure catheter: a report of two cases and review of the literature. J Matern Fetal Neonatal Med. 2008 Dec;21(12):880–3.

15. Vlemminx MWC, Thijssen KMJ, Bajlekov GI, Dieleman JP, Van Der Hout-Van Der Jagt MB, Oei SG. Electrohysterography for uterine monitoring during term labour compared to external tocodynamometry and intra-uterine pressure catheter. Eur J Obstet Gynecol Reprod Biol. 2017 Aug;215:197–205.
16. Santo S, Ayres-de-campos D, Costa-santos C, Schnettler W, Ugwumadu A, Grac ISMDA. Agreement and accuracy using the FIGO , ACOG and NICE cardiotocography interpretation guidelines. 2017;96:166–75.
17. WHO. Obesity and overweight [Internet]. 2018 [cited 2018 Nov 1]. Available from: http://www.who.int/en/news-room/fact-sheets/detail/obesity-and-overweight
18. Scott-Pillai R, Spence D, Cardwell CR, Hunter A, Holmes VA. The impact of body mass index on maternal and neonatal outcomes: a retrospective study in a UK obstetric population, 2004-2011. BJOG. 2013 Jul;120(8):932–9.
19. Magann EF, Doherty DA, Chauhan SP, Klimpel JM, Huff SD, Morrison JC. Pregnancy, obesity, gestational weight gain, and parity as predictors of peripartum complications. Arch Gynecol Obstet. 2011 Oct;284(4):827–36.
20. Kabiru W, Raynor BD. Obstetric outcomes associated with increase in BMI category during pregnancy. Am J Obstet Gynecol. 2004 Sep;191(3):928–32.
21. Sebire NJ, Jolly M, Harris JP, Wadsworth J, Joffe M, Beard RW, et al. Maternal obesity and pregnancy outcome: a study of 287,213 pregnancies in London. Int J Obes Relat Metab Disord. 2001 Aug;25(8):1175–82.
22. Carlhall S, Kallen K, Blomberg M. Maternal body mass index and duration of labor. Eur J Obstet Gynecol Reprod Biol. 2013 Nov;171(1):49–53.
23. Euliano TY, Nguyen MT, Darmanjian S, McGorray SP, Euliano N, Onkala A, et al. Monitoring uterine activity during labor: a comparison of 3 methods. Am J Obstet Gynecol. 2013 Jan;208(1):66.e1-6.
24. Cohen WR, Hayes-Gill B. Influence of maternal body mass index on accuracy and reliability of external fetal monitoring techniques. Acta Obstet Gynecol Scand. 2014 Jun;93(6):590–5.
25. Reinhard J, Hayes-Gill BR, Schiermeier S, Hatzmann H, Heinrich TM, Louwen F. Intrapartum heart rate ambiguity: a comparison of cardiotocogram and abdominal fetal electrocardiogram with maternal electrocardiogram. Gynecol Obstet Invest. 2013;75(2):101–8.
26. Stampalija T, Signaroldi M, Mastroianni C, Rosti E, Signorelli V, Casati D, et al. Fetal and maternal heart rate confusion during intra-partum monitoring: comparison of trans-abdominal fetal electrocardiogram and Doppler telemetry. J Matern Neonatal Med. 2012;25(8):1517–20.
27. Westerhuis MEMH, Visser GHA, Moons KGM, van Beek E, Benders MJ, Bijvoet SM, et al. Cardiotocography plus ST analysis of fetal electrocardiogram compared with cardiotocography only for intrapartum monitoring: a randomized controlled trial. Obstet Gynecol. 2010 Jun;115(6):1173–80.
28. Van Laar J, Peters CHL, Vullings R, Houterman S, Bergmans JWM, Oei SG. Fetal autonomic response to severe acidaemia during labour. BJOG An Int J Obstet Gynaecol. 2010;117(4):429–37.

29. Thijssen KMJ, Vlemminx MWC, Westerhuis MEMH, Dieleman JP, Van der Hout-Van der Jagt MB, Oei SG. Uterine Monitoring Techniques from Patients' and Users' Perspectives. AJP Rep. 2018 Jul;8(3):e184–91.

CHAPTER 8

User evaluation of realtime CTG home monitoring; a pilot study

Carlijn Lempersz, M. Beatrijs van der Hout-van der Jagt, Nicole Manders, Nicole Backx, Judith O.E.H. van Laar, S. Guid Oei

Accepted for publication. Available online. European Journal of Obstetrics & Gynecology and Reproductive Biology, 2021, https://doi.org/10.1016/j.ejogrb.2021.01.029.

Dear Editor, we found that pregnant women and independent midwifes are positive regarding CTG home monitoring.

In the Netherlands maternity care is primarily provided by independent midwives. In 2016 86.8% of all pregnant women started care under supervision of an independent primary care midwife.[1] Yet, about 80% of all pregnant women consult with multiple care professionals from primary care and secondary care during pregnancy. [2]

In many cases when pregnant women consult their midwife, it is desirable to make an additional cardiotocogram (CTG). Currently, a consultation at an obstetric ward is often needed to conduct a CTG. Different studies show that home monitoring can help in reducing costs and burden for the pregnant woman. [3,4] Generally, CTG home monitoring is not standard of care, and if available it is often a monitoring system without realtime remote CTG monitoring, which is required to detect fetal distress or bad signal quality instantaneously. However, most CTG systems use Doppler ultrasound and an external tocodynamometer. As both probes are very sensitive to motion and (fetal) position, they need careful placement on the abdomen of the mother for a reliable registration, and due to signal loss they often need readjustment by an experienced user during the measurement.

Recently, an electrophysiologic system is developed that makes realtime CTG home monitoring possible. This system measures the fetal electrocardiogram (NI-fECG) non-invasively by using an electrode patch that is placed on the maternal abdomen. By doing so, an electrophysiologic CTG is retrieved. The electrode patch is potentially less susceptible for movement of the mother and fetus and is designed such that there is likely no need for readjustment after the patch is placed on the maternal abdomen. A pilot study was conducted to evaluate user experience of the current NI-fECG system of both the independent midwives and pregnant women, and also to evaluate how they feel about CTG home monitoring. Twenty pregnant women of two different midwifery practices participated in the pilot. Ten measurements were in a home setting and ten at the midwifery practice.

After the measurement, the participants and midwives were asked to fill out a questionnaire about their experience regarding the user friendliness of the device and how they feel about home monitoring. The questionnaires consisted of questions that could be answered on a Likert's scale from 1 to 5, with option for additional remarks per question. From the 20 participants, 19 filled out a complete questionnaire. Table 1 shows the results of the questionnaires of the pregnant women and midwifes.

This pilot shows that, with this new device, it is possible to retrieve a CTG registration in a home setting that can be evaluated real-time remotely. This new monitoring system may be a solution in places where distances are large and daily monitoring is required.

This is also suggested from the answers in the questionnaires, as none of the women preferred to go to the hospital for CTG monitoring, and 50% of the women is even willing to pay for being monitored at home. Other advantages are that home monitoring could contribute to reducing healthcare costs, as women who otherwise need to be hospitalized for daily monitoring only, could now be monitored at home.

To conclude, the pilot data show that pregnant women and independent midwifes are positive regarding CTG home monitoring. Before implementing home monitoring, a healthcare evaluation study is needed to evaluate the effect of the intervention on the quality and costs of maternity care.

Table 1. Results questionnaire pregnant women

Subject	**Results in mean**	**Graduation-scale**
Pregnant women		
Overall experience	1,4	1=not bothersome at all, 5= very bothersome
Experience skin preparation	2,4	1=not bothersome at all, 5= very bothersome
Experience placement of the electrode patch	1,4	1=not bothersome at all, 5= very bothersome
Experience inconvenience from electrode patch on abdomen	1,6	1= no inconvenience at all, 5= a lot of inconvenience
Experience duration of measurement	2,9	1=way to short, 5= way to long
Experience regarding restriction to move	2,7	1=not restricted at all, 5= very restricted
Wish to be monitored with this device if CTG monitoring is needed	1,3	1=very willing, 5= absolutely not
Midwifes		
Experience skin preperation	1	1=very easy, 5= very difficult
Experience placement of the electrode patch	1,1	1=very easy, 5= very difficult
Experience adhesiveness of the electrode patch	1,8	1= very well, 5= very bad
Experience connecting patch to hardware	1,2	1=very easy, 5= very difficult
Experience quality of instructions	1,3	1= very clear, 5= not clear at all
Suitability of system for home monitoring	1,2	1= very suitable, 5= not suitable at all
Suitability of system for home delivery	1,4	1= very suitable, 5= not suitable at all
Communication with research supervisor	1,6	1=very easy, 5= very difficult

References

1. Perined. Perinatale Zorg in Nederland 2016. Utrecht; 2018.
2. Stuurgroep Zwangerschap en Geboorte. Een goed begin. Veilige zorg rond zwangerschap en geboorte. [Internet]. Utrecht; 2009. Available from: https://www.rijksoverheid.nl/documenten/kamerstukken/2009/12/30/een-goed-begin-veilige-zorg-rond-zwangerschap-en-geboorte
3. Truijens SEM, Pommer AM, Van Runnard Heimel PJ, Verhoeven CJM, Oei SG, Pop VJM. Development of the Pregnancy and Childbirth Questionnaire (PCQ): Evaluating quality of care as perceived by women who recently gave birth. Eur J Obstet Gynecol Reprod Biol. 2014;174(1):35–40.
4. Buysse H, Moor G De, Maele G Van, Baert E, Thienpont G, Temmerman M. Cost-effectiveness of telemonitoring for high-risk pregnant women. 2007;7:470–6.

CHAPTER 9

General discussion

In this thesis different applications of non-invasive electrophysiologic measurements of the fetus during pregnancy and labor are described. This technique uses electrodes that are non-invasively applied to the abdomen of the mother. In this thesis we describe the use of these measurements in calculating a fetal electrocardiogram (ECG) and creating a cardiotocogram (CTG) during pregnancy and labor.

In this chapter the main findings of the thesis and future perspectives are discussed.

Fetal electrocardiography and congenital heart disease

Congenital heart disease (CHD) is the most common congenital anomaly with a reported prevalence of 8 per 1000 live births. [1–3] Nowadays, a fetal anomaly scan is performed around 20 weeks of gestation to check for different congenital anomalies, amongst others CHD. Research has shown that prenatal detection of CHD lowers the fetal mortality and morbidity. Timely diagnosis gives the parents and caregivers time to prepare for the arrival of a child that needs special care. Furthermore, with severe CHD parents have the possibility to opt for termination of pregnancy.[4–9]

After the introduction of standardized screening programs, the prenatal detection rates in low risk populations for CHD increased to 40-60%.[10] In tertiary care centers detection rates can even rise to 89%. [11] But only 10% of the children born with CHD are born from mothers with high risk factors and receive standard care in tertiary care hospitals. [12] Many cases of severe CHD therefore remain undetected and methods to improve detection rates during standard prenatal screening would be highly appreciated.

This thesis describes the potential added value of the fetal electrocardiogram (ECG) for screening for CHD. In chapter 2 the study protocol towards demonstrating this added value is presented.[13] This study is a prospective case-control study that included a cohort of 328 healthy fetuses and 148 fetuses with a known congenital heart disease around mid-pregnancy. This study gives the opportunity to identify the characteristics of the ECG of a healthy fetus and to compare those results with ECG's from fetuses with a known CHD.

Noben et al. describe the potential of the fetal ECG in the prenatal diagnosis of arrhythmias in a case report.[14] In the thesis of L. Noben this subject will be further discussed. [15]

The calculation of a fetal ECG with sufficient quality to assess the presence of CHD is challenging. Because the fetus is able to move freely underneath the transabdominal electrodes, inter- and intra-fetal comparison is difficult. Every time the fetus moves, the orientation with respect to the electrodes will change. A method that standardizes the fetal orientation makes it possible to compare different fetal ECG's of the same fetus, but also to compare fetal ECG's of different fetuses. In Chapter 3 the standardization

process to calculate a fetal ECG from the electrophysiologic measurements, correcting for fetal orientation is described.[16] The results show a great improvement in signal quality which makes fetal electrocardiography a promising candidate for CHD detection in clinical practice. In this manuscript the fetal ECG complex of the included healthy fetuses is shown. Furthermore, two cases of CHD are described, including their fetal ECG complex to illustrate the potential of the fetal ECG for CHD detection.

Chapter 4 and 5 are a continuation of chapter 3. The standardization method allows for the analysis of different fetal ECG characteristics that may indicate a possible CHD. The electrical heart axis may be one of these characteristics. The electrical heart axis represents the main direction of the electrical activity of the heart during one cardiac cycle and gives information about the muscle distribution of the heart. Due to anatomical changes in CHD the workload may change and the muscle distribution of the heart may alter. The electrical heart axis could thus be a potential indicator for CHD in mid-pregnancy. We hypothesize that due to anatomical changes in CHD, some CHD might show a shift in the electrical heart axis. Up to our knowledge there are no reference values for the electrical heart axis of the fetus in mid-pregnancy. In chapter 4 we aim to define reference values for the electrical heart axis in mid-pregnancy. A total of 328 fetuses were included and 286 measurements were of sufficient quality for further analysis. We found a mean electrical heart axis (MEHA) of 122.68° (90% PI: -25.6°; 270.9°). Our results confirm earlier findings that the electrical heart axis of the fetus is oriented to the right, but it also shows that the range of possible axes in healthy fetuses is wide, making the electrical heart axis alone less suitable as screening method. The electrical heart axis, however, may be part of a multifactor prediction model in the future. In chapter 5 we describe the electrical heart axis of fetuses with a known CHD. A total of 148 fetuses are included. Three different subgroups for analyses are defined. The subgroups are conotruncal anomalies (CTA), hypoplastic right heart syndrome (HRHS) and atrioventriculair septum defects (AVSD). CTA are responsible for a significant part of all CHD and are more easily missed on the fetal anomaly scan as the four-chamber view may appear normal. Some fetuses with undiagnosed CTA, for example a transposition of the great arteries, develop acute hypoxia in the first days postpartum when the arterial duct closes. A large part of the CTA subgroup constitutes fetuses with tetralogy of Fallot and transposition of the great arteries. In these anomalies right ventricle hypertrophy is common so we expect the fetal ECG to show a right oriented electrical heart axis. Taking into account the anatomy of the heart in fetuses with AVSD and HRHS, it is to be expected that these will show a left-oriented electrical heart axis.

Overall, we found a MEHA of 83.0° (95% CI: 6.7°; 159.3°) in the fetuses with known CHD. This is not significantly different from the electrical heart axis of the healthy cohort. Analysis of the three subgroups show a MEHA in the frontal plane which is left-oriented in fetuses with an atrioventricular septal defect (-27.4°) or a hypoplastic right heart syndrome (HRHS) (26.0°), which significantly differs from the electrical

heart axis of the healthy cohort. The MEHA in the frontal plane of the group of fetuses with conotruncal anomalies (105.6°) does not significantly differ from that of the healthy cohort (122.78°).

These results show that the electrical heart axis alone cannot conclusively separate healthy fetuses from fetuses with a CHD. However, the left-oriented MEHA in the AVSD and HRHS subgroups do significantly differ from the healthy cohort and further supports the hypothesis that the electrical conduction system is influenced by the cardiac anatomy.

Non-invasive fetal electrophysiologic measurements for fetal monitoring

In general, there are two techniques that are used to acquire a fetal heart rate (FHR) for CTG monitoring; Doppler Ultrasound (DU) and the fetal scalp electrode (FSE). Doppler Ultrasound is a non-invasive technique that uses a transducer placed on the maternal abdomen, held in place with an elastic band. An advantage of the DU is that it is a non-invasive method that can be used before membranes have ruptured. A major disadvantage is its sensitivity to signal loss with reported percentages ranging from 5.2% up to 40%. [17–19] The signal loss can partially be explained by fetal and maternal movements, a high BMI of the mother and irregularities in FHR (i.e. decelerations, extrasystolic beats, and other cardiac arrythmias). [18–21] Furthermore, the method of attaching the DU device to the maternal abdomen with an elastic belt can be experienced as uncomfortable by the pregnant woman. [22] The FSE is a more reliable method and is considered the gold standard. Unfortunately, it is an invasive method that uses an electrode that is screwed on the fetal head and comes with an increased risk for complications, i.e. trauma and infection. [23,24] Furthermore, a FSE can only be applied when membranes are ruptured and with sufficient dilation.

CTG monitoring during labor and delivery was introduced in the early 1970's to identify fetuses with hypoxia and reduce neonatal morbidity and mortality. Overall, the specificity of CTG monitoring is poor, and the neonatal outcome has not improved after the introduction of the CTG. [25] Multiple techniques have been added to increase the detection rate of fetal hypoxia (e.g. fetal blood sampling (FBS) and ST waveform analysis (STAN)). However, previous studies have demonstrated that these methods do not significantly decrease neonatal morbidity and mortality. [26–32]

Monitoring multiple pregnancies is another challenge in fetal monitoring. The FSE can only be placed on the first child, the other fetus(es) is/are currently monitored with DU. To be able to monitor all fetuses with one device would be an advantage. L. Noben et al. describe the feasibility to monitor a twin pregnancy with the NI-fECG device, this is further discussed in her thesis. [15,33]

In this thesis we hypothesize that the NI-fECG has lower signal loss during labor and delivery. Moreover, additional parameters that can be derived from the NI-fECG may increase the specificity to identify fetuses in distress.

In Chapter 6 a review of the literature is presented regarding the use of the non-invasive fetal ECG for monitoring fetuses during labor and delivery.[34] Our primary outcome measures are success rate, accuracy, reliability and confusion rate of the NI-fECG compared to DU and/or FSE. Success rate is defined as the percentage of time the investigational product provides an output. Reliability is defined as the percentage of time the investigational device generates a FHR output within a predetermined range of the FHR output given by the reference method. Accuracy is defined as the difference in FHR output from the investigational device compared to the reference method. Confusion rate is defined as the percentage of time the investigational device confused MHR for FHR. Eight articles are included. Despite differences in methodology and type of NI-fECG devices, all included studies in this review demonstrate that it is possible to apply NI-fECG during labor. Compared to DU, NI-fECG performs equally well or better in most studies. Even during the second stage of labor, when a decrease in performance is noticed in most reports, it is shown that NI-fECG still performs equally well or better compared to DU. Studies that compare NI-fECG and DU with FSE showed that DU and NI-fECG have comparable success rates. However, compared to DU, accuracy and reliability of NI-fECG is higher and confusion rate is lower. Both techniques show output that may give unreliable information that could potentially lead to wrong medical decisions. For this reason it is up for debate if it is preferred to have the device to show no output over unreliable output.

In chapter 7 we aimed to validate a NI-fECG device as a non-inferior method to DU for fetomaternal monitoring during labor and delivery.[35] We compare the performance measures of the NI-fECG with the gold standard (FSE) and we compare DU performance measures described in the literature with the gold standard FSE. In this international study 125 term pregnant women were included and simultaneously monitored by the NI-fECG device as well as DU which is replaced by FSE when membranes had ruptured. The results show that NI-fECG is more accurate and reliable compared to DU. Although during the second stage of labor the reliability of the NI-fECG decreases, it remains higher compared to the reported reliability for DU. The decrease in performance during the second stage of labor may be explained by the activation of the abdominal muscles during the active phase of labor, where the woman pulls her legs towards the chest and starts to push, causing large disturbances in the electrophysiological signals. A solution might be to place those two electrodes lower and closer to the midline. The overall success rate of the NI-fECG was higher than that of DU. During the second stage of labor we found similar success rates for NI-fECG and DU. Since the risk of fetal hypoxia is highest during the second stage of labor, minimizing signal loss during this phase is essential. Furthermore, performance measures of NI-fECG are not influenced by

maternal BMI, whereas performance for DU is significantly decreased. The accuracy of NI-fECG in all stages of labor is higher compared to reported values of DU. Another problem that can occur using DU is maternal-fetal heartrate confusion. The results in chapter 7 show that the built-in maternal heart rate recording of the NI-fECG is both accurate and reliable which prevents (undiscovered) maternal-fetal confusion and therefore is an asset for this method.

CTG monitoring is not only used during labor and delivery, but also during pregnancy to monitor the fetus. In The Netherlands, maternity care is primarily provided by independent midwives. In 2016 86.8% of all pregnant women started care under supervision of an independent primary care midwife. [36] Yet, about 80% of all pregnant women consult with multiple care professionals from primary care and secondary care during pregnancy.[37] Therefore, a good collaboration between the independent primary care midwives and secondary care professionals in hospitals is of great importance, with as few transferals as possible. This positively effects the experience of maternity care by pregnant women. [38]

For many problems for which pregnant women consult their midwife, it is desirable to make a cardiotocogram (CTG). Currently, in most of these situations a consultation at an obstetric ward or outpatient clinic is needed to conduct this CTG. Different studies show that home monitoring can help in reducing costs and burden for the pregnant woman.[39,40] Generally, CTG home monitoring is not standard of care and if available it is often a monitoring system where real-time remote CTG monitoring is not possible. Most systems use DU and an external tocodynamometer. As mentioned earlier, both need careful placement on the abdomen of the mother for a reliable registration and due to signal loss they often need readjustment by an experienced user during the measurement. Furthermore, real-time assessment of the CTG is required to detect fetal distress or bad signal quality.

In chapter 8 a pilot study regarding home monitoring using the NI-fECG device is described. This study is used to evaluate user experience of the NI-fECG system by both the independent midwives and pregnant women. As the NI-fECG is a product in development, this pilot is also developed to evaluate whether the existing device meets the requirements for home monitoring and if not, which adjustments need to be made before this device will get its definite form and will be used in a larger research setting. The results of this pilot show that both midwives and pregnant women are positive about home monitoring. None of the pregnant women prefer to go to the hospital for a checkup with a CTG. Also, all participants are positive about the user friendliness of the device and its comfort. Before implementing home monitoring, a healthcare evaluation study is needed to evaluate the effect of the intervention on the quality and cost effectiveness of maternity care.

Clinical implications and future directions

The results from the research in this thesis show promising applications of electrophysiologic measurements of the fetus during pregnancy and labor.

This technique is not new and first measurements were taken over 100 years ago, but it took many decades before all difficulties were overcome and good quality signals could be obtained. [41] In this thesis the development of this non-invasive technique is shown with higher success rates in obtaining signals of sufficient quality for analysis. In chapters 2-5 the application of the fetal ECG retrieved from the electrophysiologic measurements in mid-pregnancy is described. Chapters 6-8 focus on retrieving a CTG from the electrophysiologic measurements in the third trimester of pregnancy and during labor and delivery.

As with many techniques, this technique has advantages but also some limitations that need to be overcome. For the use of NI-fECG for fetal electrocardiography and detection of congenital heart disease, signal quality has been a major point of concern in calculating a non-invasive fetal ECG. Before this technique can be of value in daily clinical practice, signal quality needs to be increased. In this thesis it is shown that we succeeded to enhance signal quality significantly for this technique. However, to enhance signal quality, averaging over 30 heartbeats is necessary. The gain in signal quality has a downside; the loss of inter-beat variability in the fetal ECG. For potential diagnosis of structural anomalies of the heart it has no or little consequences, since the anomaly will affect each heartbeat in more or less the same manner. But for screening and diagnosis of arrhythmias it is crucial to have a beat-to-beat fetal ECG, because every beat may show different ECG characteristics. Future research should focus on further developing the fetal ECG in such a manner that averaging over multiple heartbeats is no longer necessary. First steps to overcome the need for averaging by using artificial intelligence have recently be published by Fotiadou et al. [42,43] With no need for averaging the fetal ECG will be a more complete technique that can be used in clinical practice.

Another limitation is that the calculation of the 12-lead ECG from the VCG via the Dower matrix is based on assumptions about geometrical and conductive properties of the adult thorax that may not fully apply to the fetal thorax. Interpretation of the fetal ECG should therefore not be based on guidelines used for 12-lead adult ECG. Future research should define normal ranges for the fetal ECG parameters at different gestational ages. In chapter 4 the normal ranges for the electrical heart axis are defined, but normal values of most other ECG characteristics are still unknown.

Currently, the collected data have to be evaluated retrospectively. In clinical practice where prompt decisions need to be made, real-time evaluation is a must. At present, pseudo-realtime implementations of this technology are being developed to be able to show results with a delay of only a few seconds.

As a CTG device, the fetal ECG technique showed a limitation mostly in the active second stage of labor.[35] This is a crucial part of delivery where fetal distress is most common and where it is preferred to have reliable signal quality. The loss in signal quality may be caused by the abdominal muscle activation during the active phase of labor. Placing the lower two electrodes lower and more towards the midline of the abdomen, seems to give better signal quality. Furthermore, analysis of the data with improved software finds a higher reliability of 85.9% in the second stage of labor, compared to the earlier found 68.5% described in chapter 7. [35,44] This makes that the NI-fECG is a good alternative for DU and due to its non-invasive nature may also be a good alternative for the FSE.

It is known that the CTG has a low specificity for indicating fetuses in distress. Research opportunities may lay in finding additional features of the fetal ECG to better predict fetal distress in a non-invasive manner. New research should focus on the potential ability of this technique to calculate a complete fetal ECG during labor and delivery. Later research should focus on defining what the fetal ECG of a fetus without distress is composed of and compare those with the ECGs of fetuses that did suffer distress during labor and delivery.

References

1. van der Linde D, Konings EEM, Slager MA, Witsenburg M, Helbing WA, Takkenberg JJM, Roos-Hesselink JW. Birth prevalence of congenital heart disease worldwide: a systematic review and meta-analysis. J Am Coll Cardiol. 2011 Nov;58(21):2241–7.
2. Dolk H, Loane M, Garne E. Congenital heart defects in Europe: prevalence and perinatal mortality, 2000 to 2005. Circulation. 2011 Mar;123(8):841–9.
3. Hoffman JIE, Kaplan S, Liberthson RR. Prevalence of congenital heart disease. Am Heart J. 2004 Mar;147(3):425–39.
4. Verdurmen KMJ, Lempersz C, Eijsvoogel NB, Vullings R, Schroer C, van Laar JOEH, Oei SG. A systematic review of prenatal screening for congenital heart disease by fetal electrocardiography. Int J Gynecol Obstet. 2016;135(2):129–34.
5. Mäkikallio K, McElhinney DB, Levine JC, Marx GR, Colan SD, Marshall AC, Lock JE, Marcus EN, Tworetzky W. Fetal aortic valve stenosis and the evolution of hypoplastic left heart syndrome: patient selection for fetal intervention. Circulation. 2006 Mar;113(11):1401–5.
6. Franklin O, Burch M, Manning N, Sleeman K, Gould S, Archer N, Radcliffe J, Way H. Prenatal diagnosis of coarctation of the aorta improves survival and reduces morbidity. 2002;67–70.
7. Mahle WT, Clancy RR, Mcgaurn SP, Goin JE, Clark BJ, Background A. Impact of Prenatal Diagnosis on Survival and Early Neurologic Morbidity in Neonates With the Hypoplastic Left Heart Syndrome. 2018;107(6).
8. Kaguelidou F, Fermont L, Boudjemline Y, Le Bidois J, Batisse A, Bonnet D. Foetal echocardiographic assessment of tetralogy of Fallot and post-natal outcome. Eur Heart J. 2008 Jun;29(11):1432–8.
9. Bonnet D, Coltri A, Butera G, Fermont L, Le Bidois J, Kachaner J, Sidi D. Detection of transposition of the great arteries in fetuses reduces neonatal morbidity and mortality. Circulation. 1999 Feb;99(7):916–8.
10. van Velzen CL, Clur SA, Rijlaarsdam MEB, Bax CJ, Pajkrt E, Heymans MW, Bekker MN, Hruda J, de Groot CJM, Blom NA, Haak MC. Prenatal detection of congenital heart disease--results of a national screening programme. BJOG. 2016 Feb;123(3):400–7.
11. Adriaanse BME, van Vugt JMG, Haak MC. Three- and four-dimensional ultrasound in fetal echocardiography: an up-to-date overview. J Perinatol. 2016 Sep;36(9):685–93.
12. Sharland G. Fetal cardiac screening and variation in prenatal detection rates of congenital heart disease: why bother with screening at all? Future Cardiol. 2012 Mar;8(2):189–202.
13. Verdurmen K, Lempersz C, Vullings R, Schroer C, Delhaas T, van Laar JOEH, Oei SG. Normal ranges for fetal electrocardiogram values for the healthy fetus of 18-24 weeks of gestation: a prospective cohort study. BMC Pregnancy Childbirth. 2016 Aug;16(1):227.
14. Noben L, Clur S-A, van Laar JO, Vullings R. Prenatal diagnosis of a bundle branch block based on the fetal ECG. BMJ Case Rep. 2019 Jul;12(7).

15. Noben L. Diagnostic opportunities of transabdominal fetal electrocardiography.
16. Lempersz C, van Laar JOEH, Clur S-AB, Verdurmen KM, Warmerdam GJ, van der Post J, Blom NA, Delhaas T, Oei SG, Vullings R. The standardized 12-lead fetal electrocardiogram of the healthy fetus in mid-pregnancy: A cross-sectional study. PLoS One. 2020;15(4):e0232606.
17. Bakker PCAM, Colenbrander GJ, Verstraeten AA, Van Geijn HP, P.C.A.M. B, G.J. C, A.A. V. The quality of intrapartum fetal heart rate monitoring. Eur J Obstet Gynecol Reprod Biol [Internet]. 2004 Sep;116(1):22–7. Available from: http://ovidsp.ovid.com/ovidweb.cgi?T=JS&PAGE=reference&D=emed8&NEWS=N&AN=39044489
18. Spencer JAD, Belcher R, Dawes GS. The influence of signal loss on the comparison between computer analyses of the fetal heart rate in labor using pulsed doppler ultrasound (with autocorrelation) and simultaneous scalp electrocardiogram. Eur J Obstet Gynecol. 1987;25(1):29–34.
19. Dawes GS, Visser GHA, Goodman JDS, Levine DH. Numerical analysis of the human fetal heart rate : Modulation by breathing and movement. Am J Obstet Gynecol [Internet]. 1981;140(5):535–44. Available from: http://dx.doi.org/10.1016/0002-9378(81)90230-1
20. Herman P. Analysis of heart rate and beat-to-beat variability : Interval difference index. Am J Obstet Gynecol [Internet]. 1980;138(3):246–52. Available from: http://dx.doi.org/10.1016/0002-9378(80)90242-2
21. Cohen WR, Hayes-Gill B. Influence of maternal body mass index on accuracy and reliability of external fetal monitoring techniques. Acta Obstet Gynecol Scand. 2014;93(6):590–5.
22. Thijssen KMJ, Vlemminx MWC, Westerhuis MEMH, Dieleman JP, der Hout-Van der Jagt MB, Oei SG. Uterine Monitoring Techniques from Patients' and Users' Perspectives. AJP Rep [Internet]. 2018 Jul;8(3):e191. Available from: https://www.ncbi.nlm.nih.gov/pubmed/30250758
23. Kawakita T, Reddy UM, Landy HJ, Iqbal SN, Huang CC, Grantz KL. Neonatal complications associated with use of fetal scalp electrode: a retrospective study. BJOG An Int J Obstet Gynaecol. 2016;123(11):1797–803.
24. Leatherman J, Parchman ML, Lawler FH. Infection of fetal scalp electrode monitoring sites. Am Fam Physician. 1992 Feb;45(2):579–82.
25. Alfirevic Z, Devane D, Gyte G, Cuthbert A. Continuous cardiotocography (CTG) as a form of electronic fetal monitoring (EFM) for fetal assessment during labor. 2018;
26. Bretscher J, Saling E. pH values in the human fetus during labor. Am J Obstet Gynecol. 1967 Apr;97(7):906–11.
27. van den Berg P, Schmidt S, Gesche J, Saling E. Fetal distress and the condition of the newborn using cardiotocography and fetal blood analysis during labor. Br J Obstet Gynaecol. 1987 Jan;94(1):72–5.
28. Westgate J, Greene K. How well is fetal blood sampling used in clinical practice? Br J Obstet Gynaecol. 1994 Mar;101(3):250–1.

29. Westerhuis MEMH, Visser GHA, Moons KGM, Van Beek E, Benders MJ, Bijvoet SM, Van Dessel HJHM, Drogtrop AP, Van Geijn HP, Graziosi GC, Groenendaal F, Van Lith JMM, Nijhuis JG, Oei SG, Oosterbaan HP, Porath MM, Rijnders RJP, Schuitemaker NWE, Sopacua LM, Van Der Tweel I, Wijnberger LDE, Willekes C, Zuithoff NPA, Mol BWJ, Kwee A. Cardiotocography plus ST analysis of fetal electrocardiogram compared with cardiotocography only for intrapartum monitoring: A randomized controlled trial. Obstet Gynecol. 2010;115(6):1173–80.
30. Saccone G, Schuit E, Amer-Wahlin I, Xodo S, Berghella V. Electrocardiogram ST Analysis During Labor: A Systematic Review and Meta-analysis of Randomized Controlled Trials. Obstet Gynecol. 2016 Jan;127(1):127–35.
31. Belfort MA, Saade GR, Thom E, Blackwell SC, Reddy UM, Thorp JMJ, Tita ATN, Miller RS, Peaceman AM, McKenna DS, Chien EKS, Rouse DJ, Gibbs RS, El-Sayed YY, Sorokin Y, Caritis SN, VanDorsten JP. A Randomized Trial of Intrapartum Fetal ECG ST-Segment Analysis. N Engl J Med. 2015 Aug;373(7):632–41.
32. Blix E, Brurberg KG, Reierth E, Reinar LM, Oian P. ST waveform analysis versus cardiotocography alone for intrapartum fetal monitoring: a systematic review and meta-analysis of randomized trials. Acta Obstet Gynecol Scand. 2016 Jan;95(1):16–27.
33. Noben L, Westerhuis MEMH, van Laar JOEH, Kok RD, Oei SG, Peters CHL, Vullings R. Feasibility of non-invasive Foetal electrocardiography in a twin pregnancy. BMC Pregnancy Childbirth. 2020 Apr;20(1):215.
34. Lempersz C, Noben L, de Vries B, van Laar JOEH, Westerhuis MEMH, Oei SG. The Noninvasive Fetal Electrocardiogram During Labor: A Review of the Literature. Obstet Gynecol Surv. 2020 Jun;75(6):369–80.
35. Lempersz C, Noben L, van Osta G, Wassen MLH, Meershoek BPJ, Bakker P, Jacquemyn Y, Cuerva MJ, Vullings R, Westerhuis MEMH, Oei GS. Intrapartum non-invasive electrophysiological monitoring: A prospective observational study. Acta Obstet Gynecol Scand. 2020 Oct;99(10):1387–95.
36. Perined. Perinatale Zorg in Nederland 2016. Utrecht; 2018.
37. Stuurgroep Zwangerschap en Geboorte. Een goed begin. Veilige zorg rond zwangerschap en geboorte. [Internet]. Utrecht; 2009. Available from: https://www.rijksoverheid.nl/documenten/kamerstukken/2009/12/30/een-goed-begin-veilige-zorg-rond-zwangerschap-en-geboorte
38. Truijens SEM, Pommer AM, Van Runnard Heimel PJ, Verhoeven CJM, Oei SG, Pop VJM. Development of the Pregnancy and Childbirth Questionnaire (PCQ): Evaluating quality of care as perceived by women who recently gave birth. Eur J Obstet Gynecol Reprod Biol. 2014;174(1):35–40.
39. Buysse H, Moor G De, Maele G Van, Baert E, Thienpont G, Temmerman M. Cost-effectiveness of telemonitoring for high-risk pregnant women. 2007;7:470–6.
40. Romano M, Cesarelli M, D'Addio G, Mazzoleni MC, Bifulco P, Ferrara N, Rengo F. Telemedicine fetal phonocardiography surveillance: an italian satisfactory experience. Stud Health Technol Inform. 2010;155:176–81.

41. Cremer M. Über die direkte Ableitung der Aktionsströme des menschlichen Herzens vom Oesophagus und über das Elektrokardiogramm des Fötus. Munchener medizinische Wochenschrift. 1906;53:811–3.
42. Fotiadou E, Vullings R. Multi-Channel Fetal ECG Denoising With Deep Convolutional Neural Networks. Front Pediatr. 2020;8(August):1–13.
43. Fotiadou E, Konopczyński T, Hesser J, Vullings R. End-to-end trained encoder-decoder convolutional neural network for fetal electrocardiogram signal denoising. Physiol Meas. 2020 Feb;41(1):15005.
44. Vullings R, van Laar JOEH. Non-invasive Fetal Electrocardiography for Intrapartum Cardiotocography. Front Pediatr [Internet]. 2020;8:854. Available from: https://www.frontiersin.org/article/10.3389/fped.2020.599049

CHAPTER 10

Summary

Non-invasive electrophysiologic measurements of the fetus during pregnancy and labor.

This thesis entails different applications of electrophysiologic measurements of the fetus during pregnancy and labor to detect threats for the fetus. The device uses electrodes placed on the maternal abdomen. From the electrophysiological signals a fetal electrocardiogram (ECG), the fetal heart rate (FHR), the maternal heart rate (MHR) and uterine contractions (electrohysterography, EHG) can be retrieved. In this work, the use of electrophysiologic measurements on the fetus is studied for three different applications

In Chapter 2-5 the use of the non-invasive fetal ECG for the detection of CHD is described. Detection of CHD is currently done via ultrasound screening at 20 weeks gestation, but unfortunately only 40-60% of all CHD is detected and alternative information for improved screening is needed. The fetal ECG could give such information as it carries information on the propagation of electrical impulses through the heart, which we hypothesize might be affected by CHD. In chapter 2, the study protocol is described. During the study period 328 healthy fetuses and 148 fetuses with CHD were included. Chapter 3 gives the first results for a method to calculate a fetal ECG in mid-pregnancy that is corrected for fetal orientation. There may be different characteristics of the fetal ECG that could aid in the detection of CHD during pregnancy, for example the electrical heart axis. The electrical heart axis represents the main direction of the electrical activity through the heart during one cardiac cycle. We hypothesize that the direction of the electrical heart axis may change in case of CHD. In chapter 4 we determined the normal ranges of the electrical heart axis in healthy fetuses in mid-pregnancy. Our results confirm a right electrical heart axis of a healthy fetus in mid-pregnancy. For the healthy cohort, we found a mean electrical heart axis (MEHA) of 122.68° (90% Prediction Interval (PI): -25.6°; 270.9°). The PI is wide, making the electrical heart axis alone less suitable for screening for CHD. In chapter 5 the results found in chapter 4 were used to compare the electrical heart axis of fetuses with a known CHD. Here we found a MEHA of 83.0° (95% CI: 6.7°; 159.3°) in the fetuses with known CHD, which is not significantly different from the healthy cohort. Analysis of the subgroups of fetuses with an atrioventricular septal defect or hypoplastic right heart syndrome show a MEHA of -27.4° and 26.0°, respectively. This is significantly different from the healthy cohort.

During labor the fetus is monitored using cardiotocography (CTG). The most common techniques to acquire fetal heart rate (FHR) for CTG monitoring are Doppler Ultrasound (DU) and the fetal scalp electrode (FSE). DU is a non-invasive technique and can therefore be used before membranes have ruptured, but is known for a high signal loss and unreliable FHR. Monitoring via FSE is an invasive method, but more reliable and is considered the gold standard. However, this method carries an increased risk for complications, such as trauma and infection and can only be applied after membranes have ruptured and with sufficient dilation. Non-invasive fetal electrocardiography (NI-fECG) may be an alternative to conventional monitoring techniques. Chapter 6 shows a

review of the literature regarding the performance of the NI-fECG during labor. A total of 8 studies were included. Despite differences in methodology and type of NI-fECG devices, all included studies demonstrate that it is possible to apply NI-fECG during labor. Compared to DU, NI-fECG performs equally well or better in most studies. In chapter 7, we conducted a multicentre international cohort study to validate a NI-fECG device as a CTG device during labor. The results show that NI-FECG is more accurate compared to DU during labor.

Fetal monitoring during pregnancy is usually done by means of CTG monitoring. Currently, a consultation at an obstetric ward or outpatient clinic is often needed to conduct a CTG. A CTG shows the FHR, MHR and possible uterine contractions. Different studies show that home monitoring can help in reducing costs and burden for the pregnant woman. Generally, CTG home monitoring is not standard of care and if available it is often a device without real-time remote CTG monitoring. In chapter 8 we show a pilot study regarding the usability of the NI-fECG for home monitoring. This pilot is performed to evaluate user experience of the NI-fECG system of both the independent midwives and pregnant women and to establish how they feel about CTG home monitoring. This pilot is also developed to evaluate whether the existing device meets the requirements for home monitoring and if not, which adjustments need to be made. 20 pregnant women and 6 midwives participated in this pilot. Interestingly, none of the pregnant women preferred to be monitored at the hospital. The midwives and pregnant women are positive about home monitoring with the NI-FECG device.

CHAPTER 11

Nederlandse samenvatting

Niet-invasieve elektrofysiologische metingen van de foetus tijdens de zwangerschap en bevalling.

In dit proefschrift worden mogelijke toepassingen van elektrofysiologische metingen van de foetus tijdens de zwangerschap en bevalling beschreven. Het systeem maakt gebruik van non-invasieve electroden op de buik van de moeder. Uit de elektrofysiologische signalen kan een foetaal elektrocardiogram (ECG), foetaal hartritme (FHR), maternaal hartritme (MHR) en contracties van de baarmoeder verkregen worden. In dit werk worden drie mogelijke toepassingen van de elektrofysiologische metingen van de foetus beschreven.

In hoofdstukken 2-5 wordt beschreven hoe het non-invasief foetaal ECG (NI-fECG) als hulpmiddel ingezet kan worden om congenitale hartafwijkingen (CHD) in de zwangerschap op te sporen. Het screenen op en diagnosticeren van CHD in de zwangerschap wordt momenteel gedaan door middel van de 20 weken echo. Helaas wordt tijdens dit onderzoek maar 40-60% van de hartafwijkingen gezien. Daarom is het van belang dat er meer informatie beschikbaar komt om de screening te verbeteren. Het foetaal ECG kan hier mogelijk een rol in spelen, omdat het informatie bevat over de geleiding van de elektrische signalen door het hart. Wij veronderstellen dat deze geleiding aangedaan kan zijn wanneer er sprake is van een CHD. In hoofdstuk 2, wordt het studieprotocol beschreven. Tijdens de studieperiode zijn 328 foetussen zonder CHD en 148 foetussen met CHD geïncludeerd. Hoofdstuk 3 laat de eerste resultaten zien voor een methode die standaardiseert voor foetale ligging voor het berekenen van een foetaal ECG. Mogelijk zijn er verschillende karakteristieken van het foetaal ECG die kunnen bijdragen aan het detecteren van CHD in de zwangerschap, bijvoorbeeld de elektrische hart as. De elektrische hart as vertegenwoordigt de gemiddelde hoofdrichting van de elektrische activiteit door het hart tijdens één hart cyclus. Wij veronderstellen dat de richting van de elektrische hart as kan veranderen door bepaalde hartafwijkingen. In hoofdstuk 4 hebben wij de normaalwaarden voor de elektrische hart as in foetussen zonder CHD rond de 20 weken zwangerschap bepaald. Onze resultaten bevestigen dat er sprake is van een naar rechts georiënteerde elektrische hart as in foetussen halverwege de zwangerschap. De gemiddelde elektrische hart as (MEHA) werd bepaald op 122.7° (90% Predictie Interval (PI): -25.6°; 270.9°). Het PI is breed, dit betekent dat de elektrische hart as als op zichzelf staande karakteristiek van het foetaal ECG minder geschikt is voor het screenen naar CHD. In hoofdstuk 5 worden de resultaten uit hoofdstuk 4 gebruikt om de elektrische hart as van foetussen met een CHD te vergelijken met het gezonde cohort. Hier werd een MEHA van 83.0° (95% CI: 6.7°; 159.3°) gevonden, dit is niet significant verschillend ten opzichte van het gezonde cohort. Analyses van de subgroep van foetussen met een atrioventriculair septum defect en hypoplastisch rechter hart syndroom laten een MEHA van -27.4° en 26.0° zien. Deze zijn wel significant verschillend ten opzichte van de MEHA van het gezonde cohort.

Tijdens de bevalling wordt de foetus gemonitord middels het cardiotocogram (CTG). Een CTG geeft de FHR en mogelijke contracties van de baarmoeder weer. De twee meest gebruikte technieken voor het verkrijgen van een FHR voor het CTG is een niet-invasieve methode die gebruik maakt van Doppler Ultrasound (DU), of met een meer invasieve methode, een schedelelektrode (FSE). DU kan gebruikt worden voordat de vliezen gebroken zijn, maar staat erom bekend een hoger signaal verlies te hebben en een minder betrouwbaar signaal te geven. De FSE is betrouwbaarder en wordt gezien als de gouden standaard. Echter, gezien het een invasieve methode is geeft het een verhoogde kans op complicaties, zoals trauma en infectie en kan het alleen gebruikt worden wanneer de vliezen gebroken zijn en bij voldoende ontsluiting. NI-fECG kan een alternatief zijn voor de conventionele technieken voor foetale monitoring. In hoofdstuk 6 wordt een review van de literatuur gegeven betreffende de prestaties van het NI-fECG tijdens de bevalling. In totaal zijn er 8 studies geïncludeerd. Ondanks de verschillen in methodologie en typen NI-fECG systemen laten alle geïncludeerde studies zien dat het mogelijk is om monitoring middels het NI-fECG toe te passen tijdens de bevalling. In de meerderheid van de studies presteert het NI-fECG gelijk of beter in vergelijking met DU. In hoofdstuk 7 beschrijven we een multicenter internationale studie om een NI-fECG systeem te valideren als CTG-monitoringssysteem tijdens de bevalling. De resultaten laten zien dat het NI-fECG accurater is in vergelijking met DU tijdens de bevalling.

Foetale monitoring tijdens de zwangerschap is veelal door middel van CTG-monitoring. Op dit moment is hiervoor vaak een bezoek aan het ziekenhuis nodig. Verschillende studies laten zien dat thuis monitoring kan helpen bij het reduceren van de zorgkosten en belasting van de zwangere vrouw. Over het algemeen is CTG thuis monitoring geen standaard zorg en als het beschikbaar is, is het vaak een systeem zonder de mogelijkheid voor real-time CTG-monitoring op afstand. In hoofdstuk 8 laten we een pilotstudie zien met betrekking op de bruikbaarheid van het NI-fECG systeem voor thuis monitoring. Deze pilot evalueert de gebruikers ervaring van zowel de eerstelijns verloskundigen als de zwangere vrouw over het gebruik van het systeem en hun kijk op de mogelijkheid om thuis monitoring toe te passen. Verder is er gekeken of het systeem voldoet aan de vereisten voor thuis monitoring. 20 zwangere vrouwen en 6 eerstelijns verloskundigen namen deel aan de pilot. Opvallend, geen van de zwangere vrouwen gaf de voorkeur om in het ziekenhuis een CTG te ondergaan. Zowel de verloskundigen als de zwangere vrouwen staan positief tegenover thuis monitoring met het NI-fECG systeem.

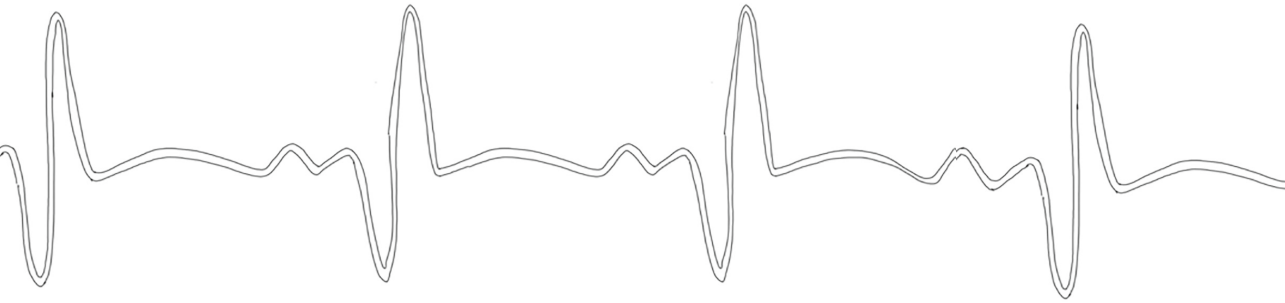

CHAPTER 12

APPENDICES

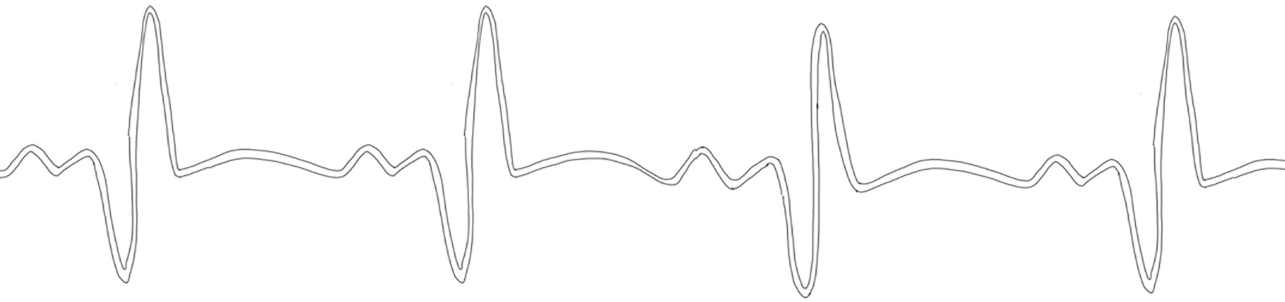

List of abbreviations

AVSD	Atrioventricular septal defect
BMI	Body mass index
bpm	Beats per minute
ccTGA	Congenitally corrected transposition of the great arteries (double discordance)
CHD	Congenital heart disease/defect
CI	Confidence interval
CTA	Conotruncal anomalies
CTG	Cardiotocography
DILV	Double inlet left ventricle
DORV	Double outlet right ventricle
DU	Doppler Ultrasound
ECG	Electrocardiogram
EHG	Electrohysterography
FBS	Fetal blooed sample
FHR	Fetal heart rate
FSE	Fetal scalp electrode
GA	Gestational age
GND	Ground
HRHS	Hypoplastic right heart syndrome
IQR	Interquartile range
IUPC	Intra-uterine pressure catheter
IVS	Intact ventriclar septum
LRT	Likelihood ratio test
MEHA	Mean electrical heart axis
MHR	Maternal heart rate
NI-fECG	Non-invasive fetal electrocardiography
PI	Prediction interval
Ref	Reference
SD	Standard deviation
SPML	Spherically projected multivariate linear
STAN	ST waveform analysis
TGA	Transposition of the great arteries
TOCO	Tocodynamometer
TOF	Tetralogy of Fallot
UA	Uterine activity
VCG	Vectorcardiogram
VSD	Ventricular septal defect

List of publications

Journal papers

Verdurmen KMJ, **Lempersz C**, Vullings R, Schroer C, Delhaas T, van Laar JOEH, Oei SG. Normal ranges for fetal electrocardiogram values for the healthy fetus of 18-24 weeks of gestation: a prospective cohort study. BMC Pregnancy Childbirth. 2016 Aug 17;16:227. doi: 10.1186/s12884-016-1021-x. PMID: 27531050; PMCID: PMC4987971

Verdurmen KM, Eijsvoogel NB, **Lempersz C**, Vullings R, Schroer C, van Laar JO, Oei SG. A systematic review of prenatal screening for congenital heart disease by fetal electrocardiography. Int J Gynaecol Obstet. 2016 Nov;135(2):129-134. doi: 10.1016/j.ijgo.2016.05.010. Epub 2016 Aug 4. PMID: 27634052.

Verdurmen KMJ, Warmerdam GJJ, **Lempersz C**, Hulsenboom ADJ, Renckens J, Dieleman JP, Vullings R, van Laar JOEH, Oei SG. The influence of betamethasone on fetal heart rate variability, obtained by non-invasive fetal electrocardiogram recordings. Early Hum Dev. 2018 Apr;119:8-14. doi: 10.1016/j.earlhumdev.2018.02.011. Epub 2018 Mar 2. PMID: 29505915.

Schramm K, Lapert F, Nees J, **Lempersz C**, Oei SG, Haun MW, Maatouk I, Bruckner T, Sohn C, Schott S. Acceptance of a new non-invasive fetal monitoring system and attitude for telemedicine approaches in obstetrics: a case-control study. Arch Gynecol Obstet. 2018 Dec;298(6):1085-1093. doi: 10.1007/s00404-018-4918-y. Epub 2018 Sep 27. PMID: 30264201.

Lempersz C, van Laar JO, Clur SB, Verdurmen KM, Warmerdam GJ, van der Post J, Blom NA, Delhaas T, Oei SG, Vullings R. The standardized 12-lead fetal electrocardiogram of the healthy fetus in mid-pregnancy: A cross-sectional study. PLoS One. 2020 Apr 30;15(4):e0232606. doi: 10.1371/journal.pone.0232606. PMID: 32353083; PMCID: PMC7192482.

Lempersz C, Noben L, van Osta G, Wassen MLH, Meershoek BPJ, Bakker P, Jacquemyn Y, Cuerva MJ, Vullings R, Westerhuis MEMH, Oei GS. Intrapartum non- invasive electrophysiological monitoring: A prospective observational study. Acta Obstet Gynecol Scand. 2020 Oct;99(10):1387-1395. doi: 10.1111/aogs.13873. Epub 2020 May 17. PMID: 32306380.

Lempersz C, Noben L, de Vries B, van Laar JOEH, Westerhuis MEMH, Oei SG. The Noninvasive Fetal Electrocardiogram During Labor: A Review of the Literature. Obstet Gynecol Surv. 2020 Jun;75(6):369-380. doi: 10.1097/OGX.0000000000000798. PMID: 32603475.

Lempersz C, Noben L, Clur SAB, van den Heuvel E, Zhan Z, Haak M, Oei SG, Vullings R, van Laar JOEH. The electrical heart axis of the fetus between 18 and 24 weeks of gestation: a cohort study. Manuscript submitted for publication

Lempersz C, van der Hout-van der Jagt MB, Manders N, Backx N, van Laar JOEH, Oei SG. User evaluation of realtime CTG home monitoring; a pilot study. Manuscript submitted for publication

Conference presentations and posters

Lempersz C, Noben L, Tissink J, Vullings R, Westerhuis MEMH, Oei SG. Signal Quality of the Non-Invasive Fetal ECG Device During Labour. A caseseries. Fetal and Neonatal Physiological Society, 2018

Lempersz C. Advances in fetal monitoring. Pecha Kucha presentation, opening Eindhoven MedTech Innovation Center (e/MTIC), 14 June 2018

Lempersz C, R Vullings, JOEH van Laar, SG Oei. Fetal ECG of Fetus With Tetralogy of Fallot. Posterpresentatie European Congres of Intrapartum Care, 2015

Noben L**, Lempersz C**, Westerhuis MEMH, Oei SG. Intrapartum non-invasive electrophysiological monitoring: a validation study. Birth Congress, Venice, 14-17 November 2018.

Dankwoord

Allereerst wil ik alle honderden zwangere vrouwen bedanken voor hun deelname aan de studies. Vaak deden jullie mee aan een studie tijdens een heel moeilijke tijd in jullie zwangerschap en ook tijdens het intieme moment van jullie bevalling. Mijn dank is groot, zonder jullie hadden de studies nooit plaats kunnen vinden.

Beste **Prof.dr. S.G. Oei**, beste **Guid**, ik weet nog heel goed dat ik voor een sollicitatie voor de onderzoeksstage bij jou op gesprek kwam. Je vertelde enthousiast over de onderzoeksgroep en de verschillende onderzoeken die liepen, ik was meteen verkocht. Niks saai achter een computer een database aanvullen, maar in de praktijk onderzoek mogen doen. Jouw enthousiasme voor (wilde) ideeën en dromen zorgt ervoor dat jezelf ook energie en enthousiasme krijgt voor de onderzoekswereld en misschien wel belangrijker om door te zetten en het onderzoek tot een goed einde te brengen. Hierin spelen de FUN-avonden natuurlijk ook een belangrijke rol met lekker eten en leuke presentaties. **Nanette** jij ook bedankt voor je gastvrijheid en net even andere invalshoek op het werk.

Beste **dr. J.O.E.H van Laar**, beste **Judith**, tijdens mijn wesp/gesp stage en het hele PhD-traject was het ontzettend fijn om jou als begeleider en mentor te hebben. Ik kon altijd bij je terecht, ook als het even wat minder soepel verliep en dan kwam ik altijd het gesprek weer uit met het idee dat het allemaal weer goed zou komen.

Beste **dr.ir. R. Vullings**, beste **Rik**, dank voor alle analyses, schrijfwerk en uitleg dat je voor dit promotieonderzoek hebt verricht. Ontzettend fijn hoe jij zeer complexe materie op een simpele manier weet weer te geven zodat het voor een niet-technisch onderlegd iemand als ik goed te vatten is.

Beste **M.E.M.H. Westerhui**s, beste **Michelle**. Dit promotietraject zijn wij samen begonnen. Dank voor je begeleiding bij de F3/F2 studie en in het vinden van een weg in een voor ons beide nieuwe wereld.

Beste **dr.ir. M.B. van der Hout-van der Jagt**, beste **Beatrijs**, we hebben samen een wat kleinere studie mogen doen wat erg leuk was. Maar ik wil je vooral bedanken voor het meedenken met de verschillende studies en dat je mij een hart onder de riem stak als ik het soms even niet meer zag zitten.

Beste **dr. S.A.B. Clur**, als een van de eerste enthousiastelingen in een extern centrum voor de Confes studie heeft u deze studie een enorme boost gegeven en kwam het van de grond, dank hiervoor. Dank dat ik (en vele studenten na mij) mee mocht kijken en leren bij u in de spreekkamer. Ook wil ik u bedanken voor het meedenken en schrijven aan de verschillende stukken in dit proefschrift.

I would like thank all the members of the Doctorate Committee. I am honored you all accepted the invitation to participate in the committee.

Beste **Bas**, ik herinner mij nog goed dat ik na een nachtdienst door jou werd wakker gebeld met de vraag of ik nog steeds geïnteresseerd was in het foetaal ECG en of ik aan de slag wilde als PhD-kandidaat. Dank dat je toen nog aan mij gedacht hebt! En natuurlijk ook voor de gezelligheid tijdens een bezoek aan Heidelberg, Londen en Chicago, wat een avontuur.

Beste **Trees** en **Moniek**, wat was het leuk om met jullie een kantoor te delen. Bedankt voor de gezellige momenten en verhalen en kennis over borstvoedingen. Dit komt nu erg goed van pas bij mijn werk op het consultatiebureau!

Lieve **Kirsten**, samen in de auto van Utrecht naar Veldhoven, bij jou kunnen ontladen en soms een beetje zeuren, want we wisten allebei dat we eigenlijk hele leuke onderzoeken hadden. Met jou begonnen en jij nu als paranimf ook dit hoofdstuk mogen afsluiten maakt het echt compleet.

Lieve **Olenka**, als semi-arts kwamen we elkaar al even tegen en later hebben we vele uurtjes in het hok doorgebracht wat altijd ontzettend gezellig was. Dank voor de gezellige etentjes, de stok achter de deur en af en toe een schouder!

En natuurlijk **Lore**, zonder jou stond dit boekje er niet. Wat was ik blij dat jij erbij kwam. Jouw structuur zorgde voor een verdere stroomversnelling van de verschillende studies en dat wij nu, op dezelfde dag, ons werk mogen verdedigen.

Lieve **Sophie**, lieve paranimf, ex-huisgenootje, ex-studiegenootje, ook al woon ik niet meer in het zuiden des lands, toch blijft het vertrouwd en vind ik het ontzettend leuk dat jij als paranimf aan mijn zijde staat!

Bij de verschillende studies, Confes, F2, TeleCTG zijn meerdere ziekenhuizen, verloskundige praktijken en andere centra betrokken die met enthousiaste vrijwilligers ervoor hebben gezorgd dat het includeren en uitvoeren van de studies ter plaatse in goed banen werden geleid. Heel veel dank aan het AMC, LUMC, Radboud MC, MUMC, Zuyderland ziekenhuis, het van Weel-Bethesda Ziekenhuis, UZA, 'Diagnostiek voor U', 040verloskunde en PUUR verloskunde. And many thanks for Hospital Universitario La Paz (Dr. M.J. Cuerva González) for its participation and dedication.

Ook wil ik mijn voormalig collega's van het **Flevoziekenhuis** met in het bijzonder **dr. W.M. van Baal** bedanken. Jullie gaven mij als net afgestuurd arts de kans om als ANIOS bij jullie aan de slag te gaan.

Lieve collega's uit het **Isala**, wat heb ik een ontzettend leuke en leerzame tijd bij jullie gehad. Het was echt ontzettend fijn om bij zulke leuke collega's in het team te mogen werken, met de gezellige lunches en borrels. Ook voelde ik mij enorm door jullie gesteund toen ik voor een weg buiten de gynaecologie koos, dit maakte de keuze een stuk minder lastig.

Lieve collega's bij de **GGD/JGZ**, door jullie voelde ik mij al snel thuis in een vakgebied dat helemaal nieuw voor mij was, ondanks de rare tijd waarin ik bij jullie ben gestart. Beste **Margot** jij zorgt met jouw duidelijkheid en het altijd bereikbaar zijn dat ik in een veilige situatie bij de JGZ aan het werk kon, dank hiervoor.

Lieve **Jet** en **Ralph**. Jet wat heb je een prachtig ontwerp voor dit boekje gemaakt dat echt bij mij past. En ik wil jullie ook allebei bedanken voor het warme onthaal in Zwolle. Het wonen daar zou een stuk minder als een thuis voelen als jullie er niet waren voor een goede borrel (met een goede discussie met jou Ralph) en BaiYok!

Lieve **Michiel** en **Marijke**, ik ben alweer 6 jaar bij jullie in de familie en jullie voelen ook echt als familie. Ik wil jullie bedanken voor jullie blijvende interesse in dit onderzoek maar ook voor de liefde voor Hugo en de leuke logeerpartijtjes.

Lieve **Marleen**, **Rick-Jan** en **Anna**, lieve zus, we worden oud, maar ik vergeet nooit je bezoekjes in Maastricht en de leuke vakanties samen. Rick-Jan je bent echt een aanwinst voor de familie en maakt de familie-etentjes en verjaardagen nog gezelliger en Anna maakt het natuurlijk helemaal af.

Lieve **pap** en **mam**, wat hebben jullie wat voor mij afgereisd door Nederland. Eerst voor de studie naar Maastricht later Eindhoven, Utrecht en nu Zwolle, dichterbij jullie. Pap die mij altijd lief ophaalde en wegbracht naar het station (of ook meer dan eens terugbracht naar Maastricht). Mam dankjewel voor al je lees- en verbeterwerk ook bij de stukken uit dit boekje. Dank voor jullie steun en interesse, ook dat heeft ervoor gezorgd dat ik heb doorgezet en dat dit werk er nu ligt. Ik vind het heerlijk om jullie nu ook als opa en oma te zien en dat Hugo het bij jullie zo ontzettend leuk heeft.

Liefste **Hugo**, jij kwam op het toneel middenin het onderzoekstraject en wat heb jij veel bij mij veranderd. Door jou en papa weet ik wat ik echt belangrijk vind. Jij brengt mij zoveel plezier en liefde en jouw lach in de ochtend zorgt ervoor dat mijn ochtendhumeur (bijna helemaal) verdwijnt. Ik hou van je schat.

Lieve lieve **Tim**, we hebben wat roerige jaren achter de rug, veel baanwisselingen bij mij, verhuizingen, maar jij was daar altijd. Door jou durfde ik te kijken of de dromen die ik had, nog steeds mijn dromen waren en met hulp van jou durfde ik van koers te veranderen. Dank voor al je steun bij dit promotietraject en bij mijn ochtendhumeur.

We verwachten snel ons tweede kindje en ik denk dat dat weer net *zoon* mooi avontuur wordt als met Hugo. Ik hou ontzettend veel van je.

Curriculum Vitae

Carlijn Lempersz was born on the 16th of April 1990 in Meppel, The Netherlands. In 2008 she graduated from secondary school Stad en Esch in Meppel. After she graduated she travelled 'around the world' and started her studies in Medicine a year later at Maastricht University. In her final year she followed her research internship at the Máxima Medical Center in Veldhoven under supervision of prof.dr. S.G. Oei. Here, she had the opportunity to participate in research regarding electrophysiologic measurements of the fetus.

After she graduated at Maastricht University in June 2015 she started as doctor not in training at the gynecology and obstetrics department at the Flevoziekenhuis in Almere. But the research subject kept fascinating her and a short year later she returned to Máxima Medical Center to start as a PhD candidate at the research group FUNdametal perinatology under supervision of prof.dr. S.G. Oei. The results are presented in this dissertation.

In 2019 she moved to Zwolle to start working at the gynecology and obstetrics department at Isala. In 2020 she decided to change course and broaden her view. She started working as a docter in child health care. Carlijn's ambition is after she may have received her PhD to start training as general practitioner.

Carlijn lives with her partner Tim and son Hugo in Zwolle, in May 2021 they expect their second child.