

Release of experimental retinal vein occlusions by direct intraluminal injection of ocriplasmin

Citation for published version (APA):

de Smet, M. D., Stassen, J. M., Meenink, T. C. M., Janssens, T., Vanheukelom, V., Naus, G. J. L., Beelen, M. J., & Jonckx, B. (2016). Release of experimental retinal vein occlusions by direct intraluminal injection of ocriplasmin. *British Journal of Ophthalmology*, 100(12), 1742-1746. <https://doi.org/10.1136/bjophthalmol-2016-309190>

DOI:

[10.1136/bjophthalmol-2016-309190](https://doi.org/10.1136/bjophthalmol-2016-309190)

Document status and date:

Published: 01/12/2016

Document Version:

Publisher's PDF, also known as Version of Record (includes final page, issue and volume numbers)

Please check the document version of this publication:

- A submitted manuscript is the version of the article upon submission and before peer-review. There can be important differences between the submitted version and the official published version of record. People interested in the research are advised to contact the author for the final version of the publication, or visit the DOI to the publisher's website.
- The final author version and the galley proof are versions of the publication after peer review.
- The final published version features the final layout of the paper including the volume, issue and page numbers.

[Link to publication](#)

General rights

Copyright and moral rights for the publications made accessible in the public portal are retained by the authors and/or other copyright owners and it is a condition of accessing publications that users recognise and abide by the legal requirements associated with these rights.

- Users may download and print one copy of any publication from the public portal for the purpose of private study or research.
- You may not further distribute the material or use it for any profit-making activity or commercial gain
- You may freely distribute the URL identifying the publication in the public portal.

If the publication is distributed under the terms of Article 25fa of the Dutch Copyright Act, indicated by the "Taverne" license above, please follow below link for the End User Agreement:

www.tue.nl/taverne

Take down policy

If you believe that this document breaches copyright please contact us at:

openaccess@tue.nl

providing details and we will investigate your claim.



OPEN ACCESS

Release of experimental retinal vein occlusions by direct intraluminal injection of ocriplasmin

Marc D de Smet,^{1,2} Jean Marie Stassen,³ Thijs C M Meenink,² Tom Janssens,⁴ Valérie Vanheukelom,⁴ Gerrit J L Naus,² Maarten J Beelen,² Bart Jonckx⁴

► Additional material is published online only. To view please visit the journal online (<http://dx.doi.org/10.1136/bjophthalmol-2016-309190>).

¹MicroInvasive Ocular Surgery Center (MIOS sa), Lausanne, Switzerland

²Preceyes nv, Eindhoven, The Netherlands

³Cristapharm bvba, Lubbeek, Belgium

⁴Thrombogenics nv, Leuven, Belgium

Correspondence to

Professor Marc D de Smet, MicroInvasive Ocular Surgery Center (MIOS sa), Av du Léman 32, Lausanne 1005, Switzerland; mddesmet1@mac.com

Received 15 June 2016

Revised 25 August 2016

Accepted 3 September 2016

Published Online First

28 September 2016

ABSTRACT

Purpose Retinal vein occlusions (RVO) are a major cause of vision loss in people aged 50 years and older. Current therapeutic options limit the consequences of RVO but do not eliminate the cause. Cannulation of the involved vessel and removal of the clot may provide a more permanent solution with a less demanding follow-up. However, cannulation of smaller retinal veins remains challenging. This paper explores the use of ocriplasmin (recombinant plasmin without its kringle) to clear RVO, using a robotic micromanipulator.

Methods Branch RVO were induced in a porcine model with rose bengal followed by 532 nm endolaser to the superior venous branch of the optic nerve. The vein was cannulated proximal to the occlusion or beyond the first branching vessel from the obstruction. The vein was infused with a physiologic citric acid buffer solution (CAM) or CAM/ocriplasmin. The time of cannulation, number of attempts, and the ability to release the thrombus were recorded.

Results Cannulation and infusion was possible in all the cases. The use of a micromanipulator allowed for a consistent cannulation of the retinal vein and positional stability allowed the vein to remain cannulated for up to 20 min. In none of the attempts (5/5) with CAM did the thrombus dissolve, despite repeat infusion/relaxation cycles. In 7/7 injections of CAM/ocriplasmin near to the point of obstruction, the clot started to dissolve within a few minutes of injection. An infusion, attempted beyond the first venous branch point proximal to the clot, was unsuccessful in 2/3 attempts.

Conclusions Ocriplasmin is effective in resolving RVO if injected close to the site of occlusion with the use of a micromanipulator.

INTRODUCTION

Retinal vein occlusions (RVO) are a frequent cause of vision loss in patients over 50 years of age.¹ These occlusions in both branch and central retinal veins are usually caused by thrombi composed of fibrin, platelets and an admixture of erythrocytes.^{2–4} As the retinal circulation is composed of end arterioles and venules with no collateral circulation, such occlusions lead within the watershed area to ischaemia, nutrient deprivation and alterations in fluid balance within the retina.^{5–6} Vision loss due to retinal thickening and macular oedema rapidly develops, followed by an inflammatory response and the formation of collateral vessels.^{5–7} Similar findings are observed in experimental models.^{8–10}

The activation of the coagulation cascade and the formation of a thrombus also lead to a direct activation of the enzymatic processes that mediate the removal of the thrombus by endogenous fibrinolysis.¹¹ Fibrinolysis is a tightly regulated process. It involves the conversion of inactive plasminogen to active plasmin—a potent serine protease capable of cleaving insoluble fibrin polymers into soluble fragments.¹² Its most important activator in the circulatory system is tissue plasminogen activator (tPA). While the latter is produced by endothelial cells adjacent to the thrombus, plasminogen is synthesised in the liver and must reach the site of obstruction via the circulation.^{12–14} Continued remodelling of the thrombus leads to a progressive depletion of the remaining plasminogen. Once plasminogen is depleted, addition of exogenous tPA adjacent to the thrombus cannot help in its dissolution. This partially explains the limited success observed in the series published so far, when tPA was injected into retinal veins to resolve an RVO.¹⁵

Arguments have been advanced that following an occlusion, its release would not lead to a permanent recannulation as the damaged endothelial lining of the vessel would lead to further clot formation. Clinical experience would be seen to contradict this statement. Garcia-Arumi *et al*¹⁶ reported that successful retinal vein sheathotomies, upon to 9 weeks after the onset of a branch retinal vein occlusion, lead to a normalised blood flow in a follow-up extending to 1 year. Sheathotomies are a delicate form of surgery requiring a high degree of expertise. A simpler approach would consist in injecting active plasmin enzyme or an analogue at the site of occlusion. Ocriplasmin is a recombinant protein containing the catalytic domain of plasmin but none of its kringle. In ophthalmology, it was initially proposed as an interfactant to separate the posterior hyaloid from its retinal insertion^{17–18} and has since been commercialised for vitreomacular adhesion. However, the compound was initially developed for use in stroke victims with the aim of dissolving thrombi within the cerebrovascular circulation.^{19–20}

In RVO, a lack of plasmin is a possible cause for the persistence of occlusions following the injection of tPA. If this hypothesis is true, an injection of ocriplasmin within the venous system before the site of occlusion should lead to a resolution of the occlusion and a re-opening of the affected vessel. To this end, rose bengal-induced RVO were generated in young pigs, as the pig retinal vasculature has structural characteristics similar to that of humans. To deliver the enzyme to the site of occlusion, retinal venules were cannulated before the site



CrossMark

To cite: de Smet MD, Stassen JM, Meenink TCM, *et al.* *Br J Ophthalmol* 2016;**100**:1742–1746.

of occlusion with the assistance of a robotic micromanipulator, which is able to compensate for physiologic tremor while providing needed positional stability required for prolonged infusions.¹⁰ Herein we report the results of these initial experiments.

METHODOLOGY

Animals and creation of a venous occlusion

All animals were housed and cared for in compliance with the Federation of European Laboratory Animal Science Associations guidelines and recommendations. The study was approved by the Ethics Committee for Animal Research at Medanex Clinic (EC MxCl-2013-017; Diest, Belgium) and conformed to the Association for Research in Vision and Ophthalmology statement for the use of animals in ophthalmic and vision research.

Farm pigs, 5–7 weeks old, were anaesthetised with an intramuscular (IM) injection of 2.2 mg/kg xylazine (Xyl-M 2%; V.M. D.nv/sa, Arendonck, Belgium) and 4.4 mg/kg tiletamin-zolazepam (Zoletil 100, Virbac, Carros, France). The animals were then intubated with a cuffed endotracheal tube (internal diameter of 6–7.5 mm) (Kruuse, Langeskov, Denmark) followed by mechanical ventilation. Anaesthesia was maintained with 1.5–2% isoflurane (IsoFlo, Ecuphar, Oostkamp, Belgium).

The venous occlusions were created and confirmed as previously described.¹⁰ Briefly, 10 mg/kg of rose bengal (4,5,6,7-tetrachloro-2',4',5',7'-tetraiodo-fluorescein; Sigma-Aldrich: Diegem, Belgium) was injected intravenously. Two to seven minutes following the injection, a retinal vein was occluded after its last bifurcation prior to the optic nerve using a 532 nm laser (Oculight-GL532, Iridex, Mountain View, California, USA) with the use of an endolaser probe inserted into the eye via a 25G cannula. About 3–4× the diameter of the vein was lasered, until there was evidence of an occlusion. The power settings were 140 mW and 110 ms. The occlusion was confirmed by the retrograde filling of the venous vasculature as described below.

Cannulation procedure

Within 1 hour of causing the occlusion, the animal was positioned and prepared for surgery as previously described.¹⁰ In brief, the set-up consisted of a standard operating suite including a M822 F40 Leica ophthalmic surgical microscope (Diegem, Belgium), a DORC Associate ACS2500 Dual vitrectomy unit (DORC bv, Zuidland, the Netherlands) coupled to a prototype robotic arm and its controller (PrecEyes bv, Eindhoven, the Netherlands). The latter was positioned on the ventral side of the animal. The pen-like prolongation of the controller was positioned laterally, 30 cm from the proposed ventral sclerotomy, in a non-obtrusive location. The robotic arm was held to a fixed base, itself firmly attached to the headrest positioned just outside the surgical field but in arm's reach. Three 25-gauge trocars were placed 2 mm posterior to the limbus. The temporal sclerotomy was enlarged using an vitrectomy knife blade to allow insertion of a funnel-shaped positional trocar provided by PrecEyes bv. This trocar allows a precise alignment between the catheter controlled by the robotic arm and the eye. After achieving a snug fit between the inner funnel of the trocar and the needle holder on the robotic arm, a glass pipette with a terminal 30 µm outer diameter and a bevelled tip (PrecEyes bv, Eindhoven, the Netherlands) was carefully advanced until visible in the vitreous cavity through the operating microscope. Illumination was provided by a standard 25G handheld light pipe, kept at an appropriate distance to provide optimal illumination of the chosen cannulation site. No vitrectomy was performed in these procedures. In all cases, the catheter was

advanced robotically while being observed via the surgical microscope. Once positioned over the intended site along a retinal vein, using an actuator, the robot was instructed to complete a preprogrammed piercing motion. The appropriate insertion into the vein was confirmed by infusing a 5 mM physiological citric acid buffer solution (CAM) via a pump at 14 µL/min (Model R99-E, Razel Scientific Instruments, Saint Albans, Vermont, USA). When appropriately inserted into the vein, the infusion of CAM leads to a retrograde distention of the venous system with the vessels becoming progressively transparent (figure 1, see online supplementary video).

Injection of active substance or control

After confirming a successful cannulation, the syringe was switched to the one containing either microplasmin (2.5 mg/mL in CAM) or the vehicle control (CAM). The surgeon was not informed of the specific substance being used. The injection was started and allowed to continue until there was evidence of recannulation—seen as a displacement of the clot (figure 2, see online supplementary video), and the appearance of a fresh blood column both proximal and distal to the site of occlusion. Alternatively, the proximal venous vasculature was allowed to fill with vehicle solution until light blanching of the retina was evident. The infusion was then stopped with the needle remaining in position within the vein, allowing the venous system to refill with blood. The process was repeated several times or until there was evidence of clot dissolution. The infusion was maintained until a normal venous circulation was re-established. When the procedure was completed, the needle was then removed in retrograde fashion from the eye.

RESULTS

The cannulation experiment was carried out in 15 eyes. In 5 eyes, a vehicle control was infused between 5 and 18 min into the eye without release of the occlusion (table 1). In 10 eyes, ocriplasmin was infused in the occluded vein near the site of occlusion. When the vein was cannulated beyond the last venous branch point prior to the site of occlusion, the thrombus was released successfully in 7/7 eyes (figure 1, see online supplementary video 1). If the cannulation was attempted beyond the first venous branch point, the ocriplasmin solution did not reach the site of the occlusion as it was deviated away via the branch vessel. Three attempts were made, two of which were unsuccessful (figure 2, see online supplementary video 2). On removal of the catheter, bleeding was sometimes encountered. The bleeding was contained by the overlying vitreous adjacent to the cannulated vessel. Raising the intraocular pressure caused the bleeding to stop, allowing the latter to be rapidly contained.

In preliminary experiments, multiple cannulations attempts were made. Without using the automated piercing protocol, both the anterior and posterior walls of the vein were pierced in about 50% of the cases. When ocriplasmin was inadvertently injected into the subretinal space, the overlying retina became less translucent (figure 3). Injection of ocriplasmin above the vein into the vitreous leads to a localised posterior vitreous detachment and the appearance of vitreous haze in the area of injection (figure 4). No such change was observed when using CAM. No other untoward effect was noted from the use of ocriplasmin.

DISCUSSION

Several studies using anti-vascular endothelial growth factor (VEGF) agents and steroids have underscored the benefit of repeat intraocular injections in restoring vision in patients with

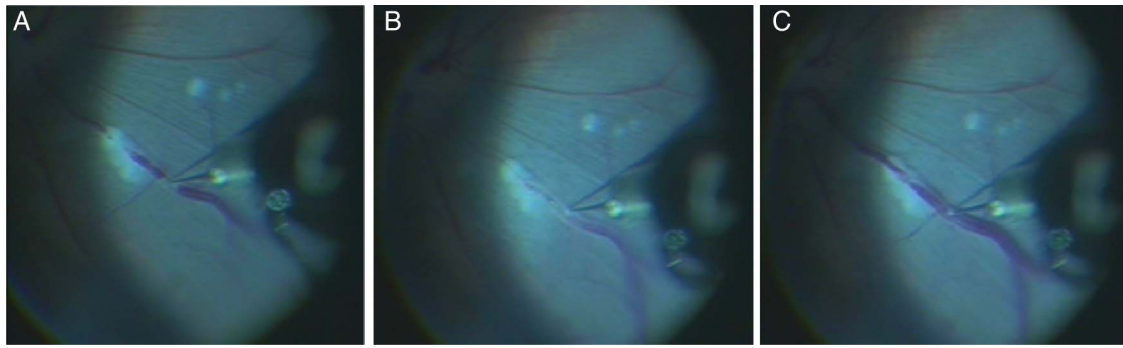


Figure 1 Effect of the injecting ocriplasmin proximal to the venous occlusion. (A) Catheter is being placed in the vessel. (B) Ocriplasmin is reaching the level of the occlusion. (C) At about 3 min in the infusion attempt, complete recannulation occurs (see also online supplementary video 1).

RVO. However, the gains are dependent on continued injections over a prolonged period of time extending over years for some patients. Since neither class of drug addresses the underlying cause but only provides temporary relief for the consequences of an occlusion, there remains a need to find and develop new therapeutic approaches. In the 1990s and early 2000, surgical techniques were attempted to address this issue, including the cannulation of retinal vein adjacent to the site of occlusion with the infusion of tPA. While technically feasible in central RVO, the thrombus was released in only 30% of cases.^{21–23} There was a trend favouring occlusions of shorter duration but successful release was also seen in some eyes with an occlusion of more than 6 months duration. Sheathotomies releasing the compression between the retinal artery and vein has also met with limited success.²⁴ Given the risks of surgery and limited success, these approaches have since been abandoned. We propose in this paper, a solution that addresses two main limitations of these techniques: (1) a more effective pharmacologic means of relieving the occlusion by relying on the physiology of thrombus dissolution and (2) a more reliable, less technically challenging mode of delivery.

The lysis of a thrombus is mediated by plasmin, an active serine protease that is produced by the cleavage of plasminogen by plasminogen activator (PA) or other cleavage enzyme. While

PA is produced locally by endothelial cells, plasminogen is synthesised in the liver and can only reach the site of an occlusion by means of the circulation.²⁵ Once activated, plasmin has a short half-life. In the absence of a collateral blood supply, locally available plasmin will progressively be depleted and further remodelling or release of a thrombus will not be possible. The low success rate with tPA in patients with RVO is likely reflective of the lack of locally available plasminogen. Ocriplasmin, the active moiety of plasmin, when placed close to the site of the occlusion is able to dissolve the clot. However, when injected beyond a vascular branch point, it was not possible to release the thrombus as ocriplasmin was unable to reach the clot. Of note, we did not notice any increase in bleeding at the site of injection or in the peri-ocular tissue. Further studies will have to determine the minimal effective dose, and whether or not a clot reforms at the site of its release.

The second point, raised regarding technical feasibility and ease, is important if a therapy is to be adopted and implemented by a large number of physicians. We have demonstrated here, in an experimental model, that the cannulation of retinal veins is possible without extensive surgery. Indeed, given the precision with which a very thin cannula is advanced through the vitreous cavity and inserted into a retinal vein, a vitrectomy can be avoided. Similarly, transvitreal biopsies of subretinal tumours are

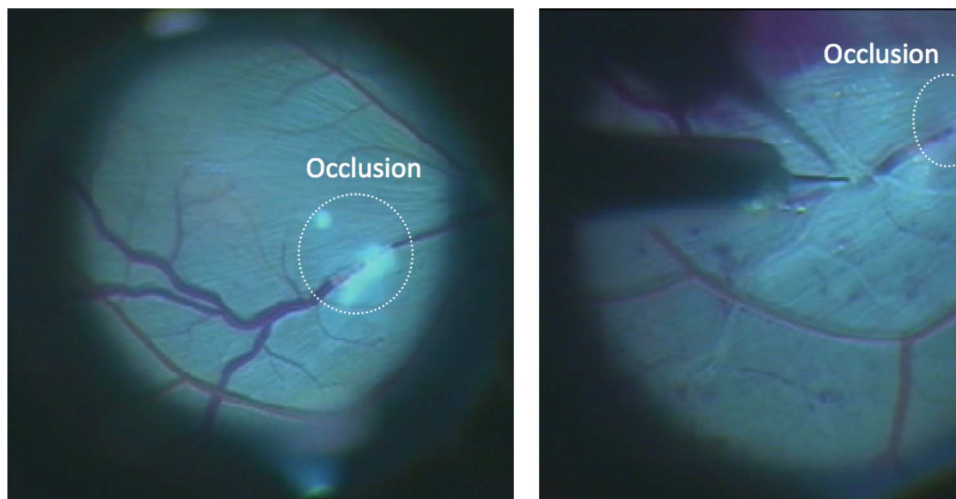


Figure 2 Injection of ocriplasmin at the level of a branching vessel or beyond prevents the active enzyme from reaching the occlusion. The occlusion was not relieved. (A) The site of occlusion. (B) The vein was cannulated and injected without release of the clot or the infusion reaching the level of the clot (see also online supplementary video 2).

Table 1 Success in achieving thrombus release following cannulation and injection of buffer or ocriplasmin

Exp no	Infused substance	Position of needle*	Infusion time	Thrombus release	Number of cycles
1	Buffer	A	17	No	5
2	Buffer	A	8	No	3
3	Buffer	A	9	No	4
4	Buffer	A	18	No	6
5	Buffer	A	5	No	3
6	Ocriplasmin	A	5	Yes	3
7	Ocriplasmin	A	6	Yes	2
8	Ocriplasmin	A	8	Yes	2
9	Ocriplasmin	A	4	Yes	2
10	Ocriplasmin	A	2	Yes	2
11	Ocriplasmin	A	13	Yes	1
12	Ocriplasmin	A	20	Yes	5†
11	Ocriplasmin	B	5	Yes	2
12	Ocriplasmin	B	7	No	2
13	Ocriplasmin	B	6	No	6

*A corresponds to a venous cannulation close to the site of occlusion and prior to the first venous branch point.

B corresponds to a cannulation beyond the first venous branch point.

†Catheter tip broke, insertion re-attempted.

usually performed without a vitrectomy. This procedure is less invasive and hence less likely to lead to complications. In the presence of an intact posterior hyaloid, it would add an additional level of security as it would limit any haemorrhage to the immediate perivascular area. The robotic arm facilitates the procedure by precisely controlling the advancement of the catheter to the occluded vein with a positional precision of under 10 μm , filtering out tremor, scaling motion, and automating critical steps.¹⁰ In the current experiments, a specific piercing protocol insured that the superficial wall of the vein was penetrated while avoiding piercing the outer wall of the vessel. Standby functionality, allowed the surgeon to release his grip while maintaining the tip at a specific location. This was required to allow the infusion of ocriplasmin to take place over several minutes until the occlusion was fully resolved. It proved capable of maintaining the cannula in position for up to 20 min

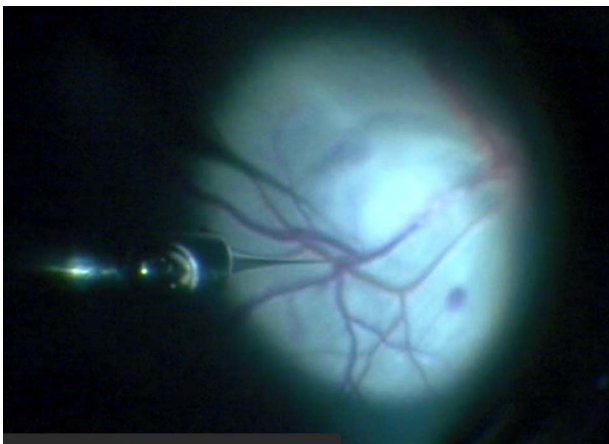


Figure 3 Ocriplasmin was injected into the subretinal space leading to a blanching of the overlying retina. This appearance remained for several minutes following the injection.

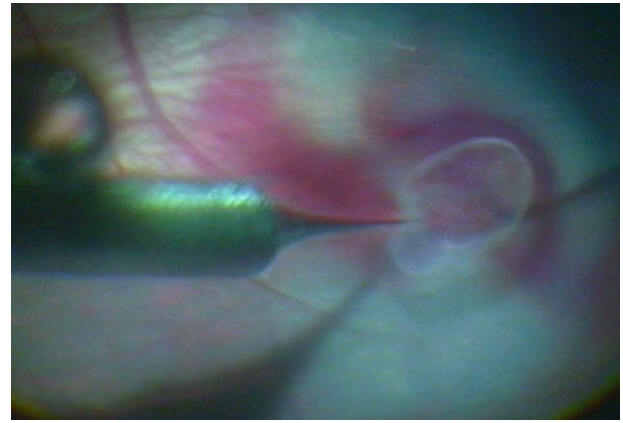


Figure 4 Ocriplasmin was injected above the vessel into the vitreous. This leads to a localised vitreous haze and with minimal traction the development of a localised vitreous detachment.

in the current experiments allowing for a successful release of the obstruction when using ocriplasmin, injected close to the site of occlusion. The design of the robotic arm allows its use in existing operating room environments with current generations of microscopes. It is both physically and visually controlled by the surgeon. However, visualisation of small vascular structures and exact positioning remain challenging as there is no force feedback mechanism that can give an indication of the forces applied, particularly when penetrating the vessel wall. The integration of a sensor measuring forces or an optical device measuring distance would allow further automation and precision when performing this procedure. While the current cannulation procedure was designed to release an obstruction, the same approach could be used to thrombosed vessels, such as in arteriovenous malformation or a macroaneurysm.

In conclusion, we have demonstrated the feasibility of relieving a retinal venous occlusion by injecting at the site of occlusion, a physiologic analogue of plasmin. The cannulation protocol involved minimal surgical steps and was assisted by a robotic micromanipulator. The injection of ocriplasmin or other plasmin analogue must be carried out in the direct proximity to the thrombus if the procedure is to be effective.

Contributors MDdS contributed to the design, data acquisition, data analysis and interpretation, wrote the first draft and made revisions to the manuscript. JMSt contributed to the design and revision of the manuscript. TCMM, GJLN and MJB contributed to the implementation of the design, data acquisition, interpretation and revisions of the draft manuscript. TJ and VV in data acquisition and analysis. BJ in design, data interpretation and analysis and writing the manuscript and its revision.

Funding Provided through an unrestricted grant from Thrombogenerics, bv; the development of the robotic system was supported by an STW valorisation grant (the Netherlands).

Competing interests MDdS reports grants, personal fees, non-financial support and other from Thrombogenerics bv, grants from Technology Foundation STW, personal fees, non-financial support and other from Preceyes bv, during the conduct of the study; grants and personal fees from Allergan Inc, personal fees from Bayer Inc, outside the submitted work; In addition, MDdS has a patent Pharmacologic vitreolysis WO 2004/052228 A2 licensed, and a patent surgical Master-Slave Robot 16154172.7-1659 issued. MS reports personal fees from Thrombogenerics bv, during the conduct of the study. TCMM, GJLN, and MJB report personal fees, non-financial support and other from Preceyes bv, during the conduct of the study; In addition, TCMM and GJLN have a patent 16154172.7-1659 issued. BJ, TJ, VV report personal fees, non-financial support and other from Thrombogenerics bv, during the conduct of the study.

Provenance and peer review Not commissioned; externally peer reviewed.

Data sharing statement Videos of surgeries performed in the context of this study can be made available on request by contacting Preceyes bv via its website (www.preceyes.nl).

Open Access This is an Open Access article distributed in accordance with the Creative Commons Attribution Non Commercial (CC BY-NC 4.0) license, which permits others to distribute, remix, adapt, build upon this work non-commercially, and license their derivative works on different terms, provided the original work is properly cited and the use is non-commercial. See: <http://creativecommons.org/licenses/by-nc/4.0/>

REFERENCES

- Rogers S, McIntosh RL, Cheung N, *et al.* The prevalence of retinal vein occlusion: pooled data from population studies from the United States, Europe, Asia, and Australia. *Ophthalmol* 2010;117:313–19.
- Green WR, Chan CC, Hutchins GM, *et al.* Central retinal vein occlusion: a prospective histopathologic study of 29 eyes in 28 cases. *Trans Am Ophthalmol Soc* 1981;79:371–422.
- Bowers DK, Finkelstein D, Wolff SM, *et al.* Branch retinal vein occlusion. A clinicopathologic case report. *Retina* 1987;7:252–9.
- Frangieh GT, Green WR, Barraquer-Somers E, *et al.* Histopathologic study of nine branch retinal vein occlusions. *Arch Ophthalmol* 1982;100:1132–40.
- Rehak M, Wiedemann P. Retinal vein thrombosis: pathogenesis and management. *J Thromb Haem* 2010;8:1886–94.
- Koferl P, Hollborn M, Rehak J, *et al.* Effects of arteriolar constriction on retinal gene expression and Muller cell responses in a rat model of branch retinal vein occlusion. *Graefes Arch Clin Exp Ophthalmol* 2014;252:257–65.
- Rehak J, Rehak M. Branch retinal vein occlusion: pathogenesis, visual prognosis, and treatment modalities. *Curr Eye Res* 2008;33:111–31.
- Ameri H, Ratanapakorn T, Rao NA, *et al.* Natural course of experimental retinal vein occlusion in rabbit; arterial occlusion following venous photothrombosis. *Graefes Arch Clin Exp Ophthalmol* 2008;246:1429–39.
- Zhang Y, Fortune B, Atchaneeyasakul LO, *et al.* Natural history and histology in a rat model of laser-induced photothrombotic retinal vein occlusion. *Curr Eye Res* 2008;33:365–76.
- de Smet MD, Meenink TCM, Janssens T, *et al.* Robotic Assisted Cannulation of Occluded Retinal Veins. *PLoS ONE* 2016;11:e0162037.
- Okafor ON, Gorog DA. Endogenous fibrinolysis: an important mediator of thrombus formation and cardiovascular risk. *J Am Coll Cardiol* 2015;65:1683–99.
- Pallis AG, Hatse S, Brouwers B, *et al.* Evaluating the physiological reserves of older patients with cancer: the value of potential biomarkers of aging? *J Geriatr Oncol* 2014;5:204–18.
- Schaller J, Gerber SS. The plasmin-antiplasmin system: structural and functional aspects. Cellular and molecular life sciences. *Cell Mol Life Sci* 2011;68:785–801.
- Raum D, Marcus D, Alper CA, *et al.* Synthesis of human plasminogen by the liver. *Science* 1980;208:1036–7.
- Yamamoto T, Kamei M, Sakaguchi H, *et al.* Comparison of surgical treatments for central retinal vein occlusion; RON vs. cannulation of tissue plasminogen activator into the retinal vein. *Retina* 2009;29:1167–74.
- Garcia-Arumi J, Martinez-Castillo V, Boixadera A, *et al.* Management of macular edema in branch retinal vein occlusion with sheathotomy and recombinant tissue plasminogen activator. *Retina (Philadelphia, Pa)* 2004;24:530–40.
- Gad Elkareem A, Willikens B, Vanhove M, *et al.* Characterization of a stabilized form of microplasmin for the induction of a posterior vitreous detachment. *Curr Eye Res* 2010;35:909–15.
- de Smet MD, Valmaggia C, Zarrantz J, *et al.* Microplasmin: ex vivo characterization of its activity in porcine vitreous. *Invest Ophthalmol Vis Sci* 2009;50:814–19.
- Suzuki Y, Nagai N, Collen D. Comparative effects of microplasmin and tissue-type plasminogen activator (tPA) on cerebral hemorrhage in a middle cerebral artery occlusion model in mice. *J Thromb Haem* 2004;2:1617–21.
- Nagai N, Demarsin E, van Hoef B, *et al.* Recombinant human microplasmin: production and potential therapeutic properties. *J Thromb Haem* 2003;1:307–13.
- Bynoe LA, Hutchins RK, Lazarus HS, *et al.* Retinal endovascular surgery for central retinal vein occlusion. Initial experience of four surgeons. *Retina* 2005;25:625–32.
- Feltgen N, Junker B, Agostini H, *et al.* Retinal endovascular lysis in ischemic central retinal vein occlusion: one-year results of a pilot study. *Ophthalmol* 2007;114:716–23.
- Berker N, Batman C. Surgical treatment of central retinal vein occlusion. *Acta Ophthalmol* 2008;86:245–52.
- Charbonnel J, Glacet-Bernard A, Korobelnik JF, *et al.* Management of branch retinal vein occlusion with vitrectomy and arteriovenous adventitial sheathotomy, the possible role of surgical posterior vitreous detachment. *Graefes Arch Clin Exp Ophthalmol* 2004;42:223–8.
- Lijnen H, Collen D. Mechanisms of physiological fibrinolysis. *Baillière's Clin Haematol* 1995;8:277–90.