

Synthetic meniscus replacement

Citation for published version (APA):

Vrancken, A., Buma, P., & van Tienen, T. G. (2013). Synthetic meniscus replacement: a review. *International Orthopaedics*, 37(2), 291-299. <https://doi.org/10.1007/s00264-012-1682-7>

DOI:

[10.1007/s00264-012-1682-7](https://doi.org/10.1007/s00264-012-1682-7)

Document status and date:

Published: 01/02/2013

Document Version:

Publisher's PDF, also known as Version of Record (includes final page, issue and volume numbers)

Please check the document version of this publication:

- A submitted manuscript is the version of the article upon submission and before peer-review. There can be important differences between the submitted version and the official published version of record. People interested in the research are advised to contact the author for the final version of the publication, or visit the DOI to the publisher's website.
- The final author version and the galley proof are versions of the publication after peer review.
- The final published version features the final layout of the paper including the volume, issue and page numbers.

[Link to publication](#)

General rights

Copyright and moral rights for the publications made accessible in the public portal are retained by the authors and/or other copyright owners and it is a condition of accessing publications that users recognise and abide by the legal requirements associated with these rights.

- Users may download and print one copy of any publication from the public portal for the purpose of private study or research.
- You may not further distribute the material or use it for any profit-making activity or commercial gain
- You may freely distribute the URL identifying the publication in the public portal.

If the publication is distributed under the terms of Article 25fa of the Dutch Copyright Act, indicated by the "Taverne" license above, please follow below link for the End User Agreement:

www.tue.nl/taverne

Take down policy

If you believe that this document breaches copyright please contact us at:

openaccess@tue.nl

providing details and we will investigate your claim.

Synthetic meniscus replacement: a review

Anne Christiane Theodora Vrancken · Pieter Buma ·
Tony George van Tienen

Received: 1 October 2012 / Accepted: 3 October 2012 / Published online: 26 October 2012
© Springer-Verlag Berlin Heidelberg 2012

Abstract The number of meniscus-related operations continues to rise due to the ageing and more active population. Irreparable meniscal lesions generally require (partial) meniscectomy. Although a majority of the patients benefit from pain relief and functional improvement post-meniscectomy, some remain symptomatic. As an alternative to a meniscal allograft, which is only indicated for the severely damaged meniscus, most patients can nowadays be treated by implantation of a synthetic meniscal substitute. Currently three of these implants, two partial and one total replacement, are clinically available and several others are in the stage of preclinical testing. Grossly, two types of meniscal substitutes can be distinguished: porous, resorbable implants that stimulate tissue regeneration and solid, non-resorbable implants that permanently replace the whole meniscus. Although the implantation of a porous meniscus replacement generally seems promising and improves clinical outcome measures to some degree, their superiority to partial meniscectomy still needs to be proven. The evaluation of new prostheses being developed requires a wider focus than has been adopted so far. Upon selection of the appropriate materials, preclinical evaluation of such implants should comprise a combination of (in vitro) biomechanical and (in vivo) biological tests, while up to now the focus has mainly been on biological aspects. Obviously, well-defined randomised controlled trials are necessary to

support clinical performance of new implants. Since the use of a meniscus replacement requires an additional costly implant and surgery compared to meniscectomy only, the clinical outcome of new products should be proven to surpass the results of the conventional therapies available.

Meniscal injuries

The knee is the most vulnerable joint in a young and active population [1, 2]. In 15 % of all knee injuries either one of the menisci is involved [3]. Previously reported incidence rates for hospital admission after meniscal injury vary between 0.35 and 0.7 per 1,000 person-years [1, 2]. However, in a large, recently published study amongst active duty US military service members, the incidence of meniscal injury (treated and non-treated) was found to be as high as 8.27 per 1,000 person-years [4].

Meniscal lesions can be classified according to their cause. Acute or traumatic tears result from forced movement of the knee joint, affecting a healthy meniscus. However, meniscal lesions also regularly arise without the presence of knee trauma. These degenerative or chronic tears are a result of the deterioration of tissue quality being part of the natural ageing process [5, 6]. The two types of tears can be morphologically discriminated: traumatic meniscal lesions generally are vertically and longitudinally oriented, whereas degenerative tears usually originate from a horizontal direction [5, 6]. The risk of tearing a meniscus in the age group over 40 years was reported to be larger by a factor of four than that of the age group under 20 years [4]. Keeping in mind the ageing of the Western population and the fact that people nowadays desire to retain their activity up to a high age, this is an alarming observation that requires an appropriate set of treatment options for patients.

Treatment

Meniscal tears require surgical intervention in approximately 85 % of the cases, a relatively high percentage compared

A. C. T. Vrancken (✉) · P. Buma · T. G. van Tienen
Orthopaedic Research Lab,
Radboud University Nijmegen Medical Centre,
Huispost 357, PO Box 9101, 6500 HB Nijmegen,
The Netherlands
e-mail: a.vrancken@orthop.umcn.nl

P. Buma
e-mail: p.buma@orthop.umcn.nl

T. G. van Tienen
e-mail: t.vantienen@orthop.umcn.nl

T. G. van Tienen
Department of Orthopaedic Surgery, ViaSana Clinic,
PO Box 4, 5450 AA Mill, The Netherlands

to other internal injuries of the knee joint [3]. The total number of meniscus-related surgeries in the USA is estimated to be 850,000 annually [7]. Repair strategies, like sutures, staples and anchors, allow preservation of the meniscal tissue. However, successful healing of the torn tissue is more likely when it is located in the vascularised region of the meniscus [8, 9], making repair techniques less suitable for degenerative tears which tend to start at the inner circumference of the meniscus. Irreparable meniscal lesions are usually treated by partial or (sub)total meniscectomy. In some cases further treatment with a meniscal substitute is indicated.

(Partial) meniscectomy

For years, the menisci were believed to be vestigial remains of leg muscles. With this principle, a torn meniscus was usually treated by a total meniscectomy. The instantaneous disappearance of impairment and pain observed after such surgery supported the value of this treatment. In the 1970s and 1980s, several studies, however, elucidated the biomechanical effects of a (partial) meniscectomy in cadaveric knees. Contact stresses on the tibial plateau were found to increase proportionally with the amount of meniscus tissue removed [10, 11], illustrating the importance of the meniscus in load bearing and distribution.

Radiographic signs of *in vivo* changes after meniscectomy were already presented in 1948, when Fairbank noticed joint space narrowing and the formation of a ridge that flattened the femoral condyle [12]. Later, a direct relation between meniscus resection and the risk of development of radiographic osteoarthritis (OA) in the long term was established [13–15]. Nevertheless, radiographic OA can only be moderately correlated to the degree of cartilage degeneration observed during arthroscopy [16]. Also the correlation between knee pain and radiographic findings and vice versa is weak [17]. Therefore radiographs should not be used as a single tool to assess patient status after meniscectomy, but should be accompanied by patient-related outcome scores, like the Knee Injury and Osteoarthritis Outcome (KOOS), Tegner activity and Lysholm scores.

Magnetic resonance images of the knee provide additional information on anatomy and composition of both hard and soft tissues, and therefore are increasingly used to assess patient condition after meniscectomy. It should also be mentioned that during development of OA the molecular structure of the meniscus itself may also change [18]. Advanced imaging techniques such as delayed gadolinium-enhanced magnetic resonance imaging of cartilage (dGEMRIC) allow visualisation of the molecular structure of the articular cartilage and of the meniscus and can be used to examine degenerative processes in time in future studies [19].

In the first period post-meniscectomy, patients generally experience pain relief and improved functionality compared

with the pre-surgery situation [20, 21]. Some patients, however, reported persistent pain in the affected joint line, without the presence of a remaining tear. This number increases as follow-up time increases. Hede et al. found Lysholm scores to be fair to poor (score <77) in 14 % of the patients 7.8 years after partial or total meniscectomy [13]. From a retrospective, controlled cohort study using the KOOS questionnaire, 50 % of the patients was found to suffer from symptomatic OA 16 years post-meniscectomy, while 19 % of the control group developed symptomatic knee OA in the same period [22]. No differences were observed between partial or (sub)total meniscectomy. Interestingly, the risk of developing symptomatic OA increased significantly after meniscectomy in the case of a degenerative tear, but not for traumatic lesions [22]. Hence, this chronic patient group in particular may benefit from a meniscal substitute to relieve pain and functional limitations.

Partial meniscal substitutes

For several years, two companies have offered a solution for these patients suffering from a post-meniscectomy syndrome, provided that the peripheral meniscal rim is still intact and cartilage damage is limited. The treatment strategy is similar for the two implants available: upon resection of the damaged tissue the resulting space is filled with a custom-sized, synthetic, porous material, which serves as a scaffold to regenerate meniscus-like tissue. The timing of implantation may either be directly following the meniscectomy or after development of symptoms. Clinical studies are being performed to evaluate efficacy of the collagen meniscus implant (CMI®) and a polyurethane polymeric implant (Actifit®). US Food and Drug Administration (FDA) approval has not been granted for either of the implants, yet both have received the CE mark for use in Europe.

The CMI® is a highly porous scaffold (Fig. 1a) made of type I collagen fibres from purified bovine Achilles tendon (Fig. 1b) which is supplemented with glycosaminoglycans. Animal studies showed that the CMI® is safe to use in a knee joint and stimulates the regeneration of meniscus-like tissue within six months after implantation [23]. In the mid-1990s the first small clinical trial with the CMI® demonstrated no adverse effects in the human knee, formation of new tissue and improved clinical scores 36 months post-implantation [24]. Although the initial trials lacked proper controls to compare the CMI® to traditional treatment standards, recently the outcomes of a prospective randomised clinical trial addressing this comparison were published [25]. A total of 311 partial meniscectomy patients with Outerbridge scores less than grade IV were subdivided into an acute and a chronic injury group and received either the CMI® or partial meniscectomy only. After a mean follow-up of five years, it was shown that the CMI® in medial meniscal defects improves clinical outcomes for chronic patients




Fig. 1 **a** Medial (*left*) and lateral (*right*) CMI[®]. Reprinted with permission of Ivy Sports Medicine GmbH. **b** Scanning electron microscopy image of the CMI[®], clearly showing the collagen laminae. Reprinted from [61]. **c** A 12-month follow-up sagittal MR image of

the CMI[®]. The *white arrow* indicates the boundary of the implant, which has decreased in size compared to the situation directly after surgery. Signal intensity of the implant is distinct from native meniscus tissue. Reprinted from [28]

but has no benefits for acute patients [25]. However, this improvement for chronic patients in comparison to partial meniscectomy patients is based on a 13 %, statistically significant, difference in Tegner index [25]. The other clinical scores reached the same level as in the meniscectomy group. Furthermore, one should question if this difference in Tegner index is clinically relevant and sufficient to support the author's conclusion that clinical outcomes improve for chronic patients receiving the CMI[®].

Zaffagnini and colleagues combined several clinical measures with radiographic and MRI evaluation to compare the CMI[®] to partial meniscectomy at a minimum follow-up of ten years [26]. The patients were not randomised between treatment groups and the outcome of acute and chronic tears was not separately analysed. In contrast to the study by Rodkey et al. [25], this study shows better results for several clinical outcome scores in the CMI[®] group compared to the partial meniscectomy group. Nevertheless, again the clinical significance of the differences was not addressed. Unique in their clinical evaluation of the CMI[®] are the data on joint space narrowing. The considerable difference between the implant group and the non-treated controls suggests that the implant decreases the risk of degenerative changes in the knee [26].

Despite the general observation of improved clinical scores, studies reporting on MRI results of the CMI[®] agree on several aspects. Firstly, the size of the CMI[®] reduced during follow-up [27–29]. Secondly, the signal intensity does not resemble that of the native meniscus, either for short follow-up [27, 28] or for follow-up periods exceeding ten years [26, 29]. Figure 1c and d show a representative MRI of a CMI[®] implanted knee 12 months post-surgery. Based on second-look arthroscopies at a mean of 12.8 months and MR scans at a mean of 19 months, Spencer et al. suggest that the regenerated tissue is not fibrocartilage [27]. Hence, the mechanism of action of the CMI[®] is not fully understood.

The second commercially available scaffold for partial meniscus replacement is the synthetic, porous Actifit[®] implant (Fig. 2a, b). To create an optimal combination of flexibility and mechanical strength, the Actifit[®] implant is built of polyurethane polymers that consist of biodegradable polyester segments combined with semi-degradable stiff segments [30]. The Actifit[®] implant originally was developed to serve as a full meniscus replacement. Based on the results of a dog study a partial implant was considered to be a more suitable application since as a total meniscus replacement the implant could not resist the shear forces in the knee joint and cartilage damage could not be prevented [31, 32]. When implanted in a bovine partial meniscal defect, however, the Actifit[®] implant promoted fibrous tissue ingrowth into the defect site while not damaging the articular cartilage [33]. Moreover, the scaffold improved contact mechanics on the bovine tibial plateau compared to a partial defect situation [34]. Verdonk et al. recently published the first outcomes of a case series involving 52 partial meniscectomy patients with International Cartilage Repair Society (ICRS) cartilage grades less than II receiving the Actifit[®] scaffold with a follow-up period of 24 months [35]. With two exceptions, all patients suffered from post-meniscectomy symptoms. Statistically significant and clinically relevant pain reduction combined with improved functionality and activity were found from six months post-operatively, which are attributed to the regeneration of meniscus-like tissue in the scaffold. These values steadily improved up to the final moment of observation at 24 months. In addition, more than 90 % of the patients showed stabilisation or improvement of the articular cartilage condition, suggesting the implant's protective effect against cartilage degeneration [35]. However, this study did not include a control group with only partial meniscectomy like in the CMI[®] study by Rodkey et al. Although the scores (visual analogue scale pain score, Lysholm score) of the Actifit[®] patients do not seem to vary




Fig. 2 **a** Medial (*top*) and lateral (*bottom*) Actifit® implant. Reprinted with permission of Orteq Sports Medicine. **b** Scanning electron microscopy image of the Actifit® implant, showing the interconnected porous structure of the material. Reprinted from [62]. Sagittal (**c**) and coronal (**d**) proton density MR images of the Actifit® implant, taken

14 months post-surgery. The images show that integrity of the construct is maintained, yet the implant displays a homogeneous oedema-like signal (*black arrow*) in comparison with the native meniscus (*white arrow*). Reprinted from [27]

much from the control patients in the CMI® study, only a proper randomised controlled study could support the additional value of the Actifit® implant.

Although Verdonk et al. collected MRI data, the two-year follow-up publication only reports on cartilage condition [35]. Spencer et al. evaluated sequential MR images of a small cohort of Actifit® implanted patients, taken at a mean of 19 months post-surgery (range six–36) [27]. Upon surgery, no progression of OA was found on subsequent scans. The Actifit® scaffold showed good structural integrity and tissue ingrowth. However, the MRI signal from the regenerated tissue in the scaffold did not suggest differentiation into fibrocartilage but rather demonstrated an oedema-like signal (Fig. 2c, d) which persisted up to 19 months post-surgery [27].

To summarise, the available implants for partial meniscal defects seem safe. For acute irreparable meniscal lesions, the additional value of the CMI® could not be proven. The implants seem to improve the clinical scores in chronic lesions compared to the pre-surgery situation, but if the implanted knee joint indeed functions better than meniscectomised control knees is still doubtful. A prospective randomised study including an Actifit® implant group and a partial meniscectomy group is necessary to assess the added value of this meniscal substitute. Moreover, extended trial periods should elucidate the long-term effects of treatment with the Actifit® implant.

Total meniscal substitutes

Despite the current belief in conserving as much of the damaged meniscus as possible, orthopaedic surgeons still encounter severe lesions that require a complete meniscectomy. Alternatively, patients may undergo several partial resections, resulting in a (sub)total meniscectomy in the end. Sixteen years after subtotal meniscectomy, about 50 % of the patients

were symptomatic compared with 19 % of the controls [22]. These patients require replacement of the meniscus to relieve pain and prevent the progression of OA to more advanced stages. Since the peripheral rim is not intact any more, the load-bearing capacity of a total meniscal substitute should exceed that of partial substitutes greatly.

For several decades, symptomatic total meniscectomy patients with minor cartilage damage have been treated by implantation of a meniscal allograft. Patient-related outcomes have been shown to increase considerably during the first five years of follow-up, yet a decrease of these scores was observed when follow-up periods up to 20 years are reviewed [36]. Ideally, a meniscal allograft would protect the articular cartilage by preventing the progression of OA. There is, however, no data that support the chondroprotective effect of donor menisci in the human knee [36].

Although allograft transplantation is currently the best treatment available for symptomatic meniscectomy patients, problems related to graft availability, size matching, high costs and disease transmission limit the widespread practice of this intervention. Moreover, upon transplantation meniscal allografts were observed to shrink [37] and undergo collagen remodeling [38], which may compromise their mechanical strength. To overcome these issues related to allograft transplantation, research into synthetic, full meniscus replacements has been carried out for several decades now. Up to now, no anatomically shaped synthetic total meniscus replacement has been tested in patients. Recently, the first synthetic meniscus-like implant (NUsurface®) has proceeded to phase 1 clinical trials. Several other approaches are still in the preclinical phase.

Synthetic total meniscal substitutes

Messner et al. were the first to publish a comprehensive series of papers on the potential of Teflon and Dacron biomaterials to

serve as permanent meniscal substitutes [39–41]. Improved designs were extensively tested in a rabbit model. However, the limited pool of biocompatible materials available in the 1990s could not provide the optimal combination of flexibility and strength, and wear resistance, resulting in severe deformation of the implant and deposition of wear particles, accompanied by synovitis and knee joint remodelling [39, 40].

van Tienen et al. explored the capacity of porous polyurethane scaffolds as total meniscal substitutes. Pore size and compressive properties were tuned to stimulate tissue ingrowth and differentiation into fibrocartilaginous tissue based on earlier findings [42, 43]. Six months after implantation in dogs, fibrous tissue had formed in the periphery of the scaffold, but cartilaginous tissue was found in the central region [31]. Compressive properties of the implant increased up to evaluation at 24 months post-implantation and were not different from native meniscus properties [32]. However, the materials were not strong enough to resist the (shear) forces in the knee joint and collagen type and orientation were not meniscus-like, possibly because of a lack of scaffold degradation at 24 months. The combination of these factors might have resulted in the lack of chondroprotectiveness of these polymer implants [32]. Following these results this type of polyurethane scaffold seemed to be more suitable as a partial meniscal substitute, to be used with a remaining peripheral meniscal rim. This partial replacement has been introduced to the market as the Actifit® partial meniscal substitute.

The polyvinyl alcohol (PVA) hydrogel implant of Kobayashi et al. was one of the first non-porous permanent replacement approaches. Compressive strength and viscoelastic behaviour of the material was highly similar to that of the native (human) meniscus, even after two years of implantation in a rabbit knee [44, 45]. The implant proved to be chondroprotective when compared to meniscectomy; however, no sham-operated controls were included to evaluate the influence of the replacement surgery on cartilage condition [45]. In a large animal model, however, the implant caused severe damage to the articular cartilage and benefits in comparison with meniscal allografts could not be proven. Moreover, structural integrity was compromised by complete radial tears in the posterior horn of all implants. It was speculated that the adverse effects were caused by hypermobility of the implant's body [46]. Recently, an American group has renewed interest in PVA hydrogels for meniscal substitution. It has been shown that by the incorporation of polyethylene fibres into the hydrogel both the compressive and tensile moduli of the biomaterial can be tuned to resemble that of the native meniscus [47], which is an important step towards the ability of any meniscus implant to convert compressive loads into hoop stresses.

Kon and co-workers have developed a porous scaffold for total meniscal substitution based on a hyaluronic acid and polycaprolactone matrix augmented with circumferential polylactic acid fibres [48–50]. Culturing autologous chondrocytes

onto the scaffold improved fibrocartilaginous tissue deposition into the implant compared with cell-free constructs. One year post-surgery, the implants contained the progression of cartilage degeneration, unlike meniscectomy. Yet, the cell-seeded scaffolds did not show better cartilage condition than the cell-free-scaffolds [50]. Based on the results of a small number of non-extruded constructs, the authors expect improved outcomes when extrusion of the implants can be prevented [50]. However, this may require a more rigid horn fixation which was associated with implant failure and dislocation in one of their earlier investigations [49].

The anisotropic approach was also followed by an Israeli company that recently started the first clinical trials to evaluate in vivo performance of their polyethylene reinforced polycarbonate urethane (PCU) meniscus implant (NUsurface®, Fig. 3a). Whereas other groups mainly published on the body's biological response to their meniscal prosthesis, this group choose FDA approved PCUs as a starting point and focused on optimisation of the biomechanical response first. The design has been optimised using finite element modelling of the implant's material behaviour and the resultant contact mechanics on the tibial articular cartilage [51]. The computed contact mechanics under the ultimate implant resembled those of an intact human meniscus measured from cadaveric experiments [51, 52]. Subsequent in vivo experiments in a sheep model showed no differences in cartilage condition between the PCU implant and the contralateral control joints up to six months post-operatively [53]. However, Mankin scores of these non-operated controls were relatively high compared to earlier reported values [54], and it would be interesting to see if the chondroprotective effect is prolonged upon long-term implantation. Moreover, results of only three animals were presented at each time point, which in our opinion is not sufficient to draw conclusions regarding the effectiveness of this implant. The most surprising aspect of the design process of the NUsurface® implant is the large difference between the sheep and human implant geometry and fixation strategy. While the sheep implant is anatomically shaped and supplemented with fixation bolts to secure the horns to the tibia (Fig. 3b), the human version is disc shaped and free-floating (Fig. 3a) [51, 53]. Arguments for this change were not provided in the literature and no publications are available describing the effects of the free-floating implant in animal studies. The first clinical results may be expected within the next two years, yet some preliminary MR images show restoration of the joint space and maintenance of cartilage signal intensity at 12 months post-surgery (Fig. 3c).

Future directions in meniscus replacement

Meniscus replacement remains an incessantly popular topic in the scientific literature. Advancements of the last decade

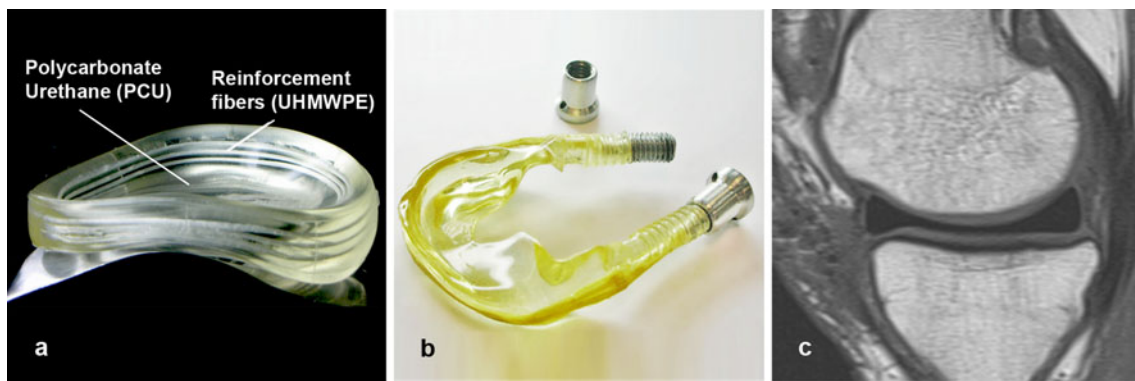


Fig. 3 **a** Disc-shaped, free-floating NUsurface® total meniscal prosthesis for replacement of the human medial meniscus. The image shows the orientation of the ring-shaped fibre bundles inside the bulk material. Reprinted from [52]. **b** Anatomically shaped version of the NUsurface® total meniscal prosthesis, including fixation bolts at both

horns. Reprinted from [53]. **c** A 12-month follow-up sagittal MR image of the NUsurface® meniscal replacement. Joint space has been restored with respect to the preoperative situation; the image does not show signs of cartilage pathologies. Reprinted with permission of Active Implants Corporation

have resulted in several implants that are now being subjected to the process of clinical evaluation. However, results keep on indicating that the substitutes still require improvement to optimally mimic native meniscus functioning and new approaches are constantly being investigated.

Synthetic partial and total meniscal substitutes

Several groups are continuously seeking for the right combination of material (properties), geometry and boundary conditions like fixation and tribological characteristics, in order to develop a synthetic meniscal substitute that has the ability to optimally mimic the function of the native meniscus. In the recent literature, the publications on clinical outcomes of the CMI® and Actifit® implants have drawn major attention. Additionally, a few new concepts have been developed over the last five years, which are in different stages of evaluation.

Publications on the design and testing processes of the disc-shaped, free-floating NUsurface® implant all originate from recent years [51–53]. The short span of time of these publications and the fact that the implant has already proceeded to phase I clinical trials illustrate the high speed at which progress can be made with synthetic implants that do not require tissue regeneration.

Balint et al. developed a fibrous scaffold for total meniscus replacement and subsequent tissue regeneration. The implant, composed of quasi-circumferentially wrapped collagen-polymeric fibres, is able to convert applied compressive loads into tensile hoop stresses, which is an important characteristic of native meniscus functioning [55, 56]. However, the lack of a supportive bulk material seems to result in compressive properties that are considerably inferior to native meniscus tissue, although only preliminary data have been provided on compressive testing and contact pressure analysis [55].

Recently, the first results on silk scaffolds for (partial) meniscal regeneration were published [57–59]. Improvement of the scaffold's mechanical properties to resemble those of the native meniscus seems to be the largest challenge. Mandal et al. published on a multilayered silk scaffold for total meniscus tissue engineering. Compressive moduli of the distinct scaffold layers exceed those of the native meniscus, yet the tensile moduli are still lower by a factor of 50–100 [57]. Although from their publication it is unclear whether they aim at partial or total meniscal substitution, in our opinion the mechanical properties of this scaffold are by far not sufficient for a total meniscus replacement. In vivo regeneration of meniscus tissue in a different partial defect silk scaffold (FibroFix™) does increase its compressive modulus towards that of the native meniscus, yet the tensile properties of the scaffold were not reported [58].

Many other research groups may be working on individual aspects of meniscus implants, like balancing scaffold porosity and material properties, improving tissue infiltration or designing fixation strategies for optimal integration with the surrounding tissues. Results of this work are not included since the authors have chosen to limit the content of this paper to full implants that have been functionally tested.

Preclinical testing platforms

Resembling the native biomechanical characteristics seems to be the key factor in (partial) meniscus replacement functioning that remains challenging and requires early attention during the development process. When reviewing the literature, however, biomechanical functioning of meniscus implants has been given too little attention compared to the biological responses, making it difficult to identify the parameters that are crucial for successful implant functioning. Maher et al.

suggest a preclinical pathway integrating *in vitro*, *in vivo* and *in silico* models for a complete functional evaluation of meniscal substitutes [60]. Pressure distribution and magnitude can be studied in cadaveric knee joints. Additional *in vitro* tests should elucidate the frictional behaviour of the implant material against cartilage. Biocompatibility, long-term fixation strength and wear of the implant material and surrounding cartilage can only be studied in *in vivo* animal models. Output data of this full set of experiments then serve as validation for finite element models which subsequently are employed to study changes to the implant design [60]. Once such a trajectory of preclinical assessment has resulted in a prosthesis that has successfully undergone all tests, a firm foundation has been laid to start phase 1 clinical trials. In our opinion such extensive preclinical screening of novel implants should be adopted by all investigators involved in the development of meniscal substitutes, in order to provide well-founded arguments for the introduction of new implants to the market.

The TRAMMPOLIN total meniscus substitute

Over the past few years, the authors of this paper have been part of a Dutch national consortium (TRAMMPOLIN) developing an anatomically shaped, non-resorbable total meniscus substitute. The consortium combines the knowledge of material scientists, tribological experts, biomechanical engineers, biologists and surgeons to optimally tune the design of the implant. The aspects determining implant functioning (material properties, geometry, fixation and surface characteristics) have been separately studied *in vitro* and *in silico* to closely match native meniscus properties and are combined in the full implant design. *In vitro* cadaveric tests are being performed to evaluate the implant's ability to restore contact mechanics and rotational stability of the knee joint. At the same time kinematics of the prosthesis will be recorded. Furthermore, a four-arm animal study is planned to assess implant performance under long-term loading conditions together with its chondroprotective capacity. The outcome of the implanted group will be compared to a meniscectomy group, an allograft group and a sham-operated control group. The contralateral joints will serve as non-operated controls. Results of these studies may be expected during the coming years.

Conclusion

Over the past few decades, a wide range of therapeutic strategies has been developed to treat meniscal injuries. Although not part of this review, the repair of a lesion with functional tissue may be the ultimate solution for the prevention of OA associated with meniscus pathology. Proposed strategies comprise a wide range of approaches: *in vitro*, scaffold-free or scaffold-based tissue engineering concepts, in which various

cell types can be used (e.g. meniscus fibroblasts, chondrocytes, stem cells, stroma cells or mixtures of these), *in vivo* tissue engineering approaches that rely on the regenerative capacity of the human body to populate resorbable scaffolds with meniscus-like tissue or permanent non-resorbable implants. Irrespective of the method used, the molecular composition and organisation of load-bearing tissues in particular has proven to be extremely difficult to duplicate, making progress in the tissue engineering and regenerative field rather slow compared to the development of synthetic prostheses. In our opinion, a starting point might be to gain more experience with non-resorbable, non-porous meniscus replacements to collect data on the baseline requirements of the implant for survival in the knee joint. From this point on, improvements can be made in several directions: development of non-degradable porous implants and eventually biodegradable porous implants relying on tissue ingrowths and remodelling during resorption of the implant material.

The interest in research on the meniscus is growing, considering the substantial increase of papers published on this subject. However, the fact that there are as yet no anatomically based implants to replace the entire meniscus and only three meniscus replacements available for clinical use (Actifit[®], CMI[®] and NUsurface[®]) proves the challenging environment of the knee in which the implant has to survive. Despite the widespread support for the use of these new implants, we have to remain critical with regard to whether the activities of daily life of implanted patients really improve. Only thorough preclinical testing and decent randomised controlled trials can supply us with data that prove the additional value of new developments. Nevertheless, all scientific output on the development and testing of meniscus replacements provides a wealth of experience to be used to design the ideal meniscal substitute.

Acknowledgements This publication forms part of the Project P2.03 TRAMMPOLIN of the research program of the BioMedical Materials Institute, co-funded by the Dutch Ministry of Economic Affairs, Agriculture and Innovation.

Conflict of interest The authors declare that they have no conflict of interest.

References

1. Nielsen AB, Yde J (1991) Epidemiology of acute knee injuries: a prospective hospital investigation. *J Trauma* 31(12):1644–1648
2. Lauder TD, Baker SP, Smith GS et al (2000) Sports and physical training injury hospitalizations in the army. *Am J Prev Med* 18(3 Suppl):118–128
3. Majewski M, Susanne H, Klaus S (2006) Epidemiology of athletic knee injuries: a 10-year study. *Knee* 13(3):184–188
4. Jones JC, Burks R, Owens BD et al (2012) Incidence and risk factors associated with meniscal injuries among active-duty US military service members. *J Athl Train* 47(1):67–73

5. Noble J, Hamblen DL (1975) The pathology of the degenerate meniscus lesion. *J Bone Joint Surg Br* 57(2):180–186
6. Poehling GG, Ruch DS, Chabon SJ (1990) The landscape of meniscal injuries. *Clin Sports Med* 9(3):539–549
7. Arendt EA (ed) (1999) Orthopaedic knowledge update: sports medicine 2. American Academy of Orthopaedic Surgeons, Rosemont
8. Rubman MH, Noyes FR, Barber-Westin SD (1998) Arthroscopic repair of meniscal tears that extend into the avascular zone. A review of 198 single and complex tears. *Am J Sports Med* 26(1):87–95
9. Ahn JH, Lee YS, Yoo JC et al (2010) Clinical and second-look arthroscopic evaluation of repaired medial meniscus in anterior cruciate ligament-reconstructed knees. *Am J Sports Med* 38(3):472–477
10. Ahmed AM, Burke DL (1983) In-vitro measurement of static pressure distribution in synovial joints—part I: tibial surface of the knee. *J Biomech Eng* 105(3):216–225
11. Baratz ME, Fu FH, Mengato R (1986) Meniscal tears: the effect of meniscectomy and of repair on intraarticular contact areas and stress in the human knee. A preliminary report. *Am J Sports Med* 14(4):270–275
12. Fairbank TJ (1948) Knee joint changes after meniscectomy. *J Bone Joint Surg Br* 30-B(4):664–670
13. Hede A, Larsen E, Sandberg H (1992) The long term outcome of open total and partial meniscectomy related to the quantity and site of the meniscus removed. *Int Orthop* 16(2):122–125
14. Roos H, Laurén M, Adalberth T et al (1998) Knee osteoarthritis after meniscectomy: prevalence of radiographic changes after twenty-one years, compared with matched controls. *Arthritis Rheum* 41(4):687–693
15. Englund M, Lohmander LS (2004) Risk factors for symptomatic knee osteoarthritis fifteen to twenty-two years after meniscectomy. *Arthritis Rheum* 50(9):2811–2819
16. Kijowski R, Blankenbaker D, Stanton P et al (2006) Arthroscopic validation of radiographic grading scales of osteoarthritis of the tibiofemoral joint. *AJR Am J Roentgenol* 187(3):794–799
17. Bedson J, Croft PR (2008) The discordance between clinical and radiographic knee osteoarthritis: a systematic search and summary of the literature. *BMC Musculoskelet Disord* 9:116
18. Hellio Le Graverand MP, Vignon E, Otterness IG et al (2001) Early changes in lapine menisci during osteoarthritis development: part II: molecular alterations. *Osteoarthritis Cartilage* 9(1):65–72
19. Krishnan N, Shetty SK, Williams A et al (2007) Delayed gadolinium-enhanced magnetic resonance imaging of the meniscus: an index of meniscal tissue degeneration? *Arthritis Rheum* 56(5):1507–1511
20. Hede A, Larsen E, Sandberg H (1992) Partial versus total meniscectomy. A prospective, randomised study with long-term follow-up. *J Bone Joint Surg Br* 74(1):118–121
21. Schimmer RC, Brühlhart KB, Duff C et al (1998) Arthroscopic partial meniscectomy: a 12-year follow-up and two-step evaluation of the long-term course. *Arthroscopy* 14(2):136–142
22. Englund M, Roos EM, Lohmander LS (2003) Impact of type of meniscal tear on radiographic and symptomatic knee osteoarthritis: a sixteen-year followup of meniscectomy with matched controls. *Arthritis Rheum* 48(8):2178–2187
23. Stone KR, Rodkey WG, Webber R et al (1992) Meniscal regeneration with copolymeric collagen scaffolds. In vitro and in vivo studies evaluated clinically, histologically, and biochemically. *Am J Sports Med* 20(2):104–111
24. Stone KR, Steadman JR, Rodkey WG et al (1997) Regeneration of meniscal cartilage with use of a collagen scaffold. Analysis of preliminary data. *J Bone Joint Surg Am* 79(12):1770–1777
25. Rodkey WG, DeHaven KE, Montgomery WH 3rd et al (2008) Comparison of the collagen meniscus implant with partial meniscectomy. A prospective randomized trial. *J Bone Joint Surg Am* 90(7):1413–1426
26. Zaffagnini S, Marcheggiani Muccioli GM, Lopomo N et al (2011) Prospective long-term outcomes of the medial collagen meniscus implant versus partial medial meniscectomy: a minimum 10-year follow-up study. *Am J Sports Med* 39(5):977–985
27. Spencer SJ, Saithna A, Carmont MR et al (2012) Meniscal scaffolds: early experience and review of the literature. *Knee*. doi:10.1016/j.knee.2012.01.006
28. Genovese E, Angeretti MG, Ronga M et al (2007) Follow-up of collagen meniscus implants by MRI. *Radiol Med* 112(7):1036–1048
29. Monllau JC, Gelber PE, Abat F et al (2011) Outcome after partial medial meniscus substitution with the collagen meniscal implant at a minimum of 10 years' follow-up. *Arthroscopy* 27(7):933–943
30. Groot JD (2010) Actifit, polyurethane meniscus implant: basic science. *The meniscus*. Springer, Berlin
31. Tienen TG, Heijkants RG, de Groot JH et al (2006) Replacement of the knee meniscus by a porous polymer implant: a study in dogs. *Am J Sports Med* 34(1):64–71
32. Welsing RT, van Tienen TG, Ramrattan N et al (2008) Effect on tissue differentiation and articular cartilage degradation of a polymer meniscus implant: a 2-year follow-up study in dogs. *Am J Sports Med* 36(10):1978–1989
33. Maher SA, Rodeo SA, Doty SB et al (2010) Evaluation of a porous polyurethane scaffold in a partial meniscal defect ovine model. *Arthroscopy* 26(11):1510–1519
34. Brophy RH, Cottrell J, Rodeo SA et al (2010) Implantation of a synthetic meniscal scaffold improves joint contact mechanics in a partial meniscectomy cadaver model. *J Biomed Mater Res A* 92(3):1154–1161
35. Verdonk P, Beaufils P, Bellemans J et al (2012) Successful treatment of painful irreparable partial meniscal defects with a polyurethane scaffold: two-year safety and clinical outcomes. *Am J Sports Med* 40(4):844–853
36. Elattar M, Dhollander A, Verdonk R et al (2011) Twenty-six years of meniscal allograft transplantation: is it still experimental? A meta-analysis of 44 trials. *Knee Surg Sports Traumatol Arthrosc* 19(2):147–157
37. Lee BS, Chung JW, Kim JM et al (2012) Morphologic changes in fresh-frozen meniscus allografts over 1 year: a prospective magnetic resonance imaging study on the width and thickness of transplants. *Am J Sports Med* 40(6):1384–1391
38. Wada Y, Amiel M, Harwood F et al (1998) Architectural remodeling in deep frozen meniscal allografts after total meniscectomy. *Arthroscopy* 14(3):250–257
39. Messner K, Lohmander LS, Gillquist J (1993) Cartilage mechanics and morphology, synovitis and proteoglycan fragments in rabbit joint fluid after prosthetic meniscal substitution. *Biomaterials* 14(3):163–168
40. Messner K (1994) Meniscal substitution with a Teflon-periosteal composite graft: a rabbit experiment. *Biomaterials* 15(3):223–230
41. Sommerlath K, Gallino M, Gillquist J (1992) Biomechanical characteristics of different artificial substitutes for rabbit medial meniscus and effect of prosthesis size on knee cartilage. *Clin Biomech (Bristol, Avon)* 7:97–103
42. Klompmaker J, Jansen HW, Veth RP et al (1993) Porous implants for knee joint meniscus reconstruction: a preliminary study on the role of pore sizes in ingrowth and differentiation of fibrocartilage. *Clin Mater* 14(1):1–11
43. Tienen TG, Heijkants RG, de Groot JH et al (2006) Meniscal replacement in dogs. Tissue regeneration in two different materials with similar properties. *J Biomed Mater Res B Appl Biomater* 76(2):389–396
44. Kobayashi M, Toguchida J, Oka M (2003) Preliminary study of polyvinyl alcohol-hydrogel (PVA-H) artificial meniscus. *Biomaterials* 24(4):639–647
45. Kobayashi M, Chang YS, Oka M (2005) A two year in vivo study of polyvinyl alcohol-hydrogel (PVA-H) artificial meniscus. *Biomaterials* 26(16):3243–3248

46. Kelly BT, Robertson W, Potter HG et al (2007) Hydrogel meniscal replacement in the sheep knee: preliminary evaluation of chondroprotective effects. *Am J Sports Med* 35(1):43–52
47. Holloway JL, Lowman AM, Palmese GR (2010) Mechanical evaluation of poly(vinyl alcohol)-based fibrous composites as biomaterials for meniscal tissue replacement. *Acta Biomater* 6(12):4716–4724
48. Chiari C, Koller U, Dorotka R et al (2006) A tissue engineering approach to meniscus regeneration in a sheep model. *Osteoarthritis Cartilage* 14(10):1056–1065
49. Kon E, Chiari C, Marcacci M et al (2008) Tissue engineering for total meniscal substitution: animal study in sheep model. *Tissue Eng Part A* 14(6):1067–1080
50. Kon E, Filardo G, Tschon M et al (2012) Tissue engineering for total meniscal substitution: animal study in sheep model—results at 12 months. *Tissue Eng Part A* 18(15–16):1573–1582
51. Elsner JJ, Portnoy S, Zur G et al (2010) Design of a free-floating polycarbonate-urethane meniscal implant using finite element modeling and experimental validation. *J Biomech Eng* 132(9):095001
52. Linder-Ganz E, Elsner JJ, Danino A et al (2010) A novel quantitative approach for evaluating contact mechanics of meniscal replacements. *J Biomech Eng* 132(2):024501
53. Zur G, Linder-Ganz E, Elsner JJ et al (2010) Chondroprotective effects of a polycarbonate-urethane meniscal implant: histopathological results in a sheep model. *Knee Surg Sports Traumatol Arthrosc* 19(2):255–263
54. Kelly BT, Potter HG, Deng XH et al (2006) Meniscal allograft transplantation in the sheep knee: evaluation of chondroprotective effects. *Am J Sports Med* 34(9):1464–1477
55. Balint E (2009) Development of a fiber-reinforced meniscus scaffold. The State University of New Jersey/University of Medicine and Dentistry of New Jersey, New Brunswick
56. Balint E, Gatt CJ Jr, Dunn MG (2011) Design and mechanical evaluation of a novel fiber-reinforced scaffold for meniscus replacement. *J Biomed Mater Res A* 100(1):195–202
57. Mandal BB, Park SH, Gil ES et al (2011) Multilayered silk scaffolds for meniscus tissue engineering. *Biomaterials* 32(2):639–651
58. Dürselen L, Gruchenberg K, Friemert B et al (2012) In vivo performance of a silk derived scaffold (FibroFix™) for partial meniscal replacement in an ovine model. Paper No. 0218, *Trans Annu Meet Orthop Res Soc*
59. Yan LP, Oliveira JM, Oliveira AL et al (2012) Macro/microporous silk fibroin scaffolds with potential for articular cartilage and meniscus tissue engineering applications. *Acta Biomater* 8(1):289–301
60. Maher SA, Rodeo SA, Potter HG et al (2011) A pre-clinical test platform for the functional evaluation of scaffolds for musculoskeletal defects: the meniscus. *HSS J* 7(2):157–163
61. Reguzzoni M, Manelli A, Ronga M et al (2005) Histology and ultrastructure of a tissue-engineered collagen meniscus before and after implantation. *J Biomed Mater Res B Appl Biomater* 74(2):808–816
62. Hannink G, van Tienen TG, Schouten AJ et al (2010) Changes in articular cartilage after meniscectomy and meniscus replacement using a biodegradable porous polymer implant. *Knee Surg Sports Traumatol Arthrosc* 19(3):441–451