

Article

Osteological Evidence of Possible Tuberculosis from the Early Medieval Age (6th–11th Century), Northern Italy

Omar Larentis *, Caterina Pangrazzi and Enrica Tonina

Centre of Research in Osteoarchaeology and Paleopathology, Department of Biotechnologies and Life Sciences, University of Insubria, 21100 Varese, Italy; caterina.pangrazzi@uninsubria.it (C.P.); enrica.tonina@uninsubria.it (E.T.)

* Correspondence: omar.larentis@uninsubria.it

Abstract: We discuss the probable presence of tuberculosis in non-adults of a medieval rural community in northern Italy with a biocultural perspective. Before birth, mother and child have a closely interconnected relationship, as suggested by the role of microchimerism on maternal health. To better understand maternal–child health and related stress factors, paleopathology has investigated the potential of this relationship in recent years. Diseases with environmental development factors such as infections depend on and are strongly affected by maternal control variables such as, for example, breastfeeding and the growth environment. This article presents ISZ2, the second possible case of childhood tuberculosis identified in northeastern Italy through recent paleopathological criteria. The subject is of primary importance as it not only represents a direct testimony of this infectious disease otherwise known only from historical sources, but also increases our knowledge on the state of health of infants in this area, which to date are scarcely analyzed.

Keywords: infectious disease; tuberculosis; children; paleopathology; bioarchaeology; Middle Ages; Italy

Citation: Larentis, O.; Pangrazzi, C.; Tonina, E. Osteological Evidence of Possible Tuberculosis from the Early Medieval Age (6th–11th Century), Northern Italy. *Heritage* **2023**, *6*, 4886–4900. <https://doi.org/10.3390/heritage6070260>

Academic Editor: Arlen F. Chase

Received: 21 May 2023

Revised: 15 June 2023

Accepted: 19 June 2023

Published: 21 June 2023



Copyright: © 2023 by the authors. Submitted for possible open access publication under the terms and conditions of the Creative Commons Attribution (CC BY) license (<https://creativecommons.org/licenses/by/4.0/>).

1. Introduction

The relationship between a mother and her child during pregnancy is a complex and mutually influential system characterized by various factors. One such factor, microchimerism, has been a subject of analysis and debate within the scientific community for decades [1,2]. This intricate exchange involves cellular and micronutrient interactions, as the mother provides these resources to support the child’s development. It is well-established that maternal malnutrition can have long-term effects on fetal well-being [3–6]. Interestingly, the mother’s immune system recognizes the fetus as a “temporary self,” protecting it during pregnancy [7,8]. These notions have led to the development of the Mother–Infant Nexus concept in bioarchaeology, highlighting the interdependent physiological and social relationship between mothers and infants [9]. This relationship holds significant value in paleopathology.

Among the various disciplines within bioarchaeology, paleopathology focuses on examining physical evidence of diseases in human remains [10]. However, the analysis of fetal and child remains in archaeological contexts presents challenges due to their scarcity. Nonetheless, these remains have gained increasing importance in recent years as they offer insights into the health status of mothers [9,11,12]. Establishing paleopathological information directly attributable to mothers is complex, as definitively identifying a woman as a mother from an anthropological standpoint remains a topic of ongoing discussion. The identification of “birth markers” still faces uncertainties [13], and one of the few reliable methods to confirm a woman’s pregnancy is by finding cases of post-mortem fetal extrusion [14]. However, other pathological conditions can provide valuable information about the mother’s health, her environment, and the growth strategies of infants,

including infectious diseases such as tuberculosis (TB) [15]. In paleopathology, the study of non-adult individuals holds significant potential when considering the broader relational system in which a child existed. Consequently, the results can provide important insights into the quality of life and health conditions within the maternal environment.

Based on these considerations, we present a probable case of TB in a non-adult individual from the Late Middle Ages in Italy. The region of Northern Italy still lacks sufficient information on the prevalence, economic impact, and social consequences of this pathology [16,17].

1.1. Tuberculosis in Non-Adults

TB is a bacterial respiratory disease caused by the *Mycobacterium tuberculosis* complex. It is primarily transmitted from person to person through the inhalation of bacteria-containing droplets expelled by an infected individual [18]. TB affects people from all social groups, age ranges, and countries. The Global Tuberculosis Report of 2022 [19] reported 10.6 million new cases of TB in 2021, with the highest prevalence observed in Southeast Asia (45%), Africa (23%), and the Western Pacific region (18%). Approximately 11% of these new cases are non-adults under the age of 16, including 1.6 million children under the age of 5.

TB can manifest in various forms within the skeletal system of both adults and non-adults, leading to bone formation and destruction. The clinical and paleopathological diagnosis often focuses on skeletal traits in the thoracic and lumbar regions of the spine [10,20,21]. In the field of paleopathology, several nonspecific lesions have been identified in the post-cranial skeleton of both adult and non-adult individuals [22–24]. These include new bone formation on the inner surface of the skull, the visceral surface of the ribs, and long bones, as well as calcified pleura, septic arthritis of the hip and knee, and tuberculous dactylitis affecting the hands and feet [24–31]. Table 1 presents a literature review of non-adult individuals in Italy with evidence of TB, spanning from the 6th millennium BCE to the Modern era.

Table 1. Non-adult subjects with probable TB from Italy; individuals are ordered chronologically.

| Site | Region | Chronology | n ID/Sex | Age |
|----------------------|---------------------|--|------------|----------------------------|
| Pollera Cave [32,33] | Liguria | C14 date: 5730 ± 30 BP; 4624–4455 BCE (2σ) | 1/- | 5 years |
| Arene Candide [34] | Liguria | C14 date: 1st half of 4th millennium BCE | 1/M | 15 years |
| Tassullo [35] | Trentino Alto-Adige | 6th–11th century CE | 1/- | 9 months |
| Parma [20] | Emilia Romagna | 19th–20th century CE | 4/F 4/M | 17–20 years 17–20 years |

1.2. Historical and Archaeological Background

The Immacolata and San Zenone Church (hereafter referred to as ISZ) is in the western part of the Trento province in northeastern Italy (Figure 1). It is a small church characterized by a single rectangular nave, a chapel, and a modest bell tower. While the precise date of its construction remains uncertain, there are historical documents that attest to its antiquity. The earliest recorded evidence of the church, dedicated to the Madonna, dates to 1360. In 1537, the church was additionally dedicated to San Zenone, and it has since been known by its current name.

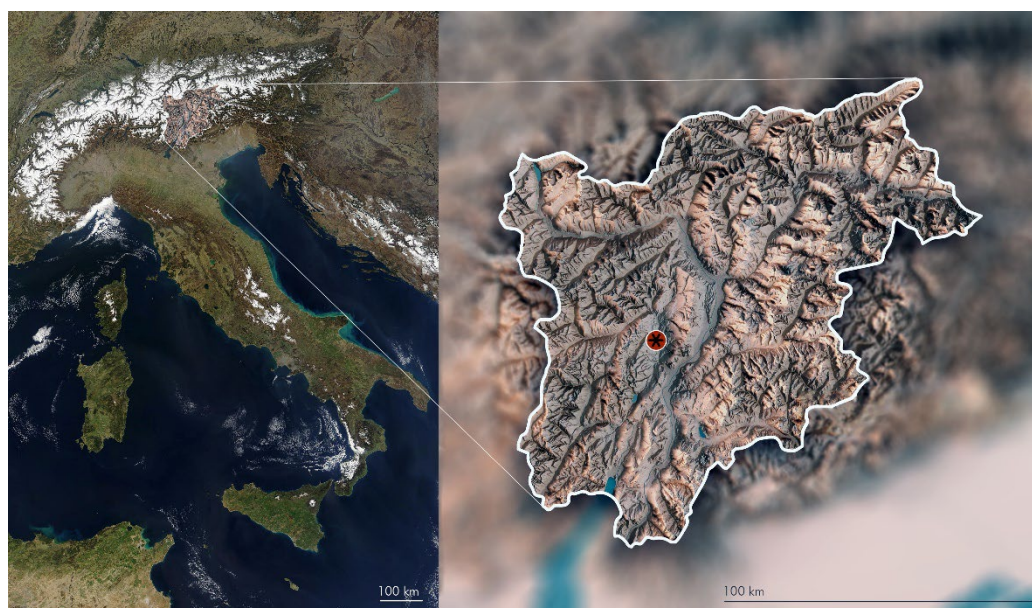


Figure 1. The Immacolata and San Zenone church is in Tassullo, in the province of Trento, in the northeastern part of Italy.

Between 2003 and 2004, the Immacolata and San Zenone church underwent restoration under the scientific direction of the Soprintendenza per i Beni Culturali of Trento province. During this restoration, the floor was removed to install a dehumidification system, which provided archaeologists with an opportunity to gather valuable historical information about the building. The excavation revealed the presence of earlier religious structures dating back to the Early Middle Ages [35]. Inside the nave, archaeologists discovered the remains of an Early Middle Age cemetery, which constitutes the oldest archaeological evidence found in the church. The dating of these burials was made possible through the analysis of grave goods found in the tombs. Among the findings, there were four masonry tombs sealed with stone slabs, as well as other burials in earth pits. The skeleton discussed in this paper is derived from one of the unstructured graves, referred to as Immacolata San Zenone Individual 2 (ISZ2) (Figure 2a). The analysis of the grave goods suggests that the individuals buried in this area lived between the 6th and 11th centuries CE.

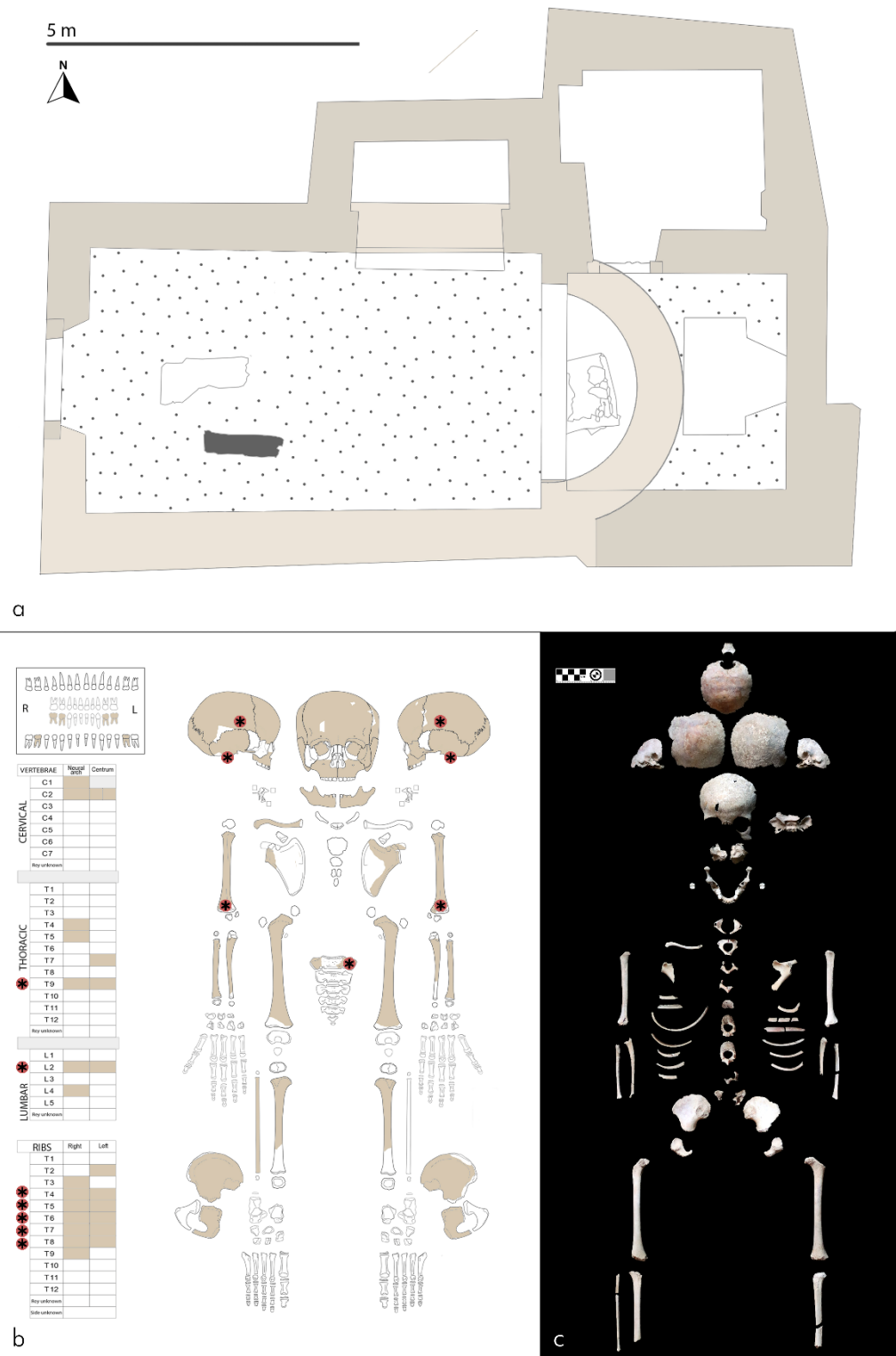


Figure 2. (a) The burial of ISZ2 was discovered in the nave of the church, and it is indicated in the building’s plan by a dark gray filling. The lighter walls in the plan represent the older phases of the building, while the darker ones represent later modifications. (b) A diagrammatic illustration of the skeleton of ISZ2 is provided. Intentionally blank spaces indicate missing parts, while the preserved bones are marked in ochre. Certain bones that display morphological changes, possibly associated with tuberculosis, are highlighted with red asterisks. (c) A photograph of the skeleton of ISZ2 is also included.

2. Materials and Methods

ISZ2 is a skeleton that is well preserved, although some elements may be fragmented or missing. Taphonomic processes have not compromised the evaluation of the bone tissue (Figure 2b,c). In the case at hand, the presence of skeletal lesions suggestive of tuberculosis (TB) and potential comorbidities should be assessed with caution to exclude pseudopathological explanations. Pseudopathological conditions that could mimic TB lesions include postmortem damage, post-depositional changes, or non-specific bone remodeling unrelated to any pathological process. We determined the skeletal age by assessing epiphyseal bone fusion [36] and teeth mineralization degree [37,38] considering their limited susceptibility to nutritional stress and diseases [39,40]. Due to the individual's immaturity, we did not attempt to determine the sex. We conducted macroscopic examination of the bones using both the naked eye and a magnifying glass. Furthermore, we radiologically analyzed the bones at the Gaetano and Piera Borghi private clinic in Brebbia, Italy when the necessary equipment was unavailable to patients. We used conventional medical radiological equipment, including X-ray and CT examinations (GE Healthcare Revolution—GSI 128 Layers). The imaging parameters were as follows: 100 kV, 80 mA. We applied a slice thickness of 0.625 mm to all the pieces reconstructed at 3 mm. We processed the acquired images using Mango software (Research Imaging Institute, UTHSCSA) and Radiant DICOM 5.0.2 Viewer (Medixant, Poznan-Poland) [41]. We documented and analyzed the pathological bone changes considering both paleopathological and clinical literature. We assessed abnormal bone loss or formation according to anthropological standards [42] and proposed a comprehensive analysis of the lesions based on the research of Mariotti and colleagues [20].

Ethical Statement

The Soprintendenza per i Beni Culturali—Trento province has archived ISZ2 in their deposits, and they granted access to the ISZ sample under the authorization of the Soprintendenza with reference number S120/2020/n. 25.4-2020-52/NP. Italian legislation does not require an ethics committee opinion for analyzing archaeological human remains. We conducted the analyses in compliance with the guidelines provided by the Istituto Centrale per l'Archeologia (ICA), the Istituto Centrale per il Catalogo e la Documentazione (ICCD) and Squires and colleagues [43]. Importantly, we performed all analyses non-destructively to preserve the integrity of the remains for possible future studies.

3. Results

ISZ2 is an individual of undetermined sex, approximately 3 years old with an age range of ± 12 months. The skeleton exhibits a high degree of completeness, and the excellent preservation of the bones indicates minimal taphonomic and diagenetic alterations, ensuring the reliability of our analysis (Figure 2b,c). Pathological lesions are observed in the skull, spine, sacrum, ribs, and upper appendicular skeleton, as indicated by the presence of red markers in Figure 2b.

The parietal bones display bilateral endocranial surface grooves (R area = 2.5×3.2 cm; L area = 1.8×3.3 cm) without diploic and ectocranial diffusion (Figure 3a,b,d). These grooves are located near the sulcus of the anterior branch of the middle meningeal artery (Figure 3c). The pars basilaris exhibits a groove ($12.3 \times 4.2 \times 1.7$ mm) with slightly curved margins and finely pitted erosion on the inner surface, representing the site of the basilar artery (Figure 3e). Moreover, reactive bone is observed at the insertions of the rectus anterior capitis and longus capitis muscles, evidenced by cortical tissue overlapping (Figure 3f). Radiological imaging reveals extensive areas of bone rarefaction, along with smaller regions of denser bone near the lateral angle (Figure 4a).

The humeral olecranon fossae exhibit bone erosion and multiple perforations, creating connections between the cortical bone and the medullary cavity (Figure 3g). Bilateral

periostosis is present on the visceral surface of the ribs from the fourth to the ninth rib, with a maximum thickness of 1.2 mm (Figure 3h).

Pathological changes also affect the thoracic and lumbar vertebrae. T9 and L2 display enlarged canals for the basivertebral vein near the anterior internal plexus (Figure 3l). Through computed tomography (CT) imaging, dense cortical tissue, and the continuation of the grooves within the vertebral body are observed (Figure 4b,c). Additionally, enlarged foramina are evident on the lateral aspects of the thoracic and lumbar vertebrae, connected to cavities that are visible on CT and extend within the vertebral body (Figure 4b,c). For a comprehensive list of evidence related to the foramina of the vertebrae, please refer to Table 2.




Figure 3. The skeletal analysis of ISZ2 reveals several pathological features in specific bones. The right parietal bone displays endocranial surface grooves (a,b,d) near the sulcus of the anterior branch of the middle meningeal artery (c). The pars basilaris exhibits a groove with fine pitted erosion on the inner surface (e), along with the presence of reactive bone near the insertions of the rectus anterior capitis and longus capitis muscles (f). Furthermore, the right humeral olecranon fossa shows evidence of erosion and perforations (g). Periostosis, characterized by increased bone formation, is observed on the visceral surface of the fourth rib (h). In addition, there is a lack of trabecular bone substance in the left S1 ala (i). The vertebral column reveals an enlarged canal for the basivertebral vein in L2 (l) and enlarged foramina on the lateral aspect of T9 (m,n).

Table 2. P/E (periosteal/outer cortical surface)—lesions observed on the outer surface of the cortex; C/D (cortex/diploe)—lesions affecting the cortex excluding the outer surface or the diploe region; Es/T/It (endosteal surface/trabeculae/internal table)—lesions present on the endosteal surface, trabecular bone, or internal table; NP (not present)—absence of lesions in the specific location. The bone lesions are further categorized based on their characteristics: ER (erosion)—areas of bone loss or erosion; EnF (Enlarged foramina)—increased size or enlargement of the foramina. The data are divided into the right (R) and left (L) sides, and measurements are reported in millimeters (mm).

| Vertebra | Side Location [42] | Bone Location [42] | Extent of Involvement [42] | Number of Foci [42] | Trait Observed [20] | Size of Lesion [20] |
|----------|--------------------|--------------------|----------------------------|---------------------|---------------------|---------------------|
| T7 | Lateral R | P/E | <1/3 | 1 | OtF | <3 mm |
| | Lateral L | NP | NP | 2 | Er (1) OtF (1) | <3 mm |
| T9 | Lateral R | P/E | <1/3 | 5 | ER (3) OtF (2) | <3 mm |
| | Lateral L | P/E | <1/3 | 3 | ER (3) | <3 mm |
| L2 | Lateral R | P/E | <1/3 | 4 | ER (2) OtF (2) | <3 mm |
| | Lateral L | P/E | <1/3 | 3 | ER (1) OtF (2) | <3 mm |

Furthermore, the radiological acquisition reveals the presence of ovoid erosive lesions that are heterogeneously distributed within the vertebral bodies (Figure 4b,c, marked with blue circles). Additionally, diffuse nodules of dense bone are observed in the vertebral bodies of the thoracic region (Figure 4b,c, marked with yellow circles). Lastly, a profound bilateral erosion is identified, affecting the cortical bone tissue of the sacrum wings. This lytic evidence extends to the internal portion of the wings, characterized by the absence of trabecular bone substance (Figure 3i).

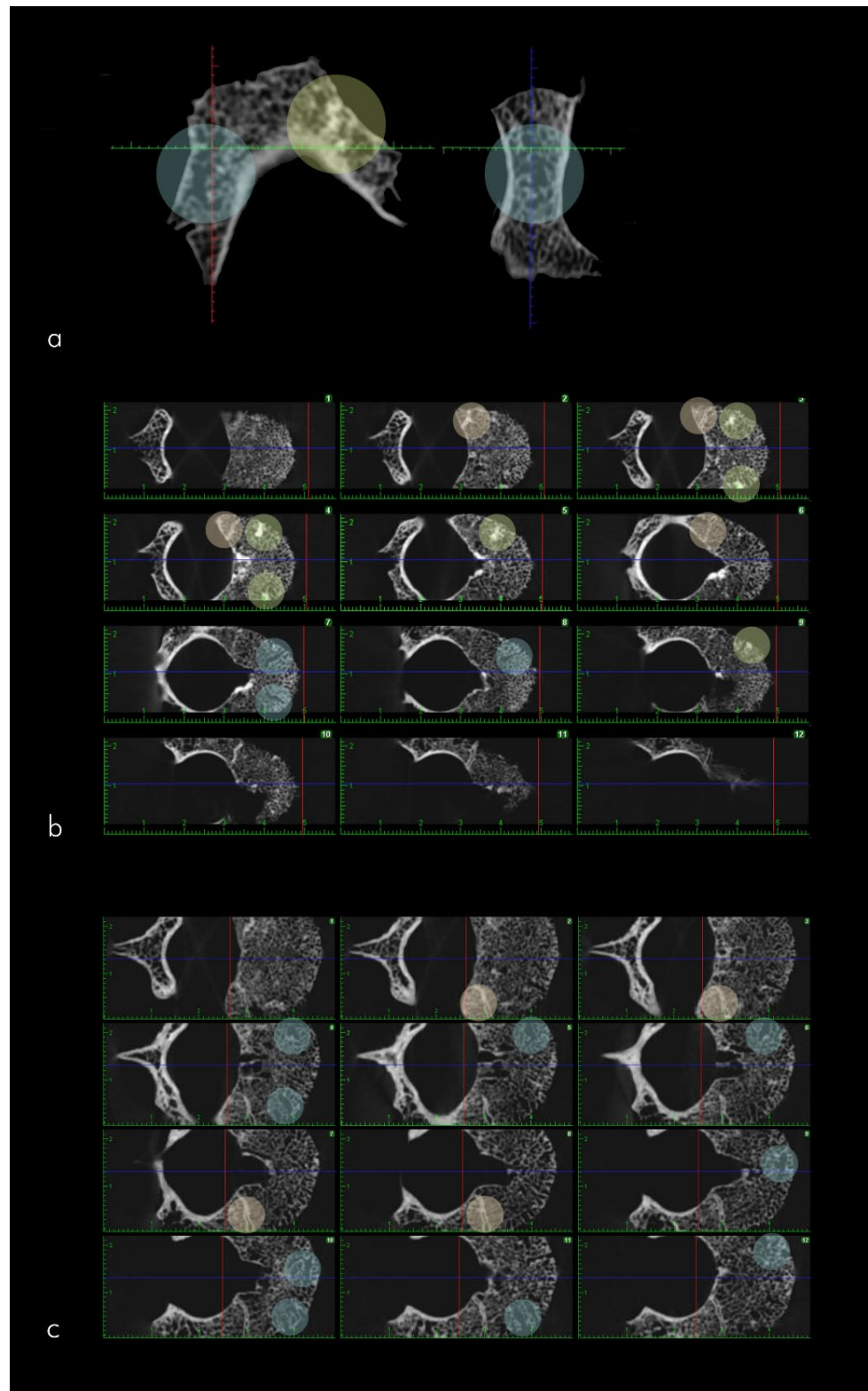


Figure 4. CT acquisitions of select pathological bones of ISZ2 are depicted. In (a), the pars basilaris exhibits areas of bone rarefaction indicated by blue circles, along with smaller regions of denser bone near the lateral angle highlighted by a yellow circle. In (b,c), the T9 and L2 vertebrae, respectively, demonstrate normal ossification patterns, with dense bone present at the border between the vertebral body and peduncle denoted by orange circles. Additionally, increased bone density is observed within the vertebral body, represented by yellow circles, and grooves are visible within the vertebral body indicated by blue circles.

4. Discussion

Diagnosing tuberculosis in the skeletal remains of young children poses considerable challenges, primarily due to the more cartilaginous nature of their juvenile skeletons compared to adults [44]. However, clinical and historical evidence strongly suggests that tuberculosis was widespread among children, highlighting the growing recognition among researchers of the potential for diagnosing tuberculosis in sub-adult skeletons from diverse temporal and geographic contexts, e.g. [12,44–52]. Although differential diagnoses such as Langerhans cell histiocytosis, infantile myofibromatosis, pneumonia, and actinomycosis should be considered, tuberculosis appears to be the most probable cause for the range of lesions observed in skeleton ISZ2. The concurrent occurrence of rib lesions, lytic skull lesions, as well as vertebral and articular modifications provides additional support for tuberculosis as the possible diagnosis in this case. Unfortunately, funding constraints prevented the testing of ancient DNA during this research, which could have provided additional confirmation of tuberculosis in this individual.

The disruption of the endocranial plate, known as *Serpens Endocranica Symmetrica* (SES) in paleopathology, is observed in the skeletal series of post-17th century adults and is considered an indicator of intrathoracic pathology, most likely tuberculosis (TB) [53,54]. However, a broader diagnostic approach should be adopted in ancient populations, particularly for subadults, as SES can also be associated with respiratory tract infections, neurovascular disorders, hematomas, and metabolic diseases [53–56]. In the absence of antibiotics, non-adults were at high risk of developing intracranial infections related to respiratory tract infections and often succumbed to them [57]. The proximity of SES to the sulcus of the anterior branch of the middle meningeal artery does not provide conclusive insights into its etiology [53]. Therefore, its presence should be considered in conjunction with other pathological changes observed in ISZ2 [58].

The bilateral evidence of pathological changes in the humeral olecranon fossa can be attributed, for example, to fractures and dislocations (which can, for example, lead to osteochondritis dissecans), juvenile arthritis, synovial chondromatosis or TB [59–61]. Although elbow dislocations are common in non-adults, the observed porosity in the olecranon is not superficial, and there is no evidence of bone production typically seen in cases of trauma [62]. Thus, TB appears to be a possible etiology, characterized by an intra-articular geographic lytic lesion in the distal humerus accompanied by sclerosis [63,64].

Subperiosteal new bone formation on the ribs is a well-documented pathological finding in skeletal collections [31,65–67] associated with respiratory tract diseases, trauma, metabolic diseases, and hemorrhage [23,68–70]. However, it is frequently observed in individuals who died from TB, as the bacteria can extend from the lungs or pleura into the ribs [10,70]. Pathological changes are also present in the axial skeleton, including lesions on the wing of the first sacral vertebra, which can be caused by pediatric sacral tumors or TB [71–73]. Both possibilities are rare, and therefore the absence of bone in S1 should be evaluated in conjunction with all other pathological findings observed in ISZ2.

The presence of an enlarged basivertebral vein canal and the surrounding area with denser bone tissue may be associated with the development of adolescent idiopathic scoliosis in non-adults, although the typical onset age for this condition is 9–17 years [74]. Pediatric spinal infections can be caused by various fungal, parasitic, bacterial, and viral agents, and these alterations in the basivertebral venous canal can be observed [66]. While distinguishing between these possibilities in paleopathology is challenging, vertebral tuberculosis (TB) deserves special attention as it can spread through Batson's venous plexus, which could be hypothesized for the subject in question. The hypervascularization of the vertebral bodies, as indicated by the presence of lateral foramina, supports the concept of this infectious agent spread [20]. CT acquisitions provide a better evaluation of this aspect and reveal the persistence of vascularization within the vertebral body. Additionally, small nodules of bone tissue are found within T9. The presence of numerous foramina, hypervascularization, and dense bony nodules in the ISZ2 vertebrae allows us to hypothesize *Mycobacterium* as the causative agent [75,76], although TB can mimic other infections and disease processes.

The likelihood that ISZ2 had skeletal tuberculosis (TB) along with potential comorbidities is substantial. Considering the observed spinal injuries, rib hyperostosis and other evidence, although not pathognomonic, it can be speculated that the individual would have experienced significant impairment and evident symptoms during their lifetime. Coexisting common conditions during that era may have included pneumonia, pleurisy, and underweight status [77–79].

It is important to note that the clinical presentation of tuberculosis in skeletal remains can manifest itself in a variety of ways, including characteristic bony lesions and deformities. These skeletal manifestations, coupled with the historical context of the prevalent tuberculosis and associated comorbidities, add to the plausibility of this diagnosis. The debilitating nature of the disease and its potential impact on respiratory function, together with the presence of other respiratory conditions, further strengthen the case for pulmonary tuberculosis as a primary underlying disease.

Additionally, it is critical to consider the socioeconomic and environmental factors of the time, as they significantly influence disease prevalence and outcomes. Poor living conditions, overcrowding, and inadequate nutrition were prevalent during this era, contributing to individual vulnerability to infectious diseases such as tuberculosis. Thus, the presence of potential TB-associated comorbidities, such as pneumonia, pleurisy, and malnutrition, aligns with the historical context and provides further support for the diagnosis.

It is important to recognize that this assessment is based on available evidence and historical context and a comprehensive analysis including clinical, radiological, and molecular investigations would be needed to confirm the diagnosis of tuberculosis and to further explore potential comorbidities.

In the case of TB, bone involvement from the time of infection is estimated to occur within a range of 10–36 months according to the clinical literature [80]. The innate immune system does not retain the memory of specific infections such as TB, and the mother–infant immunological connection has evolved to protect infants without immunity during their development, even after birth through breastfeeding [81,82]. Weaning, in terms of infectious disease development, can pose challenges. Anthropological data on children from the same area suggest that weaning in these communities typically occurred around the age of two [83]. Therefore, it is possible to hypothesize that weaning in our subject occurred at least before the age of two.

Breastfeeding played a crucial role, and wet nurses likely cared for children even during the Middle Ages. The absence of breastfeeding may have contributed to infant mortality [84,85], although in lower social classes and rural areas like Sanzenone, as demonstrated by studies on a post-medieval sample recovered from a cemetery dedicated exclusively to infants, located in a nearby church [86,87], mothers predominantly breastfed their children due to the inability to afford a wet nurse [88,89]. Ethnographic evidence indicates that breastfeeding is culturally accepted in most societies but practiced only in exceptional circumstances, such as abandonment, maternal death, breast infection, illness, or when the infant requires supplementary nutrition [9].

The development of chronic or infectious diseases in non-adults can have multifactorial causes and may be related to challenging early childhood, poor nutrition, environmental factors, and the type and quality of care received [88,89]. Variables such as breastfeeding and carrying can also influence a child's overall health, nutrition, and resistance to disease [90]. Some researchers have explored the connection between social class and immune function, suggesting a link between stressful living conditions during early childhood and the level of immunity and response regulation to infections [90–93]. The Middle Ages exemplify this, as the hygienic conditions of households were often inadequate and accompanied by overcrowding [94], creating fertile grounds for numerous infectious diseases [95,96].

Another non-adult subject, identified as SU 21 and later referred to as ISZ1, also originates from Sanzenone and exhibits probable TB [16]. This further suggests the presence of TB within the medieval community of San Zenone. The analysis of non-adults in bioarchaeology is crucial as it can provide insights into environmental stress and vulnerability to

infectious diseases during the critical early years of life. Understanding the pathological evidence associated with infections and employing modern paleopathological parameters for non-adults can facilitate the analysis of the mother–child environment [9].

5. Conclusions

Non-adults, although relatively rare in archaeological findings, provide invaluable insights for our knowledge of ancient pathologies, particularly infectious diseases. Their immature immune systems, both qualitatively and quantitatively, render non-adults more susceptible to progressing from primary infection to disease compared to adults [79,97,98]. Thus, it is imperative to identify and understand these pathologies in non-adults within ancient populations, considering their potential role as vectors. Additionally, infectious diseases are widely recognized for their association with social inequality and poor living conditions [24].

This research has contributed to the identification of a possible new case of tuberculosis (TB) in a rural medieval context in Italy. The findings complement the existing knowledge about the presence of TB in the studied area and historical period [16], as previously published research from the same site has already shed light on this aspect. The inclusion of new possible cases of TB in non-adults expands our understanding of skeletal alterations likely associated with primary TB infection.

Moreover, studying non-adults allows for the acquisition of novel data concerning bone changes specifically linked to infectious and nutritional deficiencies [11,99,100]. TB, in paleopathology, is predominantly known in its secondary chronic form, commonly observed in adults. Therefore, focusing on non-adults and identifying possible cases of TB in this population facilitates a more comprehensive examination of the available evidence about skeletal manifestations potentially attributable to primary TB.

Furthermore, a thorough and detailed analysis of the growth environment, both from a paleopathological and historical perspective, is necessary when studying non-adults. This approach considers the critical relationship between the mother and child, as well as the strategies employed for care and growth, which play significant roles. The maternal–infant immune nexus has likely evolved to provide immunological protection to infants during intrauterine development and extends postpartum through breastfeeding and other factors influencing the growth environment [101]. Consequently, investigating the relationship between weaning practices and the incidence of infectious diseases could be a promising avenue for future research in the Italian context.

Overall, this study emphasizes the importance of considering non-adults in research endeavors, as they offer unique insights into ancient pathologies and allow for a more comprehensive understanding of the historical and social dynamics underlying disease diffusion and transmission.

Author Contributions: Conceptualization, O.L.; methodology, O.L.; formal analysis, E.T.; investigation, O.L.; writing—original draft preparation, O.L.; writing—review and editing, C.P.; All authors have read and agreed to the published version of the manuscript.

Funding: This research received no external funding.

Institutional Review Board Statement: Not applicable.

Informed Consent Statement: Not applicable.

Data Availability Statement: Not applicable.

Acknowledgments: We thank Nicoletta Pisu, the archaeologist official of the Trento Province Soprintendenza per i Beni Culturali for authorization to study and publish materials.

Conflicts of Interest: The author declares no conflict of interest.

References

1. Boddy, A.M.; Fortunato, A.; Wilson Sayres, M.; Aktipis, A. Fetal microchimerism and maternal health: A review and evolutionary analysis of cooperation and conflict beyond the womb. *Bioessays* **2015**, *37*, 1106–1118. <http://doi.org/10.1002/bies.201500059>.
2. Lapaire, O.; Hösli, I.; Zanetti-Daellenbach, R.; Huang, D.; Jaeggi, C.; Gatfield-Mergenthaler, S.; Hahn, S.; Holzgreve, W. Impact of fetal-maternal microchimerism on women's health—A review. *J. Matern. Neonatal Med.* **2007**, *20*, 1–5. <http://doi.org/10.1080/14767050601144834>.
3. Veena, S.R.; Gale, C.R.; Krishnaveni, G.V.; Kehoe, S.H.; Srinivasan, K.; Fall, C.H.D. Association between maternal nutritional status in pregnancy and offspring cognitive function during childhood and adolescence; a systematic review. *BMC Pregnancy Childbirth* **2016**, *16*, 1–24. <http://doi.org/10.1186/s12884-016-1011-z>.
4. Wei, S.Q.; Qi, H.P.; Luo, Z.C.; Fraser, W.D. Maternal vitamin D status and adverse pregnancy outcomes: A systematic review and meta-analysis. *J. Matern. Neonatal Med.* **2013**, *26*, 889–899. <http://doi.org/10.3109/14767058.2013.765849>.
5. Badgett, T.; Feingold, M. Total parenteral nutrition in pregnancy: Case review and guidelines for calculating requirements. *J. Matern. Neonatal Med.* **1997**, *6*, 215–217. [http://doi.org/10.1002/\(SICI\)1520-6661\(199707/08\)6:4<215::AID-FM5>3.0.CO;2-M](http://doi.org/10.1002/(SICI)1520-6661(199707/08)6:4<215::AID-FM5>3.0.CO;2-M).
6. Lee, R.V.; Rodgers, B.D.; Young, C.; Eddy, E.; Cardinal, J. Total parenteral nutrition during pregnancy. *Obstet. Gynecol.* **1986**, *68*, 563–571. Available online: <https://pubmed.ncbi.nlm.nih.gov/3092156/> (accessed on 21 June 2023).
7. Than, N.G.; Hahn, S.; Rossi, S.W.; Szekeres-Bartho, J. Fetal-maternal immune interactions in pregnancy. *Front. Immunol.* **2019**, *10*, 2729. <http://doi.org/10.3389/fimmu.2019.02729>.
8. Trowsdale, J.; Betz, A.G. Mother's little helpers: Mechanisms of maternal-fetal tolerance. *Nat. Immunol.* **2006**, *7*, 241–246. Available online: <https://pubmed.ncbi.nlm.nih.gov/16482172/> (accessed on 21 June 2023).
9. Gowland, R.; Halcrow, C. *The Mother Infant Nexus in Anthropology: Small Beginnings, Significant Outcomes*; Springer Nature Switzerland AG: Cham, Switzerland, 2020. <https://doi.org/10.1007/978-3-030-27393-4>.
10. Buikstra, J. *Ortner's Identification of Pathological Conditions in Human Skeletal Remains*; Academic Press: Cambridge, MA, USA, 2019. <https://doi.org/10.1016/B978-0-12-809738-0.00025-9>.
11. Brickley, M.; Ives, R.; Mays, S.G.M. *The Bioarchaeology of Metabolic Bone Disease*, 2nd ed.; Academic Press: Cambridge, MA, USA, 2020.
12. Lewis, M.E. Fetal Paleopathology: An Impossible Discipline? In *The Anthropology of the Fetus: Biology, Culture, and Society*; Han, S., Betsinger, T.K., Scott, B.A., Eds.; Berghahn Books: New York City, NY, USA, 2018; pp. 112–131.
13. Ubelaker, D.H.; De La Paz, J.S. Skeletal indicators of pregnancy and parturition: A historical review: Skeletal indicators of pregnancy and parturition. *J. Forensic. Sci.* **2012**, *57*, 866–872. <http://doi.org/10.1111/j.1556-4029.2012.02102.x>.
14. Väre, T.; Lipkin, S.; Kallio-Seppä, T.; Tranberg, A.; Junno, J.A. Possible case of partial postmortem fetal extrusion: Preliminary observations on the mummified remains of a turn-of-the-19th-century noblewoman in Finland. *Int. J. Osteoarchaeol.* **2021**, *31*, 1280–1284. <https://doi.org/10.1002/oa.3023>.
15. Basu Roy, R.; Whittaker, E.; Seddon, J.A.; Kampmann, B. Tuberculosis susceptibility and protection in children. *Lancet Infect. Dis.* **2019**, *19*, e96–e108. [http://doi.org/10.1016/S1473-3099\(18\)30157-9](http://doi.org/10.1016/S1473-3099(18)30157-9).
16. Larentis, O.; Tonina, E. A possible case of tuberculosis from a medieval site in northeast Italy. The infant of the Immacolata and San Zenone church, Tassullo, Trentino. *Medicina Hist.* **2021**, *5*, e2021021.
17. Larentis, O.; Tonina, E.; Tesi, C.; Rossetti, C.; Gorini, I.; Ciliberti, R.; Licata, M. A probable case of subligamentous tuberculous spondylitis: The concealed body of the Late Modern Period (early 16th century to early 20th century), Franciscan crypt of St. Anthony and St. Eusebius church, Lombardy, Italy. *Int. J. Osteoarchaeol.* **2020**, *30*, 180–196. <http://doi.org/10.1002/oa.2845>.
18. Churchyard, G.; Kim, P.; Shah, N.S.; Rustomjee, R.; Gandhi, N.; Mathema, B.; Dowdy, D.; Kasmar, A.; Cardenas, V. What we know about tuberculosis transmission: An overview. *J. Infect. Dis.* **2017**, *216*, 629–635. <http://doi.org/10.1093/infdis/jix362>.
19. GTR (2022) *Global Tuberculosis Report 2022*; World Health Organization: Geneva, Switzerland, 2022. Available online: <https://www.who.int/teams/global-tuberculosis-programme/tb-reports/global-tuberculosis-report-2022> (accessed on 20 May 2023).
20. Mariotti, V.; Zuppello, M.; Pedrosi, M.E.; Bettuzzi, M.; Brancaccio, R.; Peccenini, E.; Morigi, M.P.; Belcastro, M.G. Skeletal evidence of tuberculosis in a modern identified human skeletal collection (Certosa cemetery, Bologna, Italy): Skeletal Evidence of Tuberculosis. *Am. J. Phys. Anthropol.* **2015**, *157*, 389–401. <http://doi.org/10.1002/ajpa.22727>.
21. Garg, R.K.; Somvanshi, D.S. Spinal tuberculosis: A review. *J. Spinal Cord Med.* **2011**, *34*, 440–454.
22. Pálfi, G.; Dutour, O.; Deak, J.; Hutás, I. *Tuberculosis Past and Present*; Golden Book: Budapest, Hungary, 1999.
23. Ortner, D.J. *Identification of Pathological Conditions in Human Skeletal Remains*, 2nd ed.; Academic Press: Cambridge, MA, USA, 2003.
24. Roberts, C.A.; Buikstra, J.E. *The Bioarchaeology of Tuberculosis. A Global View on a Reemerging Disease*, 1st ed.; University Press of Florida: Gainesville, FL, USA, 2003.
25. Roberts, C.A. Re-Emerging Infections: Developments in Bioarchaeological Contributions to Understanding Tuberculosis Today. In *A Companion to Paleopathology*, 2nd ed.; Grauer, A.L., Ed.; Blackwell: Boston, MA, USA, 2016; pp. 434–457.
26. Roberts, C.A.; Pfister, L.A.; Mays, S. Was tuberculosis present in *Homo erectus* in Turkey? *Am. J. Phys. Anthropol.* **2009**, *139*, 442–444. <http://doi.org/10.1002/ajpa.21056>.

27. Donoghue, H.D.; Spigelman, M.; Zias, J.; Gernaey-Child, A.M.; Minnikin, D.E. Mycobacterium tuberculosis complex DNA in calcified pleura from remains 1400 years old. *Lett. Appl. Microbiol.* **1998**, *27*, 265–269. <http://doi.org/10.1046/j.1472-765x.1998.00436.x>.
28. Resnick, D.; Niwayama, G. Enostosis, Hyperostosis and Periostitis. In *Bone and Joint Imaging*, 3rd ed.; Resnick, D., Ed.; WB Saunders Company: Philadelphia, PA, USA, 2004; pp. 4396–4466.
29. Resnick, D.; Niwayama, G. Osteomyelitis, Septic Arthritis, and Soft Tissue Infection: Organisms. In *Bone and Joint Imaging*, 3rd ed.; Resnick, D., Ed.; WB Saunders Company: Philadelphia, PA, USA, 2004; pp. 2467–2474.
30. Resnick, D.; Niwayama, G. Osteomyelitis, Septic Arthritis, and Soft Tissue Infection: Axial Skeleton. In *Bone and Joint Imaging*, 3rd ed.; Resnick, D., Ed.; WB Saunders Company: Philadelphia, PA, USA, 2004; pp. 2419–2447.
31. Roberts, C.; Lucy, D.; Manchester, K. Inflammatory lesions of ribs: An analysis of the Terry Collection. *Am. J. Phys. Anthropol.* **1994**, *95*, 169–182. <http://doi.org/10.1002/ajpa.1330950205>.
32. Sparacello, V.S.; Roberts, C.A.; Canci, A.; Moggi-Cecchi, J.; Marchi, D. Insights on the paleoepidemiology of ancient tuberculosis from the structural analysis of postcranial remains from the Ligurian Neolithic (northwestern Italy). *Int. J. Paleopathol.* **2016**, *15*, 50–64. <http://doi.org/10.1016/j.ijpp.2016.08.003>.
33. Sparacello, V.S.; Roberts, C.A.; Kerudin, A.; Müller, R. A 6500-year-old Middle Neolithic child from Pollera Cave (Liguria, Italy) with probable multifocal osteoarticular tuberculosis. *Int. J. Paleopathol.* **2017**, *17*, 67–74. <http://doi.org/10.1016/j.ijpp.2017.01.004>.
34. Formicola, V.; Milanese, Q.; Scarsini, C. Evidence of spinal tuberculosis at the beginning of the fourth millennium BC from Arene Candide cave (Liguria, Italy). *Am. J. Phys. Anthropol.* **1987**, *72*, 1–6. <http://doi.org/10.1002/ajpa.1330720102>.
35. Mazzoleni, P.; Pisu, N.; Asolati, M. *L’Immacolata e San Zenone a Sanzenone di Tassullo: Storia, Archeologia, Architettura e Arte di Una Chiesa Della Valle di Non*; Comune di Tassullo: Tassullo, Italy, 2015.
36. Schaefer, M.; Black, S.; Scheuer, L. *Juvenile Osteology*; Academic Press: Burlington, MA, USA, 2009.
37. Liversidge, H.M.; Dean, M.C.; Molleson, T.I. Increasing human tooth length between birth and 5.4 years. *Am. J. Phys. Anthropol.* **1993**, *90*, 307–313. <http://doi.org/10.1002/ajpa.1330900305>.
38. Liversidge, H.M.; Herdeg, B.; Rösing, F.W. Dental age estimation of non-adults. A review of methods and principles. In *Dental Anthropology*, 1st ed.; Alt, K.W., Rösing, F.W., Teschler-Nicola, M., Eds.; Springer: Vienna, Austria, 1998; pp. 419–442.
39. AlQahtani, S.J.; Hector, M.P.; Liversidge, H.M. The London atlas of human tooth development and eruption. *Am. J. Phys. Anthropol.* **2010**, *142*, 481–490. <http://doi.org/10.1002/ajpa.21258>.
40. Elamin, F.; Liversidge, H.M. Malnutrition has no effect on the timing of human tooth formation. *PLoS ONE* **2013**, *8*, e72274. <http://doi.org/10.1371/journal.pone.0072274>.
41. Fusco, R.; Larentis, O.; Cermesoni, B.; Ravagnan, A.; Tesi, C. The “mummy of Erba”: A study proposal for the analysis of a mummified egyptian specimen. *Medicina Hist.* **2018**, *2*, 163–165.
42. Buikstra, J.E.; Ubelaker, D.H. *Standards for Data Collection from Human Skeletal Remains. (Report Number 44)*, 1st ed.; Archaeological Survey; Arkansas Archaeological Survey: Fayetteville, NC, USA, 1994.
43. Squires, K.; Roberts, C.A.; Márquez-Grant, N. Ethical considerations and publishing in human bioarcheology. *Am. J. Biol. Anthropol.* **2022**, *177*, 615–619. <http://doi.org/10.1002/ajpa.24467>.
44. Daoud, A. Bone and joint tuberculosis in the child. In *Tuberculosis of the Bones and Joints*, Martini, M., Ed.; Springer: New York, NY, USA, 1988; pp. 34–38.
45. Dawson, H.; Robson Brown, K. Childhood tuberculosis: A probable case from late mediaeval Somerset, England. *Int. J. Paleopat.* **2012**, *2*, 31–35. <http://doi.org/10.1016/j.ijpp.2012.04.001>.
46. Baker, J.O.; Chamel, B.; Dutour, O. New Paleopathological Evidence of Tuberculosis in Child Skeletal Remains from Tell Aswad (8730–8290 cal. BC, southern Syria). *Paléorient* **2021**, *47*, 97–108. <https://doi.org/10.4000/paleorient.926>.
47. Bennike, P. Fact or myths? A re-evaluation of cases of diagnosed tuberculosis in the past in Denmark. In *Tuberculosis: Past and Present*; Pálfi, G., Dutour, O., Deák, J., Hutás, I., Eds.; Golden Book Publisher Ltd.: Szeged, Hungary, 1999; pp. 511–518.
48. Buikstra, J.E. Paleoepidemiology of tuberculosis in the Americas. In *Tuberculosis: Past and Present*; Pálfi, G., Dutour, O., Deák, J., Hutás, I., Eds.; Golden Book Publisher Ltd.: Szeged, Hungary, 1999; pp. 479–494.
49. Dabernat, H.; Crubézy, É. Multiple bone tuberculosis in a child from predynastic Upper Egypt (3200 BC). *Int. J. Osteoarchaeol.* **2010**, *20*, 719–730. <https://doi.org/10.1002/oa.1082>.
50. Jankauskas, R. Tuberculosis in Lithuania: Palaeopathological and historical correlations. In *Tuberculosis: Past and Present*; Pálfi, G., Dutour, O., Deák, J., Hutás, I., Eds.; Golden Book Publisher Ltd.: Szeged, Hungary, 1999; pp. 551–558.
51. Hlavenková, L.; Teasdale, M.D.; Gábor, O.; Nagy, G.; Beňuš, R.; Marcsik, A.; Pinhasi, R.; Hajdu, T. Childhood bone tuberculosis from Roman Pécs, Hungary. *HOMO-J. Comp. Hum. Biol.* **2015**, *66*, 27–37. <https://doi.org/10.1016/j.jchb.2014.10.001>.
52. Schultz, M. The role of tuberculosis in infancy and childhood in prehistoric and historic populations. In *Tuberculosis: Past and Present*; Pálfi, G., Dutour, O., Deák, J., Hutás, I., Eds.; Golden Book Publisher Ltd.: Szeged, Hungary, 1999; pp. 503–507.
53. Lewis, M.E. Endocranial lesions in non-adult skeletons: Understanding their aetiology. *Int. J. Osteoarchaeol.* **2004**, *14*, 82–97. <http://doi.org/10.1002/oa.713>.
54. Hershkovitz, I.; Greenwald, C.M.; Latimer, B.; Jellema, L.M.; Wish-Baratz, S.; Eshed, V.; Dotour, O.; Rothschild, B.M. Serpens endocrania symmetrica (SES): A new term and a possible clue for identifying intrathoracic disease in skeletal populations. *Am. J. Phys. Anthropol.* **2002**, *118*, 201–216. <http://doi.org/10.1002/ajpa.10077>.
55. Lovejoy, C.O.; Meindl, R.S.; Pryzbeck, T.R.; Barton, T.S.; Heiple, K.G.; Kottling, D. Paleodemography of the libben site, Ottawa county, Ohio. *Science* **1977**, *198*, 291–293. <http://doi.org/10.1126/science.198.4314.291>.

56. Mensforth, R.P.; Lovejoy, C.O.; Lallo, J.W.; Armelagos, G.J. The role of constitutional factors, diet, and infectious disease in the etiology of porotic hyperostosis and periosteal reactions in prehistoric infants and children. *Med. Anthropol.* **1978**, *2*, 1–59.
57. Aminov, R.I. A brief history of the antibiotic era: Lessons learned and challenges for the future. *Front. Microbiol.* **2010**, *1*, 134. <http://doi.org/10.3389/fmicb.2010.00134>.
58. Spekker, O.; Schultz, M.; Paja, L.; Váradi, O.A.; Molnár, E.; Pálfi, G.; Hunt, D. Tracking down the White Plague. Chapter two: The role of endocranial abnormal blood vessel impressions and periosteal appositions in the paleopathological diagnosis of tuberculous meningitis. *PLoS ONE* **2020**, *15*, e0238444. <http://doi.org/10.1371/journal.pone.0238444>.
59. Stans, A.A.; Lawrence, J.T.R. Dislocations of the elbows, medial Epicondylar Humerus fractures. In *Rockwood and Wilkins' Fractures in Children*, 8th ed.; Flynn, J.M., Skaggs, D.L., Waters, P.M., Eds.; Wolters Kluwer Health/Lippincott Williams & Wilkins: Philadelphia, PA, USA, 2015; pp. 625–698.
60. Lepore, N.; Cashin, M.; Bartley, D.; Ardelean, D.S. Atypical monoarthritis presentation in children with oligoarticular juvenile idiopathic arthritis: A case series. *Pediatr. Rheumatol.* **2017**, *15*, 2. <https://doi.org/10.1186/s12969-016-0129-x>.
61. Mo, J.; Pan, J.; Liu, Y.; Feng, W.; Li, B.; Luo, K.; Mo, W.; Lin, H.; Liao, S. Bilateral synovial chondromatosis of the elbow in an adolescent: A case report and literature review. *BMC Musculoskelet. Disord.* **2020**, *21*, 377. <https://doi.org/10.1186/s12891-020-03322-1>.
62. Hyvönen, H.; Korhonen, L.; Hannonen, J.; Serlo, W.; Sinikumpu, J.J. Recent trends in children's elbow dislocation with or without a concomitant fracture. *BMC Musculoskelet. Disord.* **2019**, *20*, 294. <http://doi.org/10.1186/s12891-019-2651-8>.
63. Agarwal, A.; Mumtaz, I.; Kumar, P.; Khan, S.; Qureshi, N.A. Tuberculosis of the elbow joint in children: A review of ten patients who were managed nonoperatively. *J. Bone Jt. Surg. Am.* **2010**, *92*, 436–441. <https://doi.org/10.2106/jbjs.i.00805>.
64. Gailson, T.; Arpitha, K.; Bhatia, A.; Saini, A.G. Tuberculosis of the humerus: An uncommon site in children. *BMJ Case Rep.* **2022**, *15*, e249268. <http://doi.org/10.1136/bcr-2022-249268>.
65. Kelley, M.A.; Micozzi, M.S. Rib lesions in chronic pulmonary tuberculosis. *Am. J. Phys. Anthropol.* **1984**, *65*, 381–386. <http://doi.org/10.1002/ajpa.1330650407>.
66. Santos, A.L.; Roberts, C.A. Anatomy of a serial killer: Differential diagnosis of tuberculosis based on rib lesions of adult individuals from the Coimbra Identified Skeletal Collection, Portugal. *Am. J. Phys. Anthropol.* **2006**, *130*, 38–49. <http://doi.org/10.1002/ajpa.20160>.
67. Matos, V.; Santos, A.L. On the trail of pulmonary tuberculosis based on rib lesions: Results from the Human Identified Skeletal Collection from the Museu Bocage (Lisbon, Portugal). *Am. J. Phys. Anthropol.* **2006**, *130*, 190–200. <http://doi.org/10.1002/ajpa.20309>.
68. Davies-Barrett, A.M.; Antoine, D.; Roberts, C.A. Inflammatory periosteal reaction on ribs associated with lower respiratory tract disease: A method for recording prevalence from sites with differing preservation. *Am. J. Phys. Anthropol.* **2019**, *168*, 530–542. <http://doi.org/10.1002/ajpa.23769>.
69. Waldron, T. *Palaeopathology*; Cambridge University Press: Cambridge, UK, 2009.
70. Weston, D.A. Nonspecific infection in palaeopathology: Interpreting periosteal reactions. In *A companion to Palaeopathology*, 1st ed.; Grauer, A.L., Ed.; Blackwell Publishing Ltd.: Chichester, UK, 2012; pp. 492–512.
71. Wang, J.; Li, D.; Yang, R.; Tang, X.; Yan, T.; Guo, W. Epidemiological characteristics of 1385 primary sacral tumors in one institution in China. *World J. Surg. Oncol.* **2020**, *18*, 297. <http://doi.org/10.1186/s12957-020-02045-w>.
72. Lam, C.H.; Nagib, M.G. Nonteratomatous tumors in the pediatric sacral region. *Spine* **2002**, *27*, E284–E287.
73. Raymond, F.; Levard, G.; Bataille, B. Sacral bone tuberculosis in a 6 year-old child. *Arch. Pediatr.* **1994**, *1*, 489–492.
74. Shiran, S.I.; Shabtai, L.; Ben-Sira, L.; Ovadia, D.; Wientroub, S. T1-weighted MR imaging of bone marrow pattern in children with adolescent idiopathic scoliosis: A preliminary study. *J. Child. Orthop.* **2018**, *12*, 181–186. <http://doi.org/10.1302/1863-2548.12.180035>.
75. Tyagi, R. Spinal infections in children: A review. *J. Orthop.* **2016**, *13*, 254–258.
76. Kumar, R. Spinal tuberculosis: With reference to the children of northern India. *Childs Nerv. Syst.* **2005**, *21*, 19–26. <http://doi.org/10.1007/s00381-004-1029-9>.
77. Spekker, O.; Hunt, D.R.; Váradi, O.A.; Berthon, W.; Molnár, E.; Pálfi, G. Rare manifestations of spinal tuberculosis in the Robert J. Terry Anatomical Skeletal Collection (National Museum of Natural History, Smithsonian Institution, Washington, DC, USA). *Int. J. Osteoarchaeol.* **2018**, *28*, 343–353. <http://doi.org/10.1002/oa.2658>.
78. Schirmer, P.; Renault, C.A.; Holodniy, M. Is spinal tuberculosis contagious? *Int. J. Infect. Dis.* **2010**, *14*, e659–e66.
79. Holloway, K.L.; Link, K.; Rühli, F.; Henneberg, M. Skeletal lesions in human tuberculosis may sometimes heal: An aid to palaeopathological diagnoses. *PLoS ONE* **2013**, *8*, e62798. <https://doi.org/10.1371/journal.pone.0062798>.
80. Hoskyns, W. Paediatric tuberculosis. *Postgrad. Med. J.* **2003**, *79*, 272–278.
81. Sun, J.C.; Ugolini, S.; Vivier, E. Immunological memory within the innate immune system. *EMBO J.* **2014**, *33*, 1295–1303. <http://doi.org/10.1002/embj.201387651>.
82. Newburg, D.S.; Walker, W.A. Protection of the neonate by the innate immune system of developing gut and of human milk. *Pediatr. Res.* **2007**, *61*, 2–8.
83. Larentis, O.; Licata, M.; Tonina, E.; Pangrazzi, C. Probable micronutrient deficiency diseases in a rural community. The non-adults of Mary's Nativity church, 16th century, Trentino Alto-Adige, Italy. *J. Archaeol. Sci. Rep.* **2022**, *47*, 103774. <http://doi.org/10.1016/j.jasrep.2022.103774>.
84. Morel, M.F. La mort d'un bébé au fil de l'histoire. *Spirale* **2004**, *31*, 15–34. <https://doi.org/10.3917/spi.080.0197>.

85. Lewis, M.E.; Gowland, R. Brief and precarious lives: Infant mortality in contrasting sites from medieval and post-medieval England (AD 850–1859). *Am. J. Phys. Anthropol.* **2007**, *134*, 117–129. <http://doi.org/10.1002/ajpa.20643>.
86. Larentis, O.; Tonina, E.; Iorio, S.; Gorini, I.; Licata, M. Osteological evidence of metabolic diseases from a post medieval North Italy archaeological site. *J. Matern. Fetal Neonatal Med.* **2020**, *33*, 2735–2742. <https://doi.org/10.1080/14767058.2018.1560405>
87. Larentis, O. Sepolture Infantili Bassomedievali. Il Caso Della Chiesa Della Natività della Vergine Maria di Segno (Taio-TN). In *NEALM Necropoli Altomedievali e Medievali*; Possenti, E., Ed.; Editreg: Trieste, Italy, 2017; pp. 117–140.
88. Giuffra, V.; Fornaciari, G. Breastfeeding and weaning in renaissance Italy: The Medici children. *Breastfeed. Med.* **2013**, *8*, 257–262. Available online: <https://pubmed.ncbi.nlm.nih.gov/23259644/> (accessed on 21 June 2023).
89. Haas, L. *The Renaissance Man and His Children. Childbirth and Early Childhood in Florence, 1300–1600*; MacMillan: London, UK, 1998.
90. Meehan, C.L.; Crittenden, A.N. *Childhood: Origins, Evolution, and Implications*; University of New Mexico Press: Albuquerque, NM, USA, 2016.
91. Reissland, N.; Kisilevsky, B.S. *Fetal Development: Research on Brain and Behavior, Environmental Influences, and Emerging Technologies*; Springer: Basel, Germany, 2016.
92. Wall-Scheffler, C.M.; Geiger, K.; Steudel-Numbers, K.L. Infant carrying: The role of increased locomotory costs in early tool development. *Am. J. Phys. Anthropol.* **2007**, *133*, 841–846. <http://doi.org/10.1002/ajpa.20603>.
93. Babones, S.J. Income inequality and population health: Correlation and causality. *Soc. Sci. Med.* **2008**, *66*, 1614–1626.
94. Fornaciari, G.; Ciranni, R.; Busoni, C.A.; Gamba, S.; Benedetti, E.; Mallegni, F.; Nelli, S.; Rollo, F. Santa Zita Di Lucca: Malattie, Ambiente E Società Dallo Studio Di Una Mummia Naturale Del XIII Secolo. In Proceedings of the Congresso Italiano di Anatomia, Istologia e Citologia Patologica, Università di Pisa, Pisa, 21–24 May 1997.
95. Lewis, M.E. *Urbanisation and Child Health in Medieval and Post-Medieval England*; Archaeopress: Oxford, UK, 2002.
96. Forbes, T.R. Mortality books for 1820 to 1849 from the parish of st. Bride, fleet street, London. *J. Hist. Med. Allied. Sci.* **1972**, *17*, 15–29. <http://doi.org/10.1093/jhmas/xxvii.1.15>.
97. Beaven, P.W. An analysis of tuberculous infection from birth to old age; its relationship to clinical tuberculosis and deaths from tuberculosis. *Dis. Chest* **1950**, *17*, 280–292. <http://doi.org/10.1378/chest.17.3.280>.
98. Smith, S.; Jacobs, R.F.; Wilson, C.B. Immunobiology of childhood tuberculosis: A window on the ontogeny of cellular immunity. *J. Pediatr.* **1997**, *131*, 16–26. <https://pubmed.ncbi.nlm.nih.gov/9255187/>.
99. Snoddy, A.M.E.; Buckley, H.R.; Elliott, G.E.; Standen, V.G.; Arriaza, B.T.; Halcrow, S.E. Macroscopic features of scurvy in human skeletal remains: A literature synthesis and diagnostic guide. *Am. J. Phys. Anthropol.* **2018**, *167*, 876–895.
100. Brickley, M.B.; Mays, S.G.M.; Prowse, T.L. Analysis of patterning in the occurrence of skeletal lesions used as indicators of vitamin D deficiency in subadult and adult skeletal remains. *Int. J. Paleopathol.* **2018**, *23*, 43–53. <https://doi.org/10.1016/j.ijpp.2018.01.001>.
101. Brambell, F.W.R. *The Transmission of Passive Immunity from Mother to Young*; North-Holland Publishing Co.: Amsterdam, The Netherlands, 1970.

Disclaimer/Publisher's Note: The statements, opinions and data contained in all publications are solely those of the individual author(s) and contributor(s) and not of MDPI and/or the editor(s). MDPI and/or the editor(s) disclaim responsibility for any injury to people or property resulting from any ideas, methods, instructions or products referred to in the content.