

Experimental Comparative Study of the Histotoxicity of Poly(Lactic-co-Glycolic Acid) copolymer and Poly(Lactic-co-Glycolic Acid)-Poly(Isoprene) Blend

Jung Ho Kim

*Hospital de Clínicas de Porto Alegre, Universidade Federal do Rio Grande do Sul – UFRGS
Instituto de Ortopedia de Traumatologia de Passo Fundo - Passo Fundo, RS*

Douglas Ramos Marques

Departamento de Materiais, Escola de Engenharia, Universidade Federal do Rio Grande do Sul – UFRGS

Gustavo Juliani Faller, Marcus Vinícius Collares

Hospital de Clínicas de Porto Alegre, Universidade Federal do Rio Grande do Sul – UFRGS

Rubens Rodriguez

Instituto de Patologia de Passo Fundo – Passo Fundo, RS

Luis Alberto dos Santos

Departamento de Materiais, Escola de Engenharia, Universidade Federal do Rio Grande do Sul – UFRGS

Diego da Silva Dias

Hospital de Clínicas de Porto Alegre, Universidade Federal do Rio Grande do Sul – UFRGS

Abstract: Current treatments of craniosynostosis rely on the application of metal springs for cranial bone deviation. However, those metal springs demand a second surgical procedure for their removal. An attractive alternative would be the substitution of metal for bioresorbable polymers in the composition of the springs. The addition of poly(isoprene), PI, to poly(lactic-co-glycolic acid), PLGA, produces a polymeric blend with partial miscibility and distinct mechanical behavior that may benefit the patient recover. It is necessary to compare the histotoxicity of PLGA/PI to that presented by PLGA. In order to verify the histological behavior of the blend, 46 male Wistar rats (*Rattus norvegicus*, albino strain) underwent implantation of PLGA or PLGA/PI in the skull and were allocated into subgroups by timing of euthanasia (15, 30, 60, or 90 days). After euthanasia, the skull was removed and the histotoxicity was assessed histopathologically. The PLGA/PI blend showed greater histotoxicity in animals euthanized at 60 days, although in this period the histotoxicity of the PLGA/PI blend was similar to that of the PLGA copolymer at 15 days. Despite the instability of histological response, presented in different periods of observation, the results obtained in long-term show that the material has high potential for studies in craniosynostosis treatment.

Keywords: PLGA, PI, histotoxicity, in vivo.

Introduction

In 1851, Rudolf Carl Virchow established craniosynostosis as the premature closure of cranial sutures in infants, inhibiting the cranial growth perpendicular to the suture, promoting compensatory growth in the unaffected sutures. This anomaly can cause intercranial hypertension, morbidity, exposure of eyeballs, obstructive respiratory disorder, among other comorbidities^[1-4].

Nowadays, the treatments consist mostly of osteotomies of the affected suture, linear craniotomies and use of progressive bone lengthening techniques. Among the materials used for fastening the movement of bone segments, the use of different metal alloy springs have shown to be effective, combining the advantages of distraction, significantly lowering dural detachments and manipulation, surgical time and length of hospital staying,

thus decreasing the risk of infection. However, the metal springs present the need of its removal after a certain period of treatment, what places the patient, generally a child, in great vulnerability. Likewise its removal may be more complex than its placement, because the material may be found completely covered by adjacent bone^[5-7].

An attractive alternative would be the substitution of metal for bioresorbable polymers in the composition of springs. Poly (lactic-co-glycolic acid) (PLGA) is one of the most common bioresorbable polymers. It is a copolymer of aliphatic esters, used in clinical applications that require a limited period of treatment without the need for removal. However, the application of PLGA derived orthosis/prosthesis may cause injuries to the patient during the treatment, especially because of any eventual

Corresponding author: Jung Ho Kim, Instituto de Ortopedia de Traumatologia de Passo Fundo, Rua Uruguai, 2050, Centro, CEP 99010-112, Passo Fundo, RS, Brazil, e-mail: hokim@iots.com.br

device collapse due to bioresorption. In order to settle the PLGA mechanical properties, a blending procedure may be adequate^[8-11].

The addition of Poly(Isoprene) (PI) to PLGA delivers a polymeric blend with partial miscibility and distinct mechanical behavior. PI presence in the blend stimulates a change from fragile behavior, presented by raw PLGA, to ductile behavior, meaning that the material can be molded specifically right before the application without the risk of fragile rupture. In contact with soft tissues, the material showed no infectious process in a short time observation, and *in vitro* testing showed no evidence of cytotoxicity^[11,12].

Before the development of a spring for craniosynostosis treatment from this blend, is interesting investigate the blend behavior in cranial environment. Comparing the copolymer PLGA with the blend PLGA/PI gives the appropriate idea of PI effect over material's biocompatibility. Histotoxicity assays are the most reliable when it comes to analyze the inflammatory reaction, fibrosis formation and foreign body reaction^[13-15].

Experimental

Blend

The PLGA (Purac Biomaterials – Holland) applied in this research is a copolymer with proportions of 84 mol% monomer L-lactate and 16 mol% glycolide, presenting number-average molecular weight (*Mn*) of 250,000, and was used as obtained, without previous purifications or processing. The IR (Mafer – Brazil) in the natural latex structure centrifuged at 60%, presenting *Mn*=295,000. The PLGA/PI blends were prepared at the desired ratio (60%/40% w/w), dissolved in chloroform and subjected to magnetic stirring for homogenization, as previously reported^[11]. PLGA copolymer was dissolved in chloroform during conformation process.

Both the copolymer and the blends were dried for 24h and cut into 2×2mm square samples and sterilized in ethylene oxide.

Implantability sample size and population

Sample size was calculated using the *winpepi* 10.5 software and was based on previous studies by Dadas et al.^[16]. For a significance level of 5%, 80% statistical power, and an effect size of at least 2 standard deviations between the groups, the minimum sample size was established at 5 individuals in each subgroup, for a total of 40 rats.

Based on this calculation, 46 male Wistar rats (*Rattus norvegicus*, albino), aged 67 days and with an average body mass of 273.63 g, were allocated to Groups 1 and 2 according to the type of material selected for implantation, and further divided into four subgroups according to the timing of euthanasia, which was performed at 15, 30, 60, or 90 days after implantation. The 15, 30, and 60-day subgroups had 10 animals each, and 6 animals were added (3 for each type of material) to the 90-day subgroup. This

decision was based on previous study by Cardoso et al., that proposes 90 days as the time required for hydrolyzation of poly(dioxanone)/poly(L-lactic acid) copolymer in the rabbit knees^[17].

Operative technique

All surgical procedures were performed at the Animal Experimentation Unit of Clinics Hospital de Porto Alegre (HCPA). Anesthesia was induced with ketamine (100 mg/kg intraperitoneally; Vetbrands, Jacareí, São Paulo, Brazil) and xylazine (10 mg/kg subperitoneally; Vetbrands, Jacareí, São Paulo, Brazil). Bupivacaine 0.5% (1 mg/kg) was administered for local anesthesia. After induction, the rats were weighed and the head region was shaved. The animals were placed on the operating table in prone position and antiseptis performed with aqueous iodophor solution followed by placement of sterile gauze fields. An L-shaped incision was made so as to leave the area of the material isolated from the excised and sutured area. A flap was then raised and the periosteum of the skull cap opened and folded at the site of the future defect. The size of the defect was then marked with a pen (Figure 1).

Full-thickness bone defects were fashioned with a flexible, double-faced diamond cutting disc (KG Sorensen, Brazil) in the region of the parietal bone, with the shape and size of the material to be implanted. Then, a delicate periosteal elevator was used to open the defect, minimizing meningeal lacerations. After removal of the skull flap, the polymer sample (PLGA or PLGA/PI, depending on group allocation) was implanted under slight pressure and the wound closed with simple sutures. Subsequently, the animals were placed in an incubator for recovery.

In the postoperative period, the animals were kept five to a cage under 12-hour light/dark cycles, with access to water and food *ad libitum*. Analgesia was provided with tramadol (1 mg/kg, intramuscularly every 8 hours, two doses; Carlo Erba S. A., Duque de Caxias, Brazil).

The animals were euthanized on postoperative day 15, 30, 60, or 90 according to subgroup allocation. Euthanasia was performed in a CO₂ chamber in accordance with routine HCPA Animal Experimentation Unit protocols.

This study was approved by the HCPA Research Ethics Committee under judgment number 10-511 and conducted so as to minimize pain and suffering. All procedures followed the bioethical rules established by the HCPA Graduate Research Group and the HCPA Animal Experimentation Unit, and were performed in compliance with current legislation on animal research.

Histological analysis

After death, the skull cap and implanted biomaterial were removed *en bloc* for histological analysis. The fragments containing the respective biomaterial and bone tissue were resected and fixed in 10% formalin. The material was then decalcified in 10% nitric acid solution for at least 36 hours, embedded in paraffin, and cut lengthwise into 4 µm-thick slices. These specimens then underwent routine

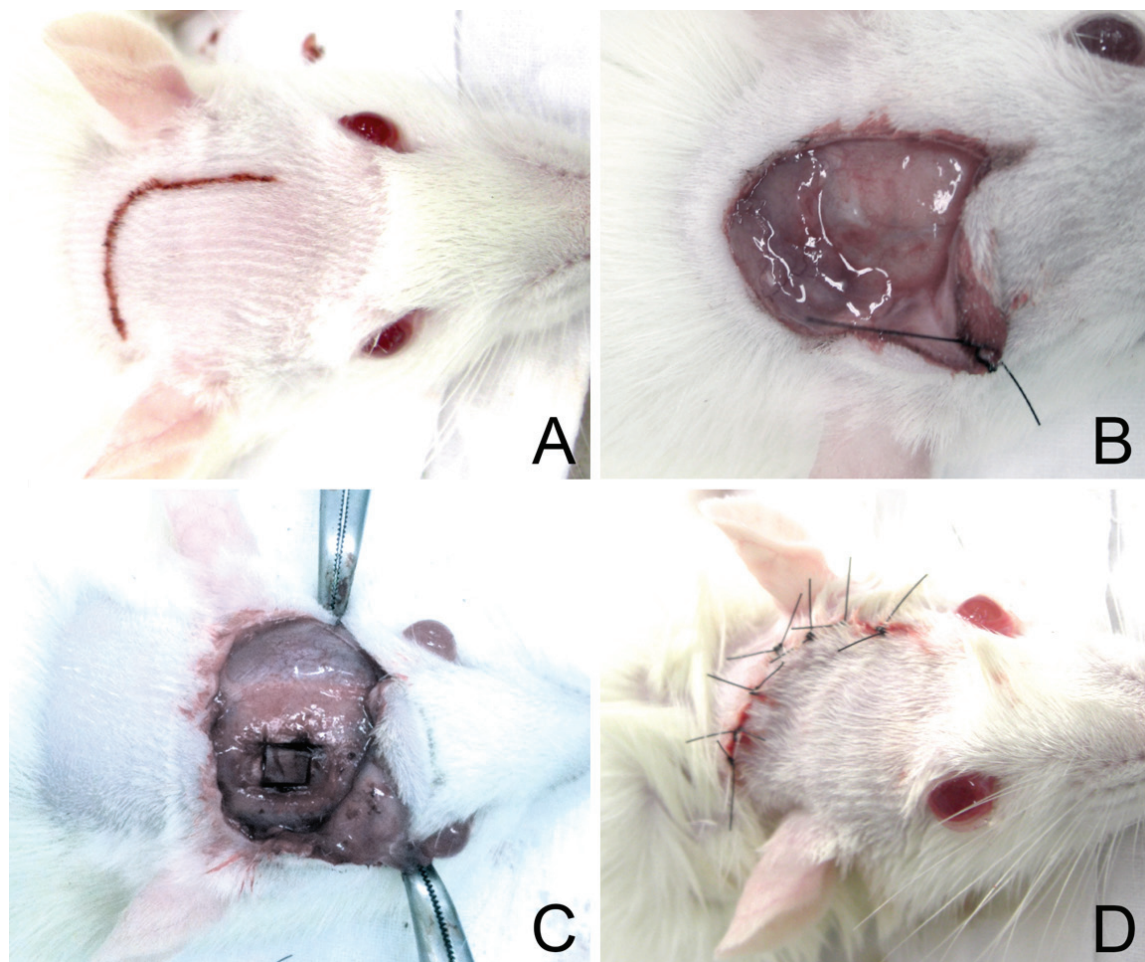


Figure 1. A) Anesthetized and positioned rat, with the area shaved and incision marked on skin; B) Opening of the periosteum; C) Material placed tightly against the bone defect; D) Suture.

histological processing and staining with hematoxylin and eosin (H&E), which yielded 46 slides.

Histological analysis was performed by observation of tissue reaction by two blinded pathologists and scored by the modified Dadas et al. score^[16]. The original score was modified because it was designed due to an inversion in severity grading in item 5. This feature of the original score was rather senseless, with scores worsening as bone reaction improved. The score was classified as follows:

1. Foreign body reaction (0 absent, 1 present).
2. Degree of inflammation (0 absent, 1 slight, 2 moderate, 3 severe, 4 severe with tissue necrosis).
3. Fibrosis (0 absent, 1 slight, 2 moderate, 3 severe).
4. Granulation tissue (0 absent, 1 slight).
5. Tissue reaction (0 bone formation, 1 bone callus, 3 fibrocartilage).
6. Structure of the newly formed tissue (0 normal, 1 proliferative).

The total score is considered to be the sum of the 6 items, ranging from 0 to 13. As some items are interpreted

subjectively, the score was established according to the following criteria, exposed in Figure 2.

Statistical analysis

The dependent variable of the study is the histological score, and the independent variables are type of biomaterial and timing of euthanasia. Scores obtained with the two materials were compared individually. The Shapiro-Wilk test was used to evaluate the distribution of the histological score, and yielded a value of $p=0.256$, that is, the distribution was considered normal. Two-way analysis of variance (ANOVA) was then performed. The significance level was set at $p=0.05$. Inter-observer agreement was assessed by means of the Bland-Altman coefficient with randomization of 20 rats from the sequence of pathological observation^[18].

Results

There was no significant differences in the average histological scores of the two evaluators (6.0 ± 2.1 vs. 6.4 ± 1.9 ; $p=0.185$). When agreement was evaluated using

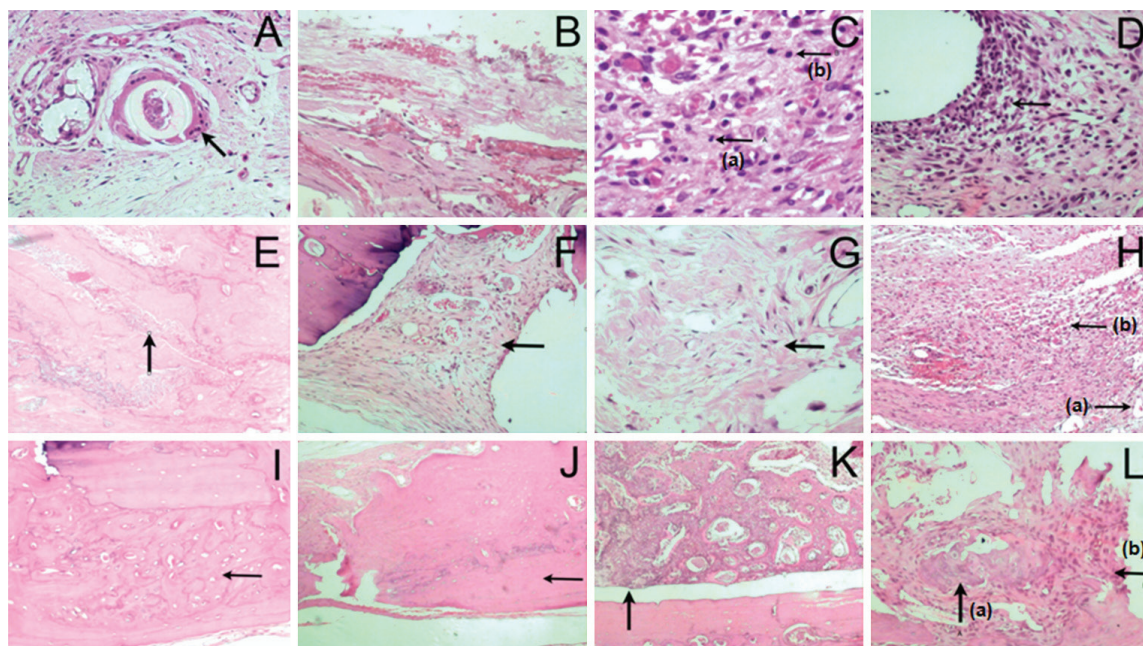


Figure 2. A) Presence of foreign body with surrounding reaction and multinucleated giant cell; B) Mild inflammation: scant mononuclear cells amid fibrosis and vascular proliferation; C) Presence of mild inflammatory reaction with abundant neutrophils (a) and macrophages (b); D) Presence of severe inflammatory reaction with several mononuclear cells and neutrophils; E) Mild fibrosis: bands of fibrosis amid bone tissue; F) Moderate fibrosis: young fibroblasts and dilated and congested blood vessels; G) Severe fibrosis: extensive area of fibrosis with mature fibroblasts and thick fibrosis; H) Granulation tissue: vascular proliferation (a), mononuclear cells, edema and polymorphonuclear leukocytes (b); I) Normal bone tissue: bone lamellae with regular distribution, small, spindle-shaped osteocytes; J) Proliferative bone tissue: bone lamellae with irregular distribution, larger osteocytes in irregular spaces, K) Proliferative bone callus; L) Fibrocartilaginous proliferative tissue: cartilage (a) and fibrosis (b).

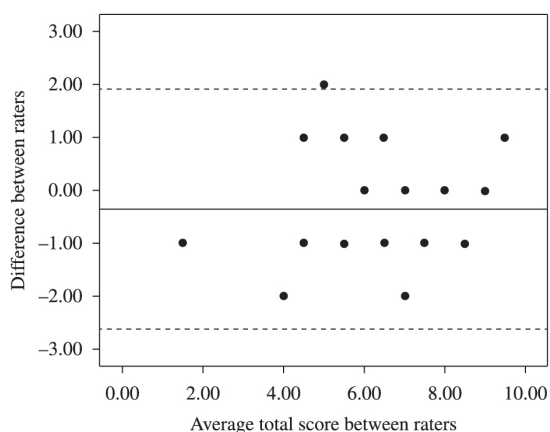


Figure 3. Inter-rater agreement according to the Bland–Altman method. The central line represents the average of differences. The upper and lower dotted lines represent the upper and lower limits of agreement (95% confidence interval).

the Bland–Altman method, disagreement occurred only in one animal (5%), as shown in Figure 3. Taking into account that the greatest subjectivity in scoring occurs in the items degree of inflammation and degree of fibrosis, there was significant agreement between the two evaluators ($\kappa > 0.5$; $p \leq 0.001$).

The average histological scores per group and timing of euthanasia are shown in Table 1. In the blend group, there was a significant reduction of the histological score from 15 to 30 days ($p=0.002$) and from 60 to 90 days ($p<0.001$); however, there was a significant increase from 30 to 60 days ($p<0.001$). In the copolymer group, a similar result was observed from 15 to 30 days ($p=0.002$). However, from 30 to 60 days ($p=0.403$) and from 60 to 90 days ($p=0.310$), the difference was not statistically significant, but the behavioral curve was similar.

When the groups were compared as to timing of euthanasia, there was a statistically significant interaction by two-way ANOVA ($F=3.52$; $\text{dof}=3.39$; $p=0.024$). As it was observed, there was a significant difference between the groups in the 60 days of death ($p<0.001$). This difference is probably attributable to the items degree of inflammation, fibrosis, and granulation tissue, as shown in Table 2.

Macroscopic visual analysis of the implanted material demonstrated the stability of the PLGA copolymer across all euthanasia subgroups, but the PLGA/PI blend showed an erosion-like change at the edges at 60-day follow-up, as shown in Figure 4.

Discussion

PLGA has been established as a desirable biomaterial since the 1970's, when its application as suture began.

Table 1. Evaluation of histological score per group and timing of euthanasia.

Group	Timing of euthanasia	Histological score			Differences	
		Mean±SD	15-30 days	30-60 days	60-90 days	
PLGA/PI	15	7.6±0.5	-2.0	2.9	-2.6	
	30	5.6±1.1				
	60	8.5±0.5				
	90	5.9±0.6				
PLGA	15	8.4±0.9	-3.2	1.4	-1.3	
	30	5.2±0.8				
	60	6.6±0.5				
	90	5.3±1.6				

Table 2. Evaluation of histological score items according to group allocation and timing of euthanasia.

Items	15 days		30 days		60 days		90 days	
	PLGA/PI	PLGA	PLGA/PI	PLGA	PLGA/PI	PLGA	PLGA/PI	PLGA
	n (%)	n (%)	n (%)	n (%)	n (%)	n (%)	n (%)	n (%)
Foreign body	5 (100)	5 (100)	5 (100)	4 (80)	6 (100)	5 (100)	8 (100)	6 (75)
Inflammation								
Absent	0 (0)	0 (0)	0 (0)	0 (0)	0 (0)	0 (0)	0 (0)	1 (12.5)
Mild	2 (40)	1 (20)	5 (100)	5 (100)	3 (50)	5 (100)	7 (87.5)	7 (87.5)
Moderate	2 (40)	3 (60)	0 (0)	0 (0)	3 (50)	0 (0)	1 (12.5)	0 (0)
Severe	1 (20)	1 (20)	0 (0)	0 (0)	0 (0)	0 (0)	0 (0)	0 (0)
Fibrosis								
Mild	1 (20)	0 (0)	2 (40)	3 (60)	0 (0)	0 (0)	0 (0)	1 (12.5)
Moderate	4 (80)	3 (60)	3 (60)	2 (40)	0 (0)	5 (100)	7 (87.5)	6 (75.0)
Severe	0 (0)	2 (40)	0 (0)	0 (0)	6 (100)	0 (0)	1 (12.5)	0 (0)
Tissue gran.	5 (100)	5 (100)	1 (20)	0 (0)	6 (100)	3 (60)	8 (100)	7 (87.5)
Tissue reaction								
Bone	0 (0)	0 (0)	1 (20)	0 (0)	0 (0)	0 (0)	8 (100)	8 (100)
Callus	5 (100)	5 (100)	4 (80)	5 (100)	6 (100)	5 (100)	0 (0)	0 (0)
Neoformation								
Normal	0 (0)	0 (0)	0 (0)	0 (0)	0 (0)	0 (0)	3 (37.5)	2 (25.0)
Proliferative	5 (100)	5 (100)	5 (100)	5 (100)	6 (100)	5 (100)	5 (62.5)	6 (75.0)

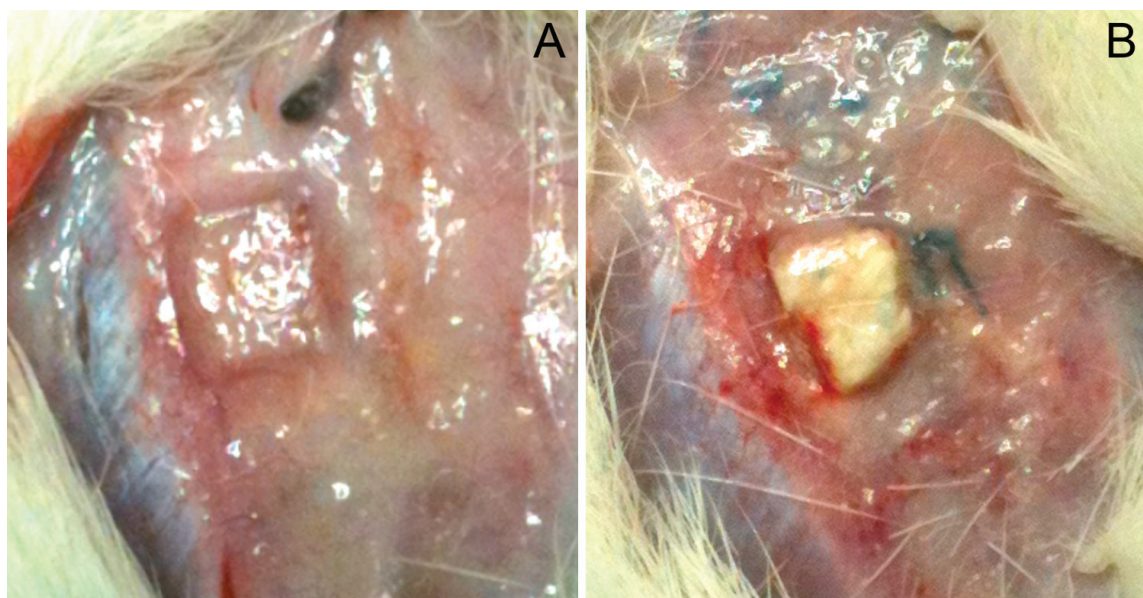


Figure 4. A) PLGA copolymer at 60 days postoperatively; B) PLGA / PI blend at 60 days postoperatively.

Nowadays, researches about his application in bone environment reinforce its characteristics, been object of study in areas such bone replacement, bone filling and tissue engineering. Its application vary in conformation, been a porous structure or microspheres to enhance ceramics properties. However, the reports for *in vivo* studies are majorly satisfactory, classifying this copolymer as almost unquestionable^[19-23].

On the other hand, the application of PI in contact with bone tissue is barely reported. The configuration trans 1,4 Poly(Isoprene), commonly known as Gutta-Percha, is widely applied in dentistry, but as a filling agent in soft tissue, whilst its applicability in dental environment remains imprecise^[24,25]. A study conducted by Molina et al. concluded the tolerability of alveolar bone to cis 1,4 Poly(Isoprene), without any outstanding findings about the material behavior in osteo environment^[26]. Previous citotoxicity studies *in vitro* showed that the PLGA/PI blend doesn't present relevant toxicity when assessed by hepatic cells^[11].

In this study, a similar histotoxic behavior was noted in both groups, with a decrease in histotoxicity from days 15 to 30, an increase between 30 and 60 days, and once again a decrease from days 60 to 90. This variation was significant in PLGA/PI group in all periods, and only significant from days 15 to 30 in PLGA group. One explanation for this phenomenon is a decrease in the inflammatory reaction to surgical trauma from days 15 to 30 and hydrolysis of PLGA (present in both materials) with release of PI granules in the blend group, which would have increased the inflammatory reaction and fibrosis. In the copolymer group, it can be presumed that the hydrolyzation process began the superficial break and activated the enzymatic system that processed the material, with no significant increase in histotoxicity at 60 days postoperatively. This is shown by the irregularity of the blend surface at postoperative day 60. Therefore, the variation of tissue reaction in the copolymer group was much milder than in the blend group.

At postoperative day 60, there was a statistically significant interaction with increased histotoxicity in the PLGA/PI group. Previous studies of implantation of Poly(Isoprene) material in the human eardrum and conjunctival membrane showed no evidence of significant clinical toxicity^[27,28]. However, on histological analysis, Balabanian et al. found a severe inflammatory reaction up to 7 days after implantation of latex in rat alveoli. As Poly(Isoprene) is not resorbable, it produced a foreign body reaction, with a severe fibrosis that was replaced gradually by lamellar bone tissue until postoperative day 42^[15].

Some mitigation procedures can also be adopted if an increased risk with the PLGA/PI blend is confirmed. PI can be treated with proteolytic enzymes or by addition of polar solvents, which reduces its antigenicity by 50%^[29]. Although, the histotoxicity of the PLGA/PI blend at 60 days was not statistically greater than that of the PLGA copolymer at 15 days. Therefore, one may presume that the increased histotoxicity observed in the blend group at 60 days does not pose any potential risk for use in the clinical setting, as PLGA copolymer is already widely used.

Formation of callus after 60 days may be seen as a natural reaction from the body to keep the fracture vascularized and structurally supported. As a consequence, the regenerated bone formation was observed after 90 days^[30]. By this point of observation, both groups showed fibrosis majorly moderated, mild inflammation and stable formation of granulation tissue. This response points the bioadaptability of both groups, as well as the body capacity to tolerate the material.

Conclusions

The histotoxicity of the PLGA / PI blend was similar to that of PLGA copolymer in 15 and 30 day euthanasia groups, as well as in the long term, after 90 days. The PLGA/PI blend showed greater histotoxicity in animals euthanized at 60 days, although in this period the histotoxicity of the PLGA/PI blend was similar to that of the PLGA copolymer at 15 days. Despite the instability of histological response presented in different periods of observation, the results obtained in long term show the material with high potential for studies in craniostylosis treatment.

Acknowledgements

The authors would like to thank the Coordenadoria de Aperfeiçoamento de Pessoal de Nivel Superior (CAPES) and the Conselho Nacional de Desenvolvimento Científico e Tecnológico (CNPq) for the financial support of this study.

References

1. Virchow, R. - Verh. Phys. Med., **2**, p.230 (1851).
2. Di Rocco, F.; Arnaud, E.; Meyer, P.; Sainte-Rose, C. & Renier, D. - Childs Nerv. Syst., **25**, p.807 (2009). PMID:19357856.
3. Scott, J. R.; Isom, C. N.; Gruss, J. S.; Salemy, S.; Ellenbogen, R. G.; Avellino, A.; Birgfeld, C. & Hopper, R. A. - Plast. Reconstr. Surg., **123**, p.289 (2009). <http://dx.doi.org/10.1097/PRS.0b013e31819346d1>
4. Kapp-Simon, K. A.; Leroux, B.; Cunningham, M. & Speltz, M. L. - Cleft Palate Craniofac. J., **42**, p.377 (2005). PMID:16001919. <http://dx.doi.org/10.1597/04-044.1>
5. Guimarães-Ferreira, J.; Gewalli, F.; David, L.; Maltese, G.; Heino, H. & Lauritzen, C. - Plast. Reconstr. Surg., **109**, p.1325 (2002). PMID:11964985.
6. Lauritzen, C. G.; Davis, C.; Ivarsson, A.; Sanger, C. & Hewitt, T. D. - Plast. Reconstr. Surg., **121**, p.545 (2008). PMID:18300975. <http://dx.doi.org/10.1097/01.prs.0000297638.76602.de>
7. Davis, C.; Windh, P. & Lauritzen, C. G. - Plast. Reconstr. Surg., **123**, p.470 (2009). PMID:19182603. <http://dx.doi.org/10.1097/PRS.0b013e3181954ce3>
8. Pandey, A.; Pandey, G. & Aswath, P. - J. Mech. Behav. Biomed. Mat., **1**, p.227 (2008). PMID:19627787. <http://dx.doi.org/10.1016/j.jmbm.2007.12.001>
9. Rezende, C. A. & Duek, E. A. R. - Polímeros, **13**, p.36 (2003). <http://dx.doi.org/10.1590/S0104-14282003000100009>
10. Isotalo, T. M.; Nuutinen, J. P.; Vaajanen, A.; Martikainen, P.; Laurila, M.; Törmälä, P.; Talja, M. & Tammela, T. L. - BJU Intern., **97**, p.856 (2005).
11. Marques, D. R.; Santos, L. A.; Schopf, L. F. & Fraga, L. C. S. - Polímeros, **23**, p.579 (2013).
12. Marques, D. R. - "Obtenção e caracterização de blendas poliméricas de poli (ácido láctico-co-glicólico) e poli (isopreno) para aplicação como biomaterial", Dissertação de

- Mestrado, Universidade Federal do Rio Grande do Sul, Brasil (2011).
13. Bodrumlu, E. - Australian Endodontic. J., **34**, p.30 (2008). PMID:18352901. <http://dx.doi.org/10.1111/j.1747-4477.2007.00085.x>
 14. Scisłowska-Czarnecka, A.; Pamula, E.; Tlalka, A. & Kolaczowska, E. - J. Biomat. Sci., **23**, p.715 (2012). PMID:21375810. <http://dx.doi.org/10.1163/092050611X559421>
 15. Balabanian, C. A.; Coutinho-Netto, J.; Lamano-Carvalho, T. L.; Lacerda, S. A. & Brentegani, L. G. - J. Oral Sci., **48**, p. 201 (2006). <http://dx.doi.org/10.2334/josnusd.48.201>
 16. Dadas, B.; Alkan, S.; Cifci, M. & Basak, T. - Eur. Arch. Otorhinolaryngol., **264**, p.539 (2007). PMID:17203306.
 17. Cardoso, T. P.; Duek, E. A. R.; Amatuzzi, M. M. & Caetano, E. B. - Rev. Bras. Ortop., **45**, p.247 (2010).
 18. Hirakata, V. N. & Camey, S. A. - Rev. HCPA, **29**, p.261 (2009).
 19. Penk, A.; Förster, Y.; Scheidt, H. A.; Nimptsch, A.; Hacker, M. C.; Schulz-Siegmund, M.; Ahnert, P.; Schiller, J.; Rammelt, S. & Huster, D. - Magn. Reson. Med., **70**, p. 925 (2013). PMID:23165861. <http://dx.doi.org/10.1002/mrm.24541>
 20. Félix Lanao, R. P.; Leeuwenburgh, S.; Wolke, J. G. & Jansen, J. A. - Biomaterials, **32**, p.8839 (2011). PMID:21871661. <http://dx.doi.org/10.1016/j.biomaterials.2011.08.005>
 21. Hoekstra, J. W. M.; Ma, J.; Plachokova, A. S.; Bronkhorst, E. M.; Bohner, M.; Pan, J.; Meijer, G. J.; Jansen, J. A. & Van Den Beucken, J. J. - Acta Biomater., **9**, p.7518 (2013). PMID:23511808. <http://dx.doi.org/10.1016/j.actbio.2013.03.007>
 22. Schneider, O. D.; Mohn, D.; Fuhrer, R.; Klein, K.; Kämpf, K.; Nuss, K. M.; Sidler, M.; Zlinszky, K.; Von Rechenberg, B. & Stark, W. J. - Open Orthop J., **5**, p.63 (2011). PMID:21566736 PMCid:PMC3092473. <http://dx.doi.org/10.2174/1874325001105010063>
 23. Schloegl, W.; Marschall, V.; Witting, M.; Volkmer, E.; Drosse, I.; Leicht, U.; Schieker, M.; Wigggenhorn, M.; Schaubhut, F.; Zahler, S. & Friess, W. - Eur. J. Pharm. Biopharm., **82**, p.554 (2012). PMID:22947486. <http://dx.doi.org/10.1016/j.ejpb.2012.08.006>
 24. Monteiro, J.; Ataíde, I. N.; Chalakkal, P. & Chandra, P. K. - J. Endodont., **37**, p.828 (2011). PMID:21787498. <http://dx.doi.org/10.1016/j.joen.2011.02.024>
 25. Schäfer, E.; Nelius, B. & Bürklein, S. - Clin. Oral Invest., **16**, p.225 (2012). PMID:21249509. <http://dx.doi.org/10.1007/s00784-011-0509-z>
 26. Molina, G. O.; Oliveira, M. T.; Buss, L.; Peruchi, J. D. F.; Pereira, J. R. & Ghizoni, J. S. - Braz. J. Oral Sci., **12**, p.184 (2013). <http://dx.doi.org/10.1590/S1677-32252013000300007>
 27. Pinho, E. C. C. M. "O uso da biomembrana de látex natural comparado ao transplante conjuntival autólogo na superfície ocular" Tese de Doutorado, Universidade de São Paulo, Brasil (2011).
 28. Oliveira, J. A. A.; Hyppolito, M. A.; Coutinho Netto, J. & Mrué, F. - Rev. Bras. Otorrinolaringol., **69**, p.649 (2003). <http://dx.doi.org/10.1590/S0034-72992003000500010>
 29. Amnuayporn Sri, S.; Sakdapipanich, J. & Tanaka, Y. - J. Appl. Polym. Sci., **118**, p.3524 (2010). <http://dx.doi.org/10.1002/app.32699>
 30. Reichert, W. M. - "Indwelling neural implant", CRC Press, Boca Raton (2008).

Received: Sept. 23, 2013

Revised: Apr. 10, 2014

Accepted: May 05, 2014