

Accuracy of computer-assisted surgery in immediate implant placement: An experimental study

Nicole Báez-Marrero, José Luis Rafel,¹ Yalil Augusto Rodríguez-Cárdenas,² Aron Aliaga-Del Castillo,³ Heraldo Luis Dias-Da Silveira,⁴ Luis Ernesto Arriola-Guillén⁵

Division of Oral and Maxillofacial Radiology, School of Dentistry, Universidad Científica del Sur, ⁵Division of Orthodontics, School of Dentistry, Universidad Científica del Sur, Lima, Peru, ¹Private Practice, Santo Domingo, Dominican Republic, ²Division of Oral and Maxillofacial Radiology, Faculty of Dentistry, Universidad Nacional de Colombia, Bogotá, Colombia, ³Department of Orthodontics, Bauru Dental School, University of Sao Paulo, São Paulo, ⁴Division of Oral Radiology, Faculty of Dentistry, Federal University of Rio Grande do Sul, Porto Alegre, Brazil

The work belongs to the Department of Oral and Maxillofacial Radiology, School of Dentistry, Universidad Científica del Sur University, Lima, Perú

Abstract:

Purpose: Computer-guided surgery has been increased in recent years. Nonetheless, few data are available on the validation of this technique for immediate implant placement. The purpose of this *in vitro* study was to evaluate the accuracy of computer-guided surgery in immediate implant placement. **Materials and Methods:** Cone-beam computed tomography scans (CBCTs) and virtual models were obtained of eight fresh pigs hemi-mandibles to perform the digital planning of implants placement. Fifteen implants were simulated, and surgical guides were designed to transfer the digital planning to the surgical procedure. Postsurgical CBCTs were performed to compare the position of the planned implants versus the real implant position. Paired *t*-test and the intra-class correlation coefficient (ICC) were used to assess the mean differences and correlations in each outcome variable evaluated twice by one experienced researcher. Furthermore, variations were compared with the results reported in the scientific literature using a one-sample *t*-test $P < 0.05$. **Results:** The measurements of the outcome variables (implants position at the neck and apex level and the angular deviation) showed significant reproducibility (mean difference-0.01 mm, 0.07 mm, and 0.30°, respectively, $P > 0.05$). The ICC values ranged from 0.888 to 0.949. Furthermore, the mean deviation was 1.43 mm at the implant neck, 2.19 mm at the apex, and 6.81° for the angular deviation. Similarly, significant differences ($P < 0.05$) were found at the neck and angular deviation when comparing the results with values reported in the literature. **Conclusions:** Although some variations were observed, they did not have a clinically significant impact. Therefore, computer-guided surgery could be satisfactorily used in immediate implants placement.

Key words:

Computer-assisted surgery, cone-beam computed tomography, immediate implant placement, surgical accuracy

INTRODUCTION

Proper positioning, angulation, and direction of dental implants are essential to achieve the success of both surgical and prosthesis treatment, and specifically to obtain predictable functional, esthetic, and hygienic results.^[1,2] The immediate implant placement reduces chair time, favoring both the clinician and the patient.^[3,4] It represents an effective technique for replacing lost teeth with a high survival rate.^[5,6] Nevertheless, the biological complications that may occur as dimensional changes at the level of crestal bone, peri-implantitis, and deficiency in primary stability remain a matter of discussion.^[7,8] However, no statistically significant differences have been reported regarding the advantages or disadvantages of immediate implant placement versus delayed placement.^[9]

The advent of computer-aided implant planning with the use of cone-beam computed tomography scans (CBCTs) and virtual models has provided new alternatives to achieve an even more accurate and predictable treatment according to

the needs of each patient.^[10,11] Computer-guided surgery allows implant planning considering the bone support and the virtual prosthesis and offers the clinician the ability to transfer the planning to the surgical procedure.^[12-16] In addition, it provides greater functional and esthetic results in complex cases.^[17,18] Several authors have indicated that clinicians must take precautions to achieve success in the surgical

This is an open access journal, and articles are distributed under the terms of the Creative Commons Attribution-NonCommercial-ShareAlike 4.0 License, which allows others to remix, tweak, and build upon the work non-commercially, as long as appropriate credit is given and the new creations are licensed under the identical terms.

For reprints contact: WKHLRPMedknow_reprints@wolterskluwer.com

How to cite this article: Báez-Marrero N, Rafel JL, Rodríguez-Cárdenas YA, Aliaga-Del Castillo A, Dias-Da Silveira HL, Arriola-Guillén LE. Accuracy of computer-assisted surgery in immediate implant placement: An experimental study. *J Indian Soc Periodontol* 2022;26:219-23.

Access this article online	
Website:	www.jisponline.com
DOI:	10.4103/jisp.jisp_763_20
Quick Response Code:	

Address for correspondence:

Dr. Luis Ernesto Arriola-Guillén, Av. Arequipa 4861, Miraflores, Lima, Peru. E-mail: luchoarriola@gmail.com

Submitted: 26-Oct-2020

Accepted: 14-Mar-2021

Published: 27-Sep-2021

procedure. Although it is a method with greater accuracy to bring implant planning to the clinical procedure, some linear and angular variations have been reported.¹¹⁹⁻²¹¹

Van Assche *et al.*¹²² described in their pilot *ex vivo* study, with a sample of 12 implants, angular deviations with a mean of $2^\circ \pm 0.8^\circ$ in implants with a range length of 10–15 mm. While the horizontal deviation at the apex was on average $1.1 \text{ mm} \pm 0.7 \text{ mm}$ and $2.0 \text{ mm} \pm 0.7 \text{ mm}$ at the neck level. The authors concluded that CBCTs is a valid image technique that can be used for implant planning, taking into account that angular deviations up to 4° and horizontal deviations at the apex and platform up to 2.4 mm may occur.

Different factors could cause deviations in implant placement using a surgical guide.¹²³ It can be attributed to the type of retention of the surgical guide, the splints with anchor pins have been reported as the most precise ones.¹²⁴ The guides for initial drilling shows greater deviation than the fully guided technique.¹²⁵ One study reported factors related to the proper design of the surgical guide, such as the offset in diameter between the drilling system and the guide sleeve.¹²⁶ Implant deviations could happen at different moments: (1) Obtaining the presurgical examinations (patient motion at the CBCT scan),¹²⁵ (2) in the planning and design of the surgical guide (correct match between digital model and CBCT scan),¹²⁷ and (3) in the surgical procedure (lack of stability of the guide).¹²⁸

Chen *et al.*¹²⁹ compared the accuracy of guided versus conventional surgery for immediate implant placement concluding that the guided surgery technique showed superior accuracy. However, even with the help of a surgical splint, the final position of the implants tends to be directed toward the buccal cortical plate when compared to the initial planning. In this way, the available literature is inconclusive regarding this subject. For this reason, the purpose of this study was to evaluate the accuracy of computer-guided surgery in immediate implant placement.

MATERIALS AND METHODS

Ethical approval for this study was obtained by Ethics in Research Committee of Científica del Sur University (Lima, Perú) with the registration number 094-2019-POSS.

Sample characteristics and sample size

In order to simulate a clinical scenario, eight fresh hemi-mandibles from cadaveric pigs were used, avoiding the use of methanol. All swine jaws were obtained from the Anatomy Department of Iberoamericana University, Santo Domingo, Dominican Republic. They were maintained frozen at -20°C once selected and maintained at the room temperature at the time of the experiment.

The inclusion criteria comprised: (1) Teeth with two roots: mesial and distal (2) presence of teeth adjacent at distal to the area of interest to allow the stability of the surgical splint (3) appropriate surrounding bone tissue to allow the primary stability of the implants and (4) areas with favorable bone thickness adjacent to the teeth for anchor pins placement. These criteria were evaluated in presurgical CBCTs. Thus, 15 favorable areas were considered to planning the implant placement.

Imaging of the hemi-mandibles

The CBCT scans were performed in the eight swine hemi-mandibles. The tomographic exposure was carried out with the ProMax three dimensional (3D) Max equipment (Planmeca, Helsinki, Finland). The parameters for obtaining the image were: $200 \mu\text{m}$ voxel size, 90 kV, 6 mA and $8 \text{ cm} \times 8 \text{ cm}$ field of view for obtaining digital image and communication in medicine (DICOM) files. Then, the surface scan was obtained with the TRIOS-4 intraoral scanner (3Shape, Copenhagen, Denmark) to obtain the files in stereolithography (STL) format [Figure 1].

Digital planning for implant placement

The DICOM and STL files were imported into the digital planning software NemoScan (Nemotec, Madrid, Spain), in which a specialist in Oral and Maxillofacial Radiology with experience in digital implant planning carried out the planning by matching the files to plan the position of the implants to be placed with emergence in dentate areas. A total of 15 AB implants (AB Dental, Ashdod, Israel) distributed among eight pig hemi-mandibles were simulated. Eight surgical guides were generated based on this planning according to the software instructions for each of the samples considering the parameters of the AB guided surgical kit (AB Dental, Ashdod, Israel). For the three-dimensional printing of the splints, the Form-2 3D digital printer (FormLabs, Massachusetts, United States) was used [Figure 2].

Surgical procedure

A dental surgeon performed the extraction of the teeth. Considering the root morphology, tooth section was performed in each tooth allowing the dislocation of both roots while preserving the integrity of the remaining bone. Root traction was performed completely in all areas. In three cases (hemi-mandibles 2, 7, and 8), bone spicules were detached by traction of the teeth. The adaptation and stability of the surgical splints were verified. In all cases, the surgical guides had dental support in the distal area and mucous support in the mesial area. A slight degree of tilt was evidenced in relation to the support; however, anchor pins were placed on the buccal or lingual surfaces to improve the fixation. A specialist in oral implantology with clinical experience in guided surgery, performed implant placement according to the protocol of the AB guided system (AB Dental, Ashdod, Israel) which uses surgical splints with 5.2 mm diameter sleeves, reduction spoons according to the drilling sequence and implant insertion tool with stoppers for the placement of 15 implants through the guide's sleeves.

Postsurgical imaging

Subsequently, a new CBCT scan of each of the hemi-mandibles was obtained with the same technical parameters used at the presurgical stage.

Outcome variables measurements and reliability

The pre- and post-surgical CBCT scans were unified by combining common bone and dental anatomical references to make the analysis of the variations using software NemoScan (Nemotec, Madrid, Spain).

The real position of the implants in relation to the planned position was evaluated comparatively, considering as

variables: the global deviation at the neck and the apex of the implants (mm) and the angular variation between the axis of both implants (°) [Figure 3].

All measurements were performed by one experienced and trained researcher twice for the entire sample.

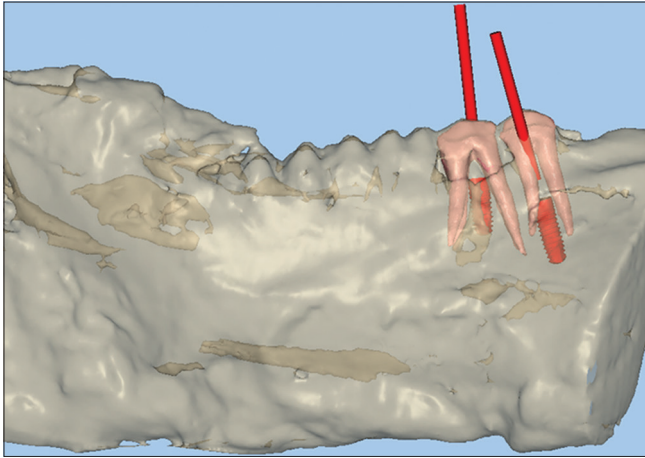


Figure 1: Digital implant planning in dentate areas of the hemi-mandible

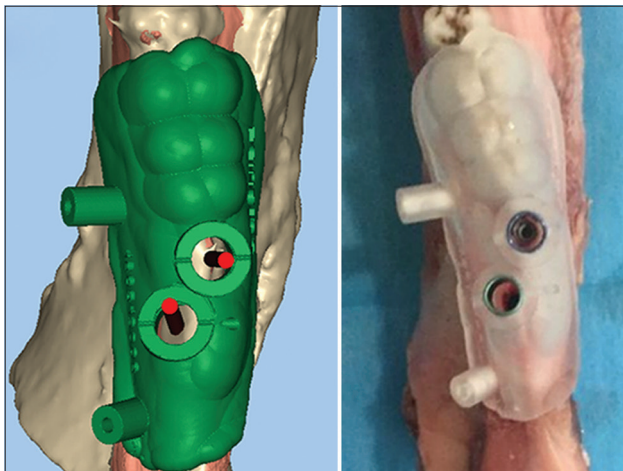


Figure 2: Surgical guide design

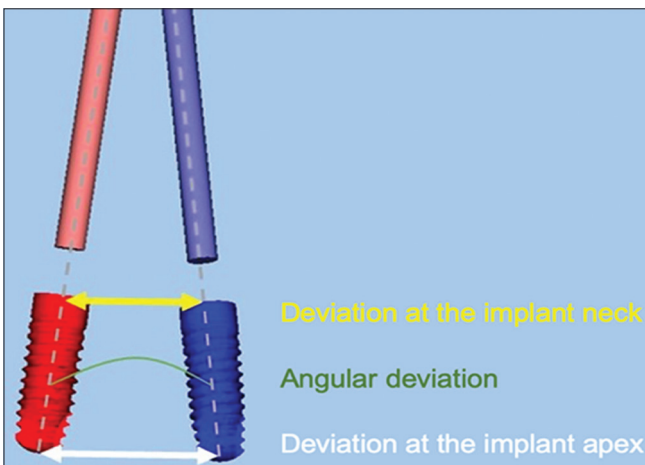


Figure 3: Graphic showing the outcome variables of the study

Statistical analysis

All statistical analyses were performed with the SPSS software (version 19.0; IBM, Armonk, NY, USA). The intra-observer reliability was evaluated using the paired *t*-test and intraclass correlation coefficient (ICC). In addition, one sample *t*-test was performed using values reported in the literature as references.^[22] Significance level was set at *P* < 0.05 for all tests.

RESULTS

The comparison between the two measurements of the same outcome variables (implants position at the neck or apex level, and the angular variation) showed no statistically significant differences. Mean differences of -0.01 mm, 0.07 mm and 0.30° were found for each variable, respectively [Table 1]. In addition, the ICC values ranged from 0.888 to 0.949 [Table 2] demonstrating good to excellent reliability.

The variations between real and planned position and angulation of the implants ranged between 0.60 mm and 2.50 mm with a mean of 1.43 mm ± 0.60 for the position at the implant neck, between 1.20 mm and 3.40 mm with a mean of 2.19 mm ± 0.63 for the position at the implant apex, and from 0.60° to 13.10° with a mean of 6.81° ± 3.10° for the angular variation [Table 3].

The results show concordance in the apex position according to a previous study reported in the literature in which the accuracy of computer-guided surgery in edentulous areas was measured.^[22] Statistically significant differences were found in the variables of the neck position and angular variation [Table 4].

DISCUSSION

Based on the results of this study, it is possible conclude that computer-guided surgery can be used in immediate implant placement considering a maximum angular variation of 13.10°, 2.5 mm at the implant neck and 3.4 mm at the implant

Table 1: Intraobserver fiability evaluation in all outcome variables

Variable	n	Mean±SD	Mean differences	P
Variation at implant neck 1	15	1.43±0.60	-0.01	0.894
Variation at implant neck 2	15	1.44±0.60		
Variation at implant apex 1	15	2.19±0.63	0.07	0.238
Variation at implant apex 2	15	2.13±0.68		
Angular variation 1	15	6.81±3.10	0.30	0.450
Angular variation 2	15	6.51±3.20		

P < 0.05 significant, Paired *t*-test. *n* - Sample size; SD - Standard deviation; *P* - *P* value

Table 2: Intraobserver reliability evaluation in all outcome variables

Variable	Intraclass correlation ICC	95% CI (upper limit-lower limit)	P
Variation at implant neck	0.949	0.857-0.983	<0.001
Variation at implant apex	0.949	0.855-0.983	<0.001
Angular variation	0.888	0.699-0.961	<0.001

P < 0.05 significant. CI - Confidence interval; ICC - Intraclass correlation coefficient; *P* - *P* value

Downloaded from http://journals.lww.com/jisp by BHMifsePHKav1ZEquum1IQIN4a+kULhEZgbsIHod4XMI0hCwWCX1AW nYQp/IIqH3D3D00RrY7TvsFAC3Vc4/OAVpDd8KKGKv0Ymy+78= on 06/21/2023

Table 3: Means and standard deviation of the variations between real and planned position among the implants placed

Variables	n	Mean±SD	Minimum	Maximum
Variation at the implant neck (mm)	15	1.43±0.60	0.60	2.50
Variation at the implant apex (mm)	15	2.19±0.63	1.20	3.40
Angular variation (°)	15	6.81±3.10	0.60	13.10

n - Sample size; SD - Standard deviation

Table 4: Comparison of the results found versus the values presented in the literature

Variable	P	Means differences	95% CI	
			Inferior	Superior
Variation at the implant neck (1.1 mm)	0.049	0.33	0.00	0.67
Variation at the implant apex (2 mm)	0.252	0.19	-0.15	0.54
Angular variation (2°)	>0.001	4.81	3.10	6.53

One sample t-test. CI - Confidence interval; P - P value was significant at P<0.05

apex. These discrepancies could reflect a clinical implication impeding esthetic or functional results in rehabilitation or lead to the invasion of adjacent anatomical structures. Then, this procedure should be carefully planned.

The variations observed in this study could have originated at the intraoperative stage due to the passive adjustment of the drill in the socket at the time of preparing the surgical site, caused by the extension of the pocked left by the roots and could generate the observed inaccuracies. Some authors recommend the use of shorter drills and longer sleeves to achieve greater stability to the drills.^[29]

The results of this method can be optimized considering the appropriate adjustment and stability of the guide, using splints with mesial and distal support, on the same surface and with the placement of anchor pins.^[22] It has even been identified that the use of multiple splints with different surfaces support combined in an ordered sequence can improve the accuracy of guided surgery in cases of immediate implant placement with certain specifications.^[26]

Chen *et al.*^[29] evaluated the accuracy of computer-guided surgery versus the traditional technique for immediate implant placement, with a sample of 12 implants in human skulls. They determined that the computer-guided procedure showed greater accuracy. Nevertheless, even with the help of a surgical splint, the final position of the implant tends to be directed with buccal orientation relative to the planned position. In this study, for the computer-guided procedure, the implants were placed without the surgical splint. To reduce deviations, it is recommended to perform fully guided technique for both the procedure of preparation of the alveolus as the installation of the implants through the surgical guide.

Van Assche *et al.*^[22] indicate that in cases of partially edentulous patients, the guide is supported on two different surfaces (oral mucosa and teeth), attributing to this condition the possibility of generating deviations due to tilt of the splint, being the best

scenario to achieve a perfect fit of the splint on a single type of surface. This condition is recommended to be counteracted with the placement of anchor pins in the guide. In the present study, the guides were planned with distal dental support and mesial mucous support, and this could be the cause of the tilting of the guide. However, anchor pins were placed to ensure the stability of the splint at the time of the drilling sequence.

Choi *et al.*^[1] assessed the accuracy in conventional surgery versus guided surgery and found improvement in the mesio-distal position of the implants. They reported that incomplete bone remodeling and the gap left by extensive roots could cause the drill's tendency to deviate to another side. However, in this investigation, the technique was validated with two-dimensional radiographs, and the buccal and palatal/lingual dimension could not be obtained, remaining to some bias.

Based on the results of this study, the improvement of the technique is suggested considering several critical factors such as an appropriate adjustment and stability of the surgical splint. These properties can be difficult to achieve when it comes to postextraction cases and immediate implant placement because the surgical site variation at the time of presenting the splint due to the three-dimensional records in which the planning is performed.^[30]

The results of this study should be interpreted with caution due to the size of the sample and the specific limitations, such as the specimen consisting of hemi-mandibles of pigs, which may not be representative for the real clinical scenario and ruled out the possibility of designing a full arch guide. This could have led to overestimation of the angular variation and of the position variation at the implant neck site in the real position with respect to the planned one.

Further clinical studies should be performed evaluating the validation of this technique. In addition, comparison between with conventional procedure using clinical trials is recommended.

CONCLUSIONS

Computer-guided surgery is a technique that could be used in immediate implant placement considering that some variations in the angulation and in the position of the neck and the apex of the implants could be expected.

Acknowledgment

The authors are grateful of the digital planning center RC Soluciones Odontológicas (Santo Domingo, Dominican Republic).

Financial support and sponsorship

Nil.

Conflicts of interest

There are no conflicts of interest.

REFERENCES

- Choi W, Nguyen BC, Doan A, Girod S, Gaudilliere B, Gaudilliere D. Freehand versus guided surgery: Factors influencing accuracy of

- dental implant placement. *Implant Dent* 2017;26:500-9.
2. Brugnami F, Caleffi C. Prosthetically driven implant placement. How to achieve the appropriate implant site development. *Keio J Med* 2005;54:172-8.
 3. Canellas JV, Medeiros PJ, Figueredo CM, Fischer RG, Ritto FG. Which is the best choice after tooth extraction, immediate implant placement or delayed placement with alveolar ridge preservation? A systematic review and meta-analysis. *J Craniomaxillofac Surg* 2019;47:1793-802.
 4. Botticelli D, Renzi A, Lindhe J, Berglundh T. Implants in fresh extraction sockets: A prospective 5-year follow-up clinical study. *Clin Oral Implants Res* 2008;19:1226-32.
 5. Lanza A, Scognamiglio F, Femiano F, Lanza M. Immediate, early, and conventional implant placement in a patient with history of periodontitis. *Case Rep Dent* 2015;2015:217895.
 6. Chen, Stephen T, Wilson TG. Immediate or early placement of implants following tooth extraction: Review of biologic basis, clinical procedures, and outcomes. *Int J Oral Maxillofac Implant* 2004;19:12-25.
 7. Ferrus J, Cecchinato D, Pjetursson EB, Lang NP, Sanz M, Lindhe J. Factors influencing ridge alterations following immediate implant placement into extraction sockets. *Clin Oral Impl Res* 2010;21:22-29.
 8. Tanaka K, Sailer I, Iwama R, Yamauchi K, Nogami S, Yoda N, et al. Relationship between cortical bone thickness and implant stability at the time of surgery and secondary stability after osseointegration measured using resonance frequency analysis. *J Periodontal Implant Sci* 2018;48:360-72.
 9. Rodrigo D, Martin C, Sanz M. Biological complications and peri-implant clinical and radiographic changes at immediately placed dental implants. A prospective 5-year cohort study. *Clin Oral Implants Res* 2012;23:1224-31.
 10. Lanis A, Álvarez Del Canto O. The combination of digital surface scanners and cone beam computed tomography technology for guided implant surgery using 3Shape implant studio software: A case history report. *Int J Prosthodont* 2015;28:169-78.
 11. Pyo SW, Lim YJ, Koo KT, Lee J. Methods used to assess the 3D accuracy of dental implant positions in computer-guided implant placement: A review. *J Clin Med* 2019;8:54-65.
 12. Barnea E, Alt I, Kolerman R, Nissan J. Accuracy of a laboratory-based computer implant guiding system. *Oral Surg Oral Med Oral Pathol Oral Radiol Endod* 2010;109:e6-10.
 13. Bover-Ramos F, Viña-Almunia J, Cervera-Ballester J, Peñarocha-Diogo M, García-Mira B. Accuracy of implant placement with computer-guided surgery: A systematic review and meta-analysis comparing cadaver, clinical, and *In vitro* Studies. *Int J Oral Maxillofac Implants* 2018;33:101-15.
 14. Kernen F, Benic GI, Payer M, Schär A, Müller-Gerbl M, Filippi A, et al. Accuracy of three-dimensional printed templates for guided implant placement based on matching a surface scan with CBCT. *Clin Implant Dent Relat Res* 2016;18:762-8.
 15. Ramasamy M, Giri, Raja R, Subramonian, Karthik, Narendrakumar R. Implant surgical guides: From the past to the present. *J Pharm Bioallied Sci* 2013;5(Suppl 1):S98-S102.
 16. Ma B, Park T, Chun I, Yun K. The accuracy of a 3D printing surgical guide determined by CBCT and model analysis. *J Adv Prosthodont* 2018;10:279-85.
 17. Ruppin J, Popovic A, Strauss M, Spüntrup E, Steiner A, Stoll C. Evaluation of the accuracy of three different computer-aided surgery systems in dental implantology: Optical tracking vs. stereolithographic splint systems. *Clin Oral Implants Res* 2008;19:709-16.
 18. Ozan O, Turkyilmaz I, Ersoy AE, McGlumphy EA, Rosenstiel SF. Clinical accuracy of 3 different types of computed tomography-derived stereolithographic surgical guides in implant placement. *J Oral Maxillofac Surg* 2009;67:394-401.
 19. Raico Gallardo YN, da Silva-Olivio IRT, Mukai E, Morimoto S, Sesma N, Cordaro L. Accuracy comparison of guided surgery for dental implants according to the tissue of support: A systematic review and meta-analysis. *Clin Oral Implants Res* 2017;28:602-12.
 20. Murat S, Kamburoğlu K, Özen T. Accuracy of a newly developed cone-beam computerized tomography-aided surgical guidance system for dental implant placement: An ex vivo study. *J Oral Implantol* 2012;38:706-12.
 21. Marlière DA, Demètrio MS, Picinini LS, Oliveira RG, Netto HD. Accuracy of computer-guided surgery for dental implant placement in fully edentulous patients: A systematic review. *Eur J Dent* 2018;12:153-60.
 22. Van Assche N, van Steenberghe D, Guerrero ME, Hirsch E, Schutyser F, Quirynen M, et al. Accuracy of implant placement based on pre-surgical planning of three-dimensional cone-beam images: A pilot study. *J Clin Periodontol* 2007;34:816-21.
 23. D'haese J, De Bruyn H. Effect of smoking habits on accuracy of implant placement using mucosally supported stereolithographic surgical guides. *Clin Implant Dent Relat Res* 2013;15:402-11.
 24. D'haese J, Van De Velde T, Komiyama A, Hultin M, De Bruyn H. Accuracy and complications using computer-designed stereolithographic surgical guides for oral rehabilitation by means of dental implants: A review of the literature. *Clin Implant Dent Relat Res* 2012;14:321-35.
 25. Zhou W, Liu Z, Song L, Kuo C ling, Shafer DM. Clinical factors affecting the accuracy of guided implant surgery – A systematic review and meta-analysis. *J Evid Base Dent Pr* 2017;18:1-3.
 26. Spielau T, Hauschild U, Katsoulis J. Computer-assisted, template-guided immediate implant placement and loading in the mandible: A case report. *BMC Oral Health* 2019;19:55.
 27. Schnutenhaus S, Gröller S, Luthardt RG, Rudolph H. Accuracy of the match between cone beam computed tomography and model scan data in template-guided implant planning: A prospective controlled clinical study. *Clin Implant Dent Relat Res* 2018;20:541-9.
 28. Schneider D, Marquardt P, Zwahlen M, Jung RE. A systematic review on the accuracy and the clinical outcome of computer-guided template-based implant dentistry. *Clin Oral Implants Res* 2009;20 Suppl 4:73-86.
 29. Chen Z, Li J, Sinjab K, Mendonca G, Yu H, Wang HL. Accuracy of flapless immediate implant placement in anterior maxilla using computer-assisted versus freehand surgery: A cadaver study. *Clin Oral Implants Res* 2018;29:1186-94.
 30. Pinto A, Raffone C. Postextraction computer-guided implant surgery in partially edentate patients with metal restorations: A case report. *Oral Implant* 2017;10:71-7.