



TITLE:

Bilateral Orbital Inflammation as a Manifestation of Paraneoplastic Syndrome

AUTHOR(S):

Yoshida, Miyo; Suda, Kenji; Oishi, Akio; Fujimoto, Masahiro; Nakano, Eri; Kashii, Satoshi; Ohsumi, Akihiro; Tsujikawa, Akitaka

CITATION:

Yoshida, Miyo ...[et al]. Bilateral Orbital Inflammation as a Manifestation of Paraneoplastic Syndrome. *Case Reports in Ophthalmology* 2022, 13(2): 534-541

ISSUE DATE:

2022-07-08

URL:

<http://hdl.handle.net/2433/283379>

RIGHT:

© 2022 The Author(s). Published by S. Karger AG, Basel; This article is licensed under the Creative Commons Attribution-NonCommercial 4.0 International License (CC BY-NC). Usage and distribution for commercial purposes requires written permission.

Case Report

Bilateral Orbital Inflammation as a Manifestation of Paraneoplastic Syndrome

Miyo Yoshida^a Kenji Suda^a Akio Oishi^{a, b} Masahiro Fujimoto^a
Eri Nakano^a Satoshi Kashii^{a, c} Akihiro Ohsumi^d Akitaka Tsujikawa^a

^aDepartment of Ophthalmology and Visual Sciences, Kyoto University Graduate School of Medicine, Kyoto, Japan; ^bDepartment of Ophthalmology and Visual Sciences, Nagasaki University, Nagasaki, Japan; ^cFaculty of Health and Medical Sciences, Aichi Syukutoku University, Nagakute, Japan; ^dDepartment of Thoracic Surgery, Kyoto University Graduate School of Medicine, Kyoto, Japan

Keywords

Orbital inflammation · Compressive optic neuropathy · Paraneoplastic syndrome · Surgical resection · Magnetic resonance imaging

Abstract

Paraneoplastic neurologic syndromes (PNS) constitute a rare group of disorders whose optimal treatment is yet to be established. We report a patient with bilateral orbital inflammation associated with PNS, who responded well to surgical resection of the primary tumor. An 83-year-old woman was referred to our department for treatment of a progressive reduction in visual acuity and palpebral swelling in both eyes for the past 2 months. She was scheduled to undergo thoracic surgery for lung cancer. The best-corrected visual acuity (BCVA) in the right and left eye had worsened from 0.3 to 0.5 one month before she was referred to our department to 0.03 and 0.07, respectively. A slit-lamp examination revealed edema in both eyelids. Goldmann perimetry revealed several paracentral scotomas with constriction of the peripheral visual fields of both eyes, along with central absolute scotomas in V-4e isopter in the right eye. Magnetic resonance imaging revealed swelling of the bilateral extraocular muscles, which compressed the bilateral optic nerves at the orbital apex. Seven days after the resection of the lung cancer, the BCVA improved to 0.07 and 0.15 in the right and left eyes, respectively, without concomitant immunotherapy. Intravenous methylprednisolone (500 mg/day) was administered for 3 days to treat the residual orbital inflammation. Fourteen days after surgery, the BCVA further improved to 0.4 and 0.5 in the right and left eyes, respectively. Swelling of the bilateral extraocular muscles and

Case Reports in Ophthalmology

DOI: 10.1159/000525632

© 2022 The Author(s). Published by S. Karger AG, Basel
www.karger.com/cop

Yoshida et al.: Orbital Inflammation as Paraneoplastic Syndrome

the visual field abnormalities improved dramatically. Early diagnosis is crucial for the management of PNS.

© 2022 The Author(s).
Published by S. Karger AG, Basel

Introduction

Paraneoplastic neurologic syndromes (PNS) constitute a rare group of disorders that occur in less than 0.01% of patients with cancer. PNS are caused by the autoimmune response against normal neuronal tissue, spurred by the ectopic expression of similar neuronal antigens by the tumor cells [1]. Any part of the nervous system (central or peripheral nervous system, including the neuromuscular junctions and muscles) may be affected by PNS. Generally, PNS shows subacute progressive clinical course and severe disability [2]. Recently, PNSs of the extraocular muscle have been reported [3–6] and discussed as “paraneoplastic orbital myositis” [7]. Herein, we report a patient with bilateral orbital inflammation whose visual acuity improved following the surgical resection of the primary tumor.

Case Report/Case Presentation

An 83-year-old female patient consulted her family physician due to the progressive reduction in visual acuity and visual field defects in both eyes. The intraocular pressure (IOP) was 22 mm Hg oculus dexter (OD) and 29 mm Hg oculus sinister (OS). Initially, she was suspected of having visual impairment caused by glaucoma and was administered tafluprost ophthalmic solution. This treatment completely not only failed to decrease the IOP but was also accompanied by the gradual swelling of both upper eyelids. The patient stopped using the ophthalmic solution since it was suspected of causing palpebral swelling. However, the bilateral eyelid edema progressed after the cessation of the eye drop. She underwent an annual health check-up 2 months after she first visited the family physician. X-rays revealed an abnormal mass with a diameter of 5 cm in her left upper lung, which was suggestive of lung cancer.

She was referred to our ophthalmology department after admission to the department of thoracic surgery of Kyoto University Hospital. She did not experience any periorbital pain, headaches, or nausea. Her medical history included diabetes, hypertension, hyperlipidemia, and angina. Her mother and sister had a history of thyroid-associated ophthalmopathy (TAO). She had smoked one pack of cigarettes per day for 63 years and drank alcohol socially. Ocular examination revealed a best-correct visual acuity (BCVA) of 0.03 and 0.07 in right and left eyes, respectively, which was considerably worse than the corresponding BCVA of 0.3 and 0.5 measured 1 month ago. A slit-lamp examination revealed palpebral swelling in both eyes (Fig. 1a). The interpalpebral fissure measured 2 mm bilaterally and the levator function was 12 mm. The optic disc appeared normal on fundus examination in both eyes, without any sign of glaucoma. The IOP was 16 mm Hg OD and 18 mm Hg OS. The critical flicker frequency was 11.3 Hz OD and 20.8 Hz OS. The right and left pupils were equal in diameter, round, and reactive, and no afferent defect was observed. There were no restrictions in eye movement in any gaze. The findings of electroretinography were normal. Optical coherence tomography (Carl Zeiss Meditec AG, Dublin, CA, USA) revealed that the outer retinal layer was intact throughout the macula (Fig. 2) in both eyes. Goldmann perimetry (Haag-Streit, Bern, Switzerland) depicted several paracentral scotomas in the V-4e isopter with constriction of the peripheral

Case Reports in Ophthalmology

DOI: 10.1159/000525632

© 2022 The Author(s). Published by S. Karger AG, Basel
www.karger.com/cop

Yoshida et al.: Orbital Inflammation as Paraneoplastic Syndrome

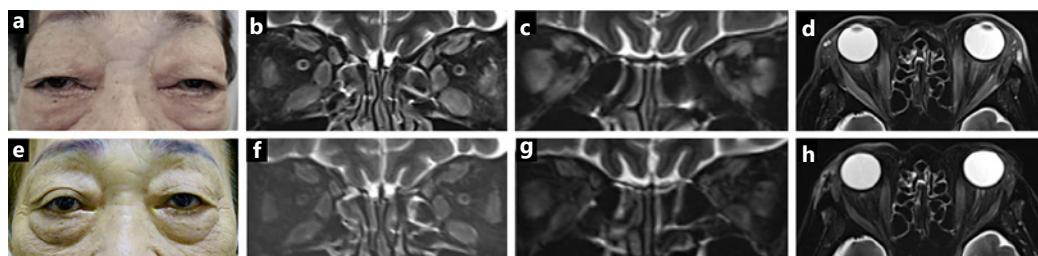


Fig. 1. Clinical course of eyelid swelling in both the eyes as seen on plain and contrast-enhanced MRI. **a** At the first visit, the bilateral palpebral swelling was found to have worsened over 2 months since onset. **b** A coronal contrast-enhanced MRI scan shows edema of all the bilateral extraocular muscles and enlargement of the bilateral lacrimal glands, without enhancement of the optic nerves or their sheaths. **c** Coronal and **d** sagittal images of the orbital apex show compression of the bilateral optic nerves by the extraocular muscles compressed. **e** Fourteen days after thoracic surgery, the length of the bilateral interpallebral fissure improved to 5 mm, which was the same as the corresponding value obtained before the patient became aware of the palpebral swelling. **f** The edema of the extraocular muscles improved slightly. **g** Coronal and **h** sagittal images of the orbital apex show that the optic nerves are no longer compressed in both the eyes.

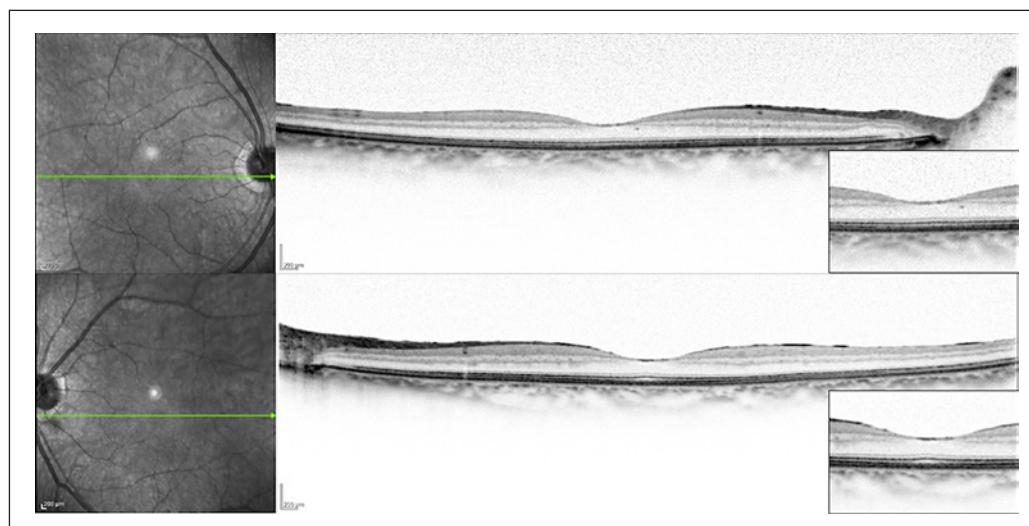


Fig. 2. OCT images obtained at the first visit. OCT shows that the outer retinal layers are intact throughout the macula, and that the ellipsoid zone at the fovea (lower right) is present in both the eyes. OCT, optical coherence tomography.

visual fields in both eyes, along with central absolute scotomas in V-4e in the right eye (Fig. 3a). Blood investigations showed evidence of a low-grade inflammatory response (C-reactive protein [CRP]: 1.1 mg/dL [normal level: <0.3 mg/dL]). The concentrations of the thyroid hormones (free T3: 2.12 pg/mL [2.33–4.00 pg/mL] and free T4: 0.969 pg/mL [0.88–1.62 pg/mL]), thyroid stimulating antibody (95% [120% or less]), serum IgG4 (14.4 mg/dL [4.5–117 mg/dL]), and soluble interleukin 2 receptor (340 U/mL [121–613 U/mL]) were all approximately within the normal range. All the following disease-specific antibodies were absent: thyroid stimulating hormone receptor antibodies, thyroid stimulating antibodies, antithyroid peroxidase antibodies, anti-acetylcholine receptor antibodies, antinuclear antibodies, proteinase-3-antineutrophil cytoplasmic antibodies, myeloperoxidase antineutrophil cytoplasmic antibodies, and antitriglyceride antibodies.

Case Reports in Ophthalmology

DOI: 10.1159/000525632

© 2022 The Author(s). Published by S. Karger AG, Basel
www.karger.com/cop

Yoshida et al.: Orbital Inflammation as Paraneoplastic Syndrome

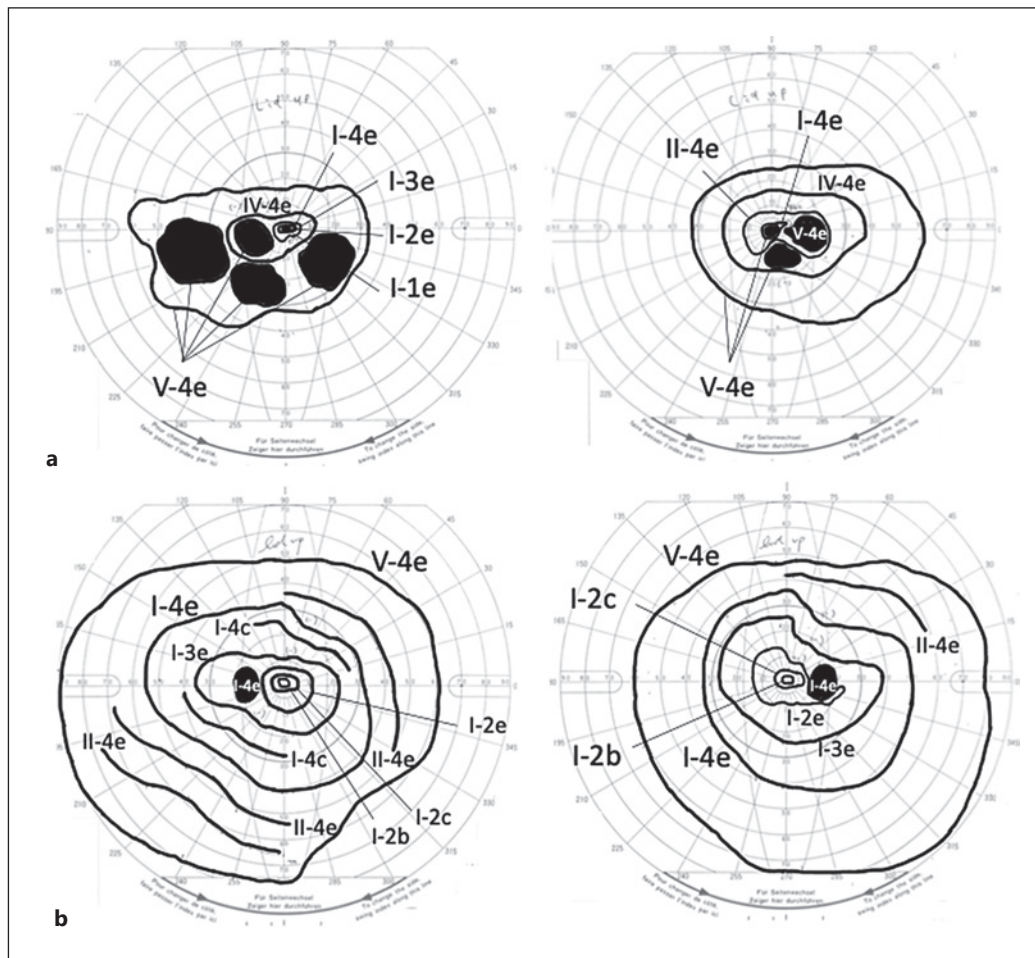


Fig. 3. Clinical course of the visual fields. **a** GP performed at the first visit shows several paracentral scotomas at the V-4e isopter with constriction of the peripheral visual fields in both the eyes. Central absolute scotomas were also detected at V-4e in the right eye. **b** GP shows complete restoration of the central and peripheral visual fields in both the eyes at 14 days after thoracic surgery. GP, Goldmann perimetry.

Plain and contrast-enhanced magnetic resonance imaging (MRI) examinations were conducted, including short T1 inversion recovery imaging. These scans showed hyperintensities and a prolonged T2-relaxation time for all the bilateral extraocular muscles. The swollen extraocular muscles (Fig. 1b) compressed the bilateral optic nerves at the orbital apex (Fig. 1c, d). The MRI studies also depicted enlargement of the bilateral lacrimal glands. T1-weighted images acquired after gadolinium administration showed enhancement of the extraocular muscles but no enhancement of the optic nerves or their sheaths.

We considered performing a biopsy of the lacrimal gland to investigate the etiology of the subacute orbital inflammation. However, thoracic surgery was prioritized, and the patient underwent left upper lobectomy. Pathological diagnosis was squamous cell carcinoma (pT3N0M0, stage IIB). Seven days after surgery, the BCVA spontaneously improved to 0.07 and 0.15 in right and left eyes, respectively, without any medication.

The patient was shifted to the department of ophthalmology for the biopsy of the right lacrimal gland 10 days after the surgery. Histopathological examination found normal-appearing tissue, neither showing multiple non-necrotizing granulomas nor abnormally increased plasma cells. While the white blood cell count and CRP level decreased significantly compared

Case Reports in Ophthalmology

DOI: 10.1159/000525632

© 2022 The Author(s). Published by S. Karger AG, Basel
www.karger.com/cop

Yoshida et al.: Orbital Inflammation as Paraneoplastic Syndrome

to the corresponding levels obtained on the day after thoracic surgery, only the serum interleukin-6 (IL-6) level was markedly high (>60 pg/mL [<2.41 pg/mL]) on the blood analysis. The bilateral palpebral swelling abated gradually, albeit incompletely, following the biopsy. Therefore, half-dose intravenous methylprednisolone pulse (500 mg/day) therapy was administered for 3 days with the aim to reduce orbital inflammation. Fourteen days after the thoracic surgery, the BCVA recovered to 0.4 and 0.5 in right and left eyes, respectively, which were the same as the corresponding values obtained when the patient became aware of the loss of vision and palpebral swelling. The bilateral interpalpebral fissure distance improved to 5 mm (Fig. 1e). The findings of Goldmann perimetry were almost normal (Fig. 3b). MRI showed that the edema of extraocular muscles had also abated (Fig. 1f), and the optic nerves in both eyes were no longer compressed at the orbital apex (Fig. 1g, h). Up to 33 months after the surgery, she has no signs of recurrence of lung cancer or orbital inflammation. One year after lobectomy, she underwent bilateral cataract surgery and the BCVA improved to 1.0 in both eyes.

Discussion

We formulated the following three differential diagnoses for the progressive bilateral vision loss in this patient: (1) cancer-associated retinopathy, (2) infiltrative optic neuropathy, and (3) compressive optic neuropathy. The electroretinography responses were normal, and optical coherence tomography demonstrated that the outer retinal layer was intact at the first visit, which were negative findings for the diagnosis of cancer-associated retinopathy. Both plain and contrast-enhanced MRI depicted swelling of the extraocular muscles, without enhancement of the optic nerves, which was evidence of compressive optic neuropathy and not invasive optic neuropathy. Therefore, we assumed that compressive optic neuropathy caused by orbital inflammation led to the reduction in the BCVA in both eyes.

Orbital inflammation is divided into infectious or noninfectious type and treated accordingly. The former is mainly caused by bacterial, fungal, and viral invasion. This case was classified as the latter because there were no characteristic findings of infection at the first visit. Considering the involvement of extraocular muscles and lacrimal glands in this case, TAO, antineutrophil cytoplasmic antibody-associated vasculitis, sarcoidosis, IgG4-related ophthalmic disease, and PNS were considered during differential diagnosis [7]. First, TAO was not indicative because thyroid function tests were in the normal range and no thyroid stimulating hormone receptor autoantibodies were present. Second, normal blood levels of antineutrophil cytoplasmic antibodies were not suggestive of antineutrophil cytoplasmic antibody-associated vasculitis. Lastly, lacrimal gland biopsy demonstrated normal-appearing tissue, neither showing multiple non-necrotizing granulomas nor abnormally increased plasma cells, which is a hallmark sign of sarcoidosis [8] and IgG4-related ophthalmic disease, respectively. Therefore, PNS was the probable cause of orbital inflammation, given that orbital myositis affected bilateral extraocular muscles [7, 9] and improved significantly after cancer resection [2].

While the principal treatment of PNS is focused on the original tumor, immunosuppressive agents are sometimes administered to relieve inflammation. In the present case, systemic corticosteroid was added to reduce the residual orbital inflammation, which was highly effective. Fortunately, we were able to stop steroid therapy in 3 days without adverse events or recurrences. Meanwhile, use of corticosteroid can induce various side effects and may have negative influence on tumor control. The duration and quantity of its use is still controversial. Taken together, we diagnosed her with paraneoplastic orbital inflammation and compressive optic neuropathy due to extraocular muscle swelling.

Table 1 presents the clinical characteristics of patients whose PNS manifested as orbital inflammation in previous studies [3–6]. Most patients with metastatic or unresectable

Case Reports in Ophthalmology

DOI: 10.1159/000525632

© 2022 The Author(s). Published by S. Karger AG, Basel
www.karger.com/cop

Yoshida et al.: Orbital Inflammation as Paraneoplastic Syndrome

Table 1. Clinical characteristics of orbital inflammation as a manifestation of paraneoplastic syndrome

Author (Year)	Age	BCVA at the first visit (right/left)	Sex	Primary disease	Onset of orbital inflammation ¹	Treatment	Effectiveness of steroid	Clinical outcome ²
Harris et al. (1994) [5]	43	1.0/1.0	M	DLBCL	3 months before	PSL 100 mg + Cyclophosphamide 75 mg	Effective	Died of multiple metastasis after 19 months
Spraul et al. (1996) [4]	52	0.4/0.8	F	Malignant paraganglioma	24 months after	Dexamethasone 8 mg	Not effective	Died of multiple metastasis after 19 months
Eckel et al. (1998) [3]	44	0.02/H.M.	M	Gastric adenocarcinoma	2.5 months after	Methylprednisolone 1,000 mg	Effective	Died of acute bleeding from the primary tumor after 15 months
Sogabe et al. (2016) [6]	68	0.9/0.2	M	Lung adenocarcinoma	8 months before	PSL 20 mg	Effective	Died of multiple metastasis after 29 months
This case (2022)	83	0.3/0.5	F	Lung squamous cell carcinoma	2 months before	Surgical resection + Methylprednisolone 500 mg	Effective	Survival without recurrence until at least March, 2022

H.M., hand motion; DLBCL, diffuse large B-cell lymphoma; PSL, prednisolone.

¹Onset of orbital inflammation before/after the diagnosis of primary disease.

²Clinical outcome after the onset of orbital inflammation.

Case Reports in Ophthalmology

DOI: 10.1159/000525632

© 2022 The Author(s). Published by S. Karger AG, Basel
www.karger.com/cop

Yoshida et al.: Orbital Inflammation as Paraneoplastic Syndrome

diseases exhibited bilateral vision loss, and the administration of steroid was beneficial in reducing orbital inflammation except in 1 case. Bilateral visual disturbance can occur before the primary tumor is detected, as seen in the present case. Interestingly, while the present case exhibited a good clinical course, the prognosis of all other cases of paraneoplastic cases was poor; it resulted in death within 18.0 ± 7.3 (mean \pm standard deviation) months after the onset of orbital inflammation due to cancer metastasis or acute bleeding from the primary tumor [3–6].

IL-6 plays an important role in ocular inflammation and angiogenesis in the conjunctiva, cornea, iris, retina, and orbit [10]. IL-6 is a pleiotropic proinflammatory cytokine, which is dysregulated in chronic inflammatory conditions, such as solid tumors and neuromyelitis optica spectrum disorder [6, 11, 12]. In our patient, the IL-6 levels were significantly high, which was similar to a previous report [6] even after the CRP concentration decreased along with the favorable postoperative course. This might indicate that IL-6 level is a more sensitive marker of orbital inflammation compared to the CRP level, but this theory remains to be substantiated.

Conclusion

In conclusion, we reported a patient with bilateral orbital inflammation associated with PNS, which responded well to surgical resection of the primary tumor. Clinicians should note that subacute progressive orbital inflammation may be caused by PNS. Early diagnosis and treatment of the original tumor are crucial for the management of PNS.

Statement of Ethics

All clinical procedures were conducted according to the principles of the Declaration of Helsinki. Written informed consent was obtained from the patient for publication of this case report and any accompanying images. This study was also reviewed and approved by the Institutional Review Board and Ethics Committee of the Kyoto University Graduate School of Medicine, approval number R0134.

Conflict of Interest Statement

The authors declare that there is no conflict of interest regarding the publication of this article.

Funding Sources

This study did not receive any external funding or grant support.

Author Contributions

Miyo Yoshida contributed to data acquisition, literature search, and manuscript draft. Kenji Suda was a major contributor in conception, interpretation of data, and writing the manuscript. Akio Oishi, Masahiro Fujimoto, Eri Nakano, Satoshi Kashii, Akihiro Ohsumi, and Akitaka Tsujikawa were involved in revising the manuscript. Miyo Yoshida, Kenji Suda, Akio

Case Reports in Ophthalmology

DOI: 10.1159/000525632 | © 2022 The Author(s). Published by S. Karger AG, Basel
www.karger.com/cop

Yoshida et al.: Orbital Inflammation as Paraneoplastic Syndrome

Oishi, Masahiro Fujimoto, Eri Nakano, Satoshi Kashii, Akihiro Ohsumi, and Akitaka Tsujikawa were directly involved in the care of the patient and read and approved the final manuscript.

Data Availability Statement

All information about this case report are included in this article. Further inquiries can be directed to the corresponding author.

References

- 1 Darnell RB, Posner JB. Paraneoplastic syndromes involving the nervous system. *N Engl J Med*. 2003;349(16):1543–54.
- 2 Graus F, Delattre JY, Antoine JC, Dalmau J, Giometto W, Grisold J, et al. Recommended diagnostic criteria for paraneoplastic neurological syndromes. *J Neurol Neurosurg Psychiatry*. 2004;75(8):1135–40.
- 3 Eckel F, Ugi I, Schmidt T, Lersch C. A 44-year-old patient with cardiac carcinoma and paraneoplastic orbital disease. *Dtsch Med Wochenschr*. 1998;123(38):1103–6.
- 4 Spraul CW, Lang GE, Lang GK. Orbital myopathy in metastatic malignant paraganglioma: a paraneoplastic syndrome? *Klin Monbl Augenheilkd*. 1996;209(2–3):153–7.
- 5 Harris GJ, Murphy ML, Schmidt EW, Hanson GA, Dotson RM. Orbital myositis as a paraneoplastic syndrome. *Arch Ophthalmol*. 1994;112(3):380.
- 6 Sogabe Y, Manabe K, Murata A, Yamaji Y, Morimoto H, Miyatani K. Bilateral orbital inflammation with optic neuropathy as a paraneoplastic syndrome associated with non-small cell lung cancer. *Neuro-ophthalmol Jpn*. 2016;33:370–8.
- 7 McNab AA. Orbital myositis: a comprehensive review and reclassification. *Ophthalmic Plast reconstr Surg*. 2020;36(2):109–17.
- 8 Buelens T, Scifo L, Valyi Z, Willerman F. Sarcoidosis revealed by simultaneous optic nerve and eyelid involvement: A case report. *Am J Ophthalmol Case Rep*. 2022;26:101451.
- 9 Hunt SV, Garrott HM, Williams ME, Ford RL. Bilateral paraneoplastic orbital myositis associated with malignant melanoma and multiple myeloma. *Ophthalmic Plast Reconstr Surg*. 2022 May–Jun 01;38(3):e72–5.
- 10 Ghasemi H. Roles of IL-6 in ocular inflammation: a review. *Ocul Immunol Inflamm*. 2018;26(1):37–50.
- 11 Kumari N, Dwarakanath BS, Das A, Bhatt AN. Role of interleukin-6 in cancer progression and therapeutic resistance. *Tumour Biol*. 2016;37(9):11553–72.
- 12 Yamamura T, Kleiter I, Fujihara K, Palace J, Greenberg B, Zakrzewska-Pniewska B, et al. Trial of satralizumab in neuromyelitis optica spectrum disorder. *N Engl J Med*. 2019;381(22):2114–24.