



TITLE:

Retinal arterial macroaneurysm rupture caused by dissection-like change in the vessel wall

AUTHOR(S):

Ishikura, Masaharu; Muraoka, Yuki; Kadomoto, Shin; Nishigori, Naomi; Murakami, Tomoaki; Ooto, Sotaro; Tsujikawa, Akitaka

CITATION:

Ishikura, Masaharu ...[et al]. Retinal arterial macroaneurysm rupture caused by dissection-like change in the vessel wall. *American Journal of Ophthalmology Case Reports* 2022, 25: 101346.

ISSUE DATE:

2022-03

URL:

<http://hdl.handle.net/2433/283374>

RIGHT:


© 2022 The Authors. Published by Elsevier Inc.; This is an open access article under the CC BY-NC-ND license.



Contents lists available at [ScienceDirect](https://www.sciencedirect.com)

American Journal of Ophthalmology Case Reports

journal homepage: www.ajocasereports.com/



Retinal arterial macroaneurysm rupture caused by dissection-like change in the vessel wall

Masaharu Ishikura, Yuki Muraoka^{*}, Shin Kadomoto, Naomi Nishigori, Tomoaki Murakami, Sotaro Ooto, Akitaka Tsujikawa

Department of Ophthalmology and Visual Sciences, Kyoto University Graduate School of Medicine, 54 Shougoin Kawahara-cho, Sakyo-ku, Kyoto, 606-8507, Japan

ARTICLE INFO

Keywords:

Adaptive optics scanning light ophthalmoscope
Anti-vascular endothelial growth factor
Optical coherence tomography
Optical coherence tomography angiography
Retinal arterial macroaneurysm

ABSTRACT

Purpose: To highlight a potential pathogenetic mechanism of retinal arterial macroaneurysm.

Observations: A 79-year-old woman presented with a ruptured retinal arterial macroaneurysm in the right eye. One year after treatment, high-resolution multimodal imaging with optical coherence tomography (OCT), OCT angiography, and adaptive optics scanning light ophthalmoscope showed that a narrow passage developed in the vessel wall of the pre-existing retinal arterial macroaneurysm and another macroaneurysm had developed adjacent to the pre-existing one.

Conclusions and Importance: These images suggest the pathogenesis of retinal arterial macroaneurysm (RAM) associated with crack-like changes in the retinal arterial wall, similar to pathologies seen in systemic arteries.

1. Introduction

1.1. Case report

The patient was a 79-year-old woman who was referred to our department with the diagnosis of a ruptured retinal arterial macroaneurysm (RAM) in the right eye. She had no other diseases except for systemic hypertension. The Snellen visual acuity was 20/20 at the initial visit. Images obtained at the initial visit showed a ruptured RAM (Fig. 1).

After the initial visit, the patient received two intravitreal injections of anti-vascular endothelial growth factor (VEGF) as the treatment for the retinal cystoid spaces involving the fovea.

One year after the initial examination, the adaptive optics scanning light ophthalmoscope (AOSLO) showed another RAM newly developed adjacent to the pre-existing aneurysm (Fig. 2, right). Optical coherence tomography (OCT) showed a narrow passage in the vessel wall shared by the two aneurysms (Fig. 3, left), and OCT angiography (OCTA) showed blood-flow signal corresponding to the passage (Fig. 3, right).

2. Discussion

Retinal arterial macroaneurysm is an acquired, focal dilation of a retinal artery, typically occurring within the first three bifurcations of the central retinal artery.¹ Rupture of a RAM can cause retinal exudative

changes and a sudden decrease in visual acuity. Older age, female sex, arteriosclerosis, and collagen diseases are known risk factors for RAM.² However, the precise pathology of RAM is not well-understood.

High-resolution non-invasive imaging techniques including OCT, OCTA, and AOSLO have been applied to evaluate the morphologic and functional changes in retinal circulatory diseases such as diabetic retinopathy,³⁻⁵ retinal vein occlusion,⁶ and RAM.^{7,8} Using AOSLO, Kadomoto et al. most recently elucidated the processes of loss of pulsation and thrombus formation in RAM.⁷ We treated this case with anti-VEGF therapy based on a previous report,⁷ which was thought to be less likely to modify the morphology of the RAM vessel wall.

Previous studies with trypsin digestion showed that blowout aneurysm in the retinal artery involves linear splits along the vessel wall.⁹ In our case, OCT and OCTA showed a narrow passage with blood flow in the vessel wall of the pre-existing RAM, with another RAM developed adjacent to this. These suggest that a crack in the retinal arterial wall could initiate the pathological condition associated with RAM, which might mimic pathologies in aneurysms or dissections in systemic arteries caused by cracks from the intima to the tunica media of the arterial wall.¹⁰

3. Conclusions

High-resolution multimodal imaging with OCT, OCTA, and AOSLO

^{*} Corresponding author.

E-mail address: muraoka@kuhp.kyoto-u.ac.jp (Y. Muraoka).

<https://doi.org/10.1016/j.ajoc.2022.101346>

Received 13 August 2021; Received in revised form 17 December 2021; Accepted 24 January 2022

Available online 26 January 2022

2451-9936/© 2022 The Authors.

Published by Elsevier Inc.

This is an open access article under the CC BY-NC-ND license

(<http://creativecommons.org/licenses/by-nc-nd/4.0/>).

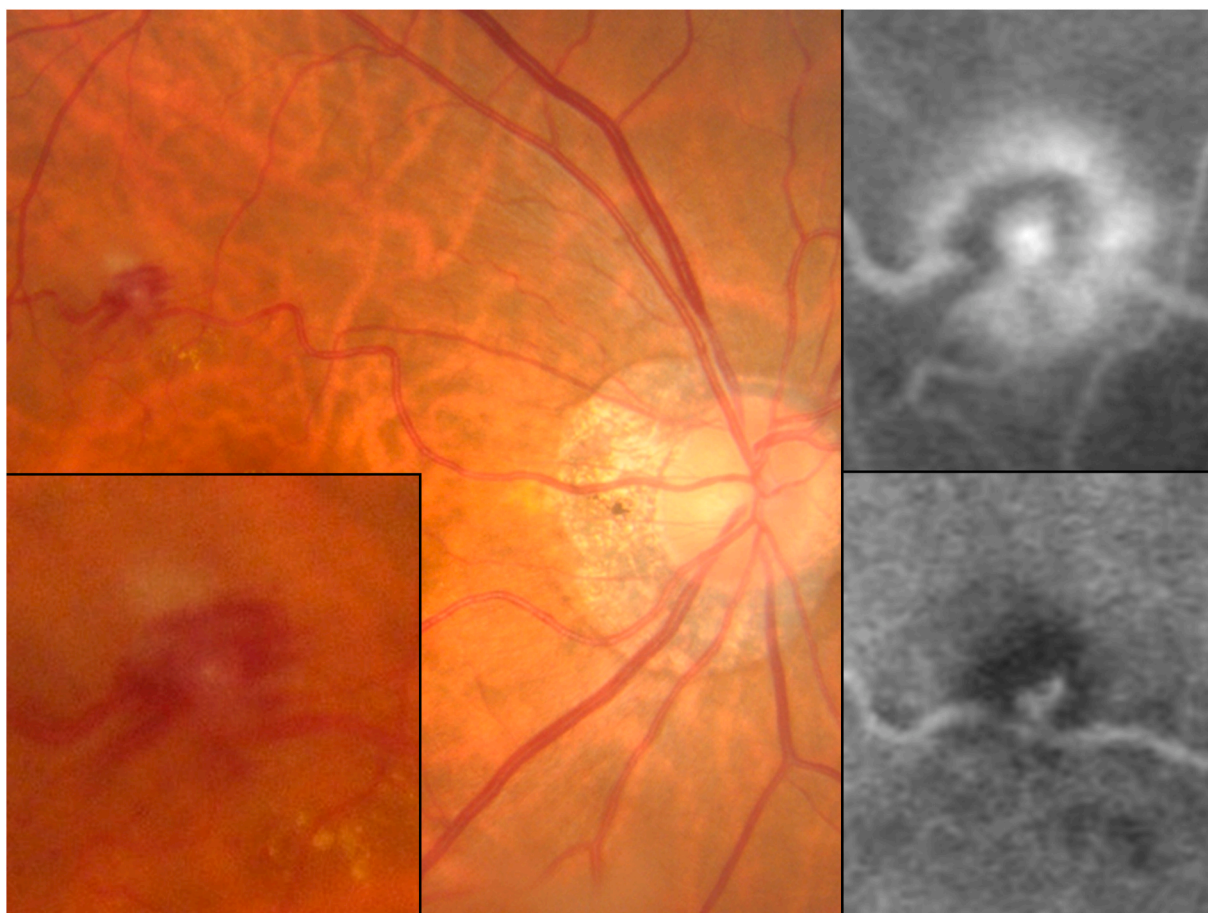


Fig. 1. Images of retinal arterial macroaneurysm rupture in the right eye of a representative case. Color fundus photographs (left), fluorescein angiogram (upper right), and indocyanine green angiogram (lower right).

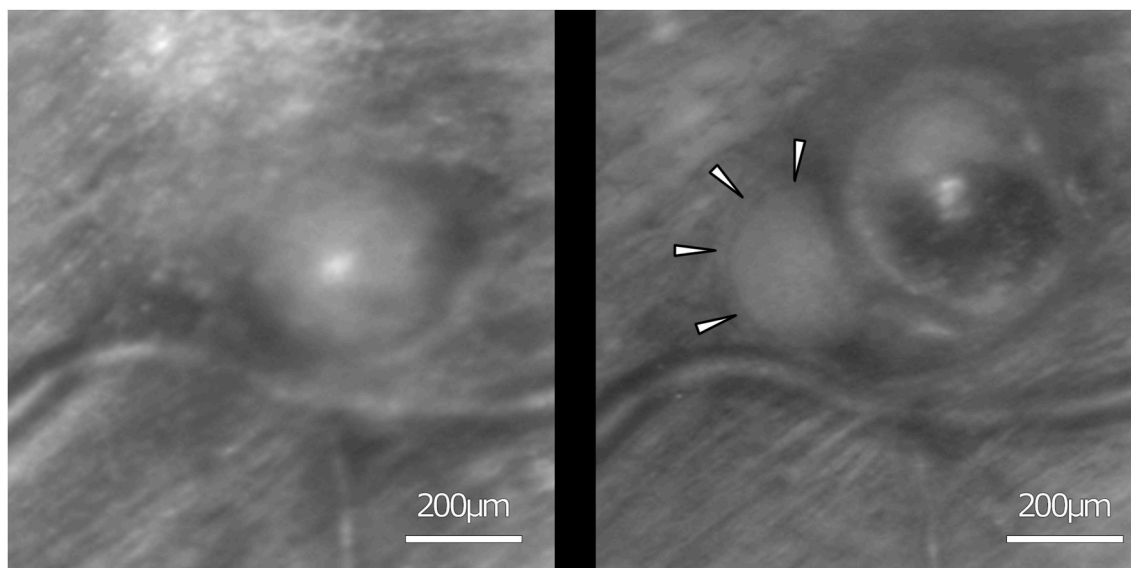


Fig. 2. A new retinal arterial macroaneurysm (RAM) ruptured adjacent to the pre-existing RAM. The adaptive optics scanning light ophthalmoscopy (AOSLO) image shows the ruptured RAM at the initial visit (left). The AOSLO image shows the newly developed aneurysm (arrowheads, right).

enabled us to visualize the mechanism of RAM formation *in vivo*. This case suggests that RAM might be caused by crack-like changes in the retinal artery wall, similar to pathologies of systemic arterial disease.

Patient consent

Consent to publish this case report has been obtained from the patient in writing.

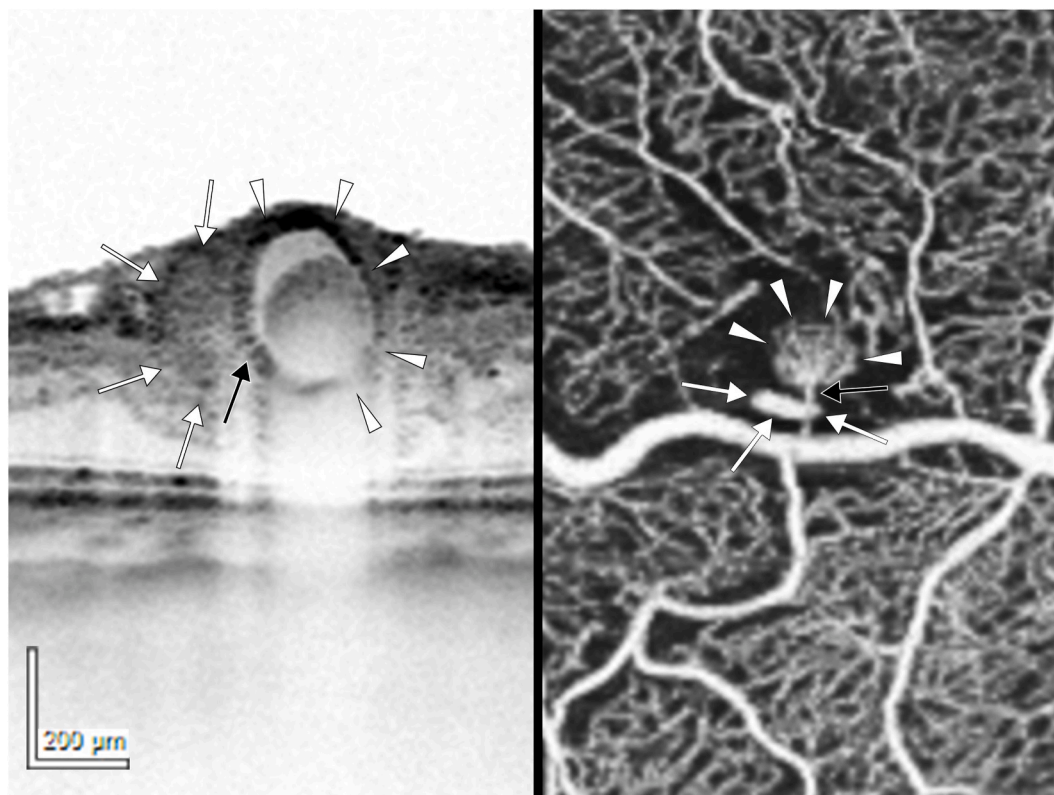


Fig. 3. Passage through the two retinal arterial macroaneurysms (RAMs). Optical coherence tomography (OCT) shows a narrow passage (left, black arrow) in the vessel wall shared by the old and new RAMs (arrowheads and white arrows, respectively), and the OCT angiogram shows the blood-flow signal corresponding to the passage (right, black arrow).

Funding

No funding or grant support.

Authorship

All authors attest that they meet the current ICMJE criteria for Authorship.

Declaration of competing interest

The following authors have no financial disclosures: MI, NN.

Y. Muraoka received grant support from Bayer, Novartis Pharma K-K., Senju, and Nidek; S. Ooto received grant support from Novartis Pharma K-K., Bayer, Santen, and Senju; T. Murakami received grant support from Bayer, Novartis Pharma K-K., Santen, and Senju; A. Tsujikawa received grant support from Pfizer, Novartis Pharma K-K., Bayer, Alcon, Santen, Senju, Nidek, and AMO Japan.

Acknowledgements

This work was partially supported by the Japan Society for the Promotion of Science (JSPS), Tokyo, Japan (Grant-in-Aid for Scientific Research(C) JP21K09771) and Canon Inc. (Tokyo, Japan).

References

- Robertson DM. Macroaneurysms of the retinal arteries. *Trans Am Acad Ophthalmol Otolaryngol.* 1973;77(1):55–67.
- Rabb MF, Gagliano DA, Teske MP. Retinal arterial macroaneurysms. *Surv Ophthalmol.* 1988;33(2):73–96.
- Arichika S, Uji A, Murakami T, et al. Retinal hemorheologic characterization of early-stage diabetic retinopathy using adaptive optics scanning laser ophthalmoscopy. *Invest Ophthalmol Vis Sci.* 2014;55(12): 8513–1822.
- Bernabeu MO, Lu Y, Abu-Qamar O, Aiello LP, Sun JK. Estimation of diabetic retinal microaneurysm perfusion parameters based on computational fluid dynamics modeling of adaptive optics scanning laser ophthalmoscopy. *Front Physiol.* 2018;9: 989.
- Lammer J, Karst SG, Lin MM, et al. Association of microaneurysms on adaptive optics scanning laser ophthalmoscopy with surrounding neuroretinal pathology and visual function in diabetes. *Invest Ophthalmol Vis Sci.* 2018;59(13):5633–5640.
- Moosavi RA, Fong KCS, Chopdar A. Retinal artery macroaneurysms: clinical and fluorescein angiographic features in 34 patients. *Eye.* 2006;20(9):1011–1020.
- Kadomoto S, Muraoka Y, Uji A, et al. Ultrastructure and hemodynamics of microaneurysms in retinal vein occlusion examined by an offset pinhole adaptive optics scanning light ophthalmoscope. *Biomed Opt Express.* 2020;11(11):6078–6092.
- Kadomoto S, Muraoka Y, Uji A, Ooto S, Murakami T, Tsujikawa A. Hemodynamic and structural changes in retinal arterial macroaneurysm after intravitreal anti-vascular endothelial growth factor injection. *Am J Ophthalmol Case Rep.* 2021;23: 101182.
- Fichte C, Streeten BW, Friedman AH. A histopathologic study of retinal arterial aneurysms. *Am J Ophthalmol.* 1978;85(4):509–518.
- Sakalihan N, Limet R, Defawe OD. Abdominal aortic aneurysm. *Lancet.* 2005;365 (9470):1577–1589.