



# How much space is needed for decompressive surgery in malignant middle cerebral artery infarction: Enabling single-stage surgery



Matteo Montalbetti<sup>\*</sup>, Sylvia Lörcher, Andreas Nowacki, Levin Häni, Werner J. Z'Graggen, Andreas Raabe, Philippe Schucht

Department of Neurosurgery, Inselspital, Bern University Hospital, University of Bern, Switzerland

## ARTICLE INFO

Handling Editor: Dr W Peul

### Keywords:

Middle cerebral artery infarction  
Stroke  
Decompressive hemicraniectomy

## ABSTRACT

**Introduction:** Decompressive hemicraniectomy (DCE) is routinely performed for intracranial pressure control after malignant middle cerebral artery (MCA) infarction. Decompressed patients are at risk of traumatic brain injury and the syndrome of the trephined until cranioplasty. Cranioplasty after DCE is itself associated with high complication rates. Single-stage surgical strategies may eliminate the need for follow-up surgery while allowing for safe brain expansion and protection from environmental factors.

**Research question:** Assess the volume needed for safe expansion of the brain to enable single-stage surgery.

**Materials and methods:** We performed a retrospective radiological and volumetric analysis of all patients that had DCE in our clinic between January 2009 and December 2018 and met inclusion criteria. We investigated prognostic parameters in perioperative imaging and assessed clinical outcome.

**Results:** Of 86 patients with DCE, 44 fulfilled the inclusion criteria. Median brain swelling was 75.35 mL (8.7–151.2 mL). Median bone flap volume was 113.3 mL (73.34–146.1 mL). Median brain swelling was 1.62 mm below the previous outer rim of the skull (5.3 mm to –2.19 mm). In 79.6% of the patients, the volume of removed bone alone was equivalent to or larger than the additional intracranial volume needed for brain swelling.

**Discussion and conclusion:** The space provided by removal of the bone alone was sufficient to match the expansion of the injured brain after malignant MCA infarction in the vast majority of our patients

A subgaleal space-expanding flap with a minimal offset can provide protection from trauma and atmospheric pressure without compromising brain expansion.

## 1. Introduction

Large cerebral infarctions in the territory of the middle cerebral artery (MCA) may lead to brain swelling, life-threatening elevation of intracranial pressure (ICP), and uncal or cingulate herniation, a condition commonly referred to as malignant MCA infarction. Performing a decompressive hemicraniectomy (DHC) allows the swollen brain to expand out of its cranial vault, which effectively alleviates ICP. A meta-analysis of 3 randomized controlled trials on DHC for malignant MCA infarction (DESTINY, DECIMAL, and HAMLET) (Jüttler et al., 2007; Hofmeijer et al., 2009; Vahedi et al., 2007) demonstrated that DHC reduced mortality after malignant MCA infarction, whereas non-surgical therapies were insufficient (Vahedi et al., 2007; Huttner

et al., 2008). The bone flap is commonly cryopreserved and re-implanted some months later in a second surgery once the swelling of the brain has subsided.

The strategy of DHC followed by cranioplasty (CP) carries several risks. Following the first surgery, shearing injuries at the edge of the craniotomy may lead to additional infarctions and hemorrhages. During rehabilitation, the brain may be injured if the patient falls, and the patient normally has to wear a helmet when walking around. In addition, several neurological deficits may occur because the brain is exposed to atmospheric pressure. These range from focal deficits to blown pupils and brainstem herniation (Joseph and Reilly, 2009). Subdural hygroma, parenchymal effusions, and hydrocephalus may occur, probably due to disturbances in the dynamics of the cerebrospinal fluid in the absence of

**Abbreviations:** 3D, three-dimensional; BFD, bone flap diameter; BFV, bone flap volume; CI, confidence interval; CT, computed tomography; DHC, decompressive hemicraniectomy; EVD, external ventricular drain; ICH, intracerebral hemorrhage; ICP, intracranial pressure; IV, infarct volume; MCA, middle cerebral artery; MLD, midline shift difference; MLS, midline shift; PACS, picture archiving and communication system; ACA, anterior cerebral artery; PCA, posterior cerebral artery.

<sup>\*</sup> Corresponding author. Department of Neurosurgery, Inselspital, Bern University Hospital, University of Bern, Freiburgstrasse 16, 3010, Bern, Switzerland.

E-mail address: [matteo.montalbetti@insel.ch](mailto:matteo.montalbetti@insel.ch) (M. Montalbetti).

<https://doi.org/10.1016/j.bas.2023.101730>

Received 4 January 2023; Received in revised form 13 March 2023; Accepted 16 March 2023

Available online 4 April 2023

2772-5294/© 2023 Published by Elsevier B.V. on behalf of EUROSPINE, the Spine Society of Europe, EANS, the European Association of Neurosurgical Societies. This is an open access article under the CC BY-NC-ND license (<http://creativecommons.org/licenses/by-nc-nd/4.0/>).

a protective bone flap (Fodstad et al., 1984; Yang et al., 2008). Lastly, surgical re-implantation of the bone flap is itself a high risk surgery and carries its own risks of infection, hemorrhage, and brain damage (Zanaty et al., 2015; Andrabi et al., 2017; Chang et al., 2010; De Bonis et al., 2012; Goedemans et al., 2020; Wachter et al., 2013).

Therefore, the current two-stage strategy of DHC followed by re-implantation leaves room for improvement. Several novel single-stage surgical strategies using hinge-craniotomies, ladder-fixation, and overlying titanium meshes provide brain protection and some degree of additional space for the brain to swell (Hsu et al., 2019; Stoner et al., 2016; Wong and Wong, 2021; Layard Horsfall et al., 2020). Most recently, a refined single-stage strategy using a custom-made, overlying Palacos® flap has been proposed (Schucht et al., 2022). All these strategies share the goal of providing sufficient space for the injured brain to expand safely, while avoiding the risk of trauma, the syndrome of the trephined, and the inconvenience and side effects of a second surgery. However, little is known about the exact amount of space required to enable safe brain expansion in single-stage surgery.

To improve the DHC strategy, find out how much additional volume is needed to safely enable single-stage decompressive surgery, and identify candidates for this kind of surgery we reviewed a consecutive series of DHC patients and assessed volumetric changes.

## 2. Methods

### 2.1. Ethics

This study was carried out in accordance with the recommendations of the local ethics committee (Kantonale Ethikkommission Bern, Switzerland). All subjects gave written general consent in accordance with the Declaration of Helsinki. The protocol was approved by the local ethics committee (Kantonale Ethikkommission Bern, Switzerland).

### 2.2. Patient selection

We screened all patients who underwent DHC for cerebral infarction at the University Hospital of Bern, Switzerland, between January 2009 and December 2018. We included all patients with infarction in the MCA territory, with or without additional anterior cerebral or posterior cerebral artery infarction. Patients with (i) additional cerebellar infarction, (ii) age <18 years, (iii) no computed tomography (CT) scan either before decompression or within 2–5 days after DHC, as well as (iv) those with large artifacts in the CT scan (for instance due to coils or clips, which lead to inaccurate measurement of ischemic brain volume) were excluded.

### 2.3. Radiological analysis

We selected the last CT before DHC as well as the postoperative CT obtained between day 2 and day 5 after DHC for radiological analysis. If the patient had multiple postoperative CTs, we chose the one obtained closest to day 5. All measurements for the volumetric analyses were performed with the Brainlab Elements© software using the SmartBrush v3.0 and iPlan Cranial v3.0 apps.

### 2.4. Midline shift (MLS), maximum bone flap diameter (BFD) measurement and uncus herniation

We measured MLS and maximum BFD manually from the pre- and postoperative CT scan using the measuring tool provided by the Sectra Workstation IDS7 v21.2 software ©Sectra AB: the radiological picture archiving and communication system (PACS) software used in our hospital.

We first marked the ideal midline at the level of the third ventricle, and then measured the shift distance at the point of maximal deviation from it to obtain the maximal MLS for both pre- and postoperative CT. A positive MLS represented a deviation away from the affected hemisphere,

whereas a negative value represented a shift towards it. We subtracted the postoperative MLS from the preoperative MLS to obtain the midline shift difference (MLD).

Using the measuring tool provided by the IDS7 software, we measured BFD in the axial plane between the outer bone rims of the craniotomy at its maximum length. We identified uncus herniation as an asymmetry of the distances between uncus tip and the brainstem on coronal and axial views of the CT scan.

### 2.5. Ischemic brain measurement

The infarcted area (infarct volume, IV) was selected visually in each axial layer of the CT 3-mm slice scan, using the 2-dimensional (2D) Brush tool of the SmartBrush© app of the Elements© software (Brainlab AG, Munich, Germany). The app then automatically interpolated the 2D segmented areas generating a 3D object representing the ischemic brain volume.

### 2.6. Brain swelling measurement

We fused pre- and postoperative CT scans in the Elements© software with the ImageFusion© app, and measured brain swelling by choosing the inner limit of the skull as the border (Fig. 1). We manually segmented each layer from the apex to the first layer in which the sella turcica could be seen. For the measurement on the DHC side of the postoperative CT, we selected the brain margin under the trauma flap as the border. We chose the sella turcica as our defining landmark for the bottom limit of our volumetric measurement; this layer was not included in the volumetric analysis.

We then subtracted the ventricles from both pre- and post-DHC CT as these were usually compressed on the ischemic side while being enlarged on the contralateral side. As not all CT scans were acquired at exactly the same angle, we adjusted the bottom level of the preoperative CT scan to that of the one obtained after decompression, so that the bases of our 3D objects (brain volume before and after DHC) were exactly superimposed. We then subtracted the preoperative brain volume from the post-DHC brain volume to obtain the volume difference after ICP release.

### 2.7. Bone flap volume (BFV) measurement

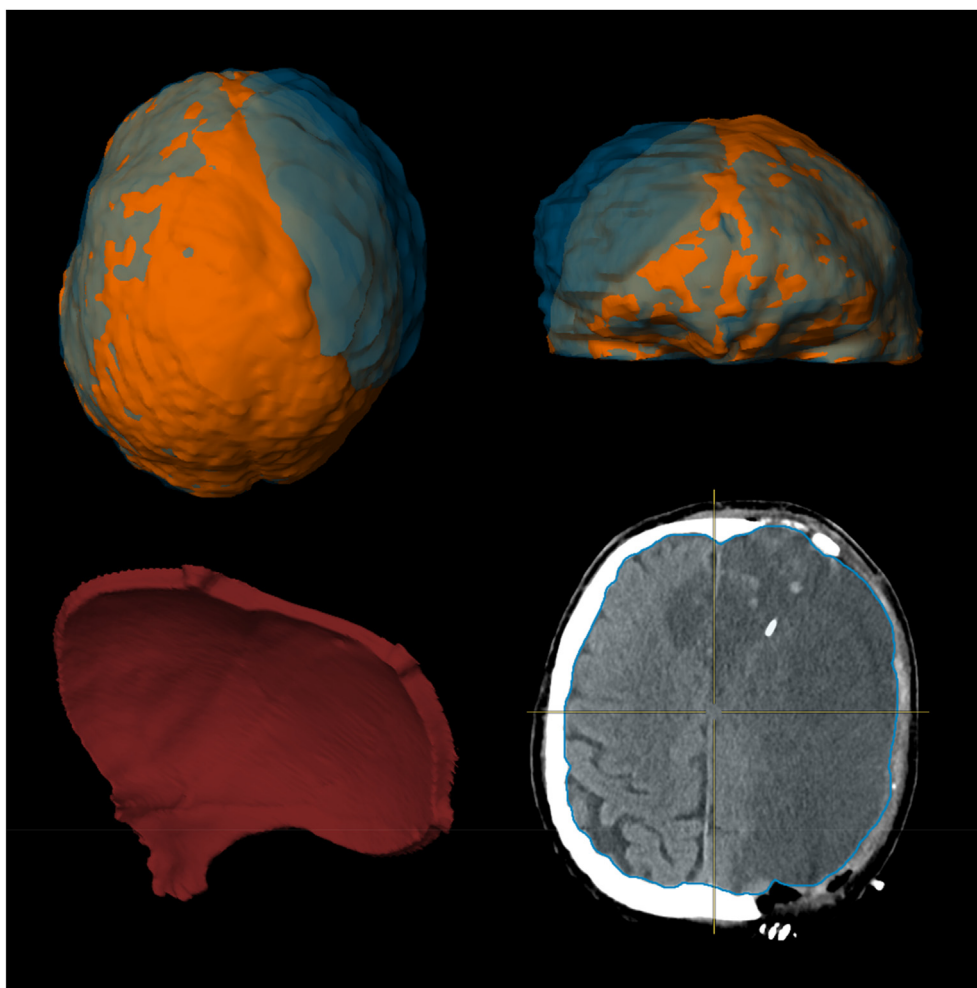
To measure the bone flap, we fused pre- and post-DHC CT scans as previously described and used the autosegmentation tool in the iPlan© Cranial app to generate 2 objects representing the skull volume before and after surgery (Fig. 1). We then subtracted the post-DHC skull object (with the bony defect) from the preoperative one to obtain the BFV. As there were often many remaining artifacts, located mostly at the skull base, we manually eliminated any objects or artifacts that were clearly not part of our bone flap as well as any segmentation or subtraction artifacts.

### 2.8. Herniation volume beyond the outer rim of the skull

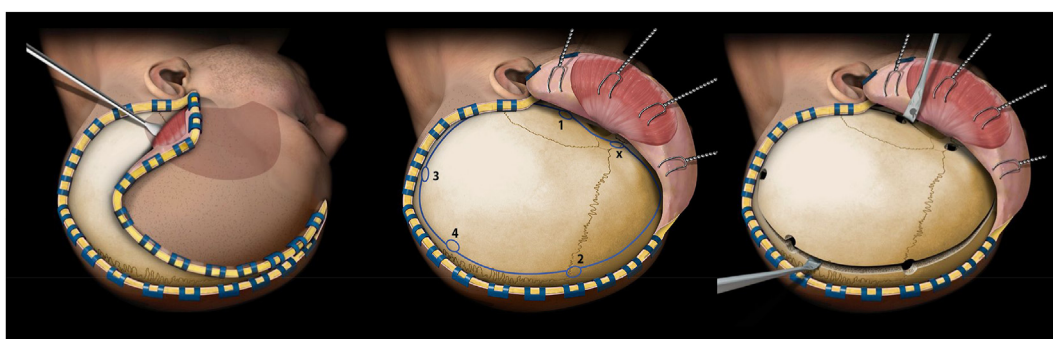
To estimate how much the brain had herniated above the previous outer bony limit of the skull, we approximated our BFV to a cylinder and subtracted it from a cylinder based on total brain volume. For this calculation, we assumed that the whole brain under the craniotomy swells equally, which clearly is not the case in a real-world situation. Therefore, we can use this only as a rough estimate, and have to correlate these values with the total volume difference (brain swell volume – BFV) for these values to have significance in a real-world scenario.

### 2.9. Assessment of hemorrhages and herniation

Two investigators (MM and SL) assessed postoperative mushrooming (herniation of brain tissue out of the craniotomy with herniation lesions at the borders due to an insufficient DHC size), intracerebral hemorrhage



**Fig. 1.** (clockwise from top left) overhead view of a 3D-rendered fully segmented brain before (orange) and after (blue) decompressive hemicraniectomy (DCE); front view of a 3D-rendered fully segmented brain before (orange) and after (blue) DCE; axial view of a segmented plane after DCE; 3D-rendered segmented removed bone flap. (For interpretation of the references to colour in this figure legend, the reader is referred to the Web version of this article.)



**Fig. 2.** Schematic representation of the main surgical steps of a decompressive hemicraniectomy as described by Raabe et al. (Raabe, 2019) Dural incision after bony decompression is not shown. From left to right: inverted question mark incision and trauma flap preparation; burr hole placement; elevation of bone flap with contralateral support to avoid brain injuries. ©Raabe A.

(ICH), and hemorrhagic transformation on each pre- and postoperative CT by categorizing each as either true or false. In cases of disagreement, we relied on the radiological report. ICH was defined as a homogeneous blood clot, while hemorrhagic transformation was defined as an inhomogeneous distribution of blood sparsely throughout the infarct area.

#### 2.10. Surgery

At our institution we perform DHC as described in the Craniotomy Atlas by Raabe et al. (Fig. 2) (Raabe, 2019) and before its publication we followed the procedure described by Güresir et al. (2011) We aim to make our craniotomies as big as possible, aiming for a BFD of 16 cm with 12 cm as our minimal BFD target.

2.11. Outcome assessment, preoperative imaging and therapeutic data

We retrieved data on modified Rankin scale (mRS), radiological (vascular territories involved, vascular dissection, thrombus location, thrombectomy) and surgical outcome (duration of surgery, surgical site infection, revision surgery) from our hospital records. Clinical outcome (mRS) was assessed from the exit records after neurological rehabilitation 3 months post-surgery. Information on the mean duration of surgery and occurrence of infection needing surgical intervention was retrieved from our surgical database.

2.12. Statistical analysis

Descriptive statistics were used to report frequencies, means, ranges, and standard deviation (SD). Continuous variables are presented as median ± SD of median or ranges depending on which is more relevant. Normal distribution was assessed with a Shapiro-Wilk test. Linear regression analysis and the Kruskal-Wallis test were performed for mRS versus IV, mean brain swelling, swelling above the outer rim of the skull, and MLS. A P value < 0.05 was considered statistically significant.

Statistical analysis was performed using the Graphpad Prism© software (v8.0.1).




Fig. 3. Flow chart representing all patients screened and the reason for their eventual exclusion from the study population.

Table 1 Demographics of patient population.

Variable	Total (n = 44)
Number of females	15
Age (±SD)	51.86 (11.15)
NIHSS (median)	18
Preoperative thrombectomy	24
Uncal herniation	24
mRS (median)	4

Table 1. Patient related baseline characteristics; NIHSS, National Institutes of Health Stroke Scale; mRS, modified Rankin scale.

Table 2 Descriptive statistics of volumetric and radiographic analysis.

Variable	median	95% CI of median	range
Ischemic brain volume	165.9 mL	151.7–205.7 mL	45.60–460.8 mL
Preoperative brain volume	1051 mL	1040–1092 mL	745.2–1424 mL
Postoperative brain volume	1132 mL	1112–1177 mL	847.4–1516 mL
Brain swelling	75.35 mL	62.40–97.02 mL	8.7–151.2 mL
Preoperative midline shift	7.1 mm	5.7–8.6 mm	0–18.7 mm
Postoperative midline shift	4.5 mm	2.7–6.0 mm	0–19.0 mm
Midline shift difference	2.4 mm	0.2mm–3.8 mm	–6.4–11.7 mm
Bone flap volume	113.3 mL	104.3–121.6 mL	73.34–146.1 mL
Bone flap diameter	157.2 mm	153.5–163.0 mm	129.3–180.1 mm
Outward herniation volume	–33.63 mL	–51.15 to –12.93 mL	–100.3–47.35 mL
Brain swelling below the outer skull rim	1.62 mm	2.32–0.53 mm	5.3 to –2.19 mm

Table 2: Descriptive statistics for the volumetric and radiological analysis results. Negative herniation volume and swelling values above the outer rim of the skull indicate no herniation beyond the previous bony boarder. Negative midline shift (MLS) indicates an increased MLS after decompressive hemicraniectomy.

Table 3 Comparison of thrombus location and possible complicating factors between patients swelling above or below the previous skull rim after DCE.

Variable	Swelling below previous skull rim (n = 35, 79.6%)	Swelling above previous skull rim (n = 9, 20.4%)
Occlusion M1 or more distal	20	3
Carotid T occlusion	11	5
ICA occlusion other than carotid T	1	1
Tandem occlusion	3	0
Additional territories involved	8	3
Fetal PCA	2	2
Thrombectomy	18	6
Persisting distal occlusion after thrombectomy	10	2
Failed Thrombectomy	1	1

3. Results

3.1. Study population

We identified 86 patients who underwent DHC for large MCA infarction. After removing 42 according to the exclusion criteria, 44 patients were included in the study (Fig. 3, Table 1).

The descriptive statistical analyses of the radiological and volumetric data are summarized in Tables 2 and 3. The noteworthy finding is the negative median herniation volume beyond the outer skull rim (Table 2, Fig. 4; median –33.63 mL (95% CI –51.15 mL to –12.93 mL) meaning that, on average, the swollen brain did not fill the entire space vacated by the removed bone (Fig. 4a). In total, 9 patients (20.4%) had brain herniation beyond the previous outer rim of the skull, while 35 (79.6%) did not (Table 2, Fig. 4; median –1.62 mm (95% CI –2.32 mm to –0.53

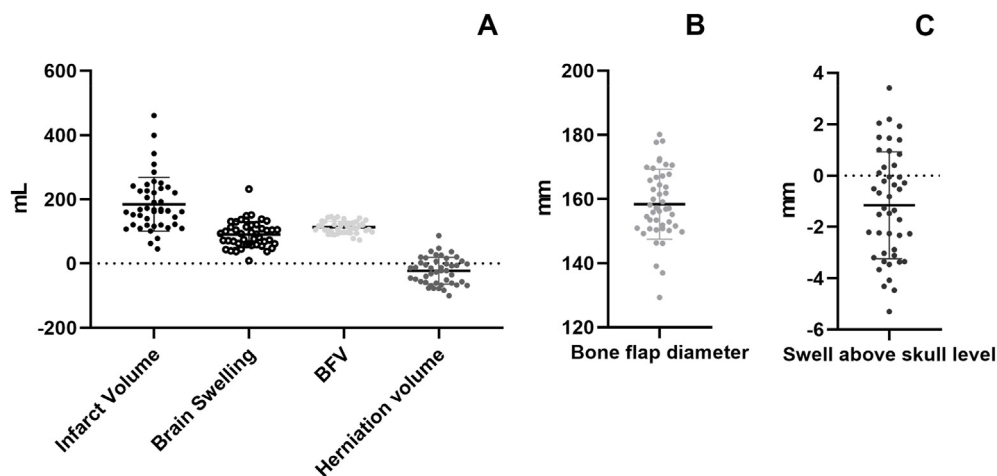


Fig. 4. A. Distribution of the different measured volumes in mL, B. the distribution of bone flap diameters, and C. the modeled swelling above the previous outer skull rim after decompressive hemicraniectomy. BFV, bone flap volume.

mm).

Median brain volume swelling over the previous skull limit for these 9 patients was 19.64 mL (range 1.9–47.35 mL). These patients had either multiple vascular territories involved ( $n = 3$ , 33.3%), a dissection of the internal carotid artery (ICA) ( $n = 4$ , 44.4%), thrombus location at the carotid T ( $n = 5$ , 55.6%), preexisting hemorrhagic transformation ( $n = 1$ , 11.1%), failed thrombectomy ( $n = 1$ , 11.1%) or a combination of the above. Thrombectomy was performed in 66.7% of those cases ( $n = 6$ ). 3 Patients (33.3%) had a thrombus location at M1, complicating factors for these were failed thrombectomy, hemorrhagic transformation, and multiple involved territories. No patient had an uncomplicated M1 occlusion (Table 3).

In contrast, of those patients in whom swelling did not extend beyond the previous skull limit, 46.9% had a simple M1 occlusion ( $n = 15$ ), 34.4% had a carotid T occlusion ( $n = 11$ ), 9.3% had a tandem ICA/M1 occlusion ( $n = 3$ ), and 6.3% ( $n = 2$ ) had proximal M2 occlusions; in one case (3.1%), the exact thrombus location could not be identified. In 22.9.1% ( $n = 8$ ) patients, additional vascular territories were involved. Thrombectomy was performed in 56.3% of cases ( $n = 18$ ); recanalization failed in 3.1% ( $n = 1$ ) patient.

### 3.2. Surgical parameters

The mean duration of surgery was 2:04 h (range 1:03 h–4:27 h). The median was 1:55 h (95% CI 01:49 h–02:12 h). Four patients (9.1%) underwent a surgical revision due to a wound infection. Two patients (4.5%) had a surgical implantation of an external ventricular drain (EVD) due to hydrocephalus (1 and 2 days after DHC, respectively). One patient (2.3%) received a burr hole trephination on the contralateral side to the DHC to evacuate a hygroma 3 months after DHC.

### 3.3. Hemorrhages

Twelve patients (27.3%) had a hemorrhagic transformation within the stroke area. One patient (2.3%) sustained a shearing injury at the craniotomy border caused by mushrooming. We did not observe any new ICH after surgery. In 3 patients (6.8%), ICH was already present at admission and was therefore present in the postoperative CT scan.

### 3.4. Clinical outcome

At 3 months after surgery, 6 (13.6%) of the patients had a mRS of 3, 22 (50.0%) had a mRS of 4, 1 (2.3%) had a mRS of 5, and 15 (34.1%) had a mRS of 6.

## 4. Discussion

In the large majority of our patients, the volume of freed bone was equal or larger than the volume of brain swelling and was only marginally lesser in the remaining patients. According to our model, the injured brain would have stayed below the outer rim of the skull in most patients and would not have expanded more than 2.19 mm beyond the rim in any patient (Table 2, Fig. 4). Authors of previous studies have postulated that an additional volume of 80–100 mL is needed in patients with malignant MCA infarction for adequate pressure relief (Flechsénhar et al., 2013). With a median craniotomy volume of 113.3 mL, the space freed up by the craniotomy itself appears sufficient for adequate pressure relief in most cases, with a minority requiring up to 50 mL additional space to match the expansion of the brain. Hence, an internal protection device with a minimal offset of approximately 2.2 mm would be adequate to avoid a dangerous increase in ICP while providing some degree of protection.

None of the patients in whom simple removal of the bone flap did not provide adequate volume for the brain to swell had an uncomplicated M1 occlusion as the stroke etiology ( $n = 3$ , 33.3%). This is in contrast to 46.9% M1 occlusions ( $n = 20$ ) in patients where bone flap removal sufficed to generate sufficient space for swelling. Although we cannot predict with certainty which patients with vascular occlusions other than M1 will experience swelling above the previous outer skull limit, it seems that patients with an uncomplicated M1 occlusion may be best suited for single-stage decompressive surgery. Since to our knowledge no single-stage decompressive procedure is performed anywhere in daily practice, there is no evidence of higher safety or lower complication rate for a single-stage procedure. In contrary, it may be argued, that all attempted single stage procedures up to now have not been shown to be equal to classical two-stage DHC (Layard Horsfall et al., 2020). In our view though the potential upsides of only having one surgical procedure as well as protection of the brain from outside influences are worth to be further explored. In a small series of patients (Schucht et al., 2022) on a single stage procedure with a space-expanding flap implanted to protect the brain no complications that would not also be expected in two-stage procedures were observed, though this will have to be confirmed in larger cohorts.

Stoner et al. performed volumetric analysis in 20 patients with malignant MCA infarction. In these patients, the average maximum herniation outside the outer rim of the skull was reported to be 3.46 mm (range, 0–8.69 mm), and was thus more than in our patients (Stoner et al., 2016). Stoner et al. concluded that a 5 mm offset would be required if a protective device was intended to be implanted during the first surgery. While the authors did not report the maximum diameter, the average BFV was 85.6 mL (range, 64.1–121.0 mL). The smaller

herniation effect in our patients may therefore be due to larger craniotomies.

Tanrikulu et al. showed that if the minimal limit of 12 cm diameter was achieved, a larger DHC did not reduce immediate surgical and secondary complications such as parenchymal herniation, hemorrhage, or swelling (Tanrikulu et al., 2015). Wagner et al. demonstrated an association between small DHC, localized DHC-associated bleeding, and an increased mortality rate and therefore postulated a minimal diameter of 12 cm for classical two-stage DHC (Wagner et al., 2001). This has also been used as a minimum diameter in patients undergoing DHC due to traumatic brain injury (Carney et al., 2017). In accordance with these findings, our institutional guidelines require a minimal diameter of 12 cm and recommend a target of 16 cm. In fact, all of the craniotomies in this series were larger than 12 cm, with a median diameter of 15.7 cm. The finding that only one (2.2%) patient had a herniation injury at the border of the craniotomy confirms the benefit of large craniotomies for prevention of these injuries. Also, craniectomies larger than 12 cm remove a higher volume of bone, allowing for an implanted device at, or slightly above, the previous outer bony limit, leading to a better single-stage cosmetic result than one with a smaller footprint but a larger offset.

Minnerup et al. suggested the ratio of ischemic lesion volume to cerebrospinal fluid could be used as a predictor of malignant infarction, indicating which patients should be considered for early decompression (Minnerup et al., 2011). Also, on CT-perfusion maps, the early involvement of more than two-thirds of the MCA territory predicts a malignant course with high sensitivity and specificity (Heiss, 2016). The decision whether to perform a single-stage procedure or a classical two-stage one may be facilitated if similar predictors that can estimate brain swelling volume can be identified.

We observed a decrease of MLS after DHC in 75% of patients (33/44), and in a further 13.6% (6/44) it only increased marginally (<2 mm). This is another important feature of DHC, as it should reduce the amount and rate of uncal and subfalcine herniation, protecting the decompressed brain from further injury.

#### 4.1. Surgical and clinical outcomes

We did not observe a large ICH after DHC in any patient that did not already have a bleed prior to surgery. Therefore, it seems that decompression of the brain does not predispose patients to bleeds as might have been expected (Disqué and Gahn, 2007).

Six patients (13.6%) had a mRS  $\leq 3$  at discharge from neurologic rehabilitation. Twenty-two (50%) had a mRS of 4 (motor hemiparesis, not able to walk unassisted) and one patient (2.3%) had a mRS of 5, while 15 (35.6%) did not survive until follow-up. This is comparable to the published data, as summarized in the meta-analysis published by Reinink et al. (Reinink et al., 2021) This meta-analysis incorporates all large randomized prospective trials on DHC including DESTINY, DECIMAL, and HAMLET, showing that 61% of patients had a mRS  $\leq 4$  at 1 year. In our study population, 63.6% of patients had a mRS  $\leq 4$  at discharge from neurological rehabilitation 3 months after infarction onset.

Our rate of surgical site infection (9.1%) requiring a second surgical procedure was similar to the rates reported in the literature (Dowlati et al., 2021).

#### 5. Limitations

This is a single-center, retrospective analysis. The use of CT scans (instead of MRI) for volumetric analysis may have led to an underestimation of infarct volume because, in many cases, infarction might still have been in a progressive phase. Maximal swelling of the hemisphere might have been underestimated because our investigation used a single time-point. Our model for the new swollen brain boundaries is an approximation, and might have underestimated the offset needed.

The results we report will have to be confirmed in a prospective study

with serial imaging studies; nevertheless, we are confident that the volumetric data acquired in this study are sufficient to indicate the approximate amount of additional space needed to allow for single-stage DHC procedures to be explored.

#### 6. Conclusion

Our series demonstrates that performing large DHCs with a minimal diameter of 12 cm and a target diameter of 16 cm is important for the prevention of herniation injuries. After a large DHC with a target diameter of 16 cm, the space generated by the removed bone alone appears to be sufficient for the brain to expand safely. No significant herniation beyond the outer rim of the skull was seen in the vast majority of patients – none if the stroke etiology was an uncomplicated M1 occlusion.

The involvement of multiple vascular territories, vascular dissection of the ICA, failed thrombectomy, thrombus location more proximal than M1, or preexisting chronic vascular occlusion may be risk factors for increased brain swelling. This will have to be further explored in larger patient cohorts to identify candidates for single-stage surgical procedures. Otherwise, if an additional offset of more than 2.2 mm is provided during surgery, patients presenting these hallmarks may also be candidates for single-stage procedures.

For the vast majority of patients with malignant MCA infarction, single-stage DHC strategies using implants to protect the brain at the previous outer skull limit may obviate the need for an additional offset after large craniotomies. Thus, such strategies could potentially improve outcome, avoiding CP and its associated morbidity. Furthermore, acceptable cosmetic results can be achieved, as large asymmetries of the skull are avoided.

#### Disclosure of funding

None.

#### Declaration of competing interest

The authors declare that they have no known competing financial interests or personal relationships that could have appeared to influence the work reported in this paper.

#### Appendix A. Supplementary data

Supplementary data to this article can be found online at <https://doi.org/10.1016/j.bas.2023.101730>.

#### References

- Andrabi, S.M., Sarmast, A.H., Kirmani, A.R., Bhat, A.R., 2017. Cranioplasty: indications, procedures, and outcome - an institutional experience. *Surg. Neurol. Int.* 8, 91. [https://doi.org/10.4103/sni.sni\\_45\\_17](https://doi.org/10.4103/sni.sni_45_17) (In eng).
- Carney, N., Totten, A.M., O'Reilly, C., et al., 2017, 1. In: *Guidelines for the Management of Severe Traumatic Brain Injury*, fourth ed., vol. 80. Neurosurgery, pp. 6–15. <https://doi.org/10.1227/neu.0000000000001432> (In eng).
- Chang, V., Hartzfeld, P., Langlois, M., Mahmood, A., Seyfried, D., 2010. Outcomes of cranial repair after craniectomy. *J. Neurosurg.* 112 (5), 1120–1124. <https://doi.org/10.3171/2009.6.Jns.09133> (In eng).
- De Bonis, P., Frassanito, P., Mangiola, A., Nucci, C.G., Anile, C., Pompucci, A., 2012. Cranial repair: how complicated is filling a "hole". *J. Neurotrauma* 29 (6), 1071–1076. <https://doi.org/10.1089/neu.2011.2116> (In eng).
- Disqué, C., Gahn, G., 2007. Ipsilateral parenchymal hemorrhage after hemicraniectomy in a patient suffering from malignant middle cerebral artery infarction. *Neurol.* 13 (2), 95–97. <https://doi.org/10.1097/01.nrl.0000254662.41344.73> (In eng).
- Dowlati, E., Mortazavi, A., Keating, G., et al., 2021. The retroauricular incision as an effective and safe alternative incision for decompressive hemicraniectomy. *Oper Neurosurg (Hagerstown)* 20 (6), 549–558. <https://doi.org/10.1093/ons/opab021> (In eng).
- Flechsenshar, J., Woitzik, J., Zweckberger, K., Amiri, H., Hacke, W., Jüttler, E., 2013. Hemicraniectomy in the management of space-occupying ischemic stroke. *J. Clin. Neurosci.* 20 (1), 6–12. <https://doi.org/10.1016/j.jocn.2012.02.019> (In eng).
- Fodstad, H., Love, J.A., Ekstedt, J., Fridén, H., Liliequist, B., 1984. Effect of cranioplasty on cerebrospinal fluid hydrodynamics in patients with the syndrome of the trephined. *Acta Neurochir.* 70 (1–2), 21–30. <https://doi.org/10.1007/bf01406039> (In eng).

- Goedemans, T., Verbaan, D., van der Veer, O., et al., 2020. Complications in cranioplasty after decompressive craniectomy: timing of the intervention. *J. Neurol.* 267 (5), 1312–1320. <https://doi.org/10.1007/s00415-020-09695-6> (In eng).
- Güresir, E., Vatter, H., Schuss, P., et al., 2011. Rapid closure technique in decompressive craniectomy. *J. Neurosurg.* 114 (4), 954–960. <https://doi.org/10.3171/2009.12.Jns091065> (In eng).
- Heiss, W.D., 2016. Malignant MCA infarction: pathophysiology and imaging for early diagnosis and management decisions. *Cerebrovasc. Dis.* 41 (1–2), 1–7. <https://doi.org/10.1159/000441627> (In eng).
- Hofmeijer, J., Kappelle, L.J., Algra, A., Amelink, G.J., van Gijn, J., van der Worp, H.B., 2009. Surgical decompression for space-occupying cerebral infarction (the Hemicraniectomy after Middle Cerebral Artery infarction with Life-threatening Edema Trial [HAMLET]): a multicentre, open, randomised trial. *Lancet Neurol.* 8 (4), 326–333. [https://doi.org/10.1016/s1474-4422\(09\)70047-x](https://doi.org/10.1016/s1474-4422(09)70047-x) (In eng).
- Hsu, Y.C., Po-Hao Huang, A., Xiao, F.R., Kuo, L.T., Tsai, J.C., Lai, D.M., 2019. Decompressive cranioplasty (Osteoplastic hinged craniectomy): a novel technique for increased intracranial pressure-initial experience and outcome. *World Neurosurg.* <https://doi.org/10.1016/j.wneu.2018.12.112> (In eng).
- Huttner, H.B., Jüttler, E., Schwab, S., 2008. Hemicraniectomy for middle cerebral artery infarction. *Curr. Neurol. Neurosci. Rep.* 8 (6), 526–533. <https://doi.org/10.1007/s11910-008-0083-1> (In eng).
- Joseph, V., Reilly, P., 2009. Syndrome of the trephined. *J. Neurosurg.* 111 (4), 650–652. <https://doi.org/10.3171/2009.3.Jns0984> (In eng).
- Jüttler, E., Schwab, S., Schmiedek, P., et al., 2007. Decompressive surgery for the treatment of malignant infarction of the middle cerebral artery (DESTINY): a randomized, controlled trial. *Stroke* 38 (9), 2518–2525. <https://doi.org/10.1161/strokeaha.107.485649> (In eng).
- Layard Horsfall, H., Mohan, M., Devi, B.I., et al., 2020. Hinge/floating craniotomy as an alternative technique for cerebral decompression: a scoping review. *Neurosurg. Rev.* 43 (6), 1493–1507. <https://doi.org/10.1007/s10143-019-01180-7> (In eng).
- Minnerup, J., Wersching, H., Ringelstein, E.B., et al., 2011. Prediction of malignant middle cerebral artery infarction using computed tomography-based intracranial volume reserve measurements. *Stroke* 42 (12), 3403–3409. <https://doi.org/10.1161/strokeaha.111.619734> (In eng).
- Raabe, A., 2019. *The Craniotomy Atlas*. Thieme, Stuttgart.
- Reinink, H., Jüttler, E., Hacke, W., et al., 2021. Surgical decompression for space-occupying hemispheric infarction: a systematic review and individual patient meta-analysis of randomized clinical trials. *JAMA Neurol.* 78 (2), 208–216. <https://doi.org/10.1001/jamaneurol.2020.3745> (In eng).
- Schucht, P., Nowacki, A., Osmanagic, A., et al., 2022. Space-expanding flap in decompressive hemicraniectomy for stroke. *J. Neurosurg.* 1–8. <https://doi.org/10.3171/2022.5.Jns22381> (In eng).
- Stoner, K.E., Abode-Iyamah, K.O., Grosland, N.M., Howard 3rd, M.A., 2016. Volume of brain herniation in patients with ischemic stroke after decompressive craniectomy. *World Neurosurg.* 96, 101–106. <https://doi.org/10.1016/j.wneu.2016.08.095> (In eng).
- Tanrikulu, L., Oez-Tanrikulu, A., Weiss, C., et al., 2015. The bigger, the better? About the size of decompressive hemicraniectomies. *Clin. Neurol. Neurosurg.* 135, 15–21. <https://doi.org/10.1016/j.clineuro.2015.04.019> (In eng).
- Vahedi, K., Vicaut, E., Mateo, J., et al., 2007. Sequential-design, multicenter, randomized, controlled trial of early decompressive craniectomy in malignant middle cerebral artery infarction (DECIMAL Trial). *Stroke* 38 (9), 2506–2517. <https://doi.org/10.1161/strokeaha.107.485235> (In eng).
- Wachter, D., Reineke, K., Behm, T., Rohde, V., 2013. Cranioplasty after decompressive hemicraniectomy: underestimated surgery-associated complications? *Clin. Neurol. Neurosurg.* 115 (8), 1293–1297. <https://doi.org/10.1016/j.clineuro.2012.12.002> (In eng).
- Wagner, S., Schnippering, H., Aschoff, A., Koziol, J.A., Schwab, S., Steiner, T., 2001. Suboptimum hemicraniectomy as a cause of additional cerebral lesions in patients with malignant infarction of the middle cerebral artery. *J. Neurosurg.* 94 (5), 693–696. <https://doi.org/10.3171/jns.2001.94.5.0693> (In eng).
- Wong, A.K., Wong, R.H., 2021. Split-thickness decompression in the management of intracranial pressure. *Korean J. Nutr.* 17 (1), 48–53. <https://doi.org/10.13004/kjnt.2021.17.e6> (In eng).
- Yang, X.F., Wen, L., Shen, F., et al., 2008. Surgical complications secondary to decompressive craniectomy in patients with a head injury: a series of 108 consecutive cases. *Acta Neurochir.* 150 (12), 1241–1247. <https://doi.org/10.1007/s00701-008-0145-9>; discussion 1248. (In eng).
- Zanaty, M., Chalouhi, N., Starke, R.M., et al., 2015. Complications following cranioplasty: incidence and predictors in 348 cases. *J. Neurosurg.* 123 (1), 182–188. <https://doi.org/10.3171/2014.9.Jns14405> (In eng).