

OPEN

Neurology Publish Ahead of Print
DOI: 10.1212/WNL.0000000000207510

Association of Presence and Pattern of MRI Markers of Cerebral Small Vessel Disease With Recurrent Intracerebral Hemorrhage

Author(s):

Simon Fandler-Höfler, MD^{1, 2}; Lena Obergottsberger¹; Gareth Ambler, PhD³; Sebastian Eppinger, MD^{1, 4}; Gerit Wunsch, PhD⁵; Markus Kneihsl, MD, PhD^{1, 4}; David Seiffge^{2, 6}; Gargi Banerjee, MD PhD²; Duncan Wilson, PhD²; Philip Nash, MD²; Hans Rudolf Jäger, MD⁷; Chris Enzinger, MD¹; David Werring, FRCP, PhD²; Thomas Gatteringer, MD^{1, 4}

Corresponding Author:

Thomas Gatteringer, thomas.gatteringer@medunigraz.at

This is an open access article distributed under the terms of the Creative Commons Attribution-NonCommercial-NoDerivatives License 4.0 (CC BY-NC-ND), which permits downloading and sharing the work provided it is properly cited. The work cannot be changed in any way or used commercially without permission from the journal.

Affiliation Information for All Authors: 1. Department of Neurology, Medical University of Graz, Austria 2. Stroke Research Centre, Department of Brain Repair & Rehabilitation, UCL Queen Square Institute of Neurology, United Kingdom 3. Department of Statistical Science, University College London, United Kingdom 4. Division of Neuroradiology, Vascular and Interventional Radiology, Department of Radiology, Medical University of Graz, Austria. 5. Institute for Medical Informatics, Statistics and Documentation, Medical University of Graz, Austria 6. Department of Neurology, University Hospital Bern, Inselspital, University of Bern, Switzerland. 7. Neuroradiological Academic Unit, Department of Brain Repair & Rehabilitation, UCL Queen Square Institute of Neurology, United Kingdom

Equal Author Contribution:

David J Werring and Thomas Gatttringer contributed equally to this work (co-senior authors).

Contributions:

Simon Fandler-Höfler: Drafting/revision of the manuscript for content, including medical writing for content; Major role in the acquisition of data; Study concept or design; Analysis or interpretation of data

Lena Obergottsberger: Major role in the acquisition of data

Gareth Ambler: Drafting/revision of the manuscript for content, including medical writing for content; Analysis or interpretation of data

Sebastian Eppinger: Major role in the acquisition of data

Gerit Wünsch: Major role in the acquisition of data

Markus Kneihsl: Drafting/revision of the manuscript for content, including medical writing for content; Major role in the acquisition of data

David Seiffge: Major role in the acquisition of data

Gargi Banerjee: Drafting/revision of the manuscript for content, including medical writing for content; Major role in the acquisition of data

Duncan Wilson: Drafting/revision of the manuscript for content, including medical writing for content; Major role in the acquisition of data

Philip Nash: Drafting/revision of the manuscript for content, including medical writing for content; Major role in the acquisition of data

Hans Rudolf Jäger: Study concept or design

Chris Enzinger: Drafting/revision of the manuscript for content, including medical writing for content; Study concept or design

David Werring: Drafting/revision of the manuscript for content, including medical writing for content; Study concept or design; Analysis or interpretation of data

Thomas Gatttringer: Drafting/revision of the manuscript for content, including medical writing for content; Study concept or design; Analysis or interpretation of data

Figure Count:

4

Table Count:

3

Search Terms:

[7] Intracerebral hemorrhage, [112] Outcome research, [120] MRI

Acknowledgment:

Study Funding:

The authors report no targeted funding.

Disclosure:

The authors report no relevant disclosures.

Preprint DOI:

Received Date:

2023-01-26

Accepted Date:

2023-04-24

Handling Editor Statement:

Submitted and externally peer reviewed. The handling editor was Editor-in-Chief José Merino, MD, MPhil, FAAN.

Abstract

Background: Assessing the risk of recurrent intracerebral hemorrhage (ICH) is of high clinical importance. MRI-based cerebral small vessel disease (SVD) markers may help establish ICH etiological subtypes (including cryptogenic ICH) relevant for recurrence risk.

Methods: We investigated the risk of recurrent ICH in a large cohort of consecutive ICH survivors with available MRI at baseline. Patients with macrovascular, structural or other identified secondary causes (other than SVD) were excluded. Based on MRI findings, ICH etiology was defined as probable cerebral amyloid angiopathy (CAA) according to the Boston 2.0 criteria, arteriolosclerosis (non-lobar ICH and additional markers of arteriolosclerosis, absent lobar hemorrhagic lesions), mixed SVD (mixed deep and lobar hemorrhagic changes) or cryptogenic (no MRI markers of SVD). Recurrent ICH was determined using electronic health records and confirmed by neuroimaging. Data from an independent multi-center cohort (CROMIS-2 ICH) was used to confirm core findings.

Results: Of 443 patients with ICH (mean age 67 ± 13 years, 41% female), ICH etiology was mixed SVD in 36.7%, arteriolosclerosis in 23.6%, CAA in 23.0%, and cryptogenic in 16.7%. During a median follow-up period of 5.7 years (IQR 2.9-10.0, 2682 patient-years), recurrent ICH were found in 59 individual patients (13.3%). The highest recurrence rate per 100 person-years was detected in patients with CAA (8.5, 95% CI 6.1-11.7), followed by mixed SVD (1.8, 95% CI 1.1-2.9) and arteriolosclerosis (0.6, 95% CI 0.3-1.5). No recurrent ICH occurred in patients with cryptogenic ICH during 510 person-years follow-up (97.5% CI, 0-0.7); this finding was confirmed in an independent cohort (CROMIS-2 ICH, $n=216$), in which there was also no recurrence in patients with cryptogenic ICH. In patients with CAA, cortical superficial siderosis was the imaging feature strongest related with ICH recurrence (hazard ratio 5.7, 95% CI 2.4-13.6).

Conclusions: MRI-based etiological subtypes are helpful in determining the recurrence risk of ICH; while the highest recurrence risk was found in CAA, recurrence risk was low for arteriolosclerosis, and negligible for cryptogenic ICH.

Background

Spontaneous intracerebral hemorrhage (ICH) is an often devastating form of stroke causing high mortality and disability.¹ ICH survivors have a substantial risk of recurrent events, which are associated with even higher risks of short- and longer-term mortality, estimated as 31% after one and 75% after ten years in a nationwide registry study.² An estimation of the individual risk of ICH recurrence is not only important for the communication of the long-term prognosis to patients and relatives, but also for the management of secondary prevention strategies, including antithrombotic (antiplatelet or anticoagulation) therapy, for which there is often an indication in ICH survivors.

Earlier studies identified a previous history of ischemic stroke³, poor blood pressure control⁴ and lobar location of the ICH⁵ as factors associated with an increased risk of recurrent ICH. The vast majority (65-80%)^{6,7} of ICH is caused by small vessel disease (SVD), namely either arteriolosclerosis (deep perforator arteriopathy) or cerebral amyloid angiopathy (CAA), while 10-20% are attributed to secondary etiologies, such as macrovascular or structural causes.^{7,8} Nevertheless, a relevant proportion of ICH (10-20%) remains unexplained (i.e., cryptogenic) after diagnostic work-up, although this proportion is not well established and will depend on the extent of investigation including the type(s), frequency and timing of brain and vascular imaging used.^{6,8}

MRI is a very sensitive method to visualize several markers of SVD, including cerebral microbleeds (CMBs), cortical superficial siderosis (cSS), lacunes, white matter hyperintensities (WMH) and enlarged perivascular spaces (ePVS).⁹ These markers allow assessment of the presence, type and severity of underlying SVD including CAA, with potential relevance for ICH recurrence risk. Probable CAA has been associated with much higher annual rates of recurrent ICH compared to patients with ICH not fulfilling diagnostic criteria for probable CAA (7.4% vs 1.1%).¹⁰

Moreover, a high burden of lobar CMBs¹⁰ and cSS^{11,12} have both been associated with a higher risk of ICH recurrence in patients with CAA. However, there are few large cohort studies systematically investigating the underlying causal arteriopathy - and its relevance for prognosis - in patients with the full spectrum of ICH due to SVD defined using MRI over a long follow-up period. We are not aware of data on the prognosis of cryptogenic ICH diagnosed after systematic investigation with MRI. Therefore, we performed a detailed observational single center, hospital-based cohort study of the prognostic relevance of MRI-defined etiological subtypes of SVD-associated ICH, including cryptogenic ICH, over a long follow-up period. We also externally validated our main findings in the independent CROMIS-2 ICH prospective UK multicenter cohort study.

Methods

Patient selection

We retrospectively identified all patients with a first-ever ICH treated between 2008 and 2021 at the University Hospital of Graz, Austria (n = 1372). Our center serves as a primary stroke center for the city of Graz and its surroundings, and as a tertiary care center for the federal state of Styria. Screening was performed using a combination of ICD-10 diagnosis (I61.X or I62.9) and free text search in discharge papers including radiological reports. Identification and exclusion of patients was done by a trained neurovascular specialist based on the electronic health records (SFH). At our center, MRI was performed as a standard of care in the inpatient work-up of ICH etiology during the entire study period, unless there were contraindications or high dependency. Diagnostic evaluation also included CT- or MR-angiography for all patients and CT- or MR-venography for suspected cerebral sinus venous thrombosis. Digital subtraction angiography, repeat MRI, or both, were routinely performed

in patients with unexplained (cryptogenic) ICH based on a weekly neurovascular meeting, consisting of vascular neurologists, neuroradiologists and neurosurgeons.

We excluded all patients who: died within 21 days of hospital admission; did not have diagnostic quality MRI within 90 days of admission; or for whom follow-up was not possible if patients moved outside of the catchment area of our electronic health records. We excluded all patients with a proven macrovascular, structural or other “secondary” cause of ICH (for details see study flowchart in **figure 1**).

Data assessment

Demographic and clinical data were extracted from the fully electronic hospital information system openMEDocs, which has been used in the larger administrative region since 1999. MRI scans were rated by a trained neurovascular specialist (SFH) with additional review in case of uncertainty by a senior neurovascular specialist (TG or DJW). MRI protocols included at least one blood-sensitive sequence (either T2* gradient-echo or susceptibility-weighted imaging), T2-weighted fluid attenuated inversion recovery, T2-weighted and diffusion-weighted images. For inclusion in the study, at least one diagnostic quality blood-sensitive sequence and at least one T2-weighted sequence had to be available. We investigated hematoma location according to the *Cerebral Haemorrhage Anatomical RaTing inStrument* (CHARTS)¹³ and trichotomized this as lobar, deep (including brainstem) and cerebellar. In uncertain cases, we determined the location of the presumed epicenter on the axial slice with the largest diameter of the ICH and compared it the corresponding anatomy in the unaffected hemisphere,¹³ and further used CT, follow-up imaging, or both, to differentiate hematoma location. We assessed hematoma size, concomitant subarachnoid and intraventricular hemorrhage, presence and severity of cortical superficial siderosis (which was defined as disseminated if affecting >3 sulci)¹⁴, evidence of silent old intracerebral hemorrhage or old territorial ischemic infarcts and markers of SVD according to the *STandards for ReportIng*

*Vascular changes on nEuroimaging (STRIVE) criteria.*⁹ The severity and distribution of cerebral microbleeds were rated according to the Microbleed Anatomical Rating Scale (MARS)¹⁵, periventricular and deep white matter hyperintensities (WMH) according to the Fazekas scale¹⁶ and enlarged perivascular spaces according to a validated four-point scale¹⁷ in the centrum semiovale and basal ganglia. WMH were defined as severe according to Fazekas scale scores of 2-3, ePVS as severe in scores of 3-4 on the visual rating scale. ICH etiology was classified as CAA when criteria for probable CAA based on the recently published Boston version 2.0 criteria¹⁸ were fulfilled. We classified the cause as arteriolosclerosis in patients with a non-lobar ICH and accompanying appropriate signs of SVD (at least one lacune, moderate or severe WMH, deep microbleeds or severely enlarged basal ganglia perivascular spaces) without any evidence of lobar microbleeds or lobar ICH. Patients with significant signs of SVD not fitting either CAA or arteriolosclerosis criteria (e.g., a mixture of lobar and deep signs of SVD) were grouped as mixed SVD. Patients without any MRI-visible signs of SVD (no microbleeds, lacunes, moderate/severe WMH nor severely enlarged perivascular spaces) were defined as cryptogenic. Examples of the four groups are illustrated in **figure 2**.

We performed detailed follow-up using the electronic health records, which are shared by all hospitals offering general and/or neurological emergency care in the larger administrative region. Recurrent events were identified through a detailed manual review of the electronic health records (which was performed in all patients) and confirmed on a case-to-case basis by a trained neurovascular specialist (SFH). For the diagnosis of recurrent ICH, neuroimaging evidence of ICH was mandatory. Mortality and time of death was also extracted from the electronic health records.

Validation cohort

To validate key findings from the primary study cohort, we used data from the CROMIS 2 ICH study cohort, a prospective observational multicenter study previously described in detail.^{19,20} In brief, patients with imaging-confirmed nontraumatic ICH were included in this study after exclusion of macrovascular or structural causes, and followed for up to approximately three years for recurrent events. For this work, we used the subset of all patients included in CROMIS-2 ICH with available baseline MRI including sequences to rate all relevant SVD markers.

Statistical analysis

We performed statistical analysis using IBM SPSS Statistics for Windows, version 28 (IBM Corp, Armonk, NY, USA) and STATA, version 16 (StataCorp LLC, College Station, USA). Categorical variables were compared by Pearson's chi-square test. After evaluation of the distribution of continuous variables, normally distributed continuous variables were compared by the unpaired Student's t-test; for other distributions non-parametric tests such as the Mann-Whitney U-test were used.

One-year, three- and five-years recurrence risks and the recurrence rate per 100 person-years were calculated for all patients and according to the presumed etiology. Kaplan-Meier curves were used to estimate risk of and freedom from recurrent ICH considering mortality as a censoring event. The proportional hazards assumption was confirmed by visual analysis of log-log plots and tests based on Schoenfeld residuals before using Cox regression to estimate hazard ratios of factors potentially related with the risk of (first) ICH recurrence. P-values of less than 0.05 were considered statistically significant.

Standard Protocol Approvals, Registrations, and Patient Consents

The study was approved by the ethics committee of the Medical University of Graz (approval number 32-265 ex 19/20). As a retrospective cohort study, the need for individual informed consent was waived. The CROMIS-2 study was approved by the National Research Ethics Service (IRAS reference 10/H0716/61).

Data availability

Anonymized data not published within this article will be made available by request from any qualified investigator.

Results

After applying all inclusion and exclusion criteria (**figure 1**), we included 443 patients with ICH (mean age 67 ± 13 years, 41% female). The most prevalent risk factor for ICH was arterial hypertension (82.6%), and the mean blood pressure at admission was $175\pm 32 / 96\pm 19$ mmHg. The median time from hospital admission to MRI was three days (IQR 1-8 days). For investigation of hemorrhagic lesions, SWI sequences were available in 62.5% of patients, 37.5% were investigated utilizing T2* gradient-echo scans.

ICH was in a deep location in 46.6%, lobar in 45.7% and cerebellar in 7.7% of patients. The median ICH volume was 9 ml (IQR 3-21 ml). Regarding ICH etiology, 23% of patients were classified as CAA, 23.6% as arteriolosclerosis, 36.7% as mixed SVD and 16.7% as cryptogenic ICH (**table 1**).

Recurrent intracerebral hemorrhage

The median follow-up period was 5.7 years (interquartile range 2.9-10.0), during which 80 recurrent ICH events were recorded in 59 individual patients. At time of recurrence, the majority of patients were not taking anticoagulation or antiplatelet therapy (79.7%), with only three patients (5.1%) taking anticoagulation and nine patients (15.3%) taking single antiplatelet therapy (all acetylsalicylic acid, no combination therapies).

Lobar location, subarachnoid extension of the index hematoma, cSS, CMB presence, total and lobar CMBs counts, and ICH etiology were all strongly associated with recurrent ICH (all $p < 0.001$) (**table 1**). Further neuroimaging findings associated with recurrent ICH were severe WMH (deep, $p = 0.01$; periventricular, $p = 0.02$) and ePVS in the centrum semiovale ($p = 0.01$, table 1) as well as age ($p = 0.03$).

The one-, three- and five-year recurrence risks were 5%, 8% and 13%, respectively, with an overall recurrence rate of 2.2 per 100 patients-years (**table 2**). Patients with CAA had the highest recurrence rate (8.5 per 100 person-years), followed by mixed SVD (1.8 per 100 person-years) and arteriolosclerosis (0.6 per 100 person-years). No patient with cryptogenic ICH had a recurrent ICH. **Figure 3** visualizes the frequencies of recurrent ICH according to baseline ICH etiology. **Figure 4** displays a Kaplan-Meier curve for risk of recurrent ICH, showing the varying risks over time in the different etiological subgroups ($p < 0.001$). During the follow-up period, 15.1% of patients died. Mortality was highest in patients with CAA (21.6%), followed by mixed SVD (18.5%), arteriolosclerosis (11.4%) and cryptogenic ICH (4.1%).

Cerebral amyloid angiopathy

The one-, three-, and five-year-risk of recurrent ICH in patients with CAA were 17%, 25% and 41%, respectively (**table 2**). The presence and severity of cSS were strongly associated with recurrent ICH (presence: hazard ratio 5.7, 95% CI 2.4-13.6; disseminated: hazard ratio 3.9, 95% CI 2.0-7.9, both $p < 0.001$). Patients with CAA and disseminated CSS had one-, three-, and five-year-risks of 36% (95% CI 23%-52%), 44% (95% CI 31%-61%) and 61% (95% CI 45%-77%), respectively. Patients with CAA and recurrent ICH had a higher rate of subarachnoid extension of the index ICH ($p = 0.04$, **table 3**).

Mixed small vessel disease and arteriolosclerosis

The risk of recurrent ICH was lower in patients with arteriosclerosis (one-, three- and five-year risks of 1% each) compared to patients with mixed SVD (one-, three- and five-year-risk of 3%, 6% and 10%, **table 2**). In patients with mixed SVD, the numbers of total CMBs ($p = 0.002$), lobar CMBs ($p = 0.04$) and deep CMBs ($p = 0.03$) were associated with a higher risk for recurrent ICH (**table 3**). We did not perform subgroup analysis of patients with arteriolosclerosis due to the low number of recurrent ICH in that group ($n = 5$).

Cryptogenic ICH

Patients with cryptogenic ICH were younger than ICH patients with a defined etiology (58.1 ± 15.7 versus 69.3 ± 11.3 years, $p < 0.001$). No significant differences were found regarding sex, ICH risk factors or prior anticoagulant/antiplatelet therapy. The predominant ICH location in these patients was lobar (51.4%), followed by deep (40.5%) and cerebellar (8.1%). Over an observation period of 510 person-years, no recurrent ICH occurred (corresponding to a rate of 0 per 100-person-years, 97.5% CI 0-0.7, **figures 3 and 4**).

Validation cohort for recurrence risks including cryptogenic ICH

To confirm the novel finding of a very low recurrence rate in patients with cryptogenic ICH, we included data from an independent external validation cohort from the multicenter CROMIS-2 ICH prospective cohort study. Of 216 patients with complete data including baseline MRI and three-year follow-up (total follow-up time: 532 person-years), 41 (19.0%) had cryptogenic ICH (48.1% had mixed SVD, 19.4% CAA, and 13.4% arteriolosclerosis). Over a follow-up period of 107 patients-years, no recurrent ICH occurred in patients with cryptogenic ICH (confidence interval calculated for both study cohorts: 0-0.6 per 100 person-years). The recurrence rates in the other etiological categories were also similar to those observed in our primary study cohort (CAA: 6.0 per 100 person-years, mixed SVD: 2.3 per 100 person-years, arteriolosclerosis: no recurrences).

Discussion

In this single-center study investigating recurrence rates in consecutive patients with spontaneous ICH that underwent brain MRI to classify the underlying cause, we made two new observations with potential clinical relevance. First, we have confirmed that MRI-based etiological classification of the underlying SVD type (beyond CAA vs non-CAA) is a critical factor in the estimation of recurrence risk of ICH. Second, in patients with cryptogenic ICH (i.e., ICH without a macrovascular, structural or other secondary cause, and no evidence of SVD on MRI) not a single recurrent ICH occurred over a long follow-up period (510 person-years); this finding was also confirmed in a well-defined external validation cohort.

The finding of a negligible recurrence risk for cryptogenic ICH (after careful investigation for SVD, macrovascular, structural and other causes of ICH) is a novel finding with immediate applicability for daily clinical practice. Our data provide prognostic information which should

be helpful for patients, carers and healthcare professionals when discussing the likely recurrence risk. Although our data do not allow the assessment of how treatments might modify this low risk, the baseline recurrence risk can nonetheless inform clinical decisions, for example in relation to (re-)initiation of antiplatelet or anticoagulation therapy. Surprisingly few prior studies have investigated cryptogenic ICH in depth using detailed and systematic investigation including brain and vascular imaging including MRI. A recent meta-analysis found an average pooled prevalence of cryptogenic ICH of 18%,⁶ corresponding to the frequency observed in our primary study cohort of 17%. However, as we excluded patients with secondary (macrovascular, structural or other) causes from the analysis, the actual prevalence in our initial unselected ICH cohort is somewhat lower (13%), which is likely due to the utilization of MRI in all patients to assess findings of SVD, some of which (e.g. CMBs, cSS) cannot be reliably assessed on CT alone. The underlying causes of cryptogenic ICH are unknown. Possible contributory factors to cryptogenic ICH could include the following individually or in combination: transient risk factors (e.g., sudden severe peaks in hypertension due to environmental stressors, recreational or over-the counter drug use such as sympathomimetic agents); early SVD too mild to be detected by conventional structural MRI; transient or elusive macrovascular lesions (e.g., a micro-arteriovenous malformation too small to be detected by the angiographic modality used or obliterated by destructive effects of the resulting acute ICH); reversible arteriopathies (e.g. reversible vasoconstriction syndrome which can be missed without early and repeated cerebral angiography); or hemorrhagic transformation of an ischemic infarct. Nevertheless, our findings indicate that despite the largely unknown and potentially diverse possible causes of cryptogenic ICH (after careful investigation for SVD, macrovascular, structural and other causes), all seem to share the same extremely low risk of recurrence.

In contrast, patients with CAA had the highest risk of recurrent ICH. While this (together with a higher risk of ICH recurrence in patients with lobar ICH) has been described previously,

detailed analysis of MRI findings in CAA as well as other SVD subtypes has seldom been performed in a large cohort with a long duration of follow-up. In line with prior cohort studies, we found cortical superficial siderosis to be the main neuroimaging risk factor for recurrence risk in patients with CAA, with a large increase in risk associated with disseminated cSS (i.e., in ≥ 3 sulci).^{11,12}

The risk of ICH recurrence in patients with arteriolosclerosis or mixed SVD has rarely been systematically investigated. We found a more pronounced risk of recurrence in patients with mixed SVD compared to “pure” arteriolosclerosis, with a higher burden of microbleeds indicating an increased risk of ICH recurrence. Two recent studies also found a higher risk of recurrent ICH in patients with mixed SVD compared to those with arteriolosclerosis, but have not investigated the association of specific neuroimaging findings in those patients with risk for recurrent ICH.^{21,22} These findings can likely be explained by one of two mechanisms, either alone or in combination: firstly, patients with CAA and some degree of arteriolosclerosis (“true” mixed SVD) will likely have higher ICH recurrence risk associated with CAA; second, patients with a high burden of microbleeds in both deep and lobar locations due to arteriolosclerosis are likely to have a more severe vasculopathy than those with only deep MRI manifestations of SVD. Neither of these studies investigated patients with cryptogenic ICH as a separate category (instead attributing patients without additional findings of SVD to one of the other groups based on ICH location alone), but our findings suggest that this has important prognostic significance.^{21,22}

Compared to prior studies investigating the recurrence risk of ICH, we found similar risk rates in our study.¹⁰ A meta-analysis of ten various studies (most of which were single-center hospital-based studies) found an average yearly risk of 7.4% in CAA patients and 1.1% in non-CAA patients (our study found 8.5% and 1.0%) with high heterogeneity. However, the mean follow-up period in included studies (1-3 years) was much lower compared to our study,

which should lead to a higher overall risk rate (due to a high rate of early ICH recurrence in patients with CAA, which was also found in our study with a one-year recurrence risk of 17%). This suggests that our ascertainment of recurrent ICH is likely to be complete and mitigates against missing follow-up data. The finding of a high rate of recurrent ICH could also be due to the broad spectrum of consecutive MRI-investigated patients included in our study – in contrast to some prior studies showing lower recurrence rates, which might be accounted for by selection bias towards performing MRI scans in younger, less severely disabled patients with ICH), limited detection of recurrent ICH, or both.

Nevertheless, based on the retrospective single-center study setting, we cannot fully exclude selection bias, although our center acts as a primary stroke center for a large catchment area. A proportion of patients with severe disability or contraindications did not undergo MRI and therefore could not be included in this study, which may lead to bias. Anticoagulation and/or antiplatelet medication use after index ICH may also play a relevant role in the risk of recurrence and could not be reliably assessed throughout the follow-up period in this study. However, the proportion of patients with antithrombotic therapy at time of ICH recurrence was rather low (20%). As we used routine MRI scans for assessment of patients, there was some variation in scanners and protocols used over the study period (including T2* being performed instead of SWI in a minority of patients), which is also a limitation of this study. Nonetheless, we were able to validate a key novel finding of this study - the very low recurrence rate in patients with cryptogenic ICH - in an independent multicenter validation cohort with a different study setting.

In conclusion, we found that MRI-based phenotyping of ICH according to the likely underlying causal arteriopathy is very helpful in stratification of recurrence risk, with the highest risk in patients with CAA (especially those with disseminated CSS), moderate risk in

mixed SVD, much lower risk in patients with arteriolosclerosis, and an apparently negligible risk in patients with cryptogenic ICH after systematic diagnostic evaluation.

Declarations

Funding: No funding was received for conducting this study.

Conflicts of interests: The authors report no disclosures relevant to the manuscript.

Acknowledgements: None.

ACCEPTED

References

1. Fogelholm R, Murros K, Rissanen A, Avikainen S. Long term survival after primary intracerebral haemorrhage: a retrospective population based study. *J Neurol Neurosurg Psychiatry*. 2005;76:1534–1538.
2. Skajaa N, Adelborg K, Horváth-Puhó E, et al. Risks of Stroke Recurrence and Mortality After First and Recurrent Strokes in Denmark: A Nationwide Registry Study. *Neurology*. Epub 2021 Nov 29.:10.1212/WNL.0000000000013118.
3. Huhtakangas J, Löppönen P, Tetri S, et al. Predictors for recurrent primary intracerebral hemorrhage: a retrospective population-based study. *Stroke*. 2013;44:585–590.
4. Biffi A, Anderson CD, Battey TWK, et al. Association Between Blood Pressure Control and Risk of Recurrent Intracerebral Hemorrhage. *JAMA*. 2015;314:904–912.
5. Poon MTC, Fonville AF, Al-Shahi Salman R. Long-term prognosis after intracerebral haemorrhage: systematic review and meta-analysis. *J Neurol Neurosurg Psychiatry*. 2014;85:660–667.
6. Malhotra K, Zompola C, Theodorou A, et al. Prevalence, Characteristics, and Outcomes of Undetermined Intracerebral Hemorrhage: A Systematic Review and Meta-Analysis. *Stroke*. 2021;52:3602–3612.
7. Hostettler IC, Seiffge DJ, Werring DJ. Intracerebral hemorrhage: an update on diagnosis and treatment. *Expert Rev Neurother*. 2019;19:679–694.
8. Goeldlin MB, Mueller A, Siepen BM, et al. Etiology, 3-Month Functional Outcome and Recurrent Events in Non-Traumatic Intracerebral Hemorrhage. *J Stroke*. 2022;24:266–277.
9. Wardlaw JM, Smith EE, Biessels GJ, et al. Neuroimaging standards for research into small vessel disease and its contribution to ageing and neurodegeneration. *The Lancet Neurology*. 2013;12:822–838.
10. Charidimou A, Imaizumi T, Moulin S, et al. Brain hemorrhage recurrence, small vessel disease type, and cerebral microbleeds: A meta-analysis. *Neurology*. 2017;89:820–829.
11. Charidimou A, Peeters AP, Jäger R, et al. Cortical superficial siderosis and intracerebral hemorrhage risk in cerebral amyloid angiopathy. *Neurology*. 2013;81:1666–1673.
12. Charidimou A, Boulouis G, Roongpiboonsopit D, et al. Cortical superficial siderosis and recurrent intracerebral hemorrhage risk in cerebral amyloid angiopathy: Large prospective cohort and preliminary meta-analysis. *Int J Stroke*. 2019;14:723–733.
13. Charidimou A, Schmitt A, Wilson D, et al. The Cerebral Haemorrhage Anatomical RaTing inStrument (CHARTS): Development and assessment of reliability. *J Neurol Sci*. 2017;372:178–183.
14. Linn J, Halpin A, Demaerel P, et al. Prevalence of superficial siderosis in patients with cerebral amyloid angiopathy. *Neurology*. 2010;74:1346–1350.

15. Gregoire SM, Chaudhary UJ, Brown MM, et al. The Microbleed Anatomical Rating Scale (MARS): reliability of a tool to map brain microbleeds. *Neurology*. 2009;73:1759–1766.
16. Fazekas F, Chawluk J, Alavi A, Hurtig H, Zimmerman R. MR signal abnormalities at 1.5 T in Alzheimer's dementia and normal aging. *American Journal of Roentgenology*. 1987;149:351–356.
17. Charidimou A, Jaunmuktane Z, Baron J-C, et al. White matter perivascular spaces: an MRI marker in pathology-proven cerebral amyloid angiopathy? *Neurology*. 2014;82:57–62.
18. Charidimou A, Boulouis G, Frosch MP, et al. The Boston criteria version 2.0 for cerebral amyloid angiopathy: a multicentre, retrospective, MRI-neuropathology diagnostic accuracy study. *Lancet Neurol*. 2022;21:714–725.
19. Seiffge DJ, Wilson D, Ambler G, et al. Small vessel disease burden and intracerebral haemorrhage in patients taking oral anticoagulants. *J Neurol Neurosurg Psychiatry*. Epub 2021 Mar 19.:jnnp-2020-325299.
20. Charidimou A, Wilson D, Shakeshaft C, et al. The Clinical Relevance of Microbleeds in Stroke study (CROMIS-2): rationale, design, and methods. *Int J Stroke*. 2015;10 Suppl A100:155–161.
21. Pasi M, Charidimou A, Boulouis G, et al. Mixed-location cerebral hemorrhage/microbleeds: Underlying microangiopathy and recurrence risk. *Neurology*. 2018;90:e119–e126.
22. Tsai H-H, Chen S-J, Tsai L-K, et al. Long-Term Vascular Outcomes in Patients With Mixed Location Intracerebral Hemorrhage and Microbleeds. *Neurology*. 2021;96:e995–e1004.

Table 1: Clinical characteristics of study participants categorized by recurrent ICH

	Entire ICH cohort n=443	Recurrent ICH n=59 (13.3%)	No recurrence n=384 (86.7%)	p-value*
Clinical data				
Age (years. mean)	67.4±12.8	70.2±10.9	67.0±13.0	0.03
Male sex	263 (59.4%)	32 (54.2%)	231 (60.2%)	0.39
Arterial hypertension	366 (82.8%)	46 (79.3%)	320 (83.3%)	0.49
Diabetes mellitus	81 (18.4%)	8 (13.8%)	73 (19.1%)	0.35
Systolic BP at admission (mean)	175±32	171±28	175±32	0.25
Diastolic BP at admission (mean)	96±19	93±16	97±20	0.17
Anticoagulation at time of index ICH	52 (12.6%)	5 (9.6%)	47 (13.0%)	0.64
Antiplatelet therapy at time of index ICH	106 (25.6%)	17 (32.7%)	89 (24.6%)	0.25
Hematoma location				
Lobar	202 (45.6%)	46 (78.0%)	156 (40.6%)	<0.001
Deep	207 (46.7%)	13 (22.0%)	194 (50.5%)	
Cerebellar	34 (7.7%)	0	34 (8.9%)	
MRI findings				
ICH volume (median, IQR)	9 (3-21)	12 (4-30)	8 (3-19)	0.13
Subarachnoid extension of ICH	112 (25.3%)	34 (57.6%)	78 (20.3%)	<0.001
Concomitant intraventricular hemorrhage	120 (27.1%)	17 (28.8%)	103 (26.8%)	0.74
Cortical superficial siderosis, any	69 (15.6%)	32 (54.2%)	37 (9.6%)	<0.001
Disseminated cortical superficial siderosis	46 (10.4%)	25 (42.4%)	21 (5.5%)	<0.001
Microbleeds, any	279 (63.0%)	49 (83.1%)	230 (59.9%)	0.001
Microbleed number (median, IQR)	2 (0-8)	6 (1-26)	1 (0-7)	<0.001
Lobar microbleed number (median, IQR)	0 (0-5)	4 (1-21)	0 (0-3)	<0.001
Deep microbleed number (median, IQR)	0 (0-2)	0 (0-2)	0 (0-2)	0.20
Old macrohemorrhage	46 (10.4%)	9 (15.3%)	37 (9.7%)	0.13
Severe deep WMH	183 (41.3%)	31 (52.5%)	152 (39.6%)	0.01
Severe periventricular WMH	207 (46.7%)	34 (57.6%)	173 (45.1%)	0.02
Lacunae, any	112 (25.3%)	12 (20.3%)	100 (26.0%)	0.26
Severely ePVS (centrum semiovale)	197 (47.1%)	33 (58.9%)	164 (45.3%)	0.007
Severely ePVS (basal ganglia)	108 (25.7%)	9 (16.1%)	99 (27.2%)	0.13
Diffusion-weighted imaging positive lesions	48 (10.8%)	7 (11.9%)	41 (10.7%)	0.43
Old cortical/cerebellar ischemic infarcts	60 (13.5%)	8 (13.6%)	52 (13.5%)	0.99
ICH etiology				
Cerebral amyloid angiopathy	102 (23.0%)	37 (62.7%)	65 (16.9%)	<0.001
Arteriosclerosis	105 (23.7%)	5 (8.5%)	100 (26.0%)	
Mixed small vessel disease	162 (36.6%)	17 (28.8%)	145 (37.8%)	
Cryptogenic	74 (16.7%)	0	74 (19.3%)	

Legend: BP: Blood pressure; CSS: Cortical superficial siderosis, ePVS: enlarged perivascular spaces, ICH: Intracerebral hemorrhage, SAH: Subarachnoid hemorrhage, WMH: White matter hyperintensities. *Calculated using Cox regression.

Table 2: Recurrence risk of intracerebral hemorrhages according to presumed etiology

	Number	Person-years	1-year risk (95% CI, n=423)	3-year risk (95% CI, n=342)	5-year risk (95% CI, n=282)	Recurrence rate per 100 person-years (95% CI)
Any intracerebral hemorrhage	443	2682	5% (3%-8%)	8% (6%-11%)	13% (10%-17%)	2.2 (1.7-2.8)
Cerebral amyloid angiopathy	102 (23.0%)	438	17% (11%-26%)	25% (17%-36%)	41% (31%-53%)	8.5 (6.1-11.7)
Mixed small vessel disease	162 (36.6%)	955	3% (1%-7%)	6% (3%-12%)	10% (6%-16%)	1.8 (1.1-2.9)
Arteriolosclerosis	105 (23.7%)	779	1% (0%-7%)	1% (0%-7%)	1% (0%-7%)	0.6 (0.3-1.5)
Cryptogenic intracerebral hemorrhage	74 (16.7%)	510	0	0	0	0 (0-0.7)

Table 3: Clinical characteristics of study participants with cerebral amyloid angiopathy and mixed small vessel disease

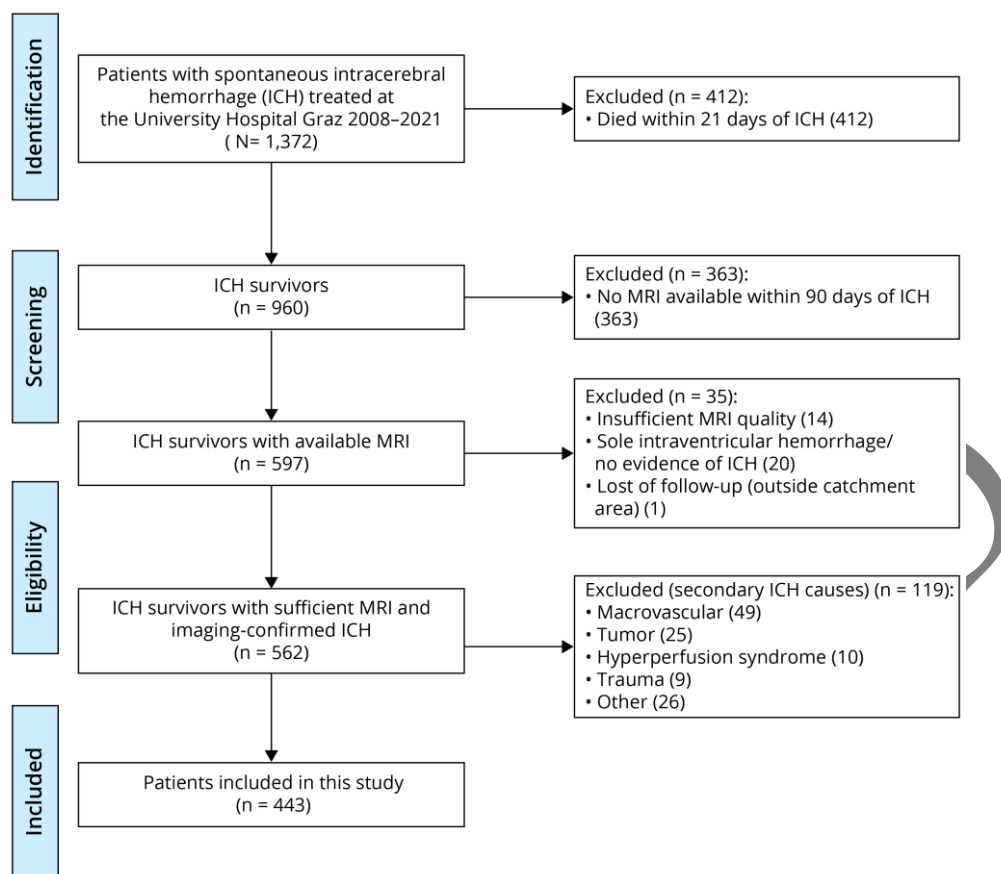
	Cerebral amyloid angiopathy (n=102)			Mixed small vessel disease (n=162)		
	Recurrent ICH n=37 (36.3%)	No recurrence n=65 (63.7%)	p-value*	Recurrent ICH n=17 (10.5%)	No recurrence n=145 (89.5%)	p-value*
Clinical data						
Age (years, mean)	73.9±7.2	72.6±8.7	0.28	65.1±13.4	68.9±11.1	0.29
Male sex	22 (59.5%)	35 (53.8%)	0.58	7 (41.2%)	90 (62.1%)	0.10
Arterial hypertension	27 (75.0%)	47 (72.3%)	0.88	14 (82.4%)	133 (91.7%)	0.24
Diabetes mellitus	4 (11.1%)	9 (13.8%)	0.98	4 (23.5%)	28 (19.4%)	0.47
Systolic BP at admission (mean)	167±26	166±26	0.61	182±33	183±33	0.82
Diastolic BP at admission (mean)	90±15	91±18	0.39	100±19	103±20	0.79
Anticoagulation at time of index ICH	2 (6.1%)	3 (4.7%)	0.77	2 (12.5%)	23 (16.8%)	0.72
Antiplatelet therapy at time of index ICH	15 (45.5%)	20 (31.3%)	0.19	2 (12.5%)	34 (24.8%)	0.26
MRI findings						
ICH volume (median, IQR)	18 (7-33)	15 (6-25)	0.41	6 (2-11)	6 (2-14)	0.76
Subarachnoid extension of ICH	32 (86.5%)	45 (69.2%)	0.04	2 (11.8%)	18 (12.4%)	0.88
Concomitant intraventricular hemorrhage	9 (24.3%)	12 (18.5%)	0.44	6 (35.3%)	38 (26.2%)	0.56
Cortical superficial siderosis, any	31 (83.8%)	26 (40.0%)	<0.001	1 (5.9%)	11 (7.6%)	0.97
Disseminated cortical superficial siderosis	25 (67.6%)	17 (26.2%)	<0.001	0	4 (2.8%)	0.49
Microbleeds, any	31 (83.8%)	43 (66.2%)	0.10	15 (88.2%)	138 (95.2%)	0.43
Microbleed number (median, IQR)	6 (1-30)	2 (0-8)	0.29	9 (4-38)	8 (3-18)	0.002
Lobar microbleed number (median, IQR)	6 (1-29)	2 (0-7)	0.34	4 (2-23)	3 (1-8)	0.04
Deep microbleed number (median, IQR)	0 (0-0)	0 (0-0)	N/A	4 (2-15)	3 (1-7)	0.003
Old macrohemorrhage	4 (10.8%)	4 (6.2%)	0.23	4 (23.5%)	24 (16.6%)	0.45
Severe deep WMH	18 (48.6%)	27 (41.5%)	0.20	12 (70.6%)	89 (61.4%)	0.33

Severe periventricular WMH	19 (51.4%)	31 (47.7%)	0.60	13 (76.5%)	97 (66.9%)	0.32
Lacunae, any	1 (2.7%)	5 (7.7%)	0.36	9 (52.9%)	69 (47.6%)	0.84
Severely ePVS (centrum semiovale)	25 (73.5%)	50 (79.4%)	0.71	6 (35.3%)	66 (48.9%)	0.73
Severely ePVS (basal ganglia)	4 (11.8%)	8 (12.7%)	0.89	4 (23.5%)	64 (47.1%)	0.11
Diffusion-weighted imaging positive lesions	6 (16.2%)	6 (9.2%)	0.20	0	23 (15.9%)	0.08
Old cortical/cerebellar ischemic infarcts	6 (16.2%)	5 (7.7%)	0.18	1 (5.9%)	29 (20.0%)	0.16

Legend: BP: Blood pressure; CSS: Cortical superficial siderosis, ePVS: enlarged perivascular spaces, ICH: Intracerebral hemorrhage, SAH: Subarachnoid hemorrhage, SVD: small vessel disease, WMH: White matter hyperintensities. *Calculated using Cox regression.

ACCEPTED

Figure 1: Study flowchart



ACCL

Figure 2: Neuroimaging examples for the four aetiological subgroups of ICH. Green arrows indicate different features of cerebral small vessel disease (SVD).

Top row: Patient with lobar occipital ICH (A1) due to probable cerebral amyloid angiopathy. MRI shows extensive confluent white matter hyperintensities (A2), disseminated cortical superficial siderosis, numerous lobar microbleeds (A3) and severely enlarged perivascular spaces in the centrum semiovale (A4). This patient had a recurrent lobar ICH two months after the index ICH.

Second row: Patient with deep ICH in the basal ganglia (B1) due to arteriolosclerosis. MRI shows confluent white matter hyperintensities (B2), deep microbleeds (B3) and severely enlarged perivascular spaces in the basal ganglia (B4).

Third row: Patient with a thalamic ICH (C1) and mixed SVD features. MRI depicts early confluent white matter hyperintensities (C2), lacunes (C2, C4) and several lobar microbleeds (C3, further deep microbleeds not shown). Bottom row: Patient with a cryptogenic lobar occipital ICH (D1) without any signs of SVD (aside from a few punctate white matter hyperintensities, D2). Detailed work-up including repeat MRI and digital subtraction angiopathy excluded structural or macrovascular causes.

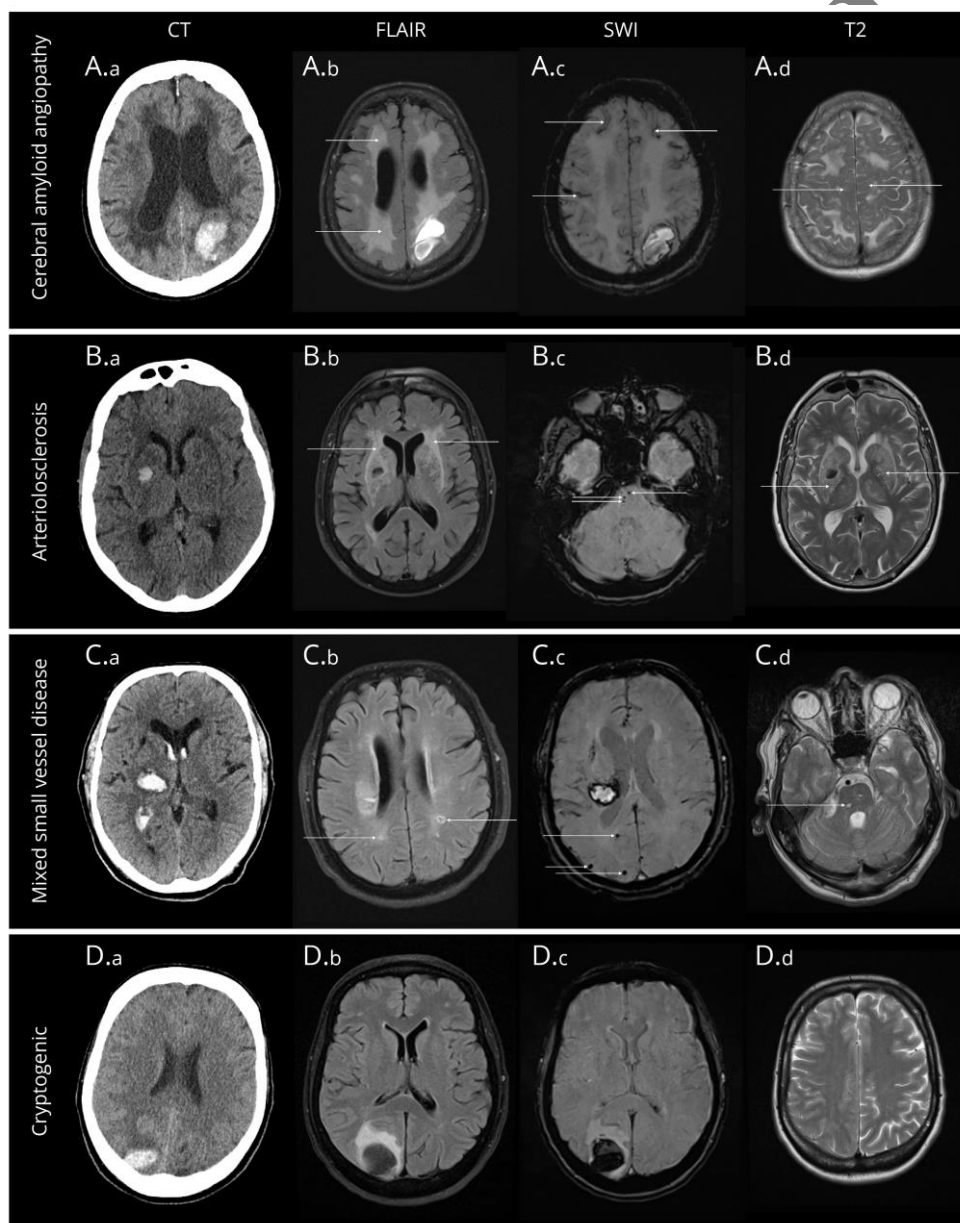


Figure 3: Absolute numbers of patients with and without recurrent intracerebral haemorrhage (ICH) according to the aetiology of the index ICH. Legend: CAA: cerebral amyloid angiopathy, SVD: small vessel disease

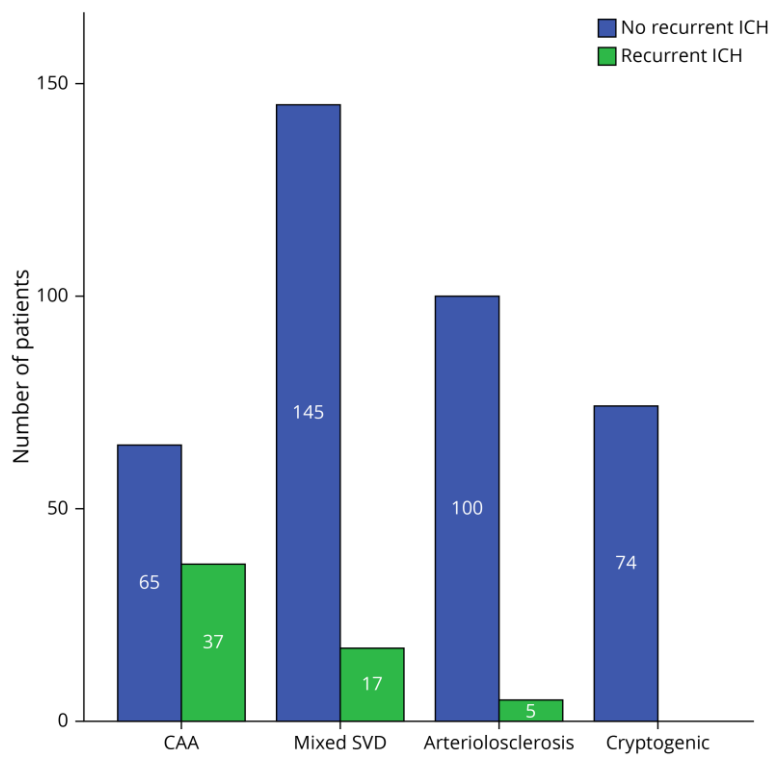
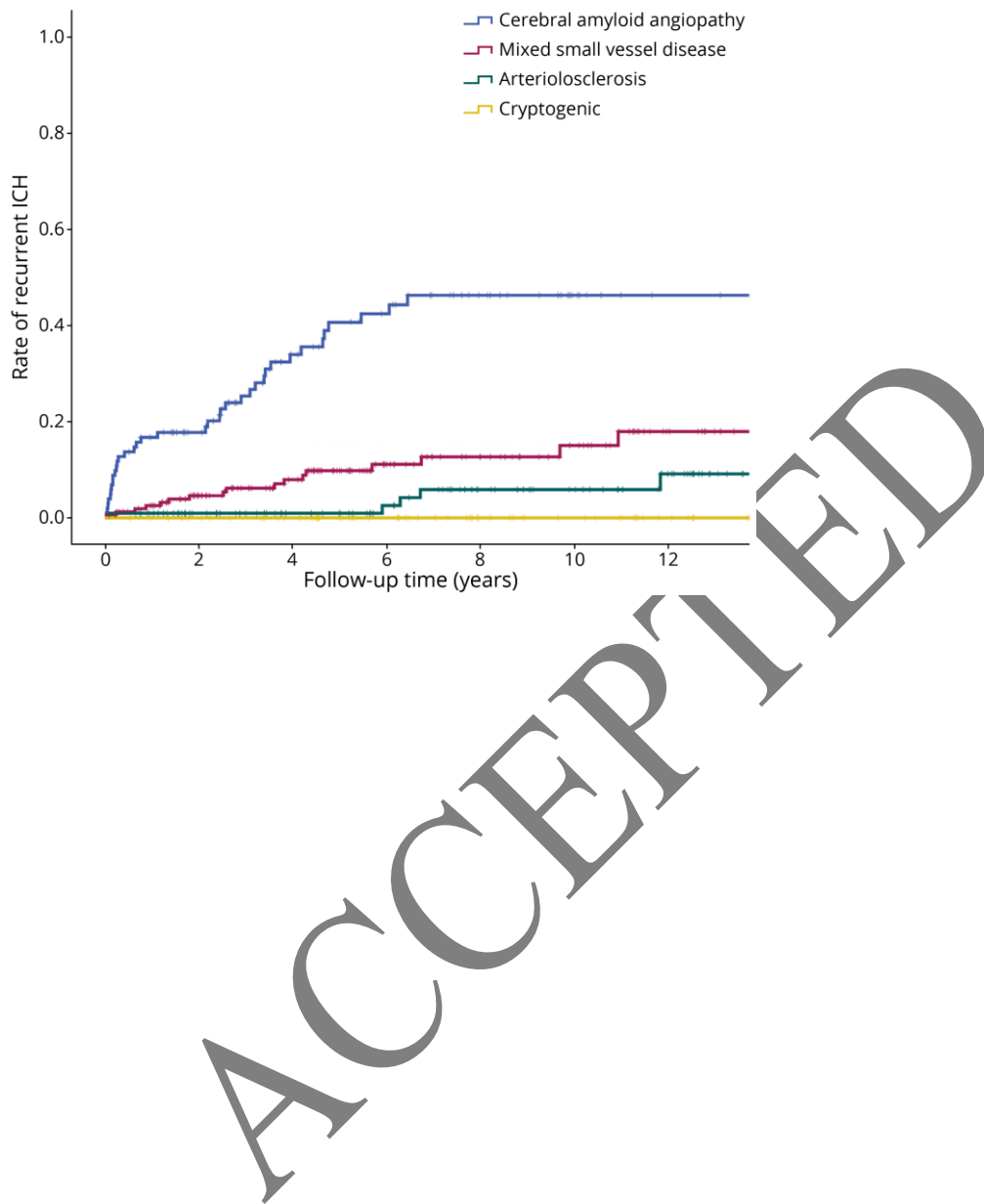


Figure 4: Kaplan-Meier curves for the recurrence risk of ICH according to aetiology determined on MRI



Neurology®

Association of Presence and Pattern of MRI Markers of Cerebral Small Vessel Disease With Recurrent Intracerebral Hemorrhage

Author(s): Simon Fandler-Höfler, Lena Obergottsberger, Gareth Ambler, et al.

Neurology published online June 22, 2023

DOI 10.1212/WNL.0000000000207510

This information is current as of June 22, 2023

Updated Information & Services	including high resolution figures, can be found at: http://n.neurology.org/content/early/2023/06/22/WNL.0000000000207510.full
Subspecialty Collections	This article, along with others on similar topics, appears in the following collection(s): Intracerebral hemorrhage http://n.neurology.org/cgi/collection/intracerebral_hemorrhage MRI http://n.neurology.org/cgi/collection/mri Outcome research http://n.neurology.org/cgi/collection/outcome_research
Permissions & Licensing	Information about reproducing this article in parts (figures, tables) or in its entirety can be found online at: http://www.neurology.org/about/about_the_journal#permissions
Reprints	Information about ordering reprints can be found online: http://n.neurology.org/subscribers/advertise

Neurology® is the official journal of the American Academy of Neurology. Published continuously since 1951, it is now a weekly with 48 issues per year. Copyright © 2023 The Author(s). Published by Wolters Kluwer Health, Inc. on behalf of the American Academy of Neurology. All rights reserved. Print ISSN: 0028-3878. Online ISSN: 1526-632X.

